

2. Crackower MA, Sarao R, Oudit GY *et al.* Angiotensin-converting enzyme 2 is an essential regulator of heart function. *Nature* 2002; **417**: 822–828.
3. Donoghue M, Hsieh F, Baronas E *et al.* A novel angiotensin-converting enzyme-related carboxypeptidase (ACE2) converts angiotensin I to angiotensin 1–9. *Circ Res* 2000; **87**: E1–E9.
4. Tipnis SR, Hooper NM, Hyde R *et al.* A human homolog of angiotensin-converting enzyme. Cloning and functional expression as a captopril-insensitive carboxypeptidase. *J Biol Chem* 2000; **275**: 33238–33243.
5. Vickers C, Hales P, Kaushik V *et al.* Hydrolysis of biological peptides by human angiotensin-converting enzyme-related carboxypeptidase. *J Biol Chem* 2002; **277**: 14838–14843.
6. Li N, Zimpelmann J, Cheng K *et al.* The role of angiotensin converting enzyme 2 in the generation of angiotensin 1–7 by rat proximal tubules. *Am J Physiol Renal Physiol* 2004; **288**: F353–F362.
7. Ferrario CM, Jessup JA, Gallagher PE *et al.* Effects of renin angiotensin system blockade on renal angiotensin-(1–7) forming enzymes and receptors. *Kidney Int* 2005; **68**: 2189–2196.
8. Rivière G, Michaud A, Breton C *et al.* Angiotensin-converting enzyme 2 (ACE2) and ACE activities display tissue-specific sensitivity to undernutrition-programmed hypertension. *Hypertension* 2005; **46**: 1169–1174.
9. Chappell MC, Modrall JG, Diz DI, Ferrario CM. Novel aspects of the renal renin-angiotensin system: angiotensin-(1–7), ACE2 and blood pressure regulation. In: Suzuki H, Saruta T (eds). *Kidney and Blood Pressure Regulation*. Karger: Basel, 2004, pp 77–89.
10. Chappell MC, Pirro NT, Sykes A, Ferrario CM. Metabolism of angiotensin-(1–7) by angiotensin converting enzyme. *Hypertension* 1998; **31**: 362–367.
11. Ferrario CM, Trask AJ, Jessup JA. Advances in the biochemical and functional roles of angiotensin converting enzyme 2 and angiotensin-(1–7) in the regulation of cardiovascular function. *Am J Physiol Heart Circ Physiol* 2005; **289**: H2281–H2290.
12. Allred AJ, Diz DI, Ferrario CM, Chappell MC. Pathways for angiotensin-(1–7) metabolism in pulmonary and renal tissues. *Am J Physiol Renal Physiol* 2000; **279**: F841–F850.
13. Gonzales-Villalobos R, Klassen RB, Allen PL *et al.* Megalin binds and internalizes angiotensin-(1–7). *Am J Physiol Renal Physiol* 2006; **290**: F1270–F1275.
14. Zhuo JL, Imig JD, Hammond TG *et al.* Ang II accumulation in rat renal endosomes during Ang II-induced hypertension: role of AT(1) receptor. *Hypertension* 2002; **39**: 116–121.
15. Huang L, Sexton DJ, Kirsten S *et al.* Novel peptide inhibitors of angiotensin-converting enzyme 2. *J Biol Chem* 2003; **278**: 15532–15540.
16. Gallagher PE, Chappell MC, Tallant EA *et al.* Distinct roles for ANG II and ANG-(1–7) in the regulation of angiotensin-converting enzyme 2 in rat astrocytes. *Am J Physiol Cell Physiol* 2005; **290**: C420–C426.
17. Ferrario CM, Jessup JA, Chappell MC *et al.* Effect of angiotensin converting enzyme inhibition and angiotensin II receptor blockers on cardiac angiotensin converting enzyme 2. *Circulation* 2005; **111**: 2605–2610.
18. Chappell MC, Ferrario CM. Angiotensin-(1–7) in hypertension. *Curr Opin Nephrol Hypertens* 1999; **88**: 231–235.
19. Pendergrass KD, Averill DB, Ferrario CM *et al.* Differential expression of nuclear AT1 receptors and angiotensin II within the kidney of the male congenic mRen2.Lewis rat. *Am J Physiol Renal Physiol* 2006; **290**: F1497–F1506

see original articles on pages 139 and 144

## Non-invasive assessment of kidney oxygenation: a role for BOLD MRI

RP Mason<sup>1</sup>

**Blood oxygen level-dependent (BOLD) contrast magnetic resonance imaging (MRI) has been applied to investigate kidney oxygenation in human patients. These investigations reflect the progress of radiology from a primarily anatomic discipline to one that provides insight into tissue physiology. In particular, magnetic resonance imaging (MRI) is non-invasive, uses no ionizing radiation, and provides insight into disease development and tissue physiology.**

*Kidney International* (2006) **70**, 10–11. doi:10.1038/sj.ki.5001560

In this issue, research groups from Northwestern University (Chicago, Illinois, USA) and the University of Berne (Switzerland) report having applied blood oxygen level-dependent (BOLD) contrast magnetic resonance imaging (MRI) to investigate kidney oxygenation in human patients.<sup>1,2</sup> These investigations reflect the progress of radiology from a primarily anatomic discipline to one that provides insight into tissue physiology. Progress in instrumentation, computing power, and data analysis has revolutionized the abilities of radiological techniques to provide non-invasive insight into disease development and tissue physiology. In particular, MRI is non-invasive and uses no ionizing radiation. Modern clinical magnetic resonance scanners can provide exquisite anatomy, but more importantly, magnetic resonance can provide images sensitive to multiple parameters, for example, longitudinal relaxation ( $T_1$  ( $=1/R_1$ )), transverse relaxation ( $T_2$  ( $=1/R_2$ )) and ( $T_2^*$  ( $=1/R_2^*$ )), and diffusion, with additional separation of water, fat, and metabolite images. These facets make MRI a complex discipline, but they open

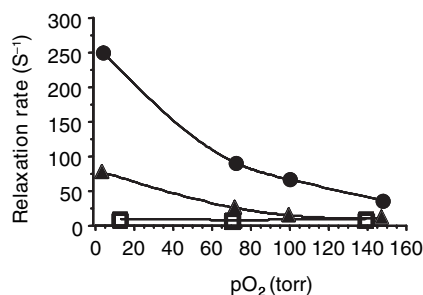
enormous opportunities for investigating tissue pathophysiology. The application of appropriate spin physics can give insight into tissue perfusion, intracellular water diffusion, blood flow, and oxygenation, which is most pertinent here.

The variation of the water proton nuclear magnetic resonance  $T_2$  with blood oxygenation was first reported by Thulborn *et al.* some 20 years ago.<sup>3</sup> Ogawa *et al.*<sup>4</sup> pioneered the application to tissues, and the BOLD approach has now become a mainstay for interrogating neurological function with so-called functional MRI. The observations are predicated on the paramagnetic properties of deoxyhemoglobin, which induces susceptibility gradients in blood, causing loss of signal in  $T_2^*$ -weighted magnetic resonance images. Conversion to oxyhemoglobin leads to signal gain.

A number of investigators<sup>5,6</sup> have shown relationships between  $R_2$  or  $R_2^*$  and partial pressure of oxygen ( $pO_2$ ) in blood, and an example is presented in Figure 1. In the range 4–148 torr, both  $R_2$  and  $R_2^*$  are sensitive to  $pO_2$ , whereas  $R_1$  is essentially invariant. Ultimately, complex quadratic relationships are often found over the range 0–760 torr, due to the sigmoidal binding of oxygen with hemoglobin. The formation of deoxyhemoglobin directly alters  $T_2$ , and this has been successfully applied to estimate  $pO_2$  in major blood vessels or the heart, brain, and abdomen. In other tissues, it can be a little more complicated,

<sup>1</sup>Laboratory of Prognostic Radiology, Department of Radiology, University of Texas Southwestern Medical Center, Dallas, Texas, USA

**Correspondence:** RP Mason, University of Texas Southwestern Medical Center at Dallas, 5323 Harry Hines Boulevard, Dallas, Texas 75390-9058, USA.  
E-mail: [ralph.mason@utsouthwestern.edu](mailto:ralph.mason@utsouthwestern.edu)



**Figure 1 | Relationship between nuclear magnetic resonance relaxation parameters  $R_1$  ( $\square$ ),  $R_2$  ( $\blacktriangle$ ), and  $R_2^*$  ( $\bullet$ ) and partial pressure of oxygen ( $pO_2$ ) in aliquots of fresh bovine blood observed by magnetic resonance imaging at 4.7 tesla. (Data kindly provided by L Jiang.)**

as individual image voxels often comprise both blood and surrounding tissues and now magnetic susceptibility gradients are pertinent as detected by  $R_2^*$ . Further complications arise because the signal may be influenced by blood flow, vascular volume, or hematocrit as well as  $pO_2$  itself.<sup>6</sup> Appropriate sequences can avoid flow effects.<sup>7</sup> Moreover, changes in the oxygen-hemoglobin dissociation curve may be influenced by such factors as pH, 2,3-diphosphoglycerate, and temperature,<sup>8</sup> which can modulate the fraction of deoxy-hemoglobin as a function of  $pO_2$  and  $R_2^*$ .

Prasad and colleagues have pioneered the use of BOLD MRI to investigate kidney disease particularly related to hypoxia with a number of reports in recent years. In their latest paper,<sup>1</sup> they demonstrate the use of a higher-field magnet (3 tesla) to examine kidney oxygenation with respect to water overload. It is widely recognized that the magnitude of the BOLD response increases at higher magnetic field. Meanwhile, Hofmann *et al.*<sup>2</sup> have examined BOLD signal response to administration of a number of common pharmaceutical drugs, which may be expected to be vasoactive and potentially induce hypoxia in kidneys. Because the human kidney is very well perfused, one might expect a particularly large BOLD response to variations in vascular oxygenation. However, the blood vessels appear too small to allow differentiation of vessel from tissue in these studies. Nonetheless, separation of the medulla and cortex is readily achieved. Both teams report that the  $T_2^*$  of the cor-

tex is considerably shorter than that of the medulla. Meanwhile, the  $T_2^*$  of the medulla is considerably higher at 3 tesla and was found to undergo a significant change upon water load. The investigators clearly demonstrate clinical applicability of these measurements with groups of five and 30 patients, respectively.<sup>1,2</sup> One of the largest issues for BOLD MRI *in vivo* is the elimination of motion artifacts, as small errors in signal co-registration for subtraction imaging can lead to anomalous results. In this case, both teams of investigators have chosen direct measurement of  $R_2^*$  rather than simple image subtraction, which should largely obviate problems of image registration.

A lack of signal change with respect to intervention (that is, drug administration) may be reasonably interpreted as constant renal vascular oxygenation. However, there must be caution in interpreting changes in signal directly in terms of  $pO_2$ . Other investigators, most notably Baudalet and Gallez,<sup>9</sup> have shown that a given change in  $R_2^*$  or signal intensity may relate to vastly different changes in  $pO_2$ . Thus, although there is a distinct relationship, quantitative interpretation must be applied with caution. Changes in  $R_2^*$  may be caused by vasodilatation or pH and not necessarily  $pO_2$ . Furthermore, an increase in  $R_2^*$  may reflect a decrease in kidney vascular oxygenation (hypoxia), but not necessarily one that achieves hypoxia or anoxia.

Ultimately, the beauty of BOLD MRI is that it uses blood itself as the reporter of vascular oxygenation. There is no need for exogenous reporter molecules. Prasad and colleagues<sup>1</sup> and Hofmann *et al.*<sup>2</sup> simply measured changes in  $R_2^*$  that accompanied drug administration. An alternative approach is to examine the ability to modulate vascular oxygenation using inhaled gas as a contrast agent. This can be highly sensitive to alterations in the rate of oxygen delivery and has been used to evaluate tumor vascular oxygenation.<sup>7</sup> Use of inhaled oxygen as a contrast agent can lead to much larger signal responses, potentially amplifying the effects of pharmaceutical interventions. Beyond the applications shown for BOLD by Prasad and colleagues<sup>1</sup> and Hofmann *et al.*<sup>2</sup> one may envisage examination of renal-cell carcinoma.

The BOLD technique must be placed in the context of other approaches to assessing tissue oxygenation. Studies with electrodes are widely reported, but highly invasive. Near-infrared spectroscopy or imaging could provide direct insight into vascular oxygenation, but currently the ability to discriminate deep-seated tissues and organs is somewhat limited. Other nuclear magnetic resonance approaches can determine absolute  $pO_2$  within tissues, most notably on the basis of the spin lattice relaxation rate,  $R_1$ , of oxygen reporter molecules such as hexafluorobenzene.<sup>10</sup> Of course, such approaches are invasive, as the agents must be introduced into the tissues being interrogated.

In conclusion, Prasad and colleagues<sup>1</sup> and Hofmann *et al.*<sup>2</sup> provide further evidence for the utility of BOLD MRI in the investigation of kidney physiology, and this may be important for assessing drug activity or the progression of disease.

#### REFERENCES

1. Tumkur SM, Vu AT, Li LP *et al.* Evaluation of intrarenal oxygenation during water diuresis: a time-resolved study using BOLD MRI. *Kidney Int* 2006; **70**: 139–143.
2. Hofmann L, Simon-Zoula S, Nowak A *et al.* BOLD-MRI for the assessment of renal oxygenation in humans: acute effect of nephrotoxic xenobiotics. *Kidney Int* 2006; **70**: 144–150.
3. Thulborn KR, Waterton JC, Matthews PM *et al.* Oxygenation dependence of the transverse relaxation time of water protons in whole blood at high field. *Biochim Biophys Acta* 1982; **714**: 265–270.
4. Ogawa S, Lee TM, Kay AR *et al.* Brain magnetic resonance imaging with contrast dependent on blood oxygenation. *Proc Natl Acad Sci USA* 1990; **87**: 9868–9872.
5. Silvennoinen MJ, Clingman CS, Golay X *et al.* Comparison of the dependence of blood  $R_2$  and  $R_2^*$  on oxygen saturation at 1.5 and 4.7 Tesla. *Magn Reson Med* 2003; **49**: 47–60.
6. Spees WM, Yablonskiy DA, Oswald MC *et al.* Water proton MR properties of human blood at 1.5 Tesla: magnetic susceptibility,  $T(1)$ ,  $T(2)$ ,  $T^*(2)$ , and non-Lorentzian signal behavior. *Magn Reson Med* 2001; **45**: 533–542.
7. Howe FA, Robinson SP, McIntyre DJ *et al.* Issues in flow and oxygenation dependent contrast (FLOOD) imaging of tumours. *NMR Biomed* 2001; **14**: 497–506.
8. Comroe JH. The transport of oxygen by blood. in: *Physiology of Respiration*. Year Book Medical Publishers: Chicago, 1965, pp 160–166.
9. Baudalet C, Gallez B. How does blood oxygen level-dependent (BOLD) contrast correlate with oxygen partial pressure ( $pO_2$ ) inside tumors? *Magn Reson Med* 2002; **48**: 980–986.
10. Zhao D, Jiang L, Mason RP. Measuring changes in tumor oxygenation. *Methods Enzymol* 2004; **386**: 378–418.
11. Jiang L. Dynamic magnetic resonance imaging for tumor prognosis. PhD thesis. Univ. Texas Southwestern Medical School 2006.