

1042-3

### Irrigated-Tip Versus 8-mm-Tip Catheter for Radiofrequency Ablation of Common Atrial Flutter in Patients With Cavo-Tricuspid Isthmus Lengths > 35 mm: Is the Catheter Selection or the Cavo-Tricuspid Anatomy a Determinant Factor for Atrial Flutter Ablation?

**Antoine Da Costa**, Bernard Samuel, Abdel Khieil, Cecile Romeyer-Bouchard, Christophe Robin, Emmanuel Faure, Alexis Cerisier, Karl Isaaz, Hôpital Nord, Saint-Etienne, France

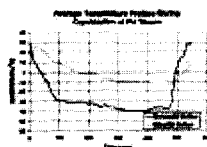
Radiofrequency ablation (RFA) lesions are expected to be deeper with a cooled-tip RFA cath (cRFA) and longer with an 8mm-tip cath. The cavo-tricuspid isthmus (CTI) length and the anatomy may influence RFA in pts with atrial flutter (AFL). Objectives. This prospective study on AFL RFA was: (1) to randomly compare the efficacy of an 8mm-tip cath or a cRFA in pts with CTI > 35 mm; (2) to evaluate the impact of CTI morphology and length. Methods. During 9 months, 115 pts with AFL were eligible; 101 pts (66±12 years; 12 females) accepted the protocol and underwent an isthmogram. Groups (gps) were considered in the CTI length (short <35 mm or long > 35 mm) and CTI anatomy: straight; concave or with a pouchlike recess. An 8-mm-tip cath was used for pts with a short CTI. The end-point was a bi-directional block. Results: history of AFib(41/101), structural heart disease (37/101), LV EF (59±12%), CTI dimension (34±6 mm), 60 pts with short CTI, bi-directional block (98%), mean RF application (12.6±13 min), mean fluoroscopic time (14±13 min) and RF failure (2%). There were no complications. In pts with long CTI (n=41), 22 patients were randomly assigned in the 8-mm gp and 19 pts in the c-RFA gp. The number of applications (min) and X-ray exposition (min) did not differ between an 8 mm-tip or c-RFA cath respectively: 16±15 vs 19±14 min and 18.6±13 vs 18.7±15 min. In the overall population, number of applications and X-Ray exposure differed between pts with short and long CTI (8.5±9 vs 18±15 min; p<.001) and (11±10 vs 19±14; p=.01). Pts with short-straight CTI had significantly (p<.05\*) lower RFA applications and X-ray exposure compared with all CTI morphologies with the exception of the short-concave CTI: short-straight\* (6±3 and 8.5±3.5; n=42); short-concave (9±5 and 11±8; n=7); short-pouchlike recess (19±19 and 24±17; n=10); long-straight (16±15 and 19±17; n=14); long-concave (20±18 and 19±13; n=14); long-pouchlike recess (19±14 and 20±14; n=14). Conclusions. RFA procedure does not differ between 8mm-tip and c-RFA catheters in pts with CTI > 35 mm. AFL RFA is influenced by both CTI anatomy and length. A short-straight CTI represents the only morphology associated with significantly lower RFA applications and X-ray exposure.

1042-4

### Cryoablation of the Pulmonary Veins Using a Novel Balloon Catheter

**Arthur R. Garan**, Teresa Mihalik, Catherine Cartier, Lea Capuano, David Holtan, Christopher Song, Munther K. Homoud, Mark S. Link, N.A. Mark Estes, III, Paul J. Wang, Tufts New England Medical Center, Boston, MA, CryoCath, Inc., Montreal, PQ, Canada

**Background:** Pulmonary vein (PV) isolation has emerged as a promising technique for the treatment of patients with drug-refractory atrial fibrillation. Cryoenergy has been used extensively to treat cardiac arrhythmias. It is hypothesized that a balloon-based cryogenic catheter system may be effective in achieving transmural lesions for PV isolation. **Methods:** Three excised ovine hearts with lungs carefully removed to preserve the PVs were placed in a bath of circulating saline (37°C). The PVs were cannulated and perfused with saline (37°C) at physiologic flow rates. To access the four PVs with the cryo-catheter and to allow good visualization, the left ventricle and left atrium were sliced open. Prior to cryoablation, the balloon was deployed and correctly positioned at the ostia of the pulmonary veins. A full 8-minute ablation was then performed. Thermocouples positioned on the endocardial (balloon surface-tissue interface) and epicardial surfaces of the ostia were used to determine whether transmural freezing was achieved. **Results:** The mean temperatures measured on the endocardial and epicardial tissue in six PV ablations was -38.8 ±6.9°C and -10.0°C ±7.5°C, respectively, for an average vein thickness of 3.3 ±1.4mm. The average temperature profiles are shown in the figure below. **Conclusions:** A novel cryoablation balloon catheter is capable of achieving transmural freezing of pulmonary vein. The catheter has promise for future clinical therapy of atrial fibrillation.



1042-5

### Minimally Invasive and Robotic Treatment of Atrial Fibrillation Using Microwave Energy

**Mathew R. Williams**, Mauricio Garrido, Jennifer Casher, L. Wiley Nifong, Kimberly Klein, Deon W. Vigilance, Mehmet Oz, Yoshifumi Naka, W. Randolph Chitwood, Michael Argenziano, Columbia University, New York, NY, East Carolina University, Greenville, NC

**Introduction:** Surgical treatment of atrial fibrillation (AF) has been found to be 70-95% successful but remains quite invasive. This procedure would be more beneficial if applied using minimally invasive techniques on the beating heart.

**Methods:** Epicardial PV isolation and resection of the left atrial appendage (LAA) was attempted on 13 canines via a 3 cm right mini-thoracotomy and 3 left thoracoscopy ports. The LAA was resected using a standard stapling device. Using microwave energy, a contiguous lesion was created on the posterior left atrium encircling all the pulmonary veins. Two types of early prototype antennae were utilized: 0.05 in. OD (n=7) and a more efficient 0.07 in. OD (n=6). During all surgeries, right atrial and right superior PV electrocar-

diograms were recorded to determine if electrical isolation was successfully created by the ablation. Isolation was further confirmed by pacing from both within and outside of the intended lesions. Animals were allowed to survive 2 hours after completion of the procedure. Multiple atrial samples were taken from each animal to characterize lesion depth. The same procedure was then applied in 6 animals using a totally endoscopic approach with robotic assistance.

**Results:** In the first set of animals (0.05 in. OD), microwave lesions did not produce electrophysiologic isolation of the pulmonary veins. 49% of these lesions were transmural. In the latter group of animals (0.07 in. OD), microwave lesions created complete isolation in all animals and this persisted to the time of sacrifice. 67% of these lesions were transmural. The entire procedure was successfully carried out using the minimally invasive techniques in all animals in less than 2 hours. The totally endoscopic robotic procedure was completed in all six animals.

**Conclusion:** A minimally invasive procedure for atrial fibrillation involving either mini-invasions or robotic assistance that includes pulmonary vein isolation and LAA removal can be successfully completed. In canines, epicardial microwave isolation of all the pulmonary veins, using a 0.07 inch OD antennae can repeatedly create electrical isolation.

1042-6

### Linear Ethanol Jet Injection for Surgical Treatment of Atrial Fibrillation: Canine Survival Study

**Mauricio J. Garrido**, Mathew R. Williams, Aftab Kherani, Deon W. Vigilance, Darcy Parish, Hadar Hermoni, Yoshifumi Naka, Craig R. Smith, Jr., Mehmet C. Oz, Michael Argenziano, Columbia University, New York, NY

**Background:** The key to minimally invasive surgical treatment of atrial fibrillation is the ability to create transmural atrial lesions through the epicardium on the beating heart. Lesion creation using traditional hyperthermic energy sources has been limited by the heat sink effect of the flowing blood at the endocardial surface. Linear chemical ablation offers a potential solution to this problem as it is not dependent on tissue heating. We evaluated the chronic histologic and electrophysiologic effects of linear epicardial ethanol ablation on atrial tissue using needle-free jet injection technology.

**Methods:** The epicardium was exposed via sternotomy in 4 dogs. Pure ethanol was injected into the left atrium with needle-free injection utilizing a 3 cm linear probe. Several ablations were performed to create one contiguous line encircling all pulmonary veins. After 4-week survival, lesions were excised and assessed grossly by staining with tetrazolium tetrachloride vital dye and histologically with a trichrome stain. Electrophysiologic (EP) effectiveness was determined by pacing from the pulmonary veins at baseline, post-ablation and at sacrifice. Successful isolation was defined as the inability to pace the remainder of the atrium beyond the lesion at a pacing current 3 times the diastolic threshold.

**Results:** In total, 75% of lesions created were transmural (33 of 44 lesion segments measured). There was no significant difference between atrial thickness in transmural and non-transmural lesions (3.5 ±1.3 mm v. 4.4 ±1.7 mm, p=0.06, respectively). There was EP isolation in 2 of 4 dogs post-ablation and 1 of 4 dogs after 4-week survival. Lack of EP isolation was associated with at least one non-transmural segment in the lesion circle.

**Conclusions:** Transmural linear lesions on the beating canine heart can be created with a needle-free epicardial ethanol injection technique. Transmurality with contiguity of the encircled pulmonary veins was correlated with EP isolation in this series. Ethanol ablation effectively overcomes the shortcomings of hyperthermic and hypothermic atrial epicardial ablation techniques and is a promising method of treating atrial fibrillation on the beating heart.

1042-7

### Concomitant Microwave Ablation Is a Superior Concept for Curative Treatment of Permanent Atrial Fibrillation in Comparison to Cardiosurgical Procedures Alone

**Michael Knaut**, Sems M. Tugtekin, Stefan G. Spitzer, Vassilios Gulielmos, Heart Center Dresden University Hospital, Dresden, Germany, Institute for Cardiovascular Research, Dresden, Germany

**Background:** Microwave ablation (MW) has been established as a safe and efficient procedure for the treatment of permanent atrial fibrillation (pAF) in patients with the need of further concomitant cardiosurgical therapy. We performed a retrospective study comparing the follow up of patients with pAF and cardiosurgical procedures alone with patients receiving MW as a concomitant procedure to a cardiosurgical intervention.

**Methods:** Group A included 62 patients, age 72 ± 9 years, ejection fraction 25 - 74 %, left atrial diameter 53 ± 9 mm suffering from mitral valve disease (MVD) (n=11), coronary heart disease (CAD) (n=35) or aortic valve disease (AVD) (n=16) with pAF documented for 6.9 ± 5.5 years. Cardiosurgical therapy included mitral valve interventions, CABG or biological aortic valve replacement. Group B included 88 patients, age 67 ± 4 years, ejection fraction 26 - 76 %, left atrial diameter 52 ± 6 mm with documented pAF for 6.4 ± 4 years suffering from MVD (n=49), CAD (n=26) or AVD (n=8). The mean additional ablation time was 13 min. **Results:** Survival rate in group A was 94.2% and 98% in group B. There were no ablation related complications. In the 1- year follow up in group A 6 % of patients with mitral valve disease, 9 % with CAD and 5 % of patients with aortic valve disease were in SR. In Group B 62 % of patients with MVD, 72 % with CAD and 83 % of patients with AVD were in SR. **Conclusions:** Our results illustrate high efficiency and safety of MW in patients with pAF and different concomitant cardiosurgical procedures independently from the nature of cardiac disease in comparison to isolated cardiosurgical procedures. As a consequence of this study we have extended this approach to most patients with cAF and cardiosurgical disease.