

Objectives: A pulseless limb is considered a hard sign of vascular injury after penetrating trauma in the civilian population. However, the reliability of this finding has never been examined in combat trauma. The purpose of this study was to examine the reliability of the pulseless limb in the combat trauma population.

Methods: The Joint Theater Trauma Registry (JTTR) identified all patients who presented to a military treatment facility in Kandahar, Afghanistan, with a penetrating extremity injury during a 2-year period. Patients with pulseless limbs were followed up, and the results of the subsequent computed tomographic angiogram (CTA) or angiogram recorded. Patient demographics and injury patterns were examined. Standard statistical analysis was performed.

Results: From 2011 to 2012, 638 patients were treated for penetrating extremity injuries. The mechanisms of injury were explosions (62%), firearms (20%), or other etiology (18%). Of the 566 patients with complete records, 436 (77%) presented with palpable pulses, 119 (21%) presented with a pulseless limb, and 11 (2%) presented with other hard signs of vascular injury. Forty-two patients (35%) with a pulseless limb underwent an immediate CTA (83%) or angiogram (17%) that identified no vascular injury. Twenty-six of those patients (62%) sustained an injury from an explosion, 14 (33%) from a gunshot wound, and two (5%) from other causes. Patients with an abnormal pulse examination and normal CTA/angiogram were compared with all other patients after a penetrating injury. There was a significantly higher chance of a pulseless limb as a result of a gunshot injury, but not an explosion or other mechanism of injury ($P < .0005$). Patient variables and risk factors were analyzed. Acidosis ($P < .0005$), gunshot wounds ($P = .025$), and battle injuries ($P = .031$) were associated with an abnormal pulse examination and normal CTA or angiogram.

Conclusions: Unlike previous studies, our results demonstrate that a pulseless limb poorly predicts a vascular injury in this population. Acidosis, a surrogate for under-resuscitation after penetrating injuries, may contribute to the decreased accuracy of the physical examination in combat warriors. Future studies must continue to focus on improved algorithms for accurate diagnosis of extremity vascular injuries in this population.

Author Disclosures: J. F. Quail: None; V. S. McDonald: None; K. K. Carter: None; J. S. Weiss: None; K. Casey: None.

Popliteal Artery Trauma: Is There a Standardized Approach To Managing These Patients? Results of a Survey

Elina Quiroga, MD, Niten Singh, MD, Benjamin W. Starnes, MD, Nam T. Tran, MD. University of Washington, Seattle, Wash

Objective: Popliteal artery trauma is a devastating injury that affects mostly young, active patients and has a reported high rate of limb loss. Not only is there scarce information on long-term outcomes, little is known on how these patients are managed periprocedurally. The purpose of this study was to describe the current management practices in our vascular community regarding popliteal artery trauma.

Methods: A voluntary, anonymous survey regarding preoperative evaluation, intraoperative management, postoperative medications, and follow-up recommendations was sent electronically to 202 members of Western Vascular Society during March 2014.

Results: Ninety-seven surgeons responded to the survey (response rate, 48%); of these, 65% were in an academic practice and 35% were in a hospital-based/private practice. Of those surgeons responding, 29% managed 1 to 5 trauma cases/year, 26% managed 6 to 10 trauma cases/year, 24% managed 10 to 20 trauma cases/year; and 19% managed >20 trauma cases/year. The imaging modality used in patients when the ankle-brachial index (ABI) was <0.9 was computed tomography angiography, 46%; arteriography, 21%; and arterial duplex ultrasound (DU), 30%. Regarding procedural details and proximal control of the vessel, 60% of surgeons performed a direct cutdown on the proximal popliteal artery, 30% used a tourniquet, and 10% responded "other" (balloons, common femoral artery cutdown). Also, no consensus response was obtained regarding antiplatelet or anticoagulant therapy after arterial or venous repair (Table). The response to postoperative DU surveillance was varied as well: 71% recommended DU during the first month, 51% DU at 6 months, 48% DU at 1 year, and 39% recommended DU every year.

Conclusions: The results of this survey reveal that even in our regional society, management of popliteal artery trauma varies widely. Because this injury usually results in a consultation to the vascular surgeon, a long-term outcome study with cost-benefits analysis of these practices needs to be done to provide the best care to our patients.

Author Disclosures: E. Quiroga: None; N. Singh: None; B. W. Starnes: None; N. T. Tran: None.

What Is the Normal Toe Brachial Index? Results From Healthy Young Adults

Adrian Fung, Whitney L. Quong, Rollin Y. Yu, York Hsiang, MD. Division of Vascular Surgery, University of British Columbia, Vancouver, British Columbia, Canada

Objective: The purpose of this study was to measure the toe-brachial index (TBI) in healthy young adults and compare it with the accepted reference range.

Methods: Medical students from the undergraduate class were prospectively recruited. Participants completed questionnaires on physical measurements (height, weight), lifestyle factors (physical activity and type, smoking status, alcohol consumption), and medical history (medications, relevant diagnoses, family history). Bilateral brachial, ankle (using both dorsalis pedis and posterior tibial arteries), and toe blood pressures were measured. TBI was calculated as the mean great toe blood pressure divided by the average of the higher arm systolic blood pressure.

Results: Forty medical students, with a mean age of 24.7 ± 2.1 years, without any comorbidities were studied. Participants maintained relatively healthy lifestyles (hours of activity per week: 5.0 ± 2.6 ; body mass index: 21.7 ± 5.8 kg/m²). Caffeine and alcohol consumption was modest (mean of 7.4 cups and 1.9 servings, respectively). There were no current smokers. The mean brachial blood pressure was 121 ± 18 mm Hg (right) and 116 ± 18 mm Hg (left). The TBI was 0.95 ± 0.22 (right) and 0.97 ± 0.24 (left) for men, and 0.87 ± 0.25 (right) and 0.86 ± 0.39 (left) for women.

Conclusions: The results of TBI (left: 0.92 ± 0.24 , right: 0.93 ± 0.34) in this healthy population differ significantly from the referenced normal range. Our findings (95% confidence interval) suggest that the accepted value of normal being >0.7 is too low, especially for men, and may promote underdiagnosis of peripheral vascular disease. In

Table. Type and duration of antiagregant or anticoagulant treatment after repair

Variable	6 weeks (%)	3 months (%)	6 months (%)	Lifelong (%)	None (%)
Interposition bypass					
Aspirin, 81 mg/d	9	8	16	28	39
Aspirin, 325 mg/d	0	4	17	28	51
Clopidogrel	9	8	0	0	83
Arterial primary repair					
Aspirin, 81 mg/d	9	8	22	20	41
Aspirin, 325 mg/d	0	5	15	27	53
Clopidogrel	8	8	0	0	84
Vein repair					
Heparin/warfarin	8	23	34	0	35
Aspirin	6	12	13	47	22
Clopidogrel	8	6	1.5	1.5	83
Direct thrombin inhibitor	3	7	0	0	90

addition, there is a significant difference between male and female TBI ($P < .05$). Thus, we recommend that the TBI reference range be modified to increase the clinical utility of this measurement and promote timely intervention.

Author Disclosures: A. Fung: None; W. L. Quong: None; R. Y. Yu: None; Y. Hsiang: None.

Outcomes Following Stent Graft Therapy of Dissection-Related Aneurysmal Degeneration in the Descending Thoracic Aorta

Derek P. Nathan, MD, Sherene Shalhub, MD, Gale L. Tang, MD, Matthew P. Sweet, MD, Edward D. Verrier, MD, Nam T. Tran, MD, Gabriel S. Aldea, MD, Benjamin W. Starnes, MD. University of Washington, Seattle, Wash

Objectives: Although stent graft therapy has emerged as a treatment option for dissection-related aneurysmal degeneration in the descending thoracic aorta (DRAD DTA), questions remain concerning the incidence of retrograde dissection, spinal cord ischemia, and secondary aortic interventions.

Methods: Data on patients who underwent stent graft therapy for DRAD DTA at a single institution between January 2006 and September 2013 were retrospectively analyzed. Perioperative and midterm outcomes were assessed.

Results: Forty-five patients underwent stent graft therapy for DRAD DTA during the study period. Patients were a mean age of 58 ± 12 years, and 73% ($n = 33$) were men. Four patients (9%) underwent nonoperative repair for rupture or refractory pain. Previous type A dissection repair was performed in 27% ($n = 12$) of patients; 67% ($n = 8$) of these patients underwent aortic arch replacement or debranching before or at the time of stent graft therapy. The left subclavian artery was covered in 49% ($n = 22$) of patients, and revascularization was performed in 86% ($n = 19$). Abdominal aortic debranching was performed in four patients. Spinal drains were used in 73% ($n = 33$) of patients. Spinal cord ischemia developed in three patients: two cases resolved and one improved. There were no cases of retrograde aortic dissection. The 30-day mortality was 4% ($n = 2$); one death was in a ruptured patient. Mean clinical follow-up was 29 ± 21 months (two patients had no follow-up). Mean radiographic follow-up was 25 ± 16 months (four patients had no radiographic follow-up). Of the 39 patients with radiographic follow-up, 85% ($n = 33$) had reduced or stable aneurysm diameters; 12% ($n = 4$) of these patients underwent secondary aortic interventions. An additional patient died during an attempted secondary aortic intervention. The 1-year and 3-year Kaplan-Meier survival was 91% and 84%, respectively (Fig).

Conclusions: Stent graft therapy can be performed safely and effectively in the management of DRAD DTA. In this single-center study, there were no cases of retrograde dissection and one case of permanent spinal cord ischemia. Eighty-five percent of patients with radiographic follow-up had reduced or stable aneurysm diameters. Aortic arch and abdominal aortic interventions may play an important role in management of DRAD DTA.

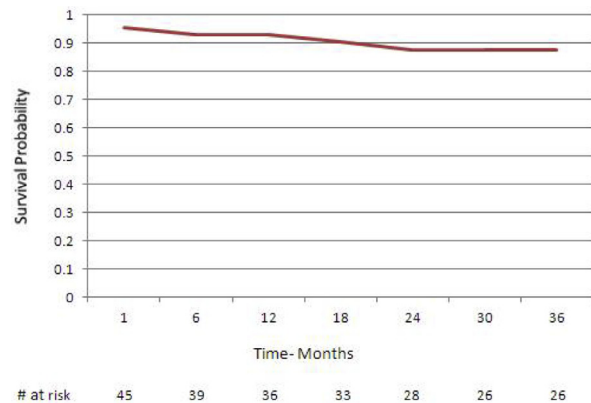


Fig. Kaplan-Meier survival of patients undergoing stent graft therapy of dissection related aneurysmal degeneration in the descending thoracic aorta.

Author Disclosures: D. P. Nathan: None; S. Shalhub: None; G. L. Tang: None; M. P. Sweet: None; E. D. Verrier: None; N. T. Tran: None; G. S. Aldea: None; B. W. Starnes: None.

Staged Hybrid Repair of Combined Ascending/Descending Thoracic Aortic Aneurysms Using the Frozen Elephant Trunk Technique With the Cook Zenith Tx2 Stent Graft

Osvaldo Yano, MD, Vicken Melikian, MD, Daniel Pellegrini, MD, Hong T. Hua, MD. Vascular Surgery, Kaiser Permanente San Francisco, San Francisco, Calif

Objectives: This study presents our results with a novel approach to combined ascending/descending aortic aneurysms treated with staged frozen elephant trunk technique.

Methods: Between January 2011 and December 2013, 149 patients underwent ascending and 38 descending thoracic aortic aneurysm repairs at our institution. Within this cohort, five patients underwent staged frozen elephant trunk technique as a treatment modality (Fig 1). The first stage involved sternotomy, cardiopulmonary bypass, and circulatory arrest to allow replacement of the ascending aorta using a hemiarch repair (Fig 2, A). Before closure of the distal arch anastomosis, the Cook Zenith TX2 stent graft was unsheathed and directly anastomosed to the aorta distal to the left common carotid or left subclavian origin. Patients were allowed to recover and brought back for second stage endovascular stent graft repair to exclude the descending aortic aneurysm (Fig 2, B).

Results: There were no perioperative deaths, spinal cord ischemia, or attachment site endoleaks. One embolic stroke occurred during the hemi-arch repair. This patient recovered fully and subsequently underwent a successful stent graft repair of her descending thoracic aortic aneurysm. No secondary intervention has been needed to date, with median follow-up of 13 months.

Conclusions: Although limited, our experience demonstrates that the utilization of a commercially available stent graft can provide a consistent and reliable device for use in the frozen elephant trunk. By concentrating our efforts initially to the open repair of the ascending/arch segment, the need for extended circulatory arrest and thus systemic ischemia is minimized. Subsequent staged endovascular repair of the descending thoracic aortic segment is facilitated by the presence of a

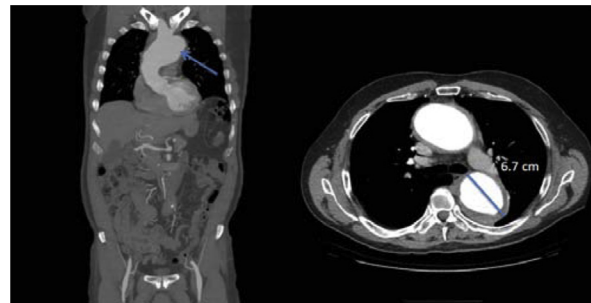


Fig 1. Pre-op.

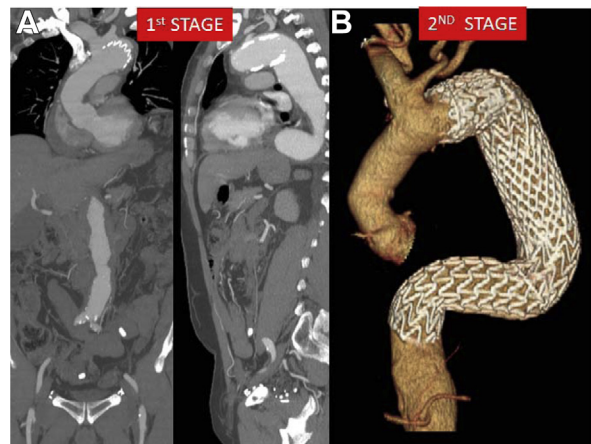


Fig 2. A, First stage repair; B, Second stage completion repair.