




## Critical Reviews in Oncology/Hematology

journal homepage: [www.elsevier.com/locate/critrevonc](http://www.elsevier.com/locate/critrevonc)

## Neurofibromatosis type 1 associated low grade gliomas: A comparison with sporadic low grade gliomas



Jelte Helfferich<sup>a,c</sup>, Ronald Nijmeijer<sup>b</sup>, Oebele F. Brouwer<sup>c</sup>, Maartje Boon<sup>c</sup>,  
Annemarie Fock<sup>c</sup>, Eelco W. Hoving<sup>d</sup>, Lisette Meijer<sup>a</sup>, Wilfred F.A. den Dunnen<sup>b</sup>,  
Eveline S.J.M. de Bont<sup>a,\*</sup>

<sup>a</sup> Department of Paediatrics, Beatrix Children's Hospital, Paediatric Oncology/Hematology Division, University Medical Center Groningen, University of Groningen, Groningen, The Netherlands

<sup>b</sup> Department of Pathology and Medical Biology, Pathology Division, University Medical Center Groningen, University of Groningen, Groningen, The Netherlands

<sup>c</sup> Department of Neurology, Paediatric Neurology Division, University Medical Center Groningen, University of Groningen, The Netherlands

<sup>d</sup> Department of Neurosurgery, University Medical Center Groningen, University of Groningen, Groningen, The Netherlands

## Contents

1. Introduction: neurofibromatosis type 1 .....	31
2. NF1 and malignancies .....	31
3. NF1 and low grade gliomas .....	31
3.1. Phenotype .....	31
3.2. Location .....	32
3.2.1. Supratentorial low grade gliomas .....	32
3.2.2. Infratentorial low grade gliomas .....	34
3.2.3. Comparison of supratentorial and infratentorial lesions .....	34
3.3. Tumourigenesis .....	34
3.3.1. NF1-associated pilocytic astrocytomas .....	35
3.3.2. Comparison with sporadic PA .....	35
3.4. Signalling pathways .....	35
3.4.1. MAPK-pathway .....	35
3.4.2. mTOR-pathway .....	36
3.5. Tumour micro-environment .....	36
3.6. Angiogenesis .....	37
4. Treatment .....	37
5. Conclusions .....	38
Conflict of interest .....	38
Funding .....	38
References .....	38
Biographies .....	41

## ARTICLE INFO

## Article history:

Received 15 April 2015

Received in revised form 24 March 2016

Accepted 12 May 2016

## ABSTRACT

Neurofibromatosis type 1 (NF1) is an autosomal dominant disorder, associated with a variable clinical phenotype including café-au-lait spots, intertriginous freckling, Lisch nodules, neurofibromas, optic pathway gliomas and distinctive bony lesions. NF1 is caused by a mutation in the NF1 gene, which codes for neurofibromin, a large protein involved in the MAPK- and the mTOR-pathway through RAS-RAF signalling.

**Abbreviations:** NF1, neurofibromatosis type 1; LGG, low grade glioma; MAPK, mitogen activated protein kinase; mTOR, mammalian target of rapamycin; PA, pilocytic astrocytoma; MPNST, malignant peripheral nerve sheath tumours; GAP, GTPase-activating protein; RB, retinoblastoma; GFAP, glial fibrillary acid protein; OPG, optic pathway glioma; JNK, c-Jun-Nh<sub>2</sub>-kinase; FTI, Farnesyltransferase inhibitors.

\* Corresponding author at: University Medical Center Groningen, Department of Paediatrics, Beatrix Children's Hospital, Paediatric Oncology Division, Hanzeplein 1, PO Box 30001, 9700 RB, Groningen, The Netherlands.

E-mail address: [e.s.j.m.de.bont@umcg.nl](mailto:e.s.j.m.de.bont@umcg.nl) (E.S.J.M. de Bont).

<http://dx.doi.org/10.1016/j.critrevonc.2016.05.008>

1040-8428/© 2016 The Author(s). Published by Elsevier Ireland Ltd. This is an open access article under the CC BY license (<http://creativecommons.org/licenses/by/4.0/>).

**Keywords:**

Neurofibromatosis  
 NF1 gene  
 BRAF:K11A1549 fusion  
 Low grade glioma  
 Pilocytic astrocytoma

NF1 is a known tumour predisposition syndrome, associated with different tumours of the nervous system including low grade gliomas (LGGs) in the paediatric population. The focus of this review is on grade I pilocytic astrocytomas (PAs), the most commonly observed histologic subtype of low grade gliomas in NF1. Clinically, these PAs have a better prognosis and show different localisation patterns than their sporadic counterparts, which are most commonly associated with a KIAA1549:BRAF fusion. In this review, possible mechanisms of tumourigenesis in LGGs with and without NF1 will be discussed, including the contribution of different signalling pathways and tumour microenvironment. Furthermore we will discuss how increased understanding of tumourigenesis may lead to new potential targets for treatment.

© 2016 The Author(s). Published by Elsevier Ireland Ltd. This is an open access article under the CC BY license (<http://creativecommons.org/licenses/by/4.0/>).

## 1. Introduction: neurofibromatosis type 1

Neurofibromatosis type 1 (NF1) or von Recklinghausen's disease is an autosomal dominant disorder with a worldwide incidence of 1 per 2500–3000 individuals. It is characterized by the presence of café-au-lait spots, intertriginous freckling, Lisch nodules, neurofibromas, optic pathway gliomas and distinctive bony lesions. Other features include malignant peripheral nerve sheath tumours (MPNSTs), neurocognitive defects, epilepsy and cardiovascular abnormalities (Williams et al., 2009). NF1 is caused by a mutation in the NF1 gene, located on chromosome 17q11.2 (Wallace et al., 1990; Viskochil et al., 1990). NF1 is a familial disorder with a mendelian inheritance pattern, but approximately half of the NF1 cases are caused by newly appearing mutations (Messiaen et al., 2000).

Although NF1 is an autosomal dominant disorder with 100% penetrance, there is a great variance in clinical presentation with relatively minor contribution of the nature of the NF1 mutation to disease expression. The only genotype–phenotype correlation that has been well established is that patients with an NF1 microdeletion have a more severe phenotype with higher incidence of neurofibromas and MPNSTs, a lower mean IQ, and distinct facial features (De Raedt et al., 2003; Wu et al., 1997). Other explanations for the great inter- and intrafamilial variation in NF1 may be environmental factors or the impact of modifier genes, such as mismatch repair genes. Cell lines with mutations in these genes show an increased number of somatic mutations of the NF1 gene, which may possibly lead to increased symptom load in patients carrying these mutations (Pasmant et al., 2012; Wang et al., 2003).

The NF1 gene codes for neurofibromin, a cytoplasmatic, 2818 amino acids containing protein. Neurofibromin is widely expressed throughout different tissues including neurons and astrocytes of the central nervous system, where it is believed to be involved in cortical development and astrocyte growth (Gutmann, 2002; Gutmann et al., 1991; Andersen et al., 1993; Zhu et al., 2001).

Neurofibromin is critically involved in different cellular processes through influencing signalling pathways. Firstly, neurofibromin promotes the conversion of ATP to cyclic AMP, where an absence of NF1 gene activity decreases c-AMP levels (Tong et al., 2002). Through this pathway, neurofibromin has a positive relationship with learning, life span and stress resistance in *Drosophila* models (Tong et al., 2007; Guo et al., 2000) (Fig. 1).

Furthermore, neurofibromin acts as a negative regulator of RAS by functioning as a GTPase-activating protein (GAP), increasing the conversion of GTP-bound RAS to its GDP-bound form (Andersen et al., 1993; Basu et al., 1992). Loss of neurofibromin increases RAS activity and induces downstream activity of the MEK-ERK (MAPK, mitogen activated protein kinase) pathway as well as the PI3K-Akt-mTOR (mammalian target of rapamycin) pathway (Sandsmark et al., 2007; Banerjee et al., 2011a; Johannessen et al., 2005). Through these signalling pathways, neurofibromin functions as a negative regulator of cell growth and proliferation (Fig. 1).

## 2. NF1 and malignancies

NF1 is associated with an increased risk of malignancies, both nervous-system and non-nervous system related. Non-nervous system tumours include gastro-intestinal stromal tumours, duodenal carcinoids and pheochromocytomas as well as breast cancer and rhabdomyosarcomas. Nervous-system malignancies are both located in the central and peripheral nervous system. Malignant tumours of the peripheral nervous system include MPNSTs, most commonly arising from plexiform neurofibromas, and more rarely neuroblastomas (Brems et al., 2009). The lifetime risk of developing MPNSTs is 8–13% for NF1 patients and these tumours usually occur in adulthood (Evans et al., 2002).

The most common central-nervous system tumours in NF1 are low grade gliomas, with the optic pathway glioma being a hallmark lesion (Szudek et al., 2000). Higher grade gliomas are also more frequently found in NF1, but are almost only observed during adult life, while low grade gliomas are far more common in the paediatric population (Gutmann et al., 2002).

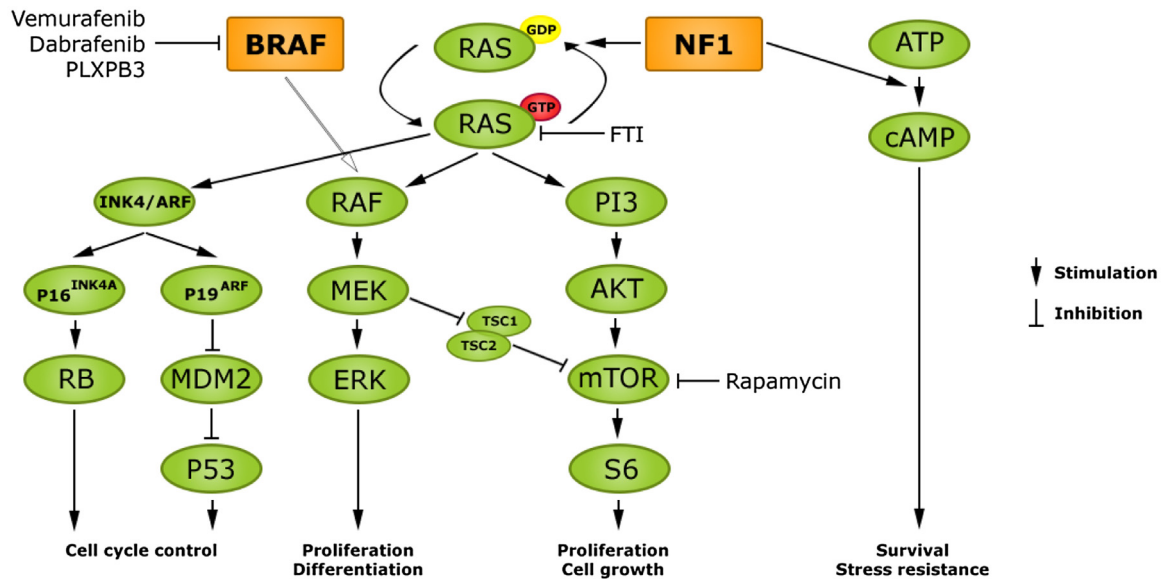
In most NF1-related malignancies, including astrocytomas, MPNSTs and neuroblastomas, biallelic inactivation of NF1 gene function is found in the affected cells (Upadhyaya et al., 2008; Origone et al., 2003; Gutmann et al., 2000). Somatic inactivation of the still functioning NF1 allele is believed to be required for tumour formation. This 'second hit' creates an absence of neurofibromin in affected cells, diminishing its normal functions, including those of controlling cell growth and proliferation. With this role of the NF1 gene as a tumour suppressor, it is not surprising that somatic mutations of the NF1 gene are also commonly found in different non NF1-associated tumours (Li et al., 1992).

In aggressive NF1-related tumours, such as MPNSTs and high grade gliomas additional mutations are found, such as mutations in TP53 and CDKN2A (Nielsen et al., 1999; Legius et al., 1994). These mutations may be important for the malignant transformation of relatively benign neurofibromas and astrocytomas, as is supported by mouse models where mice mutant for NF1 and TP53 develop high grade gliomas (Reilly et al., 2004; Zhu et al., 2005a). CDKN2A (p16) and p53 are important in regulating cell cycle control by inhibiting cell cycle progression. Their activation is partially regulated by Ras through the Ink4/ARF locus, which encodes p16<sup>INK4A</sup> and p19<sup>ARF</sup>. p16<sup>INK4A</sup> regulates the retinoblastoma (RB) protein, while p19<sup>ARF</sup> activates p53 by diminished inhibition of Mdm2 (Fig. 1) (Lin and Lowe, 2001).

## 3. NF1 and low grade gliomas

### 3.1. Phenotype

Low grade gliomas are the most commonly found tumours of the central nervous system in the paediatric population, both in children with and without NF1. While these low grade gliomas have an excellent prognosis after gross total resection, they can



**Fig. 1.** NF1 regulates cell proliferation, differentiation, survival and growth through the MAPK- and mTOR pathway and cAMP signalling. It functions as a GAP for RAS, thereby working as a negative regulator of RAS-phosphorylation. Loss of NF1 therefore activates RAS and downstream signalling pathways and inhibits cAMP signalling. RAS also controls the p16 and p53 cell cycle control pathways through Ink4/ARF. Diminished inhibition of MDM2 activates p53 while p16 regulates the retinoblastoma (RB) protein. BRAF alterations and mutations also activate the MAPK and mTOR-pathway; mTOR is activated in a TSC2-dependent way. The different inhibitors mentioned in the text and their targets are also shown in the figure. (FTI: Farnesyltransferase inhibitors).

be associated with significant morbidity and occasional mortality. For example, children with optic tract gliomas may have loss of visual acuity and show endocrine abnormalities such as diencephalic syndrome and precocious puberty. Surgery is not the first choice of treatment in NF1-associated optic gliomas, due to inaccessible tumour location and the relatively benign behaviour as well as the neurologic deterioration associated with resection of these tumours. Therefore other treatment forms such as chemotherapy or, in exceptional situations, radiotherapy are needed. The latter is however less desirable as it is associated with the development of Moya-Moya disease in NF1 patients.

Due to tumour location and therapeutic intervention, there is an elevated risk for cognitive and behavioural impairment in children with low grade gliomas (Ris et al., 2008; Armstrong et al., 2011). This side effect is rather undesirable in NF1 patients, who are already prone to cognitive impairment.

In general, low grade gliomas form a group of WHO grade I and grade II brain tumours which are classified based on malignancy grade and the presumed cell of origin. The most common subtypes are WHO grade I pilocytic astrocytomas (PAs) and grade II pilomyxoid and diffuse astrocytomas (Louis et al., 2007).

PAs are histologically characterized by GFAP-staining in the cell cytoplasm and the presence of Rosenthal fibers, but show great histological variability, sometimes making definite characterization difficult. Pilomyxoid astrocytomas exhibit histological similarities with PAs and are considered grade II variant of PAs in the WHO tumour classification of 2007. Histological classification of pilomyxoid astrocytomas can be difficult, particularly in tumours showing characteristics of both pilomyxoid and pilocytic astrocytomas (Johnson et al., 2010).

While PAs are commonly found in NF1-patients and usually follow an indolent course, pilomyxoid astrocytomas are less commonly observed in the context of NF1 (Louis et al., 2007).

Pilomyxoid and diffuse astrocytomas are classified as grade II tumours and show more aggressive behaviour than PA, but still form a group of relatively slow progressive tumours. Diffuse astrocytomas are characterized by diffuse infiltration and cytological atypia, but no anaplasia or mitotic activity.

PAs are most commonly found in children, predominantly in five till nine year olds. In contrast, diffuse astrocytomas are more common in the adult population with only 12% presenting before the age of 20 (Rodriguez et al., 2008). A summary of the different characteristics of the subtypes of paediatric low grade gliomas is given in Table 1.

A comparison will be made between NF1 and non NF1-related low grade gliomas at different anatomical locations. Because PAs are the most common subtype of low grade gliomas in the paediatric population, the focus will be on this histological subtype (see also Table 2).

### 3.2. Location

PAs generally occur at places where piloid cells are normally present in the central nervous system: along the ventricles, aqueduct and central canal as well as in the optic nerve, chiasm and optic tract. In the paediatric population, the cerebellum is the most prevalent location. However in the context of NF1, PAs are most often located in the optic pathway or brainstem. In the following section a comparison between clinical details of NF1 and non NF1-associated low grade gliomas is made, with a subdivision in supratentorial and infratentorial locations.

#### 3.2.1. Supratentorial low grade gliomas

Supratentorial low grade gliomas comprise a subgroup of tumours, including tumours of the cerebral lobes and the basal ganglia, which are only seldomly observed in NF1. However, optic pathway gliomas are far more common, both in NF1 and sporadic cases (Guillermo et al., 2003).

**3.2.1.1. Optic pathway glioma.** NF1-associated low grade gliomas are most frequently found in the optic pathway, with a prevalence of 15–25% for optic pathway gliomas (OPGs) among NF1 patients. If tissue is obtained, most of these tumours are classified as PA (Szudek et al., 2000; Hernaiz Driever et al., 2010; Guillermo et al., 2003; Listernick et al., 2007; Czyzyk et al., 2003). Presenting symptoms may include ophthalmological abnormalities, such as

**Table 1**  
Characteristics of different subtypes of low grade gliomas occurring in children.

	Pilocytic astrocytoma	Pilomyxoid astrocytoma	Diffuse astrocytoma
Histological features	Biphasic histology with piloid cells and more loosely arranged astrocytes.	Prominent myxoid matrix and angiocentric arrangement of monomorphous, piloid tumour cells.	Astrocytic cells with mild nuclear atypia.
Incidence (per 100.000 per year)	0,48	Unknown <sup>a</sup>	0,14
Association with NF1	Mainly OPG (50%)	Rare, case reports <sup>a</sup>	Rare
Age	5 to 19 years	Median age 10 months	Mean age 39.1
WHO grade	I	II	II
Mean overall survival (months)	233	60	71.1
Mutations	BRAF-fusions (mainly KIAA1549;BRAF fusion), BRAF, NF1, FGFR1, NTRK2, PTPN11	Unknown <sup>a</sup>	BRAF, TP53, IDH1
Location	Mainly cerebellum/Brainstem/Optic pathway	Mainly hypothalamic/Chiasmatic regions	Brain parenchyma

<sup>a</sup> Partially due to inconclusive diagnoses of pilocytic or pilomyxoid astrocytoma GFAP: glial fibrillary acid protein; OPG: optic pathway glioma (Louis et al., 2007; Sievert and Fisher, 2009; Komotar et al., 2004; Bourne and Schiff, 2010).

**Table 2**  
Outlining the differences between NF1 and non NF1-associated low grade gliomas in the paediatric population in different locations.

Supratentorial				
	Optic pathway NF1	Non NF1	Other NF1	Non NF1
Percentage of tumours	>50%	10%	15% (Hernaiz Driever et al., 2010; Guillamo et al., 2003)	5–10%
Most common genetic alterations	NF1 gene mutation	BRAF fusions; NTRK2 fusion	NF1 gene mutation	–
Mean age at presentation	4.6 years	4.8 years	–	–
Prognosis	5 y PFS of 71% (Stokland et al., 2010) 3 y PFS of 82% (Laithier et al., 2003) 5 y EFS of 19% (Hernaiz Driever et al., 2010) <sup>a</sup>	5 y OS of 94% (Stokland et al., 2010) <sup>b</sup> 3 y PFS of 42% (Laithier et al., 2003)	–	5 y OS of 92% (Stokland et al., 2010) <sup>b</sup> 10 y OS of 95% (Gnekow et al., 2012) <sup>b</sup> 10 y EFS of 63% (Gnekow et al., 2012) <sup>b</sup>
Infratentorial				
	Cerebellar NF1	Non NF1	Brainstem NF1	Non NF1
Percentage of tumours	4%	50%	17%	15%
Most common genetic alterations.	NF1 gene mutation	KIAA1549:BRAF fusion	NF1 gene mutation	BRAF fusions, BRAFv600E/, FGFR1 mutations
Mean age at presentation	–	7.9 years	–	6.5 years
Prognosis	–	5 y OS of 98% (Stokland et al., 2010) <sup>b</sup> 10 y OS of 98% (Gnekow et al., 2012) <sup>c</sup>	–	5 y OS of 85% (Stokland et al., 2010) <sup>b</sup> 5 y PFS of 64% (Stokland et al., 2010) <sup>b</sup>

– Indicates there is no or not sufficient data available to draw any conclusions (Grimm and Chamberlain, 2013; Hayostek et al., 1993).

<sup>a</sup> This number includes only hypothalamic and chiasmatic tumours.

<sup>b</sup> No discrimination between NF1-positive and NF1-negative patients.

<sup>c</sup> No discrimination between NF1-positive and NF1-negative patients;this percentage includes both cerebellar and brainstem tumours.

strabismus, visual field defects, decreased visual acuity, abnormal pupillary function, decreased colour function, optic nerve atrophy or proptosis as well as diencephalic syndrome and precocious puberty, especially in chiasmatic tumours. A significant percentage of patients seem to remain asymptomatic; this may be partially caused by incomplete reporting of visual impairment in younger children, due to a lack of adequate testing modalities (Listernick et al., 2007).

Compared to non-NF1 associated OPGs, NF1-related OPGs may have a slightly earlier age of presentation, with a median age of 4.6 versus 4.8 years in a group of 83 optic gliomas, but this difference is not significant over different studies.

There may be a slight female preponderance in NF1-associated OPG, but this is not consistent over different studies. OPGs not associated with NF1 show an equal sex distribution. Recently it

was shown that female patients with NF1-associated OPG are more prone to become symptomatic and three times more likely require treatment (Fisher et al., 2014; Diggs-Andrews et al., 2014). Multifocal distribution, optic nerve involvement and bilateral gliomas occur more often in NF1, while chiasmatic location, extra-optic growth and cystic morphology are more common in sporadic OPGs (Czyzyk et al., 2003; Listernick et al., 1995; Shamji and Benoit, 2007).

The classical Dodge staging system for OPGs classifies tumours based on anatomy with involvement of either the optic nerves, the optic chiasm and the hypothalamus with associated structures (Dodge et al., 1958). Based on MR image sequences, a modified Dodge classification has been developed which permits a more detailed description of tumour involvement at multiple anatomical locations in the optic pathway area. In NF1-positive tumours,

this method revealed a tendency towards an asymmetrical involvement at the optic chiasm, whereas NF1-negative tumours tend to localize more centrally at the chiasm (Taylor et al., 2008). The capacity of the modified Dodge classification to discriminate central and asymmetrical localization at the chiasm has great value in predicting visual outcome before and after OPG treatment. In line with this, postchiasmatic localization of NF1-positive OPGs was found to be correlated with worse visual outcome compared to other anatomical locations in the optic pathway area (Fisher et al., 2012). A recent multidisciplinary consensus proposed to (Taylor et al., 2008) revise the modified Dodge classification system for OPGs by addition of surgical and clinical factors, in order to assist standardized surgical assessment of tumours in the optic pathway area (Walker et al., 2013).

Progression rates of OPGs are usually slow, especially in the context of NF1. In a group of 83 OPGs, radiologic progression rates were higher in sporadic OPG (40%) even after treatment, compared to 28% in untreated NF-1 related OPG (Czyzyk et al., 2003). Spontaneous regression has been described as a typical feature of NF1-related OPG, but may occur in both NF1- and sporadic OPG (Liu et al., 2013).

In accordance with the slow progression rates, overall survival is generally good. In very young children (<1 year old), sporadic OPGs are associated with poorer overall survival, which is related to tumour location and the occurrence of diencephalic syndrome (Stokland et al., 2010; Laithier et al., 2003; Gnekow et al., 2012, 2004; Opocher et al., 2006). While survival rates are high, the most important concern in OPGs is loss of visual function. Vision loss occurs in children with NF1-associated OPG at any age, with a median age between 3 and 5 years. In younger children rates of vision loss may be underestimated due to difficulties in assessing vision loss in this population (Listernick et al., 2007; Fisher et al., 2012).

While the main reason to initiate treatment in OPG is loss of visual function, effects of treatment on visual function are variable as was shown in different non-randomized trials (Moreno et al., 2010). In a large cohort of 115 children with NF1-associated OPG, vision improved (32%), remained stable (40%) or worsened (28%) after chemotherapeutic treatment (Fisher et al., 2012).

Interestingly, a poor correlation between radiographic and visual outcome was described. Furthermore a correlation between tumour location and outcome after treatment was found, with tumours involving the optic tract or its radiations associated with worse visual outcome and increased mortality. Therefore a “wait and see” approach is suggested for prechiasmatic tumours exhibiting radiographic progression without apparent risk of visual loss, while a more aggressive treatment approach is advocated in (post)chiasmatic tumours, which pose a higher risk of visual loss (Sievert et al., 2013). Together these studies state the importance of regular radiographic, but maybe more important, ophthalmologic follow-up in NF1-associated OPGs (Opocher et al., 2006). Ophthalmologic screening should focus on visual acuity, by including specific quantitative measuring methods as visual endpoints (“Teller acuity cards” and “Snellen”, or “HOTV”), and the assessment of optic disc pallor (Fisher et al., 2013).

### 3.2.2. Infratentorial low grade gliomas

Infratentorial low grade gliomas, mainly classified as PA, include lesions of the cerebellum, brainstem and spinal cord. Spinal cord PAs are rare tumours, both in NF1 and non-NF1 patients, while brainstem low grade gliomas are more often seen. The cerebellum is the most common location for non-NF1 associated PAs but is a rare location for NF1-associated tumours.

**3.2.2.1. Cerebellum.** Tumours of the posterior fossa probably represent only approximately 4% of central nervous system tumours in NF1 (Rodriguez et al., 2008). In a cohort of 600 NF1 patients in

Spain followed for 39 years, only 4 developed grade I astrocytomas involving the posterior fossa, while only one of those had a primary origin in the cerebellum (Pascual-Castroviejo et al., 2010). Cerebellar lesions in NF1 are believed to have a less favourable natural course than optic pathway gliomas with aggressive resection being the first choice of treatment (Pollack and Mulvihill, 1996). While rare in the context of NF1, the cerebellum is the most common location for sporadic pilocytic astrocytomas (Louis et al., 2007).

**3.2.2.2. Brainstem.** In a cohort of 104 patients with NF1 and a central nervous system tumour, the brainstem was the second most common location of brain tumours, representing 17% of all and 49% of patients with an extra-optic tumour. Extra-optic tumour location was associated with a less favourable prognosis in this cohort (Guillermo et al., 2003). However in NF1, like optic pathway gliomas, brainstem lesions are most often asymptomatic and only show a low frequency of clinical progression with a more favourable prognosis than non NF1-associated brainstem gliomas (Pollack et al., 1996). Because of their relatively indolent behaviour and the high risk of invasive biopsy or resection, these procedures are seldom performed and a histologic diagnosis is therefore rarely made. A retrospective study from the Mayo-clinic on 48 resected low grade brainstem gliomas in children indicated that most of these tumours are astrocytomas, predominantly pilocytic astrocytomas, but the NF1 status of the children is not mentioned in this article (Ahmed et al., 2014).

### 3.2.3. Comparison of supratentorial and infratentorial lesions

PAs from different brain regions, both with and without an association with NF1 are histologically mostly similar. However, the age of presentation, progression free survival and overall survival depend on PA location, which is mostly due to resectability of the tumour (Stokland et al., 2010). Furthermore different gene expression profiles related to PA location have been found, such as supratentorial and infratentorial PAs (Belirgen et al., 2012).

Throughout these different gene expression profiles, the only gene consistently showing increased expression in supratentorial tumours compared to infratentorial tumours is LHX2. In the forebrain of zebrafish, this gene is involved in cellular proliferation through SIX3 (Sharif et al., 2011; Mascelli et al., 2013; Tchoghandjian et al., 2009; Ando et al., 2005). LHX2 is believed to be an important regulator of embryonic development. It functions as a suppressor of embryonic astroglialogenesis during the neurogenic period and is involved in maintaining optic identity in the optic vesicle (Subramanian et al., 2011; Roy et al., 2013). However, its role in human brain tumors remains elusive and LHX2 expression in supratentorial tumours seems to be unrelated to the NF-1 status of the patient (Sharma et al., 2007).

The observed difference in gene expression profiles between infratentorial and supratentorial tumours suggests a relation between tumourigenesis and tumour location. Recently, a whole genome sequencing study carried out by the international genome consortium pedbrain tumour project underlined this statement by revealing that different mutations found in PA may be brain region-specific, as will be further discussed below (Jones et al., 2013).

### 3.3. Tumourigenesis

Whereas NF1-associated PAs are histologically similar to sporadic PAs, the oncogenic molecular mechanisms underlying these tumours are different, which translates into differential localisation patterns and clinical behaviour. Over the past few years an increased insight into mechanisms involved in tumourigenesis in both sporadic and NF1-related PAs has helped in the understanding of these differences.

### 3.3.1. NF1-associated pilocytic astrocytomas

As in other NF1-related malignancies, loss of NF1 gene expression and neurofibromin expression has been shown in NF1-related PAs. This suggests a second hit mechanism, in which somatic inactivation of the still functioning NF1 allele is required for tumour formation (Gutmann et al., 2000, 2003; Kluwe et al., 2001). Different mechanisms, including frameshift mutation, loss of heterozygosity and methylation are known to be responsible for the somatic inactivation of the NF1 gene in human PAs (Gutmann et al., 2013).

Further evidence for this second hit mechanism came from mouse models of NF1. First, mice heterozygous for NF1 show increased astrocyte growth in the brain, dependent of neurofibromin. However, these mice do not develop astrocytomas (Gutmann et al., 1999). Second, transgenic mice with a NF1 conditional knockout specific to astrocytes do also show astrocytosis independent of the timing of the knockout, but do not exhibit astrocytoma formation (Bajenaru et al., 2002). Thus, loss of neurofibromin function in astrocytes is not sufficient for astrocytoma formation.

Third, an astrocyte-specific knockout of NF1 was performed in mice heterozygous for NF1. All of these mice developed lesions similar to optic gliomas in humans (Bajenaru et al., 2003, 2005).

These experiments do not only underline the importance of complete inactivation of NF1 in optic glioma formation, but also show the importance of a proper tumour environment for gliomagenesis.

This provides a model for tumourigenesis in NF1, but it does not explain the localisation of NF1-associated astrocytomas along the optic pathway, the cerebellum or in the brainstem. One possible explanation for this localisation pattern has been found in the mouse model of NF1 associated PAs, which is a brain region-specific effect of NF1 gene inactivation. This is shown by increased proliferation in cerebellar, brainstem and optic pathway astroglial cells but not cortical astroglial cells after NF1 inactivation, as well as the higher proliferation of neural stem cells in the brainstem but not in the cortex after NF1 loss (Yeh et al., 2009; Lee da et al., 2010).

This brain region-specific effect is further supported by the formation of optic pathway gliomas after NF1 inactivation in neural stem cells of the subventricular zone of the third ventricle during embryogenesis, but not of the lateral ventricles (Lee da et al., 2012).

The effects of NF1 inactivation are not only brain region- and cell-specific, but may also be subject to adequate timing, providing a possible explanation for the almost exclusive presentation of PAs in children. This is suggested by characteristics of progenitor cells in the OPGs in the previously described NF1 mouse model and the fact that no glioma formation is seen when NF1 knockout is performed in adult astrocytes (Bajenaru et al., 2005; Zhu et al., 2005b).

While these mice models have greatly increased the understanding of gliomagenesis and provided some answers to the brain region- and timing-specific occurrence of gliomas in NF1, it is still questionable which children with NF1 are prone to optic glioma formation. A molecular analysis of NF1 mutations in 80 patients with NF1 and an OPG found clustering of mutations at the 5' end of the NF1 gene in patients with OPG as a possible genotype-phenotype association (Sharif et al., 2011).

A recently emerging factor in tumour formation is the role of microRNAs. These are small non coding RNA-particles, that inhibit transcription through binding of the RNA-strand, and can act both as a proto-oncogene and as a tumour suppressor gene. They show alterations in paediatric PAs in general and are believed to be involved in the development of MPNSTs in NF1 (Esparza-Garrido et al., 2013; Sedani et al., 2012). Their role in NF1-associated PAs is not known yet, but these studies indicate they might be involved in tumour formation and susceptibility.

Another important factor in susceptibility to glioma formation may be the genetic background, as was shown in a murine model. In this model, mice mutated for NF1 and Tp53 only developed glioblastomas on a certain genetic background (B6), while mice with these mutations on a 129-background are highly resistant to tumour formation (Reilly et al., 2004, 2000). Further explanations for the susceptibility to glioma formation in about 20 percent of children remain to be found.

### 3.3.2. Comparison with sporadic PA

While NF1 loss is required for formation of PA, NF1 loss is not found in sporadic PA, suggesting another driving mechanism behind tumour formation (Kluwe et al., 2001; Wimmer et al., 2002). In contrast, the majority of non-NF1-associated PA show an activation of BRAF, caused by fusion of BRAF with KIAA1549, due to a duplication at 7q34 (Jones et al., 2008). This BRAF alteration is not found in glioblastoma or ependymoma, indicating that it is specific for PA.

Other genetic alterations in sporadic PAs include BRAF<sup>ins598T</sup> and BRAF<sup>V600E</sup> mutations, the latter being common in human melanomas, and fusion between SRGAP3 and RAF1 (Jones et al., 2009). Mutations in p53 are only sporadically found in paediatric PAs. One study reported a frequency of 35 percent, but this number has not been confirmed in further studies (Hayes et al., 1999).

The recently published whole genome sequencing study on 96 PAs identified BRAF fusions in 76 of 96 PAs. In correspondence with previous findings, the KIAA1549:BRAF fusion was the most frequently found alteration. Furthermore two new NTRK2-fusions were described and new mutations were identified within the kinase domain of FGFR 1 and in the phosphatase gene PTPN11. Interestingly all of these new mutations were found in non-cerebellar tumours, possibly indicating a link between mutation and the brain region of tumour formation. The results of this study are summarized in Fig. 2 (Jones et al., 2013).

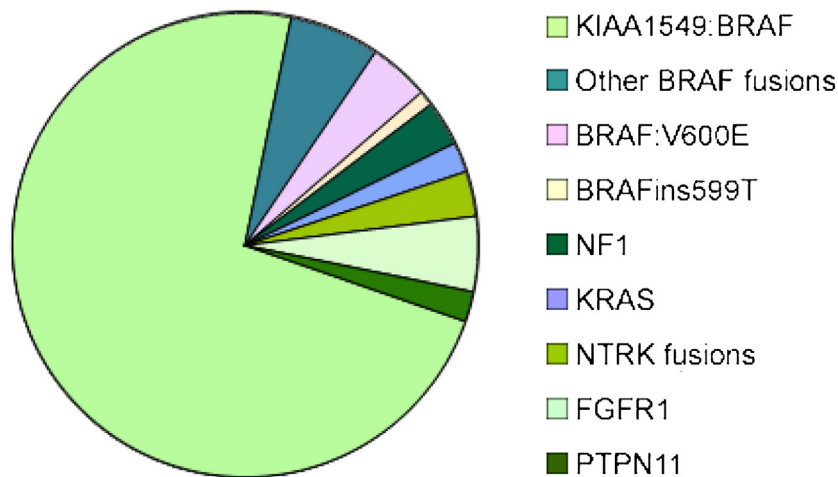
In vitro, cerebellar neural stem cells transduced with the KIAA1549:BRAF fusion show increased cell growth. After injection of these cerebellar neural stem cells in mouse cerebella, these mice develop glioma-like lesions after 6 months. Because this effect is not seen in cortical neural stem cells nor in astrocytes, this is in concordance with a brain region- and cell-specific response to the KIAA1549:BRAF fusion, comparable with that seen in NF1 (Kaul et al., 2012, 2013).

## 3.4. Signalling pathways

While the mechanism behind increased Ras/Raf signalling is different in NF1-associated and sporadic PAs, there are similar consequences of the activation of this pathway, possibly explaining the common histological properties of these tumours (Fig. 1). Because both sporadic and NF1-associated PAs show activation of the mTOR-pathway and MAPK pathway and these pathways provide possible targets to molecular therapy, we will focus on these pathways (Jones et al., 2013; Kaul et al., 2012; Forsheew et al., 2009).

### 3.4.1. MAPK-pathway

MAPK signalling is activated in most, if not all PAs with different mechanisms responsible for its activation (Jones et al., 2013, 2008; Forsheew et al., 2009). In NF1 related PAs, the MAPK pathway is activated through increased RAS-signalling after unrestrained phosphorylation of RAS through absence of neurofibromin (Lau et al., 2000). Although the downstream effects of MAPK activation in NF1 associated PA are not completely understood, inhibition of this pathway may be a potential target for treatment. In vitro and mouse models of NF1-associated MPNSTs and neurofibromas show efficacy of MAPK inhibition (Jessen et al., 2013). Furthermore, MAPK inhibition is effective in rescuing brain abnormalities in mice with



**Fig. 2.** Genetic alterations in paediatric astrocytomas as was found in the whole genome sequencing study. An underestimation of the number of NF1 associated tumours may be caused by limited tissue obtained from this group of patients (Jones et al., 2013).

biallelic inactivation of NF1 neural stem cells, with normalization of MAPK levels (Wang et al., 2012).

In sporadic PA different genetic alterations are responsible for MAPK activation, including BRAF fusions and FGFR1 mutations (Jones et al., 2013, 2009). In vitro experiments show diminished proliferation after MAPK inhibition in cell lines harbouring these gene alterations (Kaul et al., 2012; Zhang et al., 2013). The general activation of MAPK has led to clinical trials targeting this pathway in paediatric PA.

#### 3.4.2. mTOR-pathway

The mTOR pathway is a critical pathway in cell survival, cell growth and proliferation. Analogous to the MAPK-pathway, it has shown to be a potent driver of tumourigenesis (Zoncu et al., 2011).

In humans, the mTOR-pathway is hyperactivated in NF1-associated PAs, as is shown by increased levels of phosphorylated S6 (Lau et al., 2000; Dasgupta et al., 2005a). This mTOR hyperactivation is also seen in the mouse model of NF1 OPG, with higher levels of S6 in OPG tissue of genetically engineered NF1<sup>+/-</sup> mice, compared to tissue of the optic chiasm of control mice (Dasgupta et al., 2005a).

The exact mechanism of mTOR-activation in NF1 associated PAs remains to be revealed, but some evidence comes from the mouse model of NF1 OPG. In this mouse model, inhibition of mTOR with rapamycin is effective in decreasing tumour cell proliferation in a dose dependent manner (Hegedus et al., 2008). Rapamycin crosses the blood brain barrier and shows an exponential increase of brain levels as a response to increase of dosage, possibly indicating a threshold function of blood- brain barrier proteins. Interestingly, the growth inhibiting effects of rapamycin seem not to be fully reflected by S6- or Akt-phosphorylation, since a lower concentration of rapamycin was required for inhibition of S6- or Akt-phosphorylation than for maximal growth suppression (Banerjee et al., 2011b).

Further attempts on elucidating the mechanism by which mTOR regulates astrocyte proliferation were made in-vitro studies. It was shown that the mechanism by which neurofibromin regulates mTOR and controls cell growth is Akt-dependent but TSC-independent (Banerjee et al., 2011a; Johannessen et al., 2005).

Non-NF1 associated astrocytomas carrying the KIAA1549:BRAF fusion also show increased mTOR activation. In cerebellar neural stem cell lines carrying the fusion, this mTOR-pathway activation was shown to be through MEK-dependent TSC2 inactivation (Fig. 1) (Kaul et al., 2012).

While different mechanisms are responsible for mTOR-activation in NF1 and non NF1-associated PAs the common activation of this pathway and preclinical results, have led to clinical trials with different mTOR-inhibitors in paediatric PA, of which results are pending.

#### 3.5. Tumour micro-environment

Inactivation of the NF1 gene in astroglial cells is only sufficient for gliomagenesis in a context of heterozygous NF1<sup>+/-</sup> mice and shows brain region- and cell-specific effects (Bajenaru et al., 2002, 2003). This creates the idea in which inactivation of the NF1 gene is only sufficient for gliomagenesis in a proper tumour micro-environment, or in which NF1 gene loss can only occur in a specific environment.

In correspondence with these theories, there is a relatively high proportion of stromal cells in the PAs in NF1 (Gutmann et al., 2013). Different studies have focused on the role of NF1<sup>+/-</sup> stromal cells in promoting tumour formation, for example by examining cAMP (Warrington et al., 2007)-signalling in stromal cells. The chemokine CXCL12 functions as a suppressor of cAMP levels after binding its receptor CXCR4 and is highly expressed in the optic pathway of young children.

Similar to the human situation, CXCL12-expression is high in the optic pathway of young mice, and cAMP levels are high in the cortex but not in the optic pathway. In vitro, increased CXCL12-expression suppresses c-AMP signalling and causes increased survival of NF1-gene knockout astrocytes (Warrington et al., 2007). Decreased stromal cAMP expression promotes gliomagenesis in mice heterozygous for NF1. Gliomas, similar to the mouse OPGs, form in the cortex of these mice after inhibition of cAMP-expression. Glioma growth was inhibited by reversing this effect through re-increasing cAMP levels (Warrington et al., 2010).

Together these findings underline the role of paracrine signalling by the tumour microenvironment and in particular cAMP in NF1 OPGs. Furthermore they contribute to the explanation of the spatial pattern of gliomagenesis in NF1 (Warrington et al., 2007, 2010).

Other stromal influences may come from increased c-Jun-Nh<sub>2</sub>-kinase (JNK) signaling, hyaluronidase production and the expression of chemokine receptor CX3CR1. Cultured microglia from heterozygous NF1<sup>+/-</sup> mice show increased JNK signalling and inhibition of this signalling is associated with decreased proliferation both in vitro and in vivo (Daginakatte et al., 2008). Hyaluronidase is a paracrine

factor produced by NF1 heterozygous microglia and increases astrocyte proliferation through MAPK-signalling. Its inhibition is associated with decreased growth of NF1 knockout astrocytes (Daginakatte and Gutmann, 2007).

The chemokine receptor CX3CR1 is involved in signalling in the central nervous system and is also highly expressed in NF1 OPG microglia. Reduced expression of this receptor is associated with delayed optic glioma formation in mice heterozygous for NF1 (Pong et al., 2013).

Altogether, there seems to be an important role for the tumour microenvironment in NF1 glioma growth. However, the mechanism by which the microenvironment regulates tumour growth has to be further clarified. Better insights into this mechanisms may give way to the development of intelligent therapy targeting both tumour and microenvironment.

It remains to be revealed what the role of tumour microenvironment is in tumour formation in non NF1-associated PAs. The brain region-specific effects of the KIAA1549: BRAF fusion in mouse models suggest that tumour-environmental influences may also play a role in these tumours (Kaul et al., 2013).

### 3.6. Angiogenesis

Angiogenesis is critically involved in tumour growth in high grade gliomas, which has led to preclinical and clinical trials of anti-angiogenic therapy (Dunn et al., 2012). PAs, like high grade gliomas, are highly vascular, suggesting that targeting vascularisation or angiogenesis may also be a treatment option in PA.

A comparison of vasculature of paediatric PA with adult glioblastoma revealed that there are less vessels in PA, but these vessels are wider than those in glioblastoma. The lower number of vessels correlated with higher VEGF-A expression, possibly indicating VEGF as a target for therapy. Vessel maturity, described as the balance between ANGPT1 and ANGPT2, was higher in the whole group of PA. Interestingly the cerebellar PA showed less vessel maturity, even comparable with that of glioblastoma, while showing the widest vessels (Sie et al., 2010).

It has been shown that increased microvessel density is associated with shorter survival in gliomas (Leon et al., 1996). For low grade gliomas, higher microvessel density was associated with lower progression free survival in a study in 41 children with incompletely resected tumours of the optic pathway and hypothalamus.

Results were similar between NF1-associated and sporadic OPGs, suggesting that this vascularisation pattern is preserved in NF1-associated PAs. However these results may be biased by the selection of a group of NF1 associated OPGs that were eligible for surgery (Bartels et al., 2006). The highly vascular pattern and endothelial hyperplasia of OPGs in the mouse model of NF1 is in line with a comparable vascular pattern in NF1 associated gliomas (Bajenaru et al., 2005; Kim et al., 2010).

The mechanism by which increased vascularity in NF1 related tumours is attained is not completely clear but may be associated with NF1 gene loss or downstream activation of different pathways. NF1 is associated with vascular pathology, possibly involving all blood vessels (Rosser et al., 2005). Although the exact mechanism behind this vasculopathy remains unclear, neurofibromin is widely expressed in blood vessels, suggesting a possible role for NF1 signalling in NF1 vasculopathy (Rodrigues et al., 2013). NF1 signalling might have a role in pericyte and endothelial proliferation and recent studies in Schwann cell lines suggest that activation of mTOR and VEGF after NF1 loss may be involved in vascularisation (Ozerdem, 2004; Kawachi et al., 2013).

Only limited information on clinical use of angiogenic inhibitors in paediatric low grade gliomas is available, but studies in high grade gliomas in both children and adults have shown varying

results. (Reviewed in (Dasgupta and Haas-Kogan, 2013)) Effects of anti-angiogenic treatment in PAs in both NF1 and non-NF1 associated tumours remain to be determined.

## 4. Treatment

Survival rates of low grade gliomas, especially PAs, are excellent after treatment and exceed 90 percent after five and ten years in different studies (Louis et al., 2007; Stokland et al., 2010; Gnekow et al., 2012). Current treatment options for low grade gliomas in children include surgery, radiotherapy and chemotherapy or a combination of these modalities, as well as BRAF-inhibitors in specific tumours (Walker et al., 2013).

If the tumour is accessible for resection without considerable adverse damage, this is usually the mainstay of treatment as complete resection is associated with better rates of overall and progression free survival. Ten year overall survival rates of 99% vs. 94% and progressive free survival rates of 85% vs. 48% for total vs. subtotal resection were found in one large study, with comparable numbers in a second. (five year overall and progressive free survival of 99% vs. 90% and 94% vs. 49% respectively) (Stokland et al., 2010; Gnekow et al., 2012).

As for optic pathway tumours a multidisciplinary consensus stated that resection is usually not the first choice of treatment, because of the generally less aggressive behaviour, especially in the context of NF1, as well as the location hampering total resection. A multidisciplinary approach should be taken to decide timing and form of treatment, taking into account visual function and tumour progression. Both before treatment is initiated and after treatment is started, regular radiographic and ophthalmologic follow up is warranted (Hernaiz Driever et al., 2010; Fisher et al., 2012; Walker et al., 2013).

Chemotherapy is now considered as first choice adjuvant therapy in low grade gliomas, with different regimens, including a combination of carboplatin and vincristine being effective in controlling progressive disease, independent of NF1-status (Packer et al., 1997).

Furthermore this treatment regimen has shown to reach progression free survival rates of 73 percent as a primary treatment in NF1 patients (Hernaiz Driever et al., 2010). As mentioned, a major concern in low grade gliomas in NF1 located along the optic pathway is visual outcome. Effects of treatment on visual outcome are variable over different studies (Moreno et al., 2010). A study analysing visual outcome in NF1 patients after chemotherapeutic treatment showed stabilisation or improvement of visual acuity after treatment with chemotherapy in most cases, while a decline of visual acuity is still seen in 28 percent of children after treatment. A location along the optic tract or optic radiation is associated with worse visual outcome (Fisher et al., 2012). In a more recent study stability was also the most common outcome after treatment for OPGs in general, where younger age and chiasmatic/hypothalamic tumours were associated with worse visual outcome (Dodgshun et al., 2015). Furthermore, for reasons not yet known, female gender seems to be associated with a higher risk of requiring treatment (Fisher et al., 2014; Diggs-Andrews et al., 2014).

A trial comparing carboplatin and vincristine with a combination of thioguanine, procarbazine, lomustine, and vincristine in 274 children showed no significant difference between these treatment regimens, suggesting this may be an alternative depending on toxicity (Ater et al., 2012).

Other chemotherapeutics studied in low grade gliomas include temozolomide, vinblastine and etoposide, where a combination of cisplatin and etoposide may be effective instabilising disease (Massimino et al., 2002; Bouffet et al., 2012; Gururangan et al., 2007). However, unpublished results of the SIOP LGG 2004 study,



an international cohort study comparing standard therapy (carboplatin and vincristine) with carboplatin/vincristine and etoposide induction therapy show no advantage of the latter.

Radiotherapy is, because of its side-effects, not considered a first line treatment in pediatric low grade gliomas, especially not in younger children. It can however be an effective treatment form for low grade gliomas, both in patients with and without NF1 (Hernaiz Driever et al., 2010; Stokland et al., 2010; Merchant et al., 2009). In a subgroup analysis of the HIT LGG 1996 cohort both stereotactic brachytherapy and external fractionated radiotherapy were shown to be effective in controlling tumour progression in older children. Long-term functional outcome was not reported in this study, whereas long-term side effects may be more common after radiotherapy, especially in younger children (Gnekow et al., 2012; Muller et al., 2013).

In NF1 patients, radiotherapy has been associated with the occurrence of secondary brain tumours and vasculopathy (Merchant et al., 2009; Grill et al., 1999; Sharif et al., 2006). Proton beam therapy may provide an alternative to conventional radiotherapy, with radiation better targeted to the tumour site. One study performing proton therapy in 27 children with low grade gliomas showed promising results, with a high efficacy particularly in centrally localised tumors. Short term side effects were limited in small series, but included the development of Moyamoya disease in a patient with NF1. Further research on long-term side effects and efficacy are now on their way (Hug et al., 2002; Hauswald et al., 2012).

In summary, results of current treatment options in terms of overall survival and progression free survival are generally good, especially if total resection can be reached. However, particularly in children younger than one and in supratentorial midline tumours, higher rates of progression free survival are needed (Gnekow et al., 2012). Precision medicine, targeting the above mentioned pathways may provide a valuable alternative to the current treatment options (Terashima et al., 2013).

The presence of BRAF alterations in a major proportion of non NF1-associated PAs has led to an experiment in which vemurafenib, a potent inhibitor of BRAF<sup>V600E</sup> in melanoma cells, was tried on cell lines carrying a stable BRAF:KIAA1549 fusion. Paradoxal MAPK activation and mTOR activation in these cell lines suggest that first line anti-BRAF treatment is not effective. However, secondary BRAF-inhibitors, such as PLX PB-3 are more effective in these cell lines in inhibiting mTOR and cellular proliferation (Sievert et al., 2013). A first phase II clinical trial with sorafenib, an inhibitor targeting BRAF, VEGFR, PDGFR and c-kit was terminated because of an unexpected acceleration of tumour growth, which was not dependent on NF1 status (Karajannis et al., 2014).

While BRAF inhibition may only be effective in sporadic PAs, RAS activation is a feature of both NF1-related and some sporadic PAs, indicating a possible role for RAS-inhibition in PA (Sharma et al., 2005). Farnesyltransferase inhibitors, which inhibit RAS by interacting with the insertion of RAS in the plasma membrane, have however not shown to be effective in the treatment of NF1-associated plexiform neurofibromas. The authors suggest a K-RAS specific regulation by NF1 as a possible explanation for this ineffectiveness (Widemann et al., 2006; Dasgupta et al., 2005b).

Further downstream, promising targets for therapeutic intervention include the MAPK-pathway and the mTOR-pathway, with clinical trials targeting these pathways being underway. In Fig. 1, the above mentioned agents and their point of action are shown. In addition, new therapies may target the tumour micro-environment, including activation of cAMP-signalling or inhibition of angiogenesis.

As PAs are highly vascular tumours, anti-angiogenic agents are interesting candidates in novel treatment approaches and one of the mostly evaluated drugs is the monoclonal antibody beva-

cizumab, which targets all the isoforms of the vascular endothelial growth factor A (VEGF-A). In children with recurrent low-grade gliomas treated with bevacizumab in conjunction with the topoisomerase I inhibitor irinotecan, 6-month and 2-year PFS-rates were 85% and 48% respectively (Gururangan et al., 2014). A retrospective study with 16 children suffering from refractory or progressive low-grade gliomas, showed that a similar treatment approach lead to clinical improvement (44%) or stable disease (50%) (Kalra et al., 2015). In general, in pediatric low-grade glioma patients with NF1-associated and NF1-unassociated tumours, the mean therapeutic response to treatment with bevacizumab alone, or in conjugation with irinotecan, shows high variation across studies and the mean effect of bevacizumab on 2-year progression-free survival was not better than conventional treatment strategies (Kilday et al., 2014).

## 5. Conclusions

Neurofibromatosis type 1 is a tumour predisposition syndrome with a particular association with low grade gliomas in the paediatric population. These low grade gliomas, typically pilocytic astrocytomas, have a better prognosis and show a different localisation pattern than their sporadic counterparts, with a preferential location in the optic pathway. Although many is known about these low grade gliomas, a question unanswered is which children with NF1 are prone to low grade glioma formation and which are not.

Over the past years the knowledge of mechanisms behind the differences between NF1-associated and sporadic LGG, as well as those behind tumorigenesis, have greatly increased, particularly through different murine models. Different signalling pathways, including the MAPK- and mTOR-pathway, now have a well established role in PA. Other important players in gliomagenesis in NF1 are found in the tumour microenvironment and include angiogenesis and the production of different growth factors by stroma cells.

Although outcome of treatment in terms of overall survival and progression free survival is generally good, there is still room for improvement, particularly in saving vision in optic pathway gliomas. Much has been achieved improving survival using surgery, radiotherapy and different regimens chemotherapy, but toxicity and side effects of these treatments urge the search for alternative treatments, with precision medicine coming up a promising alternative.

## Conflict of interest

The authors declare no conflict of interest.

## Funding

Funding did not play a role in the study design, in the collection, analysis and interpretation of data, the writing of the manuscript and in the decision to submit the manuscript for publication.

## References

- Ahmed, K.A., Laack, N.N., Eckel, L.J., Orme, N.M., Wetjen, N.M., 2014. *Histologically proven, low-grade brainstem gliomas in children: 30-Year experience with long-term follow-up at mayo clinic*. *Am. J. Clin. Oncol.* 37, 51–56.
- Andersen, L.B., Ballester, R., Marchuk, D.A., Chang, E., Gutmann, D.H., Saulino, A.M., et al., 1993. *A conserved alternative splice in the von Recklinghausen neurofibromatosis (NF1) gene produces two neurofibromin isoforms, both of which have GTPase-activating protein activity*. *Mol. Cell. Biol.* 13, 487–495.
- Ando, H., Kobayashi, M., Tsubokawa, T., Uyemura, K., Furuta, T., Okamoto, H., 2005. *Lhx2 mediates the activity of Six3 in zebrafish forebrain growth*. *Dev. Biol.* 287, 456–468.
- Armstrong, G.T., Conklin, H.M., Huang, S., Srivastava, D., Sanford, R., Ellison, D.W., et al., 2011. *Survival and long-term health and cognitive outcomes after low-grade glioma*. *Neuro Oncol.* 13, 223–234.
- Ater, J.L., Zhou, T., Holmes, E., Mazewski, C.M., Booth, T.N., Freyer, D.R., et al., 2012. *Randomized study of two chemotherapy regimens for treatment of low-grade*

- glioma in young children: a report from the Children's Oncology Group. *J. Clin. Oncol.* 30, 2641–2647.
- Bajenaru, M.L., Zhu, Y., Hedrick, N.M., Donahoe, J., Parada, L.F., Gutmann, D.H., 2002. Astrocyte-specific inactivation of the neurofibromatosis 1 gene (NF1) is insufficient for astrocytoma formation. *Mol. Cell. Biol.* 22, 5100–5113.
- Bajenaru, M.L., Hernandez, M.R., Perry, A., Zhu, Y., Parada, L.F., Garbow, J.R., et al., 2003. Optic nerve glioma in mice requires astrocyte NF1 gene inactivation and NF1 brain heterozygosity. *Cancer Res.* 63, 8573–8577.
- Bajenaru, M.L., Garbow, J.R., Perry, A., Hernandez, M.R., Gutmann, D.H., 2005. Natural history of neurofibromatosis 1-associated optic nerve glioma in mice. *Ann. Neurol.* 57, 119–127.
- Banerjee, S., Crouse, N.R., Emmett, R.J., Gianino, S.M., Gutmann, D.H., 2011a. Neurofibromatosis-1 regulates mTOR-mediated astrocyte growth and glioma formation in a TSC/Rheb-independent manner. *Proc. Natl. Acad. Sci. U. S. A.* 108, 15996–16001.
- Banerjee, S., Gianino, S.M., Gao, F., Christians, U., Gutmann, D.H., 2011b. Interpreting mammalian target of rapamycin and cell growth inhibition in a genetically engineered mouse model of NF1-deficient astrocytes. *Mol. Cancer Ther.* 10, 279–291.
- Bartels, U., Hawkins, C., Jing, M., Ho, M., Dirks, P., Rutka, J., et al., 2006. Vascularity and angiogenesis as predictors of growth in optic pathway/hypothalamic gliomas. *J. Neurosurg.* 104, 314–320.
- Basu, T.N., Gutmann, D.H., Fletcher, J.A., Glover, T.W., Collins, F.S., Downward, J., 1992. Aberrant regulation of ras proteins in malignant tumour cells from type 1 neurofibromatosis patients. *Nature* 356, 713–715.
- Belirgen, M., Berrak, S.G., Ozdag, H., Bozkurt, S.U., Eksioğlu-Demiralp, E., Ozek, M.M., 2012. Biologic tumor behavior in pilocytic astrocytomas. *Childs Nerv. Syst.* 28, 375–389.
- Bouffet, E., Jakacki, R., Goldman, S., Hargrave, D., Hawkins, C., Shroff, M., et al., 2012. Phase II study of weekly vinblastine in recurrent or refractory pediatric low-grade glioma. *J. Clin. Oncol.* 30, 1358–1363.
- Bourne, T.D., Schiff, D., 2010. Update on molecular findings, management and outcome in low-grade gliomas. *Nat. Rev. Neurol.* 6, 695–701.
- Brems, H., Beert, E., de Ravel, T., Legius, E., 2009. Mechanisms in the pathogenesis of malignant tumours in neurofibromatosis type 1. *Lancet Oncol.* 10, 508–515.
- Czyzyk, E., Józwiak, S., Roszkowski, M., Schwartz, R.A., 2003. Optic pathway gliomas in children with and without neurofibromatosis 1. *J. Child Neurol.* 18, 471–478.
- Daginakatte, G.C., Gutmann, D.H., 2007. Neurofibromatosis-1 (NF1) heterozygous brain microglia elaborate paracrine factors that promote NF1-deficient astrocyte and glioma growth. *Hum. Mol. Genet.* 16, 1098–1112.
- Daginakatte, G.C., Gianino, S.M., Zhao, N.W., Parsadanian, A.S., Gutmann, D.H., 2008. Increased c-Jun-NH2-kinase signaling in neurofibromatosis-1 heterozygous microglia drives microglia activation and promotes optic glioma proliferation. *Cancer Res.* 68, 10358–10366.
- Dasgupta, T., Haas-Kogan, D.A., 2013. The combination of novel targeted molecular agents and radiation in the treatment of pediatric gliomas. *Front. Oncol.* 3, 110.
- Dasgupta, B., Yi, Y., Chen, D.Y., Weber, J.D., Gutmann, D.H., 2005a. Proteomic analysis reveals hyperactivation of the mammalian target of rapamycin pathway in neurofibromatosis 1-associated human and mouse brain tumors. *Cancer Res.* 65, 2755–2760.
- Dasgupta, B., Li, W., Perry, A., Gutmann, D.H., 2005b. Glioma formation in neurofibromatosis 1 reflects preferential activation of K-RAS in astrocytes. *Cancer Res.* 65, 236–245.
- De Raedt, T., Brems, H., Wolkstein, P., Vidaud, D., Pilotti, S., Perrone, F., et al., 2003. Elevated risk for MPNST in NF1 microdeletion patients. *Am. J. Hum. Genet.* 72, 1288–1292.
- Diggs-Andrews, K.A., Brown, J.A., Gianino, S.M., Rubin, J.B., Wozniak, D.F., Gutmann, D.H., 2014. Sex Is a major determinant of neuronal dysfunction in neurofibromatosis type 1. *Ann. Neurol.* 75, 309–316.
- Dodge Jr., H.W., Love, J.G., Craig, W.M., Dockerty, M.B., Kearns, T.P., Holman, C.B., et al., 1958. Gliomas of the optic nerves. *AMA Arch. Neurol. Psychiatry* 79, 607–621.
- Dodgshun, A.J., Elder, J.E., Hansford, J.R., Sullivan, M.J., 2015. Long-term visual outcome after chemotherapy for optic pathway glioma in children: site and age are strongly predictive. *Cancer* 121, 4190–4196.
- Dunn, G.P., Rinne, M.L., Wykosky, J., Genovesi, G., Quayle, S.N., Dunn, I.F., et al., 2012. Emerging insights into the molecular and cellular basis of glioblastoma. *Genes Dev.* 26, 756–784.
- Espaza-Garrido, R.R., Velazquez-Flores, M.A., Diegoperez-Ramirez, J., Lopez-Aguilar, E., Siordia Reyes, G., Hernandez-Ortiz, M., et al., 2013. A proteomic approach of pediatric astrocytomas: MiRNAs and network insight. *J. Proteomics.*
- Evans, D.G., Baser, M.E., McLaughran, J., Sharif, S., Howard, E., Moran, A., 2002. Malignant peripheral nerve sheath tumours in neurofibromatosis 1. *J. Med. Genet.* 39, 311–314.
- Fisher, M.J., Loguidice, M., Gutmann, D.H., Listerick, R., Ferner, R.E., Ullrich, N.J., et al., 2012. Visual outcomes in children with neurofibromatosis type 1-associated optic pathway glioma following chemotherapy: a multicenter retrospective analysis. *Neuro Oncol.* 14, 790–797.
- Fisher, M.J., Avery, R.A., Allen, J.C., Arden-Holmes, S.L., Bilaniuk, L.T., Ferner, R.E., et al., 2013. Functional outcome measures for NF1-associated optic pathway glioma clinical trials. *Neurology* 81, S15–24.
- Fisher, M.J., Loguidice, M., Gutmann, D.H., Listerick, R., Ferner, R.E., Ullrich, N.J., et al., 2014. Gender as a disease modifier in neurofibromatosis type 1 optic pathway glioma. *Ann. Neurol.* 75, 799–800.
- Forshew, T., Tatevossian, R.G., Lawson, A.R., Ma, J., Neale, G., Ogunkolade, B.W., et al., 2009. Activation of the ERK/MAPK pathway: a signature genetic defect in posterior fossa pilocytic astrocytomas. *J. Pathol.* 218, 172–181.
- Gnekow, A.K., Kortmann, R.D., Pietsch, T., Emser, A., 2004. Low grade chiasmatic-hypothalamic glioma-carboplatin and vincristin chemotherapy effectively defers radiotherapy within a comprehensive treatment strategy—report from the multicenter treatment study for children and adolescents with a low grade glioma – HIT-LGG 1996 – of the Society of Pediatric Oncology and Hematology (GPOH). *Klin. Padiatr.* 216, 331–342.
- Gnekow, A.K., Falkenstein, F., von Hornstein, S., Zwiener, I., Berkefeld, S., Bison, B., et al., 2012. Long-term follow-up of the multicenter, multidisciplinary treatment study HIT-LGG-1996 for low-grade glioma in children and adolescents of the German Speaking Society of Pediatric Oncology and Hematology. *Neuro Oncol.* 14, 1265–1284.
- Grill, J., Couanet, D., Cappelli, C., Habrand, J.L., Rodriguez, D., Sainte-Rose, C., et al., 1999. Radiation-induced cerebral vasculopathy in children with neurofibromatosis and optic pathway glioma. *Ann. Neurol.* 45, 393–396.
- Grimm, S.A., Chamberlain, M.C., 2013. Brainstem glioma: a review. *Curr. Neurol. Neurosci. Rep.* 13 (346), 013-0346-3.
- Guillamo, J.S., Creange, A., Kalifa, C., Grill, J., Rodriguez, D., Doz, F., et al., 2003. Prognostic factors of CNS tumours in neurofibromatosis 1 (NF1): a retrospective study of 104 patients. *Brain* 126, 152–160.
- Guo, H.F., Tong, J., Hannan, F., Luo, L., Zhong, Y., 2000. A neurofibromatosis-1-regulated pathway is required for learning in *Drosophila*. *Nature* 403, 895–898.
- Gururangan, S., Fisher, M.J., Allen, J.C., Herndon, J.E., 2nd Quinn, J.A., Reardon, D.A., et al., 2007. Temozolomide in children with progressive low-grade glioma. *Neuro Oncol.* 9, 161–168.
- Gururangan, S., Fangusaro, J., Poussaint, T.Y., McLendon, R.E., Onar-Thomas, A., Wu, S., et al., 2014. Efficacy of bevacizumab plus irinotecan in children with recurrent low-grade gliomas—a pediatric brain tumor consortium study. *Neuro Oncol.* 16, 310–317.
- Gutmann, D.H., Wood, D.L., Collins, F.S., 1991. Identification of the neurofibromatosis type 1 gene product. *Proc. Natl. Acad. Sci.* 88, 9658–9662.
- Gutmann, D.H., Loehr, A., Zhang, Y., Kim, J., Henkemeyer, M., Cashen, A., 1999. Haploinsufficiency for the neurofibromatosis 1 (NF1) tumor suppressor results in increased astrocyte proliferation. *Oncogene* 18, 4450–4459.
- Gutmann, D.H., Donahoe, J., Brown, T., James, C.D., Perry, A., 2000. Loss of neurofibromatosis 1 (NF1) gene expression in NF1-associated pilocytic astrocytomas. *Neuropathol. Appl. Neurobiol.* 26, 361–367.
- Gutmann, D.H., Rasmussen, S.A., Wolkstein, P., MacCollin, M.M., Guha, A., Inskip, P.D., et al., 2002. Gliomas presenting after age 10 in individuals with neurofibromatosis type 1 (NF1). *Neurology* 59, 759–761.
- Gutmann, D.H., James, C.D., Poyhonen, M., Louis, D.N., Ferner, R., Guha, A., et al., 2003. Molecular analysis of astrocytomas presenting after age 10 in individuals with NF1. *Neurology* 61, 1397–1400.
- Gutmann, D.H., McLellan, M.D., Hussain, I., Wallis, J.W., Fulton, L.L., Fulton, R.S., et al., 2013. Somatic neurofibromatosis type 1 (NF1) inactivation characterizes NF1-associated pilocytic astrocytoma. *Genome Res.* 23, 431–439.
- Gutmann, D.H., 2002. Review article: neurofibromin in the brain. *J. Child Neurol.* 17, 592–601.
- Hauswald, H., Rieken, S., Ecker, S., Kessel, K.A., Herfarth, K., Debus, J., et al., 2012. First experiences in treatment of low-grade glioma grade I and II with proton therapy. *Radiat. Oncol.* 7 (189), 717X-7-189.
- Hayes, V.M., Dirven, C.M., Dam, A., Verlind, E., Molenaar, W.M., Mooij, J.J., et al., 1999. High frequency of TP53 mutations in juvenile pilocytic astrocytomas indicates role of TP53 in the development of these tumors. *Brain Pathol.* 9, 463–467.
- Hayostek, C.J., Shaw, E.G., Scheithauer, B., O'Fallon, J.R., Weiland, T.L., Schomberg, P.J., et al., 1993. Astrocytomas of the cerebellum: a comparative clinicopathologic study of pilocytic and diffuse astrocytomas. *Cancer* 72, 856–869.
- Hegedus, B., Banerjee, D., Yeh, T., Rothermich, S., Perry, A., Rubin, J.B., et al., 2008. Preclinical cancer therapy in a mouse model of neurofibromatosis-1 optic glioma. *Cancer Res.* 68, 1520–1528.
- Hernaiz Driever, P., von Hornstein, S., Pietsch, T., Kortmann, R., Warmuth-Metz, M., Emser, A., et al., 2010. Natural history and management of low-grade glioma in NF-1 children. *J. Neurooncol.* 100, 199–207.
- Hug, E.B., Muentner, M.W., Archambeau, J.O., DeVries, A., Liwnicz, B., Loreda, L.N., et al., 2002. Conformal proton radiation therapy for pediatric low-grade astrocytomas. *Strahlenther. Onkol.* 178, 10–17.
- Jessen, W.J., Miller, S.J., Jousma, E., Wu, J., Rizvi, T.A., Brundage, M.E., et al., 2013. MEK inhibition exhibits efficacy in human and mouse neurofibromatosis tumors. *J. Clin. Invest.* 123, 340–347.
- Johannessen, C.M., Reczek, E.E., James, M.F., Brems, H., Legius, E., Cichowski, K., 2005. The NF1 tumor suppressor critically regulates TSC2 and mTOR. *Proc. Natl. Acad. Sci. U.S.A.* 102, 8573–8578.
- Johnson, M.W., Eberhart, C.G., Perry, A., Tihan, T., Cohen, K.J., Rosenblum, M.K., et al., 2010. Spectrum of pilomyxoid astrocytomas: intermediate pilomyxoid tumors. *Am. J. Surg. Pathol.* 34, 1783–1791.
- Jones, D.T., Kocalkowski, S., Liu, L., Pearson, D.M., Backlund, L.M., Ichimura, K., et al., 2008. Tandem duplication producing a novel oncogenic BRAF fusion gene defines the majority of pilocytic astrocytomas. *Cancer Res.* 68, 8673–8677.
- Jones, D.T., Kocalkowski, S., Liu, L., Pearson, D.M., Ichimura, K., Collins, V.P., 2009. Oncogenic RAF1 rearrangement and a novel BRAF mutation as alternatives to

KIAA1549:BRF1 fusion in activating the MAPK pathway in pilocytic astrocytoma. *Oncogene* 28, 2119–2123.

Jones, D.T., Hutter, B., Jager, N., Korshunov, A., Kool, M., Warnatz, H.J., et al., 2013. Recurrent somatic alterations of FGFR1 and NTRK2 in pilocytic astrocytoma. *Nat. Genet.* 45, 927–932.

Kalra, M., Heath, J.A., Kellie, S.J., Dalla Pozza, L., Stevens, M.M., Swamy, S., et al., 2015. Confirmation of bevacizumab activity, and maintenance of efficacy in retreatment after subsequent relapse, in pediatric low-grade glioma. *J. Pediatr. Hematol. Oncol.* 37, e341–6.

Karajannis, M.A., Legault, G., Fisher, M.J., Milla, S.S., Cohen, K.J., Wisoff, J.H., et al., 2014. Phase II study of sorafenib in children with recurrent or progressive low-grade astrocytomas. *Neuro Oncol.* 16, 1408–1416.

Kaul, A., Chen, Y.H., Emnett, R.J., Dahiya, S., Gutmann, D.H., 2012. Pediatric glioma-associated KIAA1549:BRF1 expression regulates neuroglial cell growth in a cell type-specific and mTOR-dependent manner. *Genes Dev.* 26, 2561–2566.

Kaul, A., Chen, Y.H., Emnett, R.J., Gianino, S.M., Gutmann, D.H., 2013. Conditional KIAA1549:BRF1 mice reveal brain region- and cell type-specific effects. *Genesis*.

Kawachi, Y., Maruyama, H., Ishitsuka, Y., Fujisawa, Y., Furuta, J., Nakamura, Y., et al., 2013. NF1 gene silencing induces upregulation of vascular endothelial growth factor expression in both Schwann and non-Schwann cells. *Exp. Dermatol.* 22, 262–265.

Kilday, J.P., Bartels, U.K., Bouffert, E., 2014. Targeted therapy in pediatric low-grade glioma. *Curr. Neurol. Neurosci. Rep.* 14 (441), 014-0441-0.

Kim, K.Y., Ju, W.K., Hegedus, B., Gutmann, D.H., Ellisman, M.H., 2010. Ultrastructural characterization of the optic pathway in a mouse model of neurofibromatosis-1 optic glioma. *Neuroscience* 170, 178–188.

Kluwe, L., Hagel, C., Tatagiba, M., Thomas, S., Stavrou, D., Ostertag, H., et al., 2001. Loss of NF1 alleles distinguish sporadic from NF1-associated pilocytic astrocytomas. *J. Neuroopathol. Exp. Neurol.* 60, 917–920.

Komotar, R.J., Burger, P.C., Carson, B.S., Brem, H., Olivi, A., Goldthwaite, P.T., et al., 2004. Pilocytic and pilomyxoid hypothalamic/chiasmatic astrocytomas. *Neurosurgery* 54 (72), 79–80, 9; discussion.

Laithier, V., Grill, J., Le Deley, M.C., Ruchoux, M.M., Couanet, D., Doz, F., et al., 2003. Progression-free survival in children with optic pathway tumors: dependence on age and the quality of the response to chemotherapy—results of the first French prospective study for the French Society of Pediatric Oncology. *J. Clin. Oncol.* 21, 4572–4578.

Lau, N., Feldkamp, M.M., Roncarì, L., Loefer, A.H., Shannon, P., Gutmann, D.H., et al., 2000. Loss of neurofibromin is associated with activation of RAS/MAPK and PI3-K/AKT signaling in a neurofibromatosis 1 astrocytoma. *J. Neuroopathol. Exp. Neurol.* 59, 759–767.

Lee da, Y., Yeh, T.H., Emnett, R.J., White, C.R., Gutmann, D.H., 2010. Neurofibromatosis-1 regulates neuroglial progenitor proliferation and glial differentiation in a brain region-specific manner. *Genes Dev.* 24, 2317–2329.

Lee da, Y., Gianino, S.M., Gutmann, D.H., 2012. Innate neural stem cell heterogeneity determines the patterning of glioma formation in children. *Cancer Cell* 22, 131–138.

Legius, E., Dierick, H., Wu, R., Hall, B.K., Marynen, P., Cassiman, J.J., et al., 1994. TP53 mutations are frequent in malignant NF1 tumors. *Genes Chromosomes Cancer* 10, 250–255.

Leon, S.P., Folkner, R.D., Black, P.M., 1996. Microvessel density is a prognostic indicator for patients with astroglial brain tumors. *Cancer* 77, 362–372.

Li, Y., Bollag, G., Clark, R., Stevens, J., Conroy, L., Fults, D., et al., 1992. Somatic mutations in the neurofibromatosis 1 gene in human tumors. *Cell* 69, 275–281.

Lin, A.W., Lowe, S.W., 2001. Oncogenic ras activates the ARF-p53 pathway to suppress epithelial cell transformation. *Proc. Natl. Acad. Sci. U. S. A.* 98, 5025–5030.

Listernick, R., Darling, C., Greenwald, M., Strauss, L., Charrow, J., 1995. Optic pathway tumors in children: the effect of neurofibromatosis type 1 on clinical manifestations and natural history. *J. Pediatr.* 127, 718–722.

Listernick, R., Ferner, R.E., Liu, G.T., Gutmann, D.H., 2007. Optic pathway gliomas in neurofibromatosis-1: controversies and recommendations. *Ann. Neurol.* 61, 189–198.

Liu, G.T., Katowitz, J.A., Rorke-Adams, L.B., Fisher, M.J., 2013. Optic pathway gliomas: neoplasms, not hamartomas. *JAMA Ophthalmol.* 131, 646–650.

Louis, D.N., Ohgaki, H., Wiestler, O.D., Cavenee, W.K., Burger, P.C., Jouvett, A., et al., 2007. The 2007 WHO classification of tumours of the central nervous system. *Acta Neuropathol.* 114, 97–109.

Mascelli, S., Barla, A., Raso, A., Mosci, S., Nozza, P., Biassoni, R., et al., 2013. Molecular fingerprinting reflects different histotypes and brain region in low grade gliomas. *BMC Cancer* 13, 387.

Massimino, M., Spreafico, F., Cefalo, G., Riccardi, R., Tesoro-Tess, J.D., Gandola, L., et al., 2002. High response rate to cisplatin/etoposide regimen in childhood low-grade glioma. *J. Clin. Oncol.* 20, 4209–4216.

Merchant, T.E., Kun, L.E., Wu, S., Xiong, X., Sanford, R.A., Boop, F.A., 2009. Phase II trial of conformal radiation therapy for pediatric low-grade glioma. *J. Clin. Oncol.* 27, 3598–3604.

Messiaen, L.M., Callens, T., Mortier, G., Beysen, D., Vandenbroucke, I., Van Roy, N., et al., 2000. Exhaustive mutation analysis of the NF1 gene allows identification of 95% of mutations and reveals a high frequency of unusual splicing defects. *Hum. Mutat.* 15, 541–555.

Moreno, L., Bautista, F., Ashley, S., Duncan, C., Zacharoulis, S., 2010. Does chemotherapy affect the visual outcome in children with optic pathway glioma? A systematic review of the evidence. *Eur. J. Cancer* 46, 2253–2259.

Muller, K., Gnekow, A., Falkenstein, F., Scheiderbauer, J., Zwiener, I., Pietsch, T., et al., 2013. Radiotherapy in pediatric pilocytic astrocytomas: a subgroup analysis within the prospective multicenter study HIT-LGG 1996 by the German Society of Pediatric Oncology and Hematology (GPOH). *Strahlenther. Onkol.* 189, 647–655.

Nielsen, G.P., Stemmer-Rachamimov, A.O., Ino, Y., Moller, M.B., 1999. Rosenberg AE, Louis DN. Malignant transformation of neurofibromas in neurofibromatosis 1 is associated with CDKN2A/p16 inactivation. *Am. J. Pathol.* 155, 1879–1884.

Opocher, E., Kremer, L.C., Da Dalt, L., van de Wetering, M.D., Viscardi, E., Caron, H.N., et al., 2006. Prognostic factors for progression of childhood optic pathway glioma: a systematic review. *Eur. J. Cancer* 42, 1807–1816.

Origone, P., Defferrari, R., Mazzocco, K., Lo Cunsolo, C., De Bernardi, B., Tonini, G.P., 2003. Homozygous inactivation of NF1 gene in a patient with familial NF1 and disseminated neuroblastoma. *Am. J. Med. Genet. A* 118A, 309–313.

Ozderdem, U., 2004. Targeting neovascular pericytes in neurofibromatosis type 1. *Angiogenesis* 7, 307–311.

Packer, R.J., Ater, J., Allen, J., Phillips, P., Geyer, R., Nicholson, H.S., et al., 1997. Carboplatin and vincristine chemotherapy for children with newly diagnosed progressive low-grade gliomas. *J. Neurosurg.* 86, 747–754.

Pascual-Castroviejo, I., Pascual-Pascual, S.I., Viano, J., Carceller, F., Gutierrez-Molina, M., Morales, C., et al., 2010. Posterior fossa tumors in children with neurofibromatosis type 1 (NF1). *Childs Nerv. Syst.* 26, 1599–1603.

Pasmant, E., Vidaud, M., Vidaud, D., Wolkenstein, P., 2012. Neurofibromatosis type 1: from genotype to phenotype. *J. Med. Genet.* 49, 483–489.

Pollack, I.F., Mulvihill, J.J., 1996. Special issues in the management of gliomas in children with neurofibromatosis 1. *J. Neurooncol.* 28, 257–268.

Pollack, I., Shultz, B., Mulvihill, J., 1996. The management of brainstem gliomas in patients with neurofibromatosis 1. *Neurology* 46 (June), 1652–1660.

Pong, W.W., Higer, S.B., Gianino, S.M., Emnett, R.J., Gutmann, D.H., 2013. Reduced microglial CX3CR1 expression delays neurofibromatosis-1 glioma formation. *Ann. Neurol.* 73, 303–308.

Reilly, K.M., Loisel, D.A., Bronson, R.T., McLaughlin, M.E., Jacks, T., 2000. Nf1;Trp53 mutant mice develop glioblastoma with evidence of strain-specific effects. *Nat. Genet.* 26, 109–113.

Reilly, K.M., Tuskan, R.G., Christy, E., Loisel, D.A., Ledger, J., Bronson, R.T., et al., 2004. Susceptibility to astrocytoma in mice mutant for NF1 and Trp53 is linked to chromosome 11 and subject to epigenetic effects. *Proc. Natl. Acad. Sci. U. S. A.* 101, 13008–13013.

Ris, M.D., Beebe, D.W., Armstrong, F.D., Fontanesi, J., Holmes, E., Sanford, R.A., et al., 2008. Cognitive and adaptive outcome in extracerebellar low-grade brain tumors in children: a report from the Children's Oncology Group. *J. Clin. Oncol.* 26, 4765–4770.

Rodrigues, L.O., Rodrigues, L.O., Castro, L.L., Rezende, N.A., Ribeiro, A.L., 2013. Non-invasive endothelial function assessment in patients with neurofibromatosis type 1: a cross-sectional study. *BMC Cardiovasc. Disord.* 13 (18), 2261-13-18.

Rodriguez, F.J., Perry, A., Gutmann, D.H., O'Neill, B.P., Leonard, J., Bryant, S., et al., 2008. Gliomas in neurofibromatosis type 1: a clinicopathologic study of 100 patients. *J. Neuroopathol. Exp. Neurol.* 67, 240–249.

Rosser, T.L., Vezina, G., Packer, R.J., 2005. Cerebrovascular abnormalities in a population of children with neurofibromatosis type 1. *Neurology* 64, 553–555.

Roy, A., de Melo, J., Chaturvedi, D., Thein, T., Cabrera-Socorro, A., Houart, C., et al., 2013. LHX2 is necessary for the maintenance of optic identity and for the progression of optic morphogenesis. *J. Neurosci.* 33, 6877–6884.

Sandsmark, D.K., Zhang, H., Hegedus, H., Pelletier, C.L., Weber, J.D., Gutmann, D.H., 2007. Nucleophosmin mediates mammalian target of rapamycin-dependent actin cytoskeleton dynamics and proliferation in neurofibromin-deficient astrocytes. *Cancer Res.* 67, 4790–4799.

Sedani, A., Cooper, D.N., Upadhyaya, M., 2012. An emerging role for microRNAs in NF1 tumorigenesis. *Hum. Genomics* 6 (23), 7364-6-23.

Shamji, M.F., Benoit, B.G., 2007. Syndromic and sporadic pediatric optic pathway gliomas: review of clinical and histopathological differences and treatment implications. *Neurosurg. Focus* 23, E3.

Sharif, S., Ferner, R., Birch, J.M., Gillespie, J.E., Gattamaneni, H.R., Baser, M.E., et al., 2006. Second primary tumors in neurofibromatosis 1 patients treated for optic glioma: substantial risks after radiotherapy. *J. Clin. Oncol.* 24, 2570–2575.

Sharif, S., Upadhyaya, M., Ferner, R., Majounie, E., Shenton, A., Baser, M., et al., 2011. A molecular analysis of individuals with neurofibromatosis type 1 (NF1) and optic pathway gliomas (OPGs), and an assessment of genotype-phenotype correlations. *J. Med. Genet.* 48, 256–260.

Sharma, M.K., Zehnbauer, B.A., Watson, M.A., Gutmann, D.H., 2005. RAS pathway activation and an oncogenic RAS mutation in sporadic pilocytic astrocytoma. *Neurology* 65, 1335–1336.

Sharma, M.K., Mansur, D.B., Reifenberger, G., Perry, A., Leonard, J.R., Aldape, K.D., et al., 2007. Distinct genetic signatures among pilocytic astrocytomas relate to their brain region origin. *Cancer Res.* 67, 890–900.

Sie, M., De Bont, E.S.J.M., Scherpen, F.J.G., Hoving, E.W., Den Dunnen, W.F.A., 2010. Tumour vasculature and angiogenic profile of paediatric pilocytic astrocytoma; is it much different from glioblastoma. *Neuropathol. Appl. Neurobiol.* 36, 636–647.

Sievert, A.J., Fisher, M.J., 2009. Pediatric low-grade gliomas. *J. Child Neurol.* 24, 1397–1408.

Sievert, A.J., Lang, S.S., Boucher, K.L., Madsen, P.J., Slaunwhite, E., Choudhari, N., et al., 2013. Paradoxical activation and RAF inhibitor resistance of BRAF protein kinase fusions characterizing pediatric astrocytomas. *Proc. Natl. Acad. Sci. U. S. A.* 110, 5957–5962.

- Stokland, T., Liu, J.F., Ironside, J.W., Ellison, D.W., Taylor, R., Robinson, K.J., et al., 2010. A multivariate analysis of factors determining tumor progression in childhood low-grade glioma: a population-based cohort study (CCLG CNS9702). *Neuro Oncol.* 12, 1257–1268.
- Subramanian, L., Sarkar, A., Shetty, A.S., Muralidharan, B., Padmanabhan, H., Piper, M., et al., 2011. Transcription factor *Lhx2* is necessary and sufficient to suppress astroglialogenesis and promote neurogenesis in the developing hippocampus. *Proc. Natl. Acad. Sci. U. S. A.* 108, E265–74.
- Szudek, J., Birch, P., Riccardi, V.M., Evans, D.G., Friedman, J.M., 2000. Associations of clinical features in neurofibromatosis 1 (NF1). *Genet. Epidemiol.* 19, 429–439.
- Taylor, T., Jaspan, T., Milano, G., Gregson, R., Parker, T., Ritzmann, T., et al., 2008. Radiological classification of optic pathway gliomas: experience of a modified functional classification system. *Br. J. Radiol.* 81, 761–766.
- Tchoghandjian, A., Fernandez, C., Colin, C., El Ayachi, I., Voutsinos-Porche, B., Fina, F., et al., 2009. Pilocytic astrocytoma of the optic pathway: a tumour deriving from radial glia cells with a specific gene signature. *Brain* 132, 1523–1535.
- Terashima, K., Chow, K., Jones, J., Ahern, C., Jo, E., Ellezam, B., et al., 2013. Long-term outcome of centrally located low-grade glioma in children. *Cancer* 119, 2630–2638.
- Tong, J., Hannan, F., Zhu, Y., Bernards, A., Zhong, Y., 2002. Neurofibromin regulates G protein-stimulated adenylyl cyclase activity. *Nat. Neurosci.* 5, 95–96.
- Tong, J.J., Schriener, S.E., McCleary, D., Day, B.J., Wallace, D.C., 2007. Life extension through neurofibromin mitochondrial regulation and antioxidant therapy for neurofibromatosis-1 in *Drosophila melanogaster*. *Nat. Genet.* 39, 476–485.
- Upadhyaya, M., Kluwe, L., Spurlock, G., Monem, B., Majounie, E., Mantripragada, K., et al., 2008. Germline and somatic NF1 gene mutation spectrum in NF1-associated malignant peripheral nerve sheath tumors (MPNSTs). *Hum. Mutat.* 29, 74–82.
- Viskochil, D., Buchberg, A.M., Xu, G., Cawthon, R.M., Stevens, J., Wolff, R.K., et al., 1990. Deletions and a translocation interrupt a cloned gene at the neurofibromatosis type 1 locus. *Cell* 62, 187–192.
- Walker, D.A., Liu, J., Kieran, M., Jabado, N., Picton, S., Packer, R., et al., 2013. A multi-disciplinary consensus statement concerning surgical approaches to low-grade, high-grade astrocytomas and diffuse intrinsic pontine gliomas in childhood (CPN Paris 2011) using the Delphi method. *Neuro Oncol.* 15, 462–468.
- Wallace, M.R., Marchuk, D.A., Andersen, L.B., Letcher, R., Odeh, H.M., Saulino, A.M., et al., 1990. Type 1 neurofibromatosis gene: identification of a large transcript disrupted in three NF1 patients. *Science* 249, 181–186.
- Wang, Q., Montmain, G., Ruano, E., Upadhyaya, M., Dudley, S., Liskay, R.M., et al., 2003. Neurofibromatosis type 1 gene as a mutational target in a mismatch repair-deficient cell type. *Hum. Genet.* 112, 117–123.
- Wang, Y., Kim, E., Wang, X., Novitsch, B.G., Yoshikawa, K., Chang, L.S., et al., 2012. ERK inhibition rescues defects in fate specification of *Nf1*-deficient neural progenitors and brain abnormalities. *Cell* 150, 816–830.
- Warrington, N.M., Woerner, B.M., Dagainakatte, G.C., Dasgupta, B., Perry, A., Gutmann, D.H., et al., 2007. Spatiotemporal differences in *CXCL12* expression and cyclic AMP underlie the unique pattern of optic glioma growth in neurofibromatosis type 1. *Cancer Res.* 67, 8588–8595.
- Warrington, N.M., Gianino, S.M., Jackson, E., Goldhoff, P., Garbow, J.R., Pivnicka-Worms, D., et al., 2010. Cyclic AMP suppression is sufficient to induce gliomagenesis in a mouse model of neurofibromatosis-1. *Cancer Res.* 70, 5717–5727.
- Widemann, B.C., Salzer, W.L., Arceci, R.J., Blaney, S.M., Fox, E., End, D., et al., 2006. Phase I trial and pharmacokinetic study of the farnesyltransferase inhibitor tipifarnib in children with refractory solid tumors or neurofibromatosis type 1 and plexiform neurofibromas. *J. Clin. Oncol.* 24, 507–516.
- Williams, V.C., Lucas, J., Babcock, M.A., Gutmann, D.H., Korf, B., Maria, B.L., 2009. Neurofibromatosis type 1 revisited. *Pediatrics* 123, 124–133.
- Wimmer, K., Eckart, M., Meyer-Puttlitz, B., Fonatsch, C., Pietsch, T., 2002. Mutational and expression analysis of the NF1 gene argues against a role as tumor suppressor in sporadic pilocytic astrocytomas. *J. Neuropathol. Exp. Neurol.* 61, 896–902.
- Wu, B.L., Schneider, G.H., Korf, B.R., 1997. Deletion of the entire NF1 gene causing distinct manifestations in a family. *Am. J. Med. Genet.* 69, 98–101.
- Yeh, T.H., Lee da, Y., Gianino, S.M., Gutmann, D.H., 2009. Microarray analyses reveal regional astrocyte heterogeneity with implications for neurofibromatosis type 1 (NF1)-regulated glial proliferation. *Glia* 57, 1239–1249.
- Zhang, J., Wu, G., Miller, C.P., Tatevossian, R.G., Dalton, J.D., Tang, B., et al., 2013. Whole-genome sequencing identifies genetic alterations in pediatric low-grade gliomas. *Nat. Genet.* 45, 602–612.
- Zhu, Y., Romero, M.I., Ghosh, P., Ye, Z., Charnay, P., Rushing, E.J., et al., 2001. Ablation of NF1 function in neurons induces abnormal development of cerebral cortex and reactive gliosis in the brain. *Genes Dev.* 15, 859–876.
- Zhu, Y., Guignard, F., Zhao, D., Liu, L., Burns, D.K., Mason, R.P., et al., 2005a. Early inactivation of p53 tumor suppressor gene cooperating with NF1 loss induces malignant astrocytoma. *Cancer Cell* 8, 119–130.
- Zhu, Y., Harada, T., Liu, L., Lush, M.E., Guignard, F., Harada, C., et al., 2005b. Inactivation of NF1 in CNS causes increased glial progenitor proliferation and optic glioma formation. *Development* 132, 5577–5588.
- Zoncu, R., Efeyan, A., Sabatini, D.M., 2011. mTOR: from growth signal integration to cancer, diabetes and ageing. *Nat. Rev. Mol. Cell Biol.* 12, 21–35.

## Biographies

**Jelte Helfferich** (M.D.) is a resident in neurology at the Department of Neurology, University Medical Center Groningen, Groningen, The Netherlands. He graduated in Medicine at the University of Groningen in 2014 and performed research at the Department of Neurology, University of Pennsylvania in 2010/2011. He is currently involved in a PhD program focusing on protein expression in pediatric low grade gliomas, particularly in Neurofibromatosis type 1.

**Eveline S.J.M. de Bont** (M.D., Ph.D.) is professor and head of the Division of Paediatric Oncology/Hematology, Department of Paediatrics, Beatrix Children's Hospital, University Medical Center Groningen, Groningen, The Netherlands. She graduated in Medicine at the University of Amsterdam in 1989. She has worked at the Department for Cancer Biology, Harvard School of Public Health, Boston, USA, in 1997. She obtained her Ph.D. degree in Medical Sciences at the University of Groningen in 1999. Her main research interests are focused on dissecting the role (and mechanism) of receptor tyrosine kinase signalling especially VEGF/VEGFR signalling on tumour cells and surrounding cells in paediatric brain tumours and acute myeloid leukemia to develop new therapeutic strategies.