



## Fungal osteomyelitis with vertebral re-ossification



Devon J. O'Guinn, Demitre Serletis, Noojan Kazemi\*

Department of Neurosurgery, University of AR for Medical Sciences, Little Rock, AR 72205, USA

### ARTICLE INFO

#### Article history:

Received 19 October 2015

Accepted 30 November 2015

Available online 8 December 2015

#### Keywords:

Blastomycosis

Osteomyelitis

Thoracic

Lytic

Fungal infection

Re-ossification

### ABSTRACT

**INTRODUCTION:** We present a rare case of thoracic vertebral osteomyelitis secondary to pulmonary *Blastomyces dermatitides*.

**PRESENTATION OF CASE:** A 27-year-old male presented with three months of chest pains and non-productive cough. Examination revealed diminished breath sounds on the right. CT/MR imaging confirmed a right-sided pre-/paravertebral soft tissue mass and destructive lytic lesions from T2 to T6. CT-guided needle biopsy confirmed granulomatous pulmonary Blastomycosis. Conservative management with antifungal therapy was initiated. Neurosurgical review confirmed no clinical or profound radiographic instability, and the patient was stabilized with TLSO bracing. Serial imaging 3 months later revealed near-resolution of the thoracic soft tissue mass, with vertebral re-ossification from T2 to T6.

**DISCUSSION:** Fungal osteomyelitis presents a rare entity in the spectrum of spinal infections. In such cases, lytic spinal lesions are classically seen in association with a large paraspinal mass. Fungal infections of the spinal column may be treated conservatively, with surgical intervention reserved for progressive cases manifesting with neurological compromise and/or spinal column instability. Here, we found unexpected evidence for vertebral re-ossification across the affected thoracic levels (T2–6) in response to IV antibiotic therapy and conservative bracing, nearly 3 months later.

© 2015 The Authors. Published by Elsevier Ltd. on behalf of IJS Publishing Group Ltd. This is an open access article under the CC BY-NC-ND license (<http://creativecommons.org/licenses/by-nc-nd/4.0/>).

### 1. Introduction

Fungal osteomyelitis presents a rare entity in the spectrum of spinal infections [1], and is typically caused by *Aspergillus* or *Candida* [2]. We report here on a case of vertebral osteomyelitis causing lytic destruction from T2 to T6, in the context of pulmonary *Blastomyces dermatitides*. Following conservative therapy (anti-fungal medication and TLSO bracing), serial imaging revealed infectious resolution with unusual vertebral re-ossification across the affected thoracic levels. To the best of our knowledge, this phenomenon has not yet been reported in the literature [3].

### 2. Case report

A 27-year-old male presented with a three-month history of chest, back and abdominal pains, in the context of a non-productive cough. Past medical history was significant for IV drug use and alcohol dependence. Physical examination revealed no infectious symptoms or neurological deficits; however, he was noted to have diminished breath sounds on the right. CT/MR imaging confirmed a right-sided lung mass, with an associated 9 × 5 cm pre-/paravertebral soft tissue mass extending towards

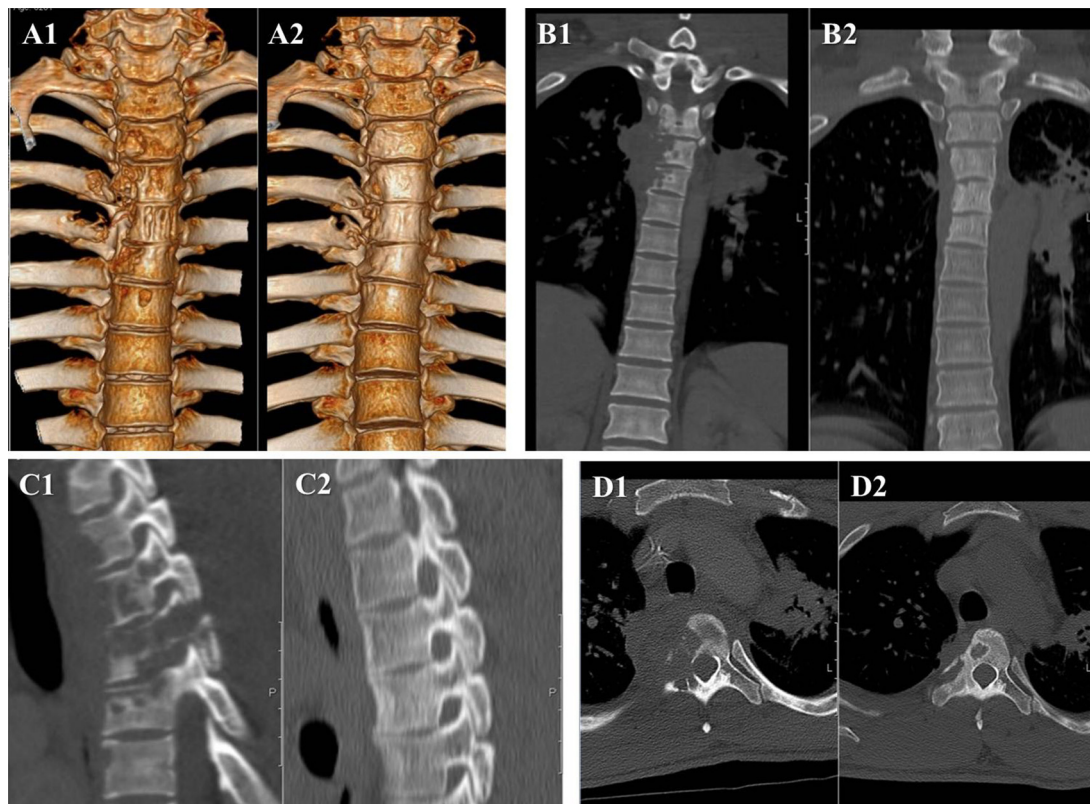
the right anterolateral epidural space. Of note, destructive lytic lesions were also found at multiple thoracic (T2–T6) vertebrae (Fig. 1A1,B1,C1,D1). CT-guided needle biopsy of the lung mass confirmed necrotizing, granulomatous, pulmonary *Blastomycosis*. Conservative management with IV amphotericin B (which resulted in acute kidney failure), followed by oral voriconazole, was initiated by the ID service. Neurosurgical review confirmed no clinical or profound radiographic instability, and the patient was treated with precautionary TLSO bracing for axial stabilization. Serial imaging 3 months later revealed near-resolution of the thoracic soft tissue mass, with evidence for thoracic vertebral re-ossification from T2 to T6 (Fig. 1A2,B2,C2,D2).

### 3. Discussion

Fungal osteomyelitis presents a rare entity in the spectrum of spinal infections [1,4], and is typically caused by *Aspergillus* or *Candida* [2]. *Blastomyces* infections are typically granulomatous cutaneous or respiratory in etiology, more commonly seen in the south-eastern and mid-western United States, and the diagnosis may be considered not only in these endemic regions but also in immunocompromised patients [5]. The spine is a primary target in such infections, with destructive lesions classically seen in association with a large paraspinal mass. As with most cases of granulomatous vertebral osteomyelitis [4], fungal infections of the spinal column may be treated conservatively with antifun-

\* Correspondence to: 4301 W. Markham St., #507, Little Rock, AR 72205, USA. Fax: +1 501 686 8767.

E-mail address: [njkazemi@uams.edu](mailto:njkazemi@uams.edu) (N. Kazemi).



**Fig. 1.** Osteomyelitis secondary to spinal *Blastomycosis*. A1, Coronal, contrast-enhanced, 3-D CT identifying extensive necrotic changes and bony destruction of the T2–T6 vertebral bodies, with loss of intervertebral disc spaces at T3/4 and T4/5. There is evidence for destruction of the right-sided fourth and fifth thoracic ribs (specifically at the sternocostal joints, extending toward each rib's head, neck and tubercle). A2, Coronal, contrast-enhanced, 3-D CT reveals resolution of the previously-identified osseous destruction following anti-fungal therapy, nearly 8 months later. B1, Coronal, T1-weighted MRI showing a focal, paraspinous infection with contiguous lytic destruction of the T2–T6 vertebral bodies. B2, Coronal, T1-weighted MRI confirming resolution of the previously-identified infection, with re-ossification of the T2–T6 vertebral bodies nearly 8 months following treatment. C1, Sagittal, non-contrast CT illustrating osseous destruction of the T2–T6 vertebral bodies, including pedicle destruction of T4 and T5. C2, Sagittal, non-contrast CT revealing re-ossification at these levels, nearly 8 months following treatment. D1, Axial, non-contrast CT showing destruction of the T4 vertebral body, pedicle, transverse process and lamina. D2, Axial, non-contrast CT shows re-ossification of the T4 vertebral body with annealed pedicle, transverse process and lamina, in addition to resolution of the previously-identified paraspinous mass.

gal agents (such as amphotericin B), with surgical intervention reserved for progressive cases manifesting with neurological compromise and/or spinal column instability. In regards to the unusual case of fungal osteomyelitis presented herein, we found unexpected evidence for vertebral re-ossification across the affected thoracic levels (T2–6) in response to IV antibiotic therapy and conservative bracing, over 3 months later.

#### 4. Conclusion

This case report illustrates a rare fungal infection of the vertebral spinal column causing extensive lytic destruction from T2 to T6, with excellent response to conservative therapy (i.e., IV anti-fungal therapy and bracing). Serial imaging at 3 months confirmed the unusual finding of vertebral re-ossification across the affected levels. We conclude that spinal *Blastomycosis* may be treated conservatively when there is no evidence for neurological compromise or spinal instability, and should be followed for resolution with serial imaging. We also report on the rare finding of subsequent vertebral re-ossification with conservative management; to the best of our knowledge, this rare phenomenon has not yet been reported in the literature [3].

#### Conflict of interest

None.

#### Funding

Nothing to declare.

#### Ethical approval

N/A.

#### Consent

Written informed consent was obtained from the patient for publication of this case report and accompanying images. A copy of the written consent is available for review by the Editor-in-Chief of this journal on request.

#### Authors' contributions

Devon J. O'Guinn—helped with data collection, interpretation and writing the paper. Demitre Serletis—contributed to initial draft, review of the final manuscript and final submission of the paper. Noojan Kazemi—contributed to study concept/design, data collection, data analysis and interpretation, and review of the final manuscript and its final submission.

#### Guarantor

Dr. Noojan Kazemi.

**Acknowledgements**

None.

**References**

- [1] J.R. Dimar, R.M. Puno, M.R. Nowacki, L.Y. Carreon, Surgery for blastomycosis of the spine, *Am. J. Orthop.* 43 (2014) E266–E271.
- [2] D. Ganesh, J. Gottlieb, S. Chan, O. Martinez, F. Eismont, Fungal infections of the spine, *Spine* 40 (2015) E719–E728.
- [3] A.G. Hadjipavlou, J.T. Mader, H.J. Nauta, J.T. Necessary, G. Chaljub, A. Adesokan, Blastomycosis of the lumbar spine: case report and review of the literature, with emphasis on diagnostic laboratory tools and management, *Eur. Spine J.* 7 (1998) 416–421.
- [4] M.R. Murray, G.D. Schroeder, W.K. Hsu, Granulomatous vertebral osteomyelitis: an update, *J. Am. Acad. Orthop. Surg.* 23 (2015) 529–538.
- [5] J.R. Youmans, H.R. Winn, *Youmans Neurological Surgery*, 6th ed., Saunders, Philadelphia, PA, 2011.

**Open Access**

This article is published Open Access at [scimedirect.com](http://scimedirect.com). It is distributed under the [IJSCR Supplemental terms and conditions](#), which permits unrestricted non commercial use, distribution, and reproduction in any medium, provided the original authors and source are credited.