pts) with E/A ≥ 2 and A ≤ 35, and a nonrestrictive (30 pts) with E/A < 2 or A > 35. Results (mean ± SD):

	S	D	Ar	LA
Restrictive:	28 ± 11	66 ± 13	12 ± 10	4.8 ± 0.4
Nonrestrictive:	51 ± 10	44 ± 10	24 ± 9	4.2 ± 0.6
p:	<0.01	<0.01	<0.01	<0.01

There was no relationship between PWP and Ar (r = 0.003, p = NS). However, an elevated PWP was associated a decreased S (r = – 0.70, P < 0.01) and an increased D (r = 0.76, p < 0.01). Thus, the Doppler echo findings in heart failure pts with a restrictive transmitral flow pattern suggest that both reduced LA compliance (i.e. decreased systolic atrial filling and high PWP) and reduced LA contraction (i.e. decreased forward and backward flow during atrial systole) contribute to abnormal left atrial transport function.

984-113 Stroke Volume From Computerized Analysis of Digital Color Flow Images: Comparison With Transonic Flow Probe

Jeffrey S. Soble, Thomas Stamos, Beomjin Kim, Alex Neumann, JoAnne Schmitt, Mark J. Harry, Niraj Sehgal, Gary L. Schaer, Tony Hursey, James Robergé, Richard H. Marcus. *Rush Medical College and Illinois Institute of Technology, Chicago, IL*

Validation studies of color flow stroke volume (CFSV), obtained by analysis of quantitative velocities within digital color flow (CF) images of the left ventricular outflow tract (LVOT), have shown a small systematic underestimation compared to the standard pulsed wave method in humans. We sought to compare CFSV to a more rigorous flow standard. CFSV using custom software designed for Hewlett-Packard digital CF images was compared to stroke volume measured simultaneously by an aortic Transonic flow probe (TSFP) in six open chested dogs. Digital CF images were acquired at frame rates of 35–45 MHz by epicardial imaging at baseline, after propranolol, and with pacing at 80 and 110 BPM, then redisplayed and analyzed off-line. After identifying the LVOT, the spatial distribution and magnitude of pixel velocities were determined automatically for each frame. Four pairs of semicircular concentric flow velocity rings were generated and CFSV was calculated from spatial and temporal integration of velocities throughout ejection. Hemiaxial symmetry was assumed. *Results:* Mean values for the CFSV and TSFP were 26.6 ± 8.4 and 26.7 ± 7.3 ml, respectively. The bias (average difference) was small (–0.1 ml) and the 95% confidence intervals narrow (+6.9 to –7.1 ml).

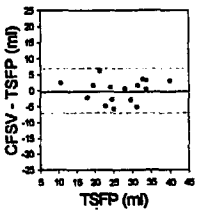

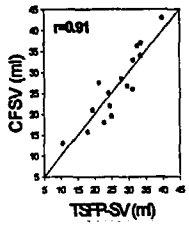

Conclusions: CFSV from computerized quantitative analysis of digital CF images is accurate compared to TSFP in this animal model. Discrepancies in humans may be related to a higher range of stroke volume or the quality of transthoracic images.

984-114 Accuracy of Computerized Quantitative Analysis of Digital Color Flow Doppler Images for Stroke Volume Determination

Jeffrey S. Soble, Thomas Stamos, Beomjin Kim, Alex Neumann, James H. Stein, Dae H. Kim, Joseph E. Parillo, James Robergé, Richard H. Marcus. *Rush Medical College/Illinois Institute of Technology, Chicago, IL*

Computer analysis of the quantitative velocity information within digital color flow images of the left ventricular outflow tract (LVOT) may provide easier and faster access to flow quantitation than current methods. Color flow stroke volume (CFSV) was obtained in 10 patients using custom software designed for Hewlett-Packard digital color flow images. CFSV was compared with stroke volume from pulsed wave (PW) Doppler and LVOT cross sectional area. Digital color flow data were acquired in the apical long-axis view at frame rates of 35–45 MHz, redisplayed and analyzed off-line. After identifying the LVOT, the spatial distribution and magnitude of pixel velocities were determined automatically for each frame. Four pairs of semicircular concentric flow velocity rings were generated, and CFSV was calculated from spatial and temporal integration of velocities throughout ejection. Hemiaxial symmetry was assumed. *Results:* Mean values for the CFSV and PW techniques were 74.9 ± 7.5 and 80.9 ± 4.4 ml, respectively. CFSV systematically underestimated PW but the bias *(average difference)* was small (–7.6%, p = 0.004) and the 95% confidence limits of agreement between the two methods were narrow (–19.8% to +4.5%).

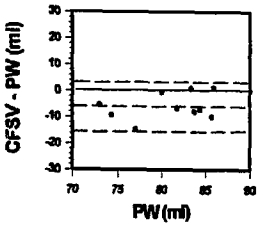

Conclusions: CFSV from computerized quantitative analysis of digital images is feasible, with slight underestimation of stroke volume compared with standard PW Doppler. Further study is needed to identify whether this small systematic difference arises from velocimetric, spatial or temporal components of the color flow data or CFSV algorithm.

984-115 In Vivo Determination of Left Ventricular Stress-Shortening Relations in Mice Using Echocardiography

Zia U. Khan, Corinn Dahm, Richard A. Walsh, Brian D. Hoit. *Univ. of Cincinnati, Cincinnati, OH*

Although targeted alterations of the mouse genome are used increasingly to identify the mechanisms underlying cardiac function, the methods used to study the phenotypic expression of these alterations *in vivo* are limited. In order to derive a noninvasive, load-independent measure of LV contractility in mice, we cannulated the femoral artery and performed 2-D directed M-mode echo studies (9 MHz, Interspec – ATL CX 200) in 16 anesthetized FVB/N mice (31.3 ± 2.6 gm). Loading conditions were altered by intraarterial methoxamine (3–12 μg/g), and LV shortening fraction (SF) was determined at several steady states both before and after myocardial contractility was altered by intraperitoneal dobutamine (4 μg/gm). The slopes of the pooled LV systolic meridional stress-shortening relation were inverse and linear both before (r = 0.80, slope = 0.2 %/g/cm^2, intercept = 50%, SEE = 1.3%) and after dobutamine (r = 0.78, slope = 0.2%/g/cm^2, intercept = 59%, SEE = 0.9%, both p < 0.0001):

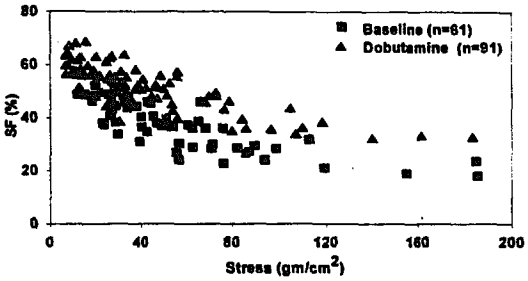

At matched low (28 ± 8 g/cm^2) and high (61 ± 19 g/cm^2) levels of LV stress, SF was significantly greater after dobutamine than before (55 ± 5 vs. 44 ± 5% and 45 ± 7 vs. 35 ± 8%, respectively; both p < 0.05). We conclude: 1) inverse stress-shortening relations can be assessed noninvasively in mice; 2) these relations are sensitive to alterations in inotropic state, independent of loading conditions.

985 Advances in Doppler Echocardiography

Tuesday, March 26, 1996, 3:00 p.m.–5:00 p.m.
Orange County Convention Center, Hall E
Presentation Hour: 3:00 p.m.–4:00 p.m.

985-101 Incremental Information Provided by Three-Dimensional Echocardiography in the Delineation of Vegetations, Perforations and Abscesses in Patients With Endocarditis

Tsui-Lieh Hsu, Shuenn-Jinn Ho, Alain Delabays, Lissa Sugeng, Giuseppina Magni, Stefano De Castro, Gerald Marx, Ravi Kasliwal, Ajay Kanojia, Naresh Trehan, Natesa Pandian. *VA General Hospital, Taipei; Tufts-New England Medical Center, Boston, Mass.*

To explore whether 3-D echocardiography (3DE) provides added information