

# Remote-Control Percutaneous Coronary Interventions

## Concept, Validation, and First-in-Humans Pilot Clinical Trial

Rafael Beyar, MD, DSc,\* Luis Gruberg, MD,\* Dan Deleanu, MD,† Ariel Roguin, MD, PhD,\* Yaron Almagor, MD,‡ Silviu Cohen, RN,\* Ganesh Kumar, MD,\* Tal Wenderow, BSc§

Haifa and Jerusalem, Israel; and Bucharest, Romania

<b>OBJECTIVES</b>	This study was designed to assess the feasibility and safety of a Remote Navigation System (RNS, NaviCath, Haifa, Israel) in which the angioplasty guidewire, the balloon, and the stent are navigated via a computerized system.
<b>BACKGROUND</b>	Percutaneous coronary interventions (PCIs) are manually performed under fluoroscopic guidance, requiring lead protection for the operators. A system in which the operator can remotely, safely, and precisely navigate the procedure during PCI would have clear advantages.
<b>METHODS</b>	The RNS involves a computer-controlled wire and delivery system navigator. Following preclinical validation, the system was assessed in patients undergoing single-vessel PCI.
<b>RESULTS</b>	The study involved 18 patients (age 55.9 years, 16% women). The RNS successfully crossed lesions with the guidewire in 17 patients. The stent was then advanced by the advance/rotate mode and adequately positioned in 15 of 17 cases. Technical malfunction was encountered in three patients in whom the procedure was successfully completed manually. Direct stenting was employed in 10 of 18 patients, pre-dilation in 7 patients, and after-stent balloon dilation in 5 patients. The total fluoroscopy time for 17 RNS patients was compared with the corresponding time of 20 consecutive patients who underwent standard single-lesion PCI. Fluoroscopy time was similar for both procedures, with $8.8 \pm 4.8$ min with the RNS versus $9.1 \pm 3.5$ min with the standard techniques ( $p = \text{NS}$ ). Clinical success was 100% and technical success 94% for the guidewire and 83% for the overall procedure.
<b>CONCLUSIONS</b>	The use of the RNS for guidewire, balloon, and stent manipulation during PCI appears safe and feasible for the treatment of patients with coronary stenosis. The system offers operator radiation safety and may enhance precision of stent placement and balloon dilation strategies. (J Am Coll Cardiol 2006;47:296–300) © 2006 by the American College of Cardiology Foundation

Stent-assisted percutaneous coronary interventions (PCIs) have become the major method for revascularization (1). These interventions have been recently affected by drug-eluting stents that have markedly reduced restenosis rates (2–4). Radiation exposure is a concern, particularly in view of the increasing number and complexity of coronary interventions, which require strict staff monitoring (5–7). In addition, spine problems attributable to lead aprons have become known as “interventionalist’s disc disease” (8). This phenomenon may underscore the need for a method that will enable coronary interventions from a remote location away from radiation fields. Remote-control robotic interventions have been suggested for radiologic and surgical procedures (9–11) and enable increased accuracy and the ability to work through small ports. However, such systems have not been developed for coronary interventions. We report here the preclinical experiments and first-in-humans experience with a remote-control manipulation system for

PCI allowing navigation of the guidewire and angioplasty devices in a convenient, radiation-free environment.

## METHODS

**Device description.** An overview of the setup of the Remote Navigation System (RNS, NaviCath, Haifa, Israel) during the pilot clinical experiments is shown in [Figure 1](#). The bedside unit ([Fig. 2](#)) includes the motor base and the detachable wire and device navigators. The operator control unit ([Fig. 3](#)), located away from the patient bed, comprises a computerized touch-screen control console and a joystick. The system controls the wire for axial (advance/retract) and rotational movements and the device for movements along the axial direction as detailed later.

The guidewire is maneuvered using both the joystick and the touch screen. The axial and rotational guidewire motions are achieved by a mechanical transmission module. An option for discrete wire rotations is available in which the guidewire can be rotated at 30° angles. When the guidewire is manipulated, the device is locked at its position and vice versa. Similarly, the angioplasty device (stent or balloon) can be guided both in a continuous motion (joystick) and in discrete steps (touch screen). Axial motion is achieved by the motored-roller pair. An additional passive roller pair located behind the motored pair is used to monitor the function of the roller device transmission ([Fig. 2](#)). If the

From the \*Division of Invasive Cardiology, Rambam Medical Center and the Technion, Haifa, Israel; †Cardiovascular Disease Institute “Prof. C. C. Iliescu,” Fundeni Hospital, Bucharest, Romania; ‡Department of Cardiology, Shaare’i Zedek Medical Center, Jerusalem, Israel; and §NaviCath Ltd., Haifa, Israel. Dr. Beyar is a co-founder and stock owner of NaviCath Ltd. Mr. Wenderow is a co-founder, stock owner, and CEO of NaviCath Ltd.

Manuscript received May 14, 2005; revised manuscript received September 2, 2005, accepted September 12, 2005.

#### Abbreviations and Acronyms

LAD	= left anterior descending coronary artery
LCX	= left circumflex artery
MACE	= major adverse coronary events
PCI	= percutaneous coronary intervention
RCA	= right coronary artery
RNS	= Remote Navigation System
TFT	= total fluoroscopy time

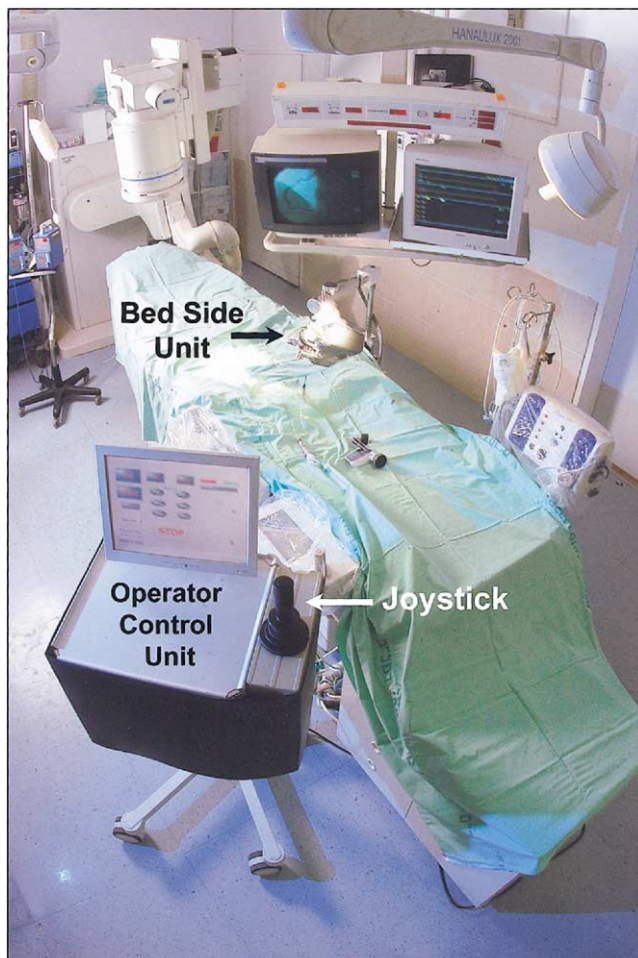
device meets resistance and the motored rollers slide, the motion-sensing rollers report malfunction and the system halts.

**Preclinical studies.** The system was initially tested on a transparent glass coronary model. The model showed that the guidewire can be easily manipulated through branches and that the angioplasty device could be easily positioned at the required location. The system was then tested in an anesthetized coronary sheep model. The procedure was repeated in each animal several times; after stent implanta-

tions by the RNS, the results were angiographically assessed.

**Pilot clinical study.** A total of 18 patients (age  $55.9 \pm 12.0$  years; 15 men, 3 women) underwent RNS-guided PCI at three medical centers under an approved protocol. After femoral cannulation with a 6- or 7-F sheath, the target coronary artery was engaged with the appropriate guiding catheter, which was hooked to the RNS. Contrast injections were done either manually or by Automatic Coronary Injection System (ACIST Medical Systems Inc., Eden Prairie, Minnesota). The RNS was loaded with standard 0.014-inch coronary guide wires that were navigated across the lesion by the operator. Subsequently, the device was driven to the lesion using both continuous- and discrete-mode movements for precise positioning. The lesion was predilated in cases of severe stenosis ( $n = 8$ ), and high-pressure post-stent dilation was performed in cases of suboptimal results ( $n = 5$ ). Baseline and final angiograms were recorded. The patients underwent follow-up for immediate, in-hospital, and 30-day major adverse coronary events (MACE) (death, myocardial infarction, urgent revascularization).

The study end points were success in navigating the guidewire across the lesion and success in precise positioning of the device. Technical success was defined as the ability to complete the procedure without reverting to manual mode. Clinical success was defined as the ability to successfully complete the procedure without complications. Offline quantitative coronary angiography was performed at the Rambam Core Laboratory using a CAAS II system (Pie Medical Imaging, Maastricht, the Netherlands). Total catheterization times and total fluoroscopy time (TFT) were recorded for 17 cases (1 unavailable) and were compared with a control group consisting of 20 consecutive patients who underwent single-lesion PCI during the same time period at the Rambam Medical Center.

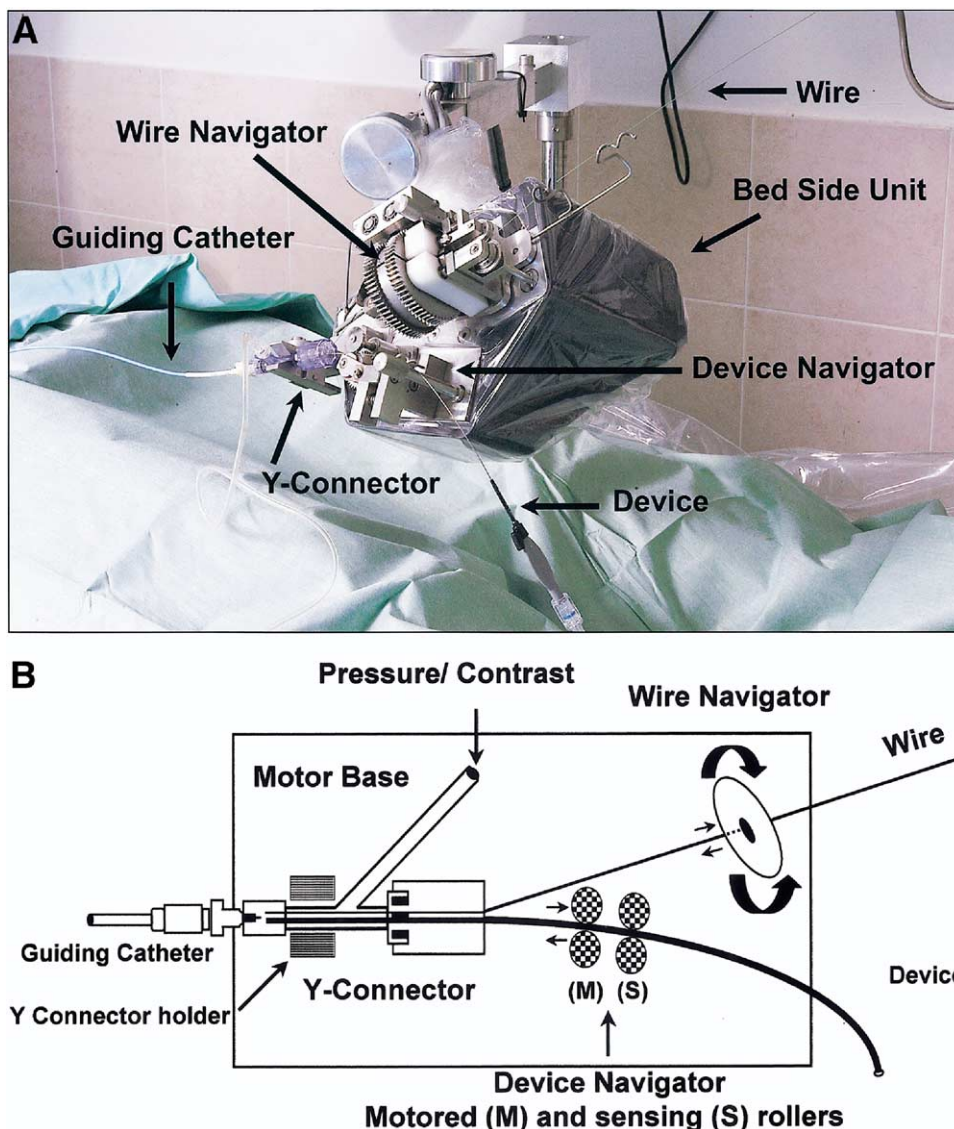


**Figure 1.** The setup of the Remote Navigation System (RNS) during the pilot clinical experiments. The operator control unit of the RNS was placed at the catheterization laboratory. The bedside unit was attached to the table side and adjusted to the groin position. The standard imaging screens were used for guiding the navigation process.

## RESULTS

**Preclinical studies.** After appropriate testing in the transparent glass model, the animal model experiments showed successful navigation of the guide wires at a total of 14 coronary branches. Device malfunctions (system not advancing or retracting) were encountered in two cases and handled manually. A total of eight stents were positioned using the discrete step mode and successfully implanted. There was no angiographic evidence of vessel dissection or trauma. These studies demonstrated the feasibility of wire navigation and device positioning using the RNS.

**Pilot clinical study.** The majority of patients (16 of 18) had stable angina pectoris and typical risk factors for coronary artery disease (diabetes, 22%; hypertension, 39%; smoking history, 32%; hyperlipidemia, 83%; previous myocardial infarction, 39%). The majority ( $n = 11$ ) of patients underwent treatment of the left anterior descending coronary artery (LAD) 11 patients, left circumflex artery (LCX) (2 patients), and right coronary artery (RCA) (5 patients).



**Figure 2.** (A) A prototype of the bedside unit attached to the patient table, loaded with a wire and device. A standard guiding catheter and Y-connector are hooked to a special holder on the base. (B) A schematic diagram of the bedside unit loaded with a wire and device. The guiding catheter hooks to a standard Y-connector, which is attached to the base through a sterile holder. Similarly, the wire and device navigators are attached to the sterile plastic sheet-covered base. The wire navigator controls both axial and rotational motions (arrows). The device navigator, composed of two pairs of rollers, controls the axial motion and discrete positioning of the device delivery system (arrows) and provides online position feedback of the device.


Lesion types ranged between A and C with minimal calcification or angulations.

Clinical success was achieved in all patients. The guide-wire was successfully navigated across the lesion in 17 of 18 cases. In one case a technical problem with the RNS (the system stalled) was successfully managed by immediate transition to manual operation. The stent was successfully delivered in 15 of 17 cases. In two cases, the procedures were completed manually because of device malfunction. Overall, technical success was achieved in 15 of 18 of the patients. Ten patients were treated with direct stenting. In five patients, high-pressure after-stent dilation was performed. All patients were treated with a single stent, except for two patients who required additional stents because of incomplete lesion coverage and distal dissection. There were

no MACE during the procedure or during hospitalization. One patient had a non-target vessel myocardial infarction three weeks after the procedure.

With respect to procedural times, TFT was  $8.8 \pm 4.8$  min with the RNS versus  $9.1 \pm 3.5$  min with the standard techniques ( $p = \text{NS}$ ). Total catheterization time was  $44 \pm 32.7$  min with the RNS versus  $61 \pm 19$  min with the regular cases ( $p = \text{NS}$ ). Although the groups are not randomized, they are comparable with respect to the single-vessel treatment, the mixture of vessels (LAD, 10; RCA, 8; and LCX, 2), and the requirements for additional stents (3 in the control group vs. 2 in the treatment group). Therefore, procedural times for the RNS are comparable to those with standard PCI, despite the early phase of the technology and the limited clinical experience.





**Figure 3.** The operator control unit, composed of a computer, a control console, and a joystick. The screen has various control features, including precise positioning and discrete wire rotation options. Safety “STOP” button is emphasized in red.

By QCA, the reference vessel diameter was  $2.73 \pm 0.66$  mm before PCI and  $2.95 \pm 0.50$  mm after PCI. Minimal luminal diameter increased from  $1.06 \pm 0.42$  mm to  $2.43 \pm 0.40$  mm and the diameter stenosis decreased from 60.6% to  $17.0 \pm 7.8\%$ .

## DISCUSSION

This is the first-in-humans report of coronary stent-assisted PCI using a remote navigation system. We have shown that PCI with stent implantation can be performed safely and efficiently with the RNS, enabling accurate guidewire navigation and precise device positioning.

Robotic manipulation of surgical devices has been reported for several applications, including computed tomography-guided biopsy (9) and surgery (10–12). The shared feature of robotic surgery and the current RNS is the ability to translate the operator maneuvers to remotely manipulate devices and potential increased accuracy (13,14). However, there are basic differences between the surgical and endovascular systems. The surgical systems enable working through small ports under direct visual control and offer patient benefit related to the minimally invasive feature of the technique. The current RNS works through the standard port and does not alter the procedure for the patient, but may have a precision benefit for the patient and a benefit for the operator.

Remote-control magnetically driven manipulation of catheters was recently applied to electrophysiologic procedures as well as to coronary wire navigation (15). In contrast to the magnetically driven system, which has shown magnetic navigation of specific guide wires, the current RNS performs the entire stent-assisted PCI using standard equipment.

The potential advantages of a remote catheterization system can be summarized as:

- reduced operator radiation exposure and spine problems;
- provision of a convenient working environment;

- enhanced precision of balloon and stent positioning, which may translate to clinical benefit;
- future inclusion of semiautomatic, robotically controlled functions; and
- minimizing operator-based errors.

Safety issues with the system have been a crucial element. Built-in safety mechanisms prevent unattended and accidental system malfunctions. The motion units are designed to apply only a mild force; any force that exceeds a threshold causes system stall. Switch to manual operation is quick and simple. For safety reasons, the current protocol requires that the operators stay at the bedside.

Some limitations are inherent to this early phase of device development and evaluation. The system was applied to relatively simple lesions. The ability of the system to tackle complex cases will have to be addressed in the future by upgrading the engineering design and adding additional features that have been suggested for the surgical systems, such as haptic mechanical force feedback (16). In addition, guiding catheter control may be important for online modification of catheter support that may be needed in some cases. Therefore, the results of this study should be considered only as encouraging and facilitating further testing.

In summary, we have shown that remote-controlled, stent-assisted PCI by the RNS is feasible and appears safe. The RNS provides convenient conditions for the operator in an X-ray-free environment and can increase the precision of stent deployment. This report opens the door for ergonomic technologic developments in the catheterization laboratory, aiding physicians in achieving their therapeutic goals.

---

**Reprint requests and correspondence:** Dr. Rafael Beyar, Women’s Division/Dr. Phillip and Sarah Gottlieb Chair in Medicine and Biomedical Engineering, Head, Division of Invasive Cardiology, Rambam Medical Center, Haifa, Israel. E-mail: rafael@tx.technion.ac.il.

---

## REFERENCES

1. Lenzen MJ, Boersma E, Bertrand ME, et al. European Society of Cardiology. Management and outcome of patients with established coronary artery disease: the Euro Heart Survey on coronary revascularization. *Eur Heart J* 2005;26:1169–79.
2. Morice MC, Serruys PW, Sousa JE, et al. A randomized comparison of a sirolimus-eluting stent with a standard stent for coronary revascularization. *N Engl J Med* 2002;346:1773–80.
3. Stone GW, Ellis SG, Cox DA, et al. One-year clinical results with the slow-release, polymer-based, paclitaxel-eluting TAXUS stent: the TAXUS-IV trial. *Circulation* 2004;109:1942–7.
4. Lemos PA, Hoye A, Goedhart D. Clinical, angiographic, and procedural predictors of angiographic restenosis after sirolimus-eluting stent implantation in complex patients: an evaluation from the Rapamycin-Eluting Stent evaluated at Rotterdam Cardiology Hospital (RESEARCH) study. *Circulation* 2004;109:1366–70.
5. Bashore TM, Bates ER, Berger PB, et al. ACC/SCA&I expert consensus document on cath lab standards. *J Am Coll Cardiol* 2001;37:170–214.
6. Batler S, Bates ER, Berger PB, et al. Radiation safety in the cardiac catheterization laboratory: operational radiation safety. *Cath Cardiovasc Interv* 1999;47:347–53.

7. Russell JG, Webb GA. Spending on radiation protection. *Lancet* 1985;1:391.
8. Ross AM, Segal J, Borenstein D, et al. Prevalence of spinal disc disease among interventional cardiologists. *Am J Cardiol* 1997;79:68-70.
9. Solomon SB, Patriciu A, Bohlman ME, et al. Robotically driven interventions: a method of using CT fluoroscopy without radiation exposure to the physician. *Radiology* 2002;225:277-82.
10. Autschbach R, Onnasch JF, Falk V, et al. The Leipzig experience with robotic valve surgery. *J Card Surg* 2000;15:82-7.
11. Stoianovici D, Withcomb LL, Anderson JH, et al. A modular surgical robotic system for image guided percutaneous procedures. In: 1998 MICCAI Lecture, Notes in Computer Science. Berlin, Germany: Springer-Verlag, 1998;1496:404-10.
12. Marescaux J, Leroy J, Gagner M, et al. Transatlantic robot-assisted telesurgery. *Nature* 2001;413:379-80.
13. Fadda M, Marcacci M, Toksvig-Larsen S, et al. Improving accuracy of bone resections using robotics tool holder and a high speed milling cutting tool. *J Med Eng Technol* 1998;22:280-4.
14. Kwoh YS, Hou J, Jonckheere EA, et al. A robot with improved absolute positioning accuracy for CT guided stereotactic brain surgery. *IEEE Trans Biomed Eng* 1988;35:153-60.
15. Ernst S, Ouyang FF, Linder C, et al. Initial experience with remote catheter ablation using a novel magnetic navigation system: magnetic remote catheter ablation. *Circulation* 2004;109:1472-5.
16. Basdogan C, De S, Kim J, et al. Haptics in minimally invasive surgical simulation and training. *IEEE Comp Graph Appl* 2004;24:56-64.