



Case Report

Idiopathic erythrocytosis in a patient on chronic hemodialysis

Dong Hyun Lee, Ji Hye Min, Sang Byung Bae, Hyo Wook Gil, Jong Oh Yang,
Eun Young Lee*, Sae Yong Hong

Department of Internal Medicine, Soonchunhyang University Cheonan Hospital, Cheonan, Korea

A B S T R A C T

Article history:

Received 27 May 2014
Received in revised form
12 September 2014
Accepted 17 September 2014
Available online 27 November 2014

Keywords:

End-stage renal disease
Erythrocytosis
Hemodialysis

A 78-year-old man on hemodialysis presented to our hospital with erythrocytosis. He had started hemodialysis 4 years previously, with a hemoglobin level of 9.8 g/dL, and was administered erythropoiesis stimulating agents and ferrous sulfate. Two years previously, his hemoglobin level increased to 14.5 g/dL and the treatment for anemia was discontinued. He continued hemodialysis thrice weekly; however, the hemoglobin level had increased to 17.0 g/dL at the time of presenting to our hospital. His serum erythropoietin level was 31.4 mIU/mL (range, 3.7–31.5 mIU/mL), carboxyhemoglobin level was 0.6% (range, 0–1.5%), and oxygen saturation in ambient air was 95.4%. The JAK2 V617F mutation was not observed and other bone marrow abnormalities were not identified. The patient was diagnosed with bladder cancer and a transurethral resection was performed. Eight months after the treatment of bladder cancer, his hemoglobin level was 15.1 g/dL, and he was diagnosed with idiopathic erythrocytosis.

Copyright © 2015. The Korean Society of Nephrology. Published by Elsevier. This is an open access article under the CC BY-NC-ND license (<http://creativecommons.org/licenses/by-nc-nd/4.0/>).

Introduction

Erythrocytosis develops when the hemoglobin level increases above the normal level (hematocrit, > 0.51 in males and > 0.48 in females [1]). Erythrocytosis is classified as relative (due to decreased plasma volume), primary (due to an intrinsic defect of the erythropoietic component in the bone marrow [1]), or secondary (associated with conditions that increase erythropoietin levels) in origin. Secondary erythrocytosis can be caused by a physiological elevation due to tissue hypoxia or an abnormal overproduction of erythropoietin (i.e., patients with renal cysts, renal artery stenosis, and tumors with ectopic erythropoietin production) [2]. Idiopathic erythrocytosis is diagnosed when no causes for erythrocytosis are identified. In the present report, we describe a case of an end-stage renal disease (ESRD) patient who developed idiopathic erythrocytosis after initiating hemodialysis.

Case report

A 78-year-old man presented to our hospital with erythrocytosis in November 2013. He was in a good condition while continuing to receive hemodialysis thrice weekly for 4 years, except for the presence of erythrocytosis, as per his monthly blood tests. When he first started hemodialysis, his hemoglobin level was 9.8 g/dL, and therefore, ferrous sulfate and erythropoiesis stimulating agents were prescribed. Iron studies were consistent with anemia of chronic disease (iron level, 100 µg/dL; total iron binding capacity, 261 µg/dL; ferritin, 266 ng/mL). However, the hemoglobin level had increased to 14.5 g/dL after 2 years, and therefore, treatment for anemia was discontinued. After discontinuing anemia treatment, the hemoglobin level increased to 17.0 g/dL despite the absence of any specific events occurring to the patient (Fig. 1). He was diagnosed with hypertension 10 years previously, gout 8 years previously, and had started chronic hemodialysis 4 years previously. A computed tomography (CT) scan was performed 4 years previously because he was found to have renal stones during radiography. CT indicated the presence of multiple renal stones and dilated

* Corresponding author. Soonchunhyang University Cheonan Hospital, 23-20 Bongmyung-dong, Cheonan 330-721, Korea.
E-mail address: eylee@sch.ac.kr (EY Lee).

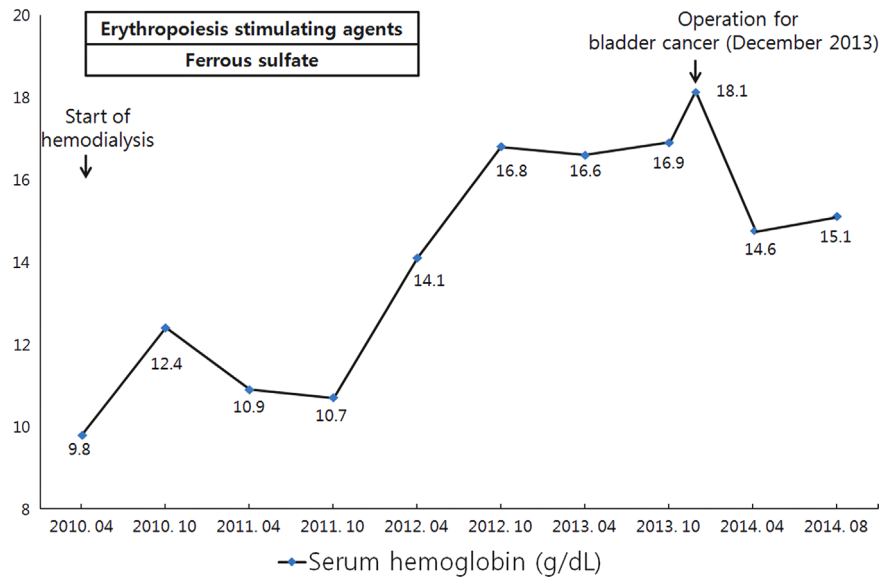


Figure 1. Patient's hemoglobin levels. The X-axis denotes the time course since the start of hemodialysis and the Y-axis denotes the serum hemoglobin level (g/dL). Bars with text represent the duration for which erythropoiesis stimulating agents and ferrous sulfate were prescribed. The patient started hemodialysis in April 2010, with the administration of erythropoiesis stimulating agents and ferrous sulfate. In April 2012, the serum hemoglobin level in the patient was 14.1 g/dL and treatment with erythropoiesis stimulating agents and ferrous sulfate was discontinued. Despite discontinuing anemia treatment, the serum hemoglobin level gradually increased to 18.1 g/dL. In December 2013, an operation was performed for bladder cancer, and the serum hemoglobin level decreased to 14.6 g/dL in April 2014. However, the hemoglobin level again increased to 15.1 g/dL in August 2014.

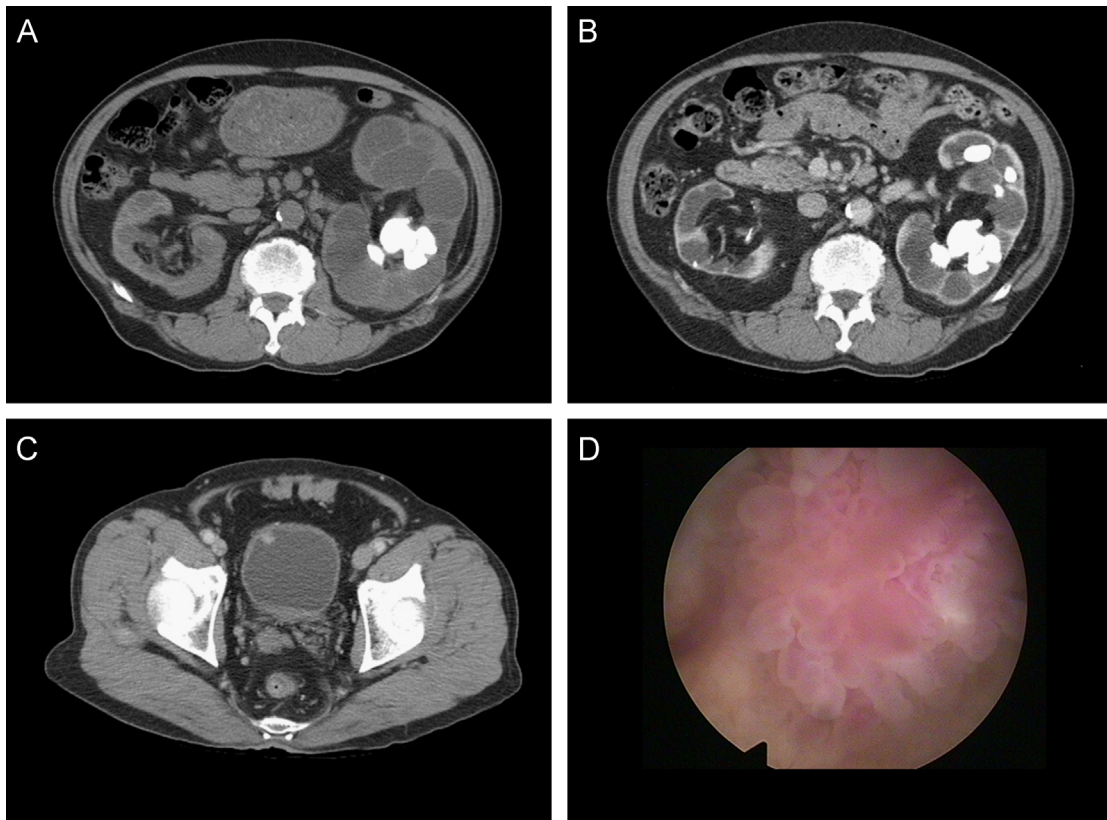


Figure 2. The patient's computed tomographic (CT) and cystoscopic images. (A) The patient's CT image in February 2010. Multiple renal parenchymal and renal pelvic stones with dilated calyces in both kidneys and hydronephrosis in the left kidney are shown. (B) The patient's CT image in November 2013. Multiple renal stones in the left kidney and dilated calyces and hydronephrosis are shown. The dilated calyces and hydronephrosis had not worsened compared with the CT image obtained in February 2010. (C) The patient's CT image in November 2013. A nodular lesion in the right anterior aspect of the urinary bladder is shown. (D) The patient's cystoscopic image. A solitary mass lesion on the right anterior wall of the urinary bladder is shown.

calyces in both kidneys and hydronephrosis in the left kidney. (Fig. 2A).

When the patient presented to our hospital in 2013, he was stable with a blood pressure of 130/80 mmHg and a pulse rate of 88 beats/min. The patient had a height of 162 cm, weight of 66 kg, and a body mass index of 25.1 kg/m². He had been living at an altitude of ~50 m above sea level. He had no complaints of headache, visual disturbances, vertigo, paresthesia, fatigue, and chest or abdominal pain. His only complaint was painless gross hematuria. According to his family, he did not snore or have any apneic periods during sleep. He had a history of smoking (65 pack-year), but stopped 4 years previously. There was no history of cardiopulmonary disease and transfusion of blood products. We referred the patient to a urologist due to his CT findings, but the urologist did not treat the patient because the related symptoms were not present. The patient did not have a familial history of erythrocytosis. His medication included: pyridoxine 10 mg; thiamine 1.5 mg; riboflavin 1.7 mg; ascorbic acid 60 mg; folic acid 1 mg; cyanocobalamin 6 µg; aspirin 100 mg; lercanidipine 20 mg; ezetimibe 10 mg; simvastatin 10 mg; doxazosin 8 mg; allopurinol 100 mg; and tianeptine 12.5 mg daily. He was not taking androgens or anabolic steroids.

The following findings were observed during the evaluation when the patient visited us: white blood cell count, 7,520/µL; hemoglobin, 18.9 g/dL; hematocrit, 53.5%; platelet count, 145,000/µL; blood urea nitrogen, 26.7 mg/dL; creatinine, 6.7 mg/dL; protein, 7.5 g/dL; albumin, 4.4 g/dL; aspartate transaminase/alanine transaminase, 22/24 IU/L; uric acid, 5.3 mg/dL; calcium, 10.1 mg/dL; and phosphorus, 3.1 mg/dL. Hepatosplenomegaly was not observed. According to the peripheral blood smear, there were no other defects, except for normochromic macrocytic red blood cells. The patient's serum erythropoietin level was 31.4 mIU/mL (range, 3.7–31.5 mIU/mL). Arterial blood gas analysis revealed the following: pH, 7.46; PaCO₂, 37.9; PaO₂, 75.6; HCO₃⁻, 26.7; and O₂ saturation in ambient air, 95.4%. The serum carboxyhemoglobin level was 0.6% (range, 0–1.5%). Serum tumor marker levels were normal (CEA, 2.64 ng/mL; AFP, 2.38 ng/mL; PSA, 2.04 ng/mL). After bone marrow aspiration and biopsy of the patient, we observed a slight increase in erythroid elements with a

megaloblastoid appearance of some late normoblasts. The V617F mutation of the JAK2 gene was absent (Fig. 3).

The chest radiograph did not reveal cardiomegaly or any parenchymal abnormalities. The following values were obtained from the pulmonary function test: FEV1/FVC, 71%; FVC, 101%; and FEV1, 104%. In the echocardiographic image, the right to left shunt was not observed, and the systolic and diastolic functions were normal. A gastric ulcer was observed with esophagogastroduodenoscopy, and no abnormal lesions were observed with colonofiberscopy. In the abdominopelvic CT image, we observed no interval change in both renal stones and a decrease in the size of the dilated calyces of left kidney compared with the images obtained 4 years previously (Fig. 2B). There was no evidence of renal cysts, renal cell carcinoma (RCC), or hepatocellular carcinoma (HCC) in the CT image.

A nodular lesion suspicious for bladder cancer was detected in the bladder and the patient underwent a transurethral resection of the bladder in December 2013. The nodular lesion was subsequently diagnosed as transitional cell carcinoma (Fig. 2C and D). After the treatment of bladder cancer, the hemoglobin level decreased gradually to 14.6 g/dL 4 months after the operation, and bladder cancer was considered as the cause of erythrocytosis. However, the hemoglobin level increased again to 17.2 g/dL 5 months after the operation and to 15.1 g/dL after 8 months. After excluding the possible causes of erythrocytosis, we diagnosed the patient with idiopathic erythrocytosis, and the patient is currently being monitored closely.

Discussion

Some of the reported causes of erythrocytosis in hemodialysis patients include polycythemia vera, gastric cancer, RCC, acquired cystic kidney disease, and obstructive sleep apnea syndrome [3–7].

Acquired renal cystic disease is a frequently reported cause of secondary erythrocytosis in hemodialysis patients. The main mechanism of elevation in the serum erythropoietin levels in patients with acquired renal cystic disease involves the overproduction of erythropoietin by the epithelial lining of renal cysts [8].

Several investigators have previously reported on cases of erythrocytosis caused by hydronephrosis, regardless of the hemodialysis state. The mechanism involves increased medullary hypoxia caused by increased pressure of the renal pelvis on the medullary vasculature [9]. In the present case, left-sided hydronephrosis was already present 4 years previously; however, erythrocytosis was not present at that time, and we predicted that decreased kidney function may have been a contributing factor in such cases.

Another cause of excessive erythropoietin production is the presence of erythropoietin-producing tumors. Erythropoietin-producing tumors such as RCC and HCC are frequently encountered in ESRD patients [10]. Therefore, malignancies should also be considered as a cause of erythrocytosis in chronic hemodialysis patients.

Another suspected factor for erythrocytosis in our patient was bladder cancer. However, the erythropoietin-producing property of bladder cancer has not yet been established. At present, there is only a single report of spontaneous erythrocytosis proven to be caused by bladder cancer in a patient with normal renal function [11]. However, the bladder cancer in the present case was not found to be the cause of erythrocytosis because the serum hemoglobin levels again increased after the operation for tumor removal.

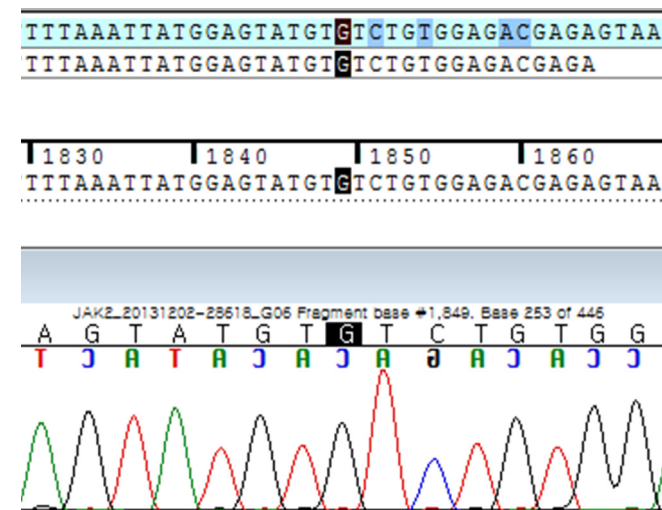


Figure 3. Patient's DNA sequencing test for the JAK2 V617F mutation. A substitution of guanine (G) by thymine (T) at the nucleotide position 1849 [c.1849G > T (V617F) mutation] within exon 14 of the JAK2 gene was not identified.

Finally, erythrocytosis can be caused by mutations of the erythropoietin receptor gene [i.e., a deletion mutation (Del1377-1411), nonsense mutation (C1370A), and missense mutation (G1445A)], or mutations in the erythropoietin-receptor signaling system (JAK2 mutation) [12]. We searched for JAK2 mutation, but mutations of the erythropoietin receptor gene were not tested. We suggest that mutations of the erythropoietin receptor gene should also be considered as a cause of erythrocytosis.

Sheqwarra et al [8] reported occurrence of idiopathic erythrocytosis in a hemodialysis patient. The differences from our patient were as follows. The patient was a 68-year-old man with a history of diabetes mellitus who did not use erythropoietin-stimulating agents or iron supplements. The time to identification of erythrocytosis was shorter (22 months) in their patient than in our patient (55 months). Furthermore, there were no radiologic evidences for hydronephrosis or malignancy. However, the reported patient's erythropoietin level was 49.45 mU/mL (range, 3.7–31.5 mU/mL). We believe that they should have searched for possible causes of elevated erythropoietin level, such as sleep apnea syndrome.

In the present case, the serum erythropoietin level was 31.4 mU/mL. Given the high serum hemoglobin levels, we can interpret that the serum erythropoietin level in our patient was relatively raised; the serum erythropoietin level would otherwise have been near the lower normal limit because of the negative feedback mechanism. However, Artunc and Risler [13] reported that the correlation between hemoglobin and serum erythropoietin concentrations was absent in chronic kidney diseases stages 4 and 5. Based on this finding, we can expect that the serum erythropoietin level in the present case would not be relatively elevated. Therefore, it would be more reasonable to assume that the cause of erythrocytosis in ESRD patients with erythrocytosis and normal erythropoietin levels is not secondary erythrocytosis. Hence, further studies are required to evaluate the relationship between erythrocytosis and erythropoietin levels and the causes for erythrocytosis in ESRD patients.

Conflict of interest

All authors have no conflict of interest to declare.

Acknowledgments

This research was supported by the Basic Science Research Program through the National Research Foundation of Korea

(NRF) and funded by the Ministry of Education, Science, and Technology (2012R1A1A2044121) and the Soonchunhyang University Research Fund,

References

- [1] McMullin MF: The classification and diagnosis of erythrocytosis. *Int Jnl Lab Hem* 30:447–459, 2008
- [2] Longo DL, Adamson JW: Anemia and polycythemia. In: Longo DL, Fauci AS, Kasper D, Hauser S, Jameson JL, Loscalzo J, editors. *Harrison's Principles of Internal Medicine*. 18th edition. New York: McGraw-Hill, 456–457, 2012.
- [3] Jermanovich NB: Polycystic kidney disease and polycythemia vera. Occurrence in a patient receiving hemodialysis. *Arch Intern Med* 143:1822–1823, 1983
- [4] Matsuo M, Koga S, Kanetake H, Ohtani H, Higami Y, Shimokawa I, Watanabe J: EPO-producing gastric carcinoma in a hemodialysis patient. *Am J Kidney Dis* 42:E3–E4, 2003
- [5] Hanada T, Mimata H, Ohno H, Nasu N, Nakagawa M, Nomura Y: Erythropoietin-producing renal cell carcinoma arising from acquired cystic disease of the kidney. *Int J Urol* 5:493–495, 1998
- [6] Adeniyi M, Sun Y, Servilla KS, Hartshorne F, Tzamaloukas AH: Spontaneous erythrocytosis in a patient on chronic hemodialysis. *Hemodial Int* 13:S30–S33, 2009
- [7] Nistico A, Iliescu EA, Fitzpatrick M, White CA: Polycythemia due to obstructive sleep apnea in a patient on hemodialysis. *Hemodial Int* 14:333–336, 2010
- [8] Sheqwarra J, Alkhatib Y, Dabak V, Kuriakose P: Idiopathic erythrocytosis in dialysis patients: a case report and literature review. *Am J Nephrol* 37:333–338, 2013
- [9] Heyman SN, Brezis M, Perlberg S, Metzner Y: Bilateral hydronephrosis and erythrocytosis. *Harefuah* 117:358–360, 1989
- [10] Holley JL: Screening, diagnosis, and treatment of cancer in long-term dialysis patients. *Clin J Am Soc Nephrol* 2:604–610, 2007
- [11] Yanagizawa R, Abe S, Mikata N, Kinoshita K: Case of bladder cancer associated with erythrocytosis: a review of the Japanese literature on tumors associated with erythrocytosis. *Nihon Hinyokika Gakkai Zasshi* 74:1044–1050, 1983
- [12] Gross M, Ben-Califa N, McMullin MF, Percy MJ, Bento C, Cario H, Minkov M, Neumann D: Polycythaemia-inducing mutations in the erythropoietin receptor (EPOR): mechanism and function as elucidated by epidermal growth factor receptor–EPOR chimeras. *Br J Haematol* 165:519–528, 2014
- [13] Artunc F, Risler T: Serum erythropoietin concentrations and responses to anemia in patients with or without chronic kidney disease. *Nephrol Dial Transplant* 22:2900–2908, 2007