

### 1038-147 Treatment of AL Cardiac Amyloidosis With Intravenous High-Dose Melphalan and Stem Cell Transplantation

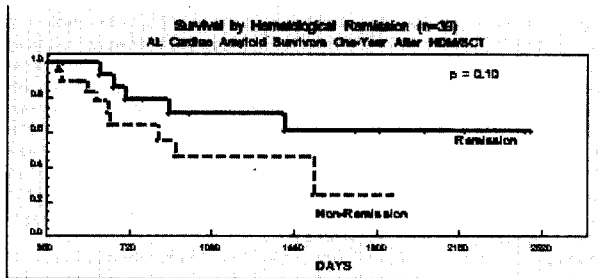
Jina Chung, Vaishali Sanchorawala, Martha Skinner, Rodney H. Falk, Boston Medical Center, Boston, Massachusetts.

**Background:** Primary systemic amyloidosis (AL) with cardiac involvement is rapidly progressive and, if untreated, has a median survival of about six months. Intravenous high-dose melphalan chemotherapy with stem cell transplantation (HDM/SCT) can induce hematological remission (HR) in AL amyloid patients. However, cardiac involvement significantly increases therapy-related morbidity and mortality and the risk-to-benefit ratio is unknown.

**Methods:** 95 patients with biopsy-proven AL amyloidosis and cardiac involvement (age, 55 ± 13 years) were treated with HDM/SCT and compared to 143 similarly treated non-cardiac amyloid patients (age, 57 ± 10 years).

**Results:** One-year survival was 88% in non-cardiac patients and 49% in cardiac patients ( $p < 0.00001$ ). In the cardiac group, those with congestive heart failure (CHF) at baseline (51%) had decreased 1-year survival compared to those without CHF (40% vs. 58%,  $p = 0.07$ ). Among 39 cardiac patients who survived 1 year after therapy, 44% achieved HR. At 2 years, there was a strong trend to improved survival among cardiac patients in HR compared to those not in HR (78% vs. 64%,  $p = 0.10$ ).

**Conclusions:** Cardiac involvement in AL amyloidosis is associated with worse outcome after HDM/SCT, particularly if CHF is present. HR among survivors 1 year after therapy is a marker of better intermediate-term prognosis than persistent hematological disease. However, some patients in HR still die, presumably due to complications of severe pre-existing amyloid heart disease.



### 1038-148 Echocardiographic Features of Constrictive Pericarditis in the Setting of Severe Tricuspid Regurgitation

Richard Y. Bae, Jae K. Oh, Jong-Won Ha, Marion E. Barnes, Lieng H. Ling, A Jamil Tajik, Mayo Clinic, Rochester, Minnesota.

**Background.** Two-dimensional (2D) and Doppler echocardiographic features of constrictive pericarditis (CP) have been well described. Expiratory accentuation ( $\geq 40\%$  compared with inspiration) of hepatic vein (HV) diastolic flow reversal is one important diagnostic feature of CP. However, it is not clear whether this feature is obscured by the presence of severe tricuspid regurgitation (TR), which causes HV systolic flow reversal. The purpose of this study was to characterize the 2D and Doppler echocardiographic features of CP in the presence of severe TR.

**Methods.** From 1985 to 2000, 9 patients (age 66 ± 9, 67% male) with surgically confirmed constrictive pericarditis and severe TR (grade 3 or 4) underwent comprehensive hemodynamic evaluation by echocardiography preoperatively.

**Results.** Three patients (33%) were in atrial fibrillation, the remaining were in sinus rhythm (67%). Left ventricular ejection fraction was 59 ± 10%. 2D findings included characteristic ventricular septal bounce in 8 patients (89%), thickened pericardium in 6 (67%), and dilated inferior vena cava in all patients. Estimated pulmonary artery systolic pressure was 42 ± 10 mm Hg. Analysis of mitral inflow Doppler patterns demonstrated respiratory variation of mitral E wave velocity  $\geq 25\%$  in 5 of 9 patients (56%) and shortened deceleration times of 141 ± 43 ms and 164 ± 41 ms (inspiration and expiration, respectively). HV Doppler analysis revealed HV systolic flow reversal in 8 patients (89%) and HV diastolic forward flow decrease during expiration in all patients (100% with a mean decrease of 35%). Prominent HV diastolic flow reversal accentuation with expiration was only seen in 2 (22%) patients.

**Conclusion.** In patients with CP and severe TR: 1) typical 2D features of CP are present in most patients; 2) mitral inflow velocity patterns are similar to those observed in CP patients without severe TR; and 3) diagnostic expiratory increase of HV diastolic flow reversal is usually not present.

### 1038-149 Electrocardiographic Findings in Patients With Arrhythmogenic Right Ventricular Cardiomyopathy and Idiopathic Ventricular Tachycardia: Potential Role for Risk Stratification?

Matthias Paul, Hans-Juergen Bruns, Guenter Breithardt, Thomas Wichter, University of Muenster, Department of Cardiology, Muenster, Germany.

**Background:** Both patients (pts) with arrhythmogenic right ventricular cardiomyopathy (ARVC) and idiopathic ventricular tachycardia or fibrillation (IVT) clinically present with ventricular tachyarrhythmias, syncope, or cardiac arrest. We assessed the diagnostic value of different ECG parameters for the electrocardiographic distinction between ARVC and IVT and their potential role for risk stratification.

**Methods:** 12-lead surface ECG of 76 pts with ARVC (mean age 39.5 ± 15.4 yrs) and 44 pts with IVT (mean age 39.2 ± 14.3 yrs) were analysed for the maximal duration of the QRS-complex (QRSmax), QRS dispersion (QRSdisp), sum of QRS durations in leads V<sub>1-3</sub> (QRS-V<sub>1-3</sub>) and the ratio of QRS durations in right (QRS-V<sub>1-3</sub>) and left (QRS-V<sub>4-6</sub>)

precordial leads (QRS-V<sub>1-3</sub> / V<sub>4-6</sub>). These parameters were compared to the clinical events sudden death (7 pts; 5.8%), resuscitated cardiac arrest (21 pts; 17.5%) and inducibility of sustained ventricular tachycardia during electrophysiological study (65 pts; 71.4%).

**Results:** QRS-V<sub>1-3</sub> was the strongest predictor of ventricular tachycardia inducibility (specificity 65%, sensitivity 75%,  $p < 0.004$ ). The ratio of summed QRS durations QRS-V<sub>1-3</sub> / V<sub>4-6</sub> also showed a significant correlation with inducibility for both ARVC ( $p < 0.003$ ) and IVT pts ( $p < 0.022$ ). In ARVC pts with a history of sudden death/cardiac arrest ( $n = 20$ ), QRSmax was longer when compared to pts without such an event (121.3 ± 12.6 ms vs. 115.4 ± 18.1 ms;  $p < 0.05$ ). In contrast to resuscitated patients with idiopathic ventricular fibrillation ( $n = 6$ ), QRS-V<sub>1-3</sub> showed a trend towards a longer duration in ARVC pts but did only reach borderline significance (329.4 ± 42.4 ms vs. 290.0 ± 46.6 ms;  $p < 0.059$ ).

**Conclusions:** In pts with ARVC, the 12-lead ECG parameter QRSmax appears to be correlated with an increased risk of sudden death or cardiac arrest. Our data indicate the potential role of QRS-V<sub>1-3</sub> analysis as a quickly available tool to predict the inducibility of ventricular tachyarrhythmias during electrophysiological study in pts with ARVC and IVT. Further investigations are required to identify threshold levels, which was not possible in the present study due to the limited number of pts.

### 1038-150 A Novel Lamin A/C Missense Mutation in a Family With Autosomal Dominant Dilated Cardiomyopathy With Conduction Abnormalities

Ryuichiro Anan, Hideshi Niimura, Takeshi Sasaki, J. G. Seidman, Christine E. Seidman, Shinichi Minagoe, Chuwa Tei, Kagoshima University, Kagoshima, Japan, Harvard Medical School, Boston, Massachusetts.

**Background:** Dilated cardiomyopathy is a form of heart muscle disease characterized by impaired systolic function and ventricular dilatation. Familial inheritance is observed in approximately 30% of cases with dilated cardiomyopathy. Recent studies have shown that mutations in the lamin A/C gene could cause four different autosomal dominant inherited disorders: familial dilated cardiomyopathy with preceding conduction system diseases, Emery-Dreifuss muscular dystrophy, limb-girdle muscular dystrophy type 1B, and familial partial lipodystrophy. Mutations that encode the helical rod 1 domain or the globular tail region of lamin A/C protein cause familial dilated cardiomyopathy. **Methods:** We studied six families with autosomal dominant dilated cardiomyopathy. Four families were associated with conduction abnormalities. Direct sequence analyses for coding regions of lamin A/C gene were performed in the probands of the six families. **Results:** A novel lamin A/C gene mutation was found in a proband with familial dilated cardiomyopathy associated with conduction abnormalities. The mutation is a missense mutation, which changes arginine to tryptophan at codon 190 (Arg190Trp) in exon 3 in the lamin A/C gene. This change encodes the amino acid located in the helical rod 1 portion of lamin A/C protein. Electrocardiogram of the proband showed first degree atrio-ventricular block and complete right bundle branch block. Echocardiogram of the proband showed diffuse hypokinetic motion of the left ventricle. The left ventricular diastolic dimension was 64 mm, and the fractional shortening was 0.09. The proband died of congestive heart failure at age of 48. In this family, dilated cardiomyopathy was diagnosed in six individuals. Five affected individuals died of congestive heart failure. The mean age of deaths was 50 ± 3 years. These results predict an incidence of lamin A/C mutation in approximately one fourth of individuals with dilated cardiomyopathy associated with conduction system disease. **Conclusion:** A novel missense mutation (Arg190Trp) in the lamin A/C gene was detected in a family with dilated cardiomyopathy associated with conduction abnormalities.

### 1038-151 Reorganization of the Cardiac Gap Junctions in Adriamycin-Induced Cardiomyopathy

Gabriele Plenz, Volker Arps, Eschert Heike, Stefan Christiansen, Joerg Stypmann, Ulrich Jahn, Mario C. Deng, Hans H. Scheld, Dieter Hammel, Hospital of Muenster University, Muenster, Germany, Institute for Arteriosclerosis Research, Muenster, Germany.

**Background:** Gap junctions mediate the propagation of the electrical impulse between cardiac myocytes. The connexins (Cx) constituting the cardiac gap junctions are Cx43, Cx40 and Cx45. In normal human hearts Cx43 is homogeneously distributed in all chambers, while Cx40 is more abundant in atria. In advanced heart failure alterations of the Cx patterns are found. We hypothesized that adriamycin-induced cardiomyopathy is accompanied by a reorganization of the Cx patterns analogous to that reported for dilated cardiomyopathy.

**Methods:** In FBI dogs (30-35 kg) the development of a cardiomyopathy was induced using repetitive intracoronary administration of adriamycin (10 mg/50 ml saline over 1 h per week) through a silicone-catheter insertion. Transmural left ventricular biopsies were taken after catheter insertion (control) and 4 weeks after adriamycin administration. mRNA was analyzed by RT-PCR for Cx43, Cx40 and Cx45.

**Results:** In normal canine hearts only Cx43 was detected. Adriamycin administration led changes in LVEDD and FS. Moderate changes (hypertrophy = HY; LVEDD: 0.21 ± 0.21 over control; FS: 70.65 ± 3.7% of control) were associated with increased Cx43 levels (2.46fold) and an induction of Cx40. With further deterioration of cardiac function (cardiomyopathy = CM; LVEDD: 0.67 ± 0.05 over control; FS: 46.45 ± 3.61% of control) Cx patterns changed again. Cx43 levels decreased (8.2fold), Cx40 levels remained elevated and Cx45 was induced.

**Conclusions:** The present study suggests that repetitive intracoronary adriamycin administration resulted in a stepwise deterioration of cardiac function. Concomitantly the connexin patterns changed. First patterns were found as reported for HY in small animal and humans and consecutively patterns as described for dilated CM in humans. The present data indicate that adriamycin administration induces dilated CM in dogs and therefore is a suitable model to study the effects on the propagation of the electrical impulse after surgical treatment strategies of DCM such as partial left ventriculectomy. (Deutsche Stiftung für Herzforschung, Frankfurt)