

Available online at www.sciencedirect.com

SciVerse ScienceDirect

journal homepage: www.elsevier.com/locate/ihj

Case report

Erosion/malapposition of a sirolimus eluting stent – Optical coherence tomography image – A case report

G. Sengottuvelu

Senior Consultant & Interventional Cardiologist, Department of Cardiology, Apollo Hospitals, Greams Lane, Chennai 600 006, India

ARTICLE INFO

Article history:

Received 29 July 2012

Accepted 26 November 2012

Available online 27 November 2012

Keywords:

Stent malapposition

OCT

Sirolimus eluting stent

ABSTRACT

The presence of erosion/malapposition of a Sirolimus eluting stent was clearly visualized using Optical Coherence Tomography (OCT) imaging. The presence of erosion/malapposition and the absence of neointimal hyperplasia after 10 months of sirolimus eluting stent could constitute a potential thrombogenic substrate for late stent thrombosis.

Copyright © 2012, Cardiological Society of India. All rights reserved.

1. Introduction

A 65 years old male, known hypertensive presented with typical angina of one day duration. He had history of PTCA and stenting to left circumflex artery with Cypher (Cordis, J&J) stent 6 years ago and history of PTCA and stenting to proximal left anterior descending artery with Cypher select plus stent (Cordis, J&J) 10 months ago. He was on regular doses of both aspirin and clopidogrel. His ECG and echocardiogram were normal. Cardiac enzymes were within normal limits. In view of the typical angina and previous history of PCI, he was taken up for coronary angiogram. Coronary angiogram showed patent Cypher stents in the proximal LAD and the OM.

Since patient had typical angina, and to study the stented segments further it was decided to perform FFR and OCT.

Using standard protocol through the right radial approach 6F XB guiding catheter and intracoronary nitrates, 0.014 inch St. Jude prime FFR wire was parked in the distal LAD. Maximal hyperemia was achieved using intravenous adenosine

(140 mcg/kg/h). FFR measured at maximal hyperemia was 0.93 (Fig. 1A, B).

St. Jude 6F C7 Dragon fly OCT catheter was introduced into LAD and OCT images were captured using standard protocol (Fig. 1C).

Cross-sectional OCT images were analyzed at every 1 mm. OCT images showed well demarcated areas of erosion/malapposition in several areas of LAD stent. These are areas of unhealed erosions or acquired malapposition which can predispose to late stent thrombosis. These may be the consequence of chronic inflammation and delayed healing, resulting in tissue necrosis and erosion around the stent. Even the struts which were well apposed did not develop neointimal hyperplasia even after 10 months.

Then using the standard protocol and same 0.014 inch St. Jude prime FFR wire was parked in the distal OM. Maximal hyperemia was achieved using intravenous adenosine (140 mcg/kg/h). FFR measured at maximal hyperemia was 0.90 in the OM (Fig. 2A, B).

E-mail address: drsgeng@gmail.com.

0019-4832/\$ – see front matter Copyright © 2012, Cardiological Society of India. All rights reserved.

<http://dx.doi.org/10.1016/j.ihj.2012.11.008>

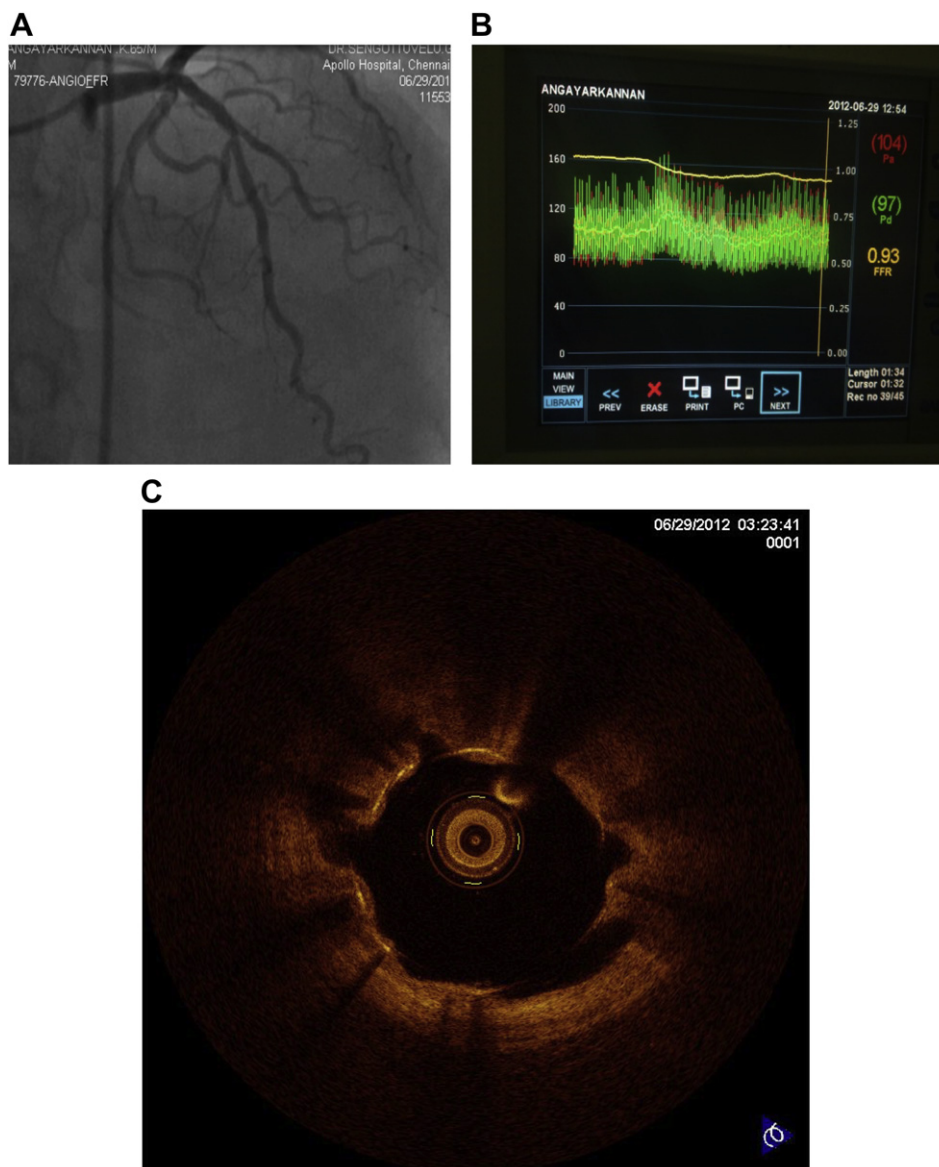


Fig. 1 – A–C – Angiogram, FFR and OCT images of LAD.

St. Jude 6F C7 Dragon fly OCT catheter was introduced into OM and OCT images were captured using standard protocol (Fig. 2C). The OM stent was well opposed and was completely endothelialised with well covered struts.

In contrast to LAD stent, there were no erosions or malapposition in the OM stent. In view of the OCT findings of LAD stent erosion/malapposition, his antiplatelet regimen was changed to aspirin and prasugrel.

2. Discussion

Recent IVUS studies have suggested that stent malapposition plays an important role in patients who develop very late stent thrombosis after drug-eluting stent implantation. Two mechanisms for late acquired stent malapposition (LASM) were described: decrease of the plaque volume behind the

stent (including clot lysis or plaque regression) and positive remodeling of the vessel wall.¹

Cardiovascular optical coherence tomography (OCT) is a catheter-based invasive imaging system. Using light rather than ultrasound, OCT produces high-resolution in vivo images of coronary arteries and deployed stents. This imaging modality may be useful not only in detecting different types of intravascular pathology such as type of the plaque (lipid-rich, fibrous, and calcific plaque) but also in visualizing detailed structural changes such as ulcerated plaques, intraluminal thrombus, tissue prolapse, stent apposition and intimal hyperplasia in cases of in-stent restenosis.²⁻⁶

Following stent implantation, the stent is covered by regrowth of intima, this covering of intima is difficult to assess with IVUS as thickness of the intimal covering following DES is less than 100 microns. OCT can assess this neointimal covering of stent due to its high resolution capability.

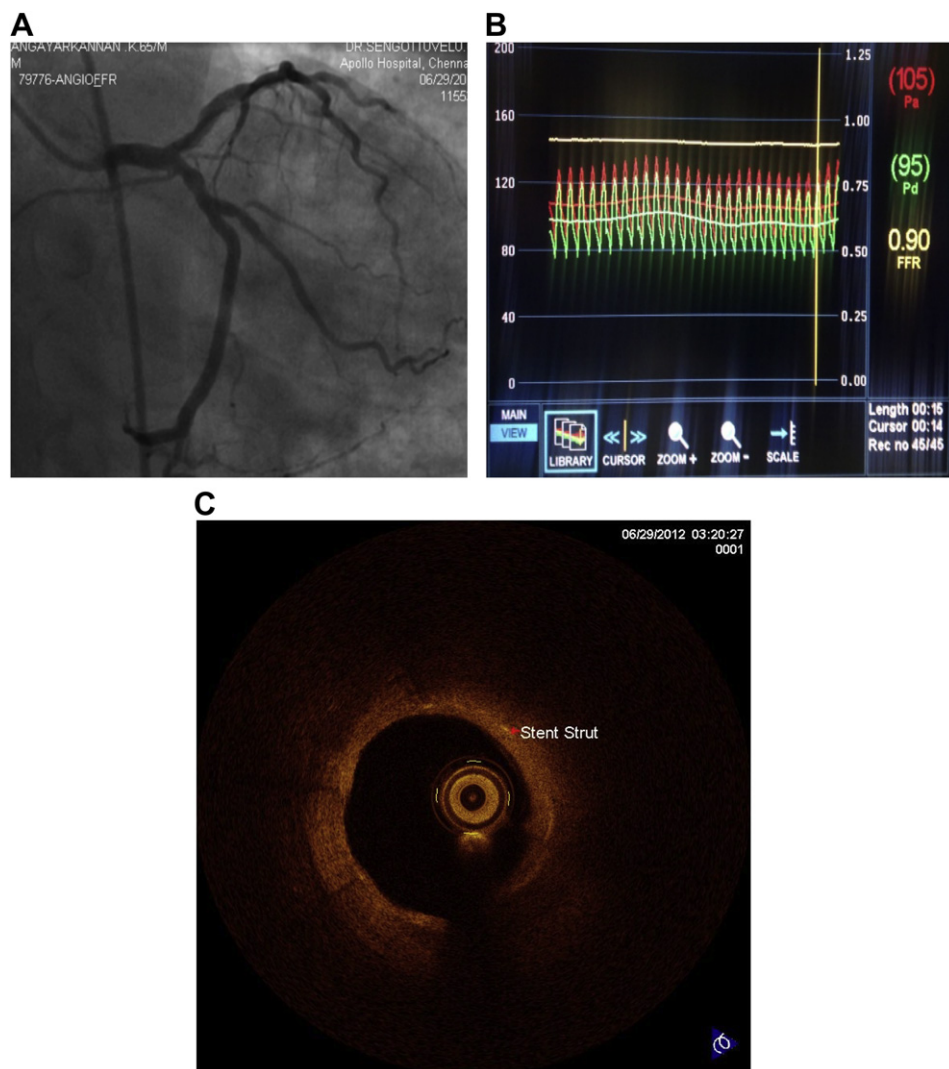


Fig. 2 – A–C – Angiogram, FFR and OCT images of OM.

Matsumoto et al following SES implantation at 6 months found using OCT, median neointimal thickness of 53 microns and average rate of neointimal struts covered was 89%.⁷ Yamamoto et al with use of OCT for SES at 2 year follow-up found neointima of 71 microns, 5% of the struts were uncovered and 10% of bifurcation lesions were uncovered.⁸

The mechanism by which late stent malapposition contribute to stent thrombosis may be that it serves as a local nidus for thrombus formation by allowing fibrin and platelet deposition. Delayed re-endothelialization, impaired vasomotion, and chronic inflammation may also contribute to stent thrombosis by allowing platelet adhesion, initiation of the coagulation cascade, and subsequent thrombotic stent occlusion.¹

The Limus group prototype is Rapamycin (sirolimus), a macrolide with cytostatic properties that blocks progression from G1 to S in the cell cycle and inhibits thus the vascular smooth muscle cell migration and proliferation.¹ In patients with sirolimus eluting stents, incomplete stent apposition can fail to heal and even complete apposition can be associated with no neointimal hyperplasia. Incomplete stent apposition

without neointimal hyperplasia was significantly associated with the presence of OCT-detected thrombus at follow-up, and may constitute a potent substrate for late stent thrombosis.⁹ OCT may be used as guide for assessing duration of dual antiplatelet therapy following DES implantation.

3. Conclusion

The presence of erosion/malapposition and the absence of neointimal hyperplasia after 10 months of sirolimus eluting stent could constitute a potent thrombogenic substrate for late stent thrombosis. The presence of erosion/malapposition of LAD was clearly visualized using OCT-imaging and led to changing the antiplatelet regimen in this patient.

Conflicts of interest

The author has none to declare.

REFERENCES

1. Hassan Ayman KM, et al. Late stent malapposition risk is higher after drug-eluting stent compared with bare-metal stent implantation and associates with late stent thrombosis. *Eur Heart J*. 2010;31:1172–1180.
2. Diaz-Sandoval Larry J, Bouma Brett E, Tearney Guillermo J, Jang Ik-Kyung. Optical coherence tomography as a tool for percutaneous coronary interventions. *Catheter Cardiovasc Interv*. 2005;65:492–496.
3. Bezerra Hiram G, et al. Intracoronary optical coherence tomography: a comprehensive review. *J Am Coll Cardiol Intv*. 2009;2:1035–1046.
4. Prati, Regar, Mintz, et al. Expert review document on methodology, terminology, clinical applications of OCT: physical principals, methodology of image acquisition, and clinical application for assessment of coronary arteries and atherosclerosis. *Eur Heart J*. 2010 Feb;31(4):401–415. Epub 2009 Nov.
5. Barlis, Schmitt, et al. Current and future developments in intracoronary OCT imaging. *EuroIntervention*. 2009 Jan: 529–533.
6. Waksman Ron, Weinberger Judah. *Coronary Brachytherapy in the Drug-eluting Stent Era, Don't Bury It Alive*. Published by the American Heart Association; 2003;108:386–388.
7. Matsumoto Daisuke, et al. Neointimal coverage of sirolimus-eluting stents at 6-month follow-up: evaluated by optical coherence tomography. *Eur Heart J*. 2007;28:961–967.
8. Takano Masamichi, et al. Long-term follow-up evaluation after sirolimus-eluting stent implantation by optical coherence tomography – do uncovered struts persist? *J Am Coll Cardiol*. 2008;51(9):968–969.
9. Ozaki Yukio, et al. The fate of incomplete stent apposition with drug-eluting stents: an optical coherence tomography-based natural history study. *Eur Heart J Adv Access*; April 2, 2010.