



Endovascular retrieval of an irrigation cannula from the thoracic aorta following cardiac surgery: A case report



Biju K. Thomas, James R. Elmore*, Robert P. Garvin, Evan J. Ryer

Department of Vascular and Endovascular Surgery, Geisinger Medical Center, Danville, PA, United States

ARTICLE INFO

Article history:

Received 18 June 2015
Received in revised form
29 September 2015
Accepted 29 September 2015
Available online 22 October 2015

Keywords:

Endovascular retrieval of foreign body
Irrigation cannula
Complications following cardiac surgery

ABSTRACT

INTRODUCTION: Endovascular techniques to retrieve intravascular foreign bodies are a necessary component of the Vascular surgeon's skill set. We report the successful retrieval of an embolized irrigation cannula from the thoracic aorta following aortic valve replacement.

PRESENTATION OF CASE: The patient is an 81 year old male who underwent coronary artery bypass grafting and aortic valve replacement. Prior to closure, the aortotomy was irrigated with heparinized saline using a syringe with an olive tip irrigation cannula. When the syringe was handed back to the nursing staff, the tip was noted to be missing but could not be found. Prior to closure of the sternum, the field was searched again for the tip and thus the chest was closed. The missing instrument then prompted an intraoperative chest radiograph that demonstrated a metal irrigation cannula superimposed on the cardiac silhouette. Additionally, a transesophageal echocardiogram was performed, which demonstrated the irrigation cannula within the descending thoracic aorta. Right common femoral artery was accessed and a thoracic aortogram was performed demonstrating the cannula to be lodged in the descending thoracic aorta. Intravascular ultrasound (IVUS) was performed to exclude an aortic abnormality preventing the caudad migration of the cannula. No aortic pathology was identified. A tri-lobed snare was used to grasp the cannula at its tip and withdrawn into the right external iliac artery. The cannula was successfully removed through a transverse arteriotomy in the distal right external iliac artery. The patient's postoperative course was uneventful.

CONCLUSION: Endovascular retrieval of intravascular foreign bodies is minimally invasive, relatively simple, and carries minimal morbidity compared to conventional open surgical techniques. This unusual case demonstrates the importance of a working knowledge of techniques and instruments requisite for retrieval of intravascular foreign bodies

© 2015 The Authors. Published by Elsevier Ltd. on behalf of IJS Publishing Group Ltd. This is an open access article under the CC BY-NC-ND license (<http://creativecommons.org/licenses/by-nc-nd/4.0/>).

1. Introduction

The discovery of intra-vascular foreign bodies is increasing and their associated danger is well recognized [1]. Endovascular retrieval of intravascular foreign bodies offers a high success rate with minimal morbidity and mortality [2]. A variety of tools are available to the interventionist to aid in foreign body extraction; however, a thorough knowledge of available devices and techniques is necessary to minimize the associated complications of endovascular retrieval. We describe the endovascular retrieval of an unusual intravascular foreign body, an irrigation cannula, from the thoracic aorta following cardiac surgery.

2. Presentation of case

An 81 year old male underwent coronary artery bypass grafting and aortic valve replacement. During the procedure, the ascending aorta had been irrigated several times with heparinized saline using a syringe capped with a stainless-steel olive tip irrigation cannula. When the syringe was handed back to the nursing staff, the tip was noted to be missing but could not be found. Prior to closure of the sternum, the pericardium and the surgical field were searched again for the irrigating tip and thus the chest was closed. The missing instrument prompted a chest radiograph that demonstrated a metal irrigation cannula superimposed on the cardiac silhouette (Fig. 1). An intraoperative trans-esophageal echocardiogram (TEE) was then done which showed the irrigation cannula within the descending thoracic aorta.

Vascular Surgery was consulted emergently for intravascular foreign body retrieval. Right common femoral artery access was obtained and a thoracic aortogram was performed demonstrating the cannula to be lodged in the descending thoracic aorta (Fig. 2).

* Corresponding author.

E-mail address: jelmore@geisinger.edu (J.R. Elmore).

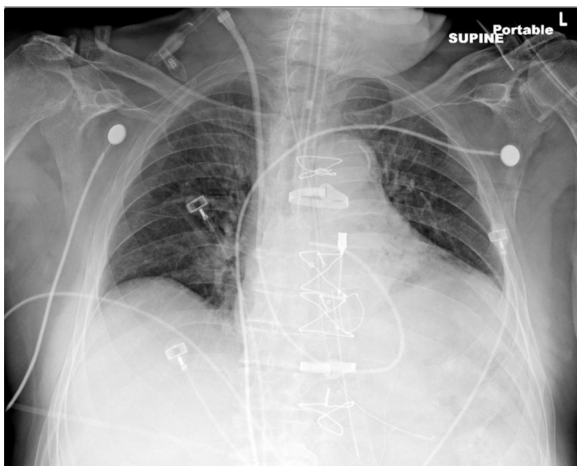


Fig. 1. Olive tip cannula noted on the left of the sternum (permission obtained from patient).

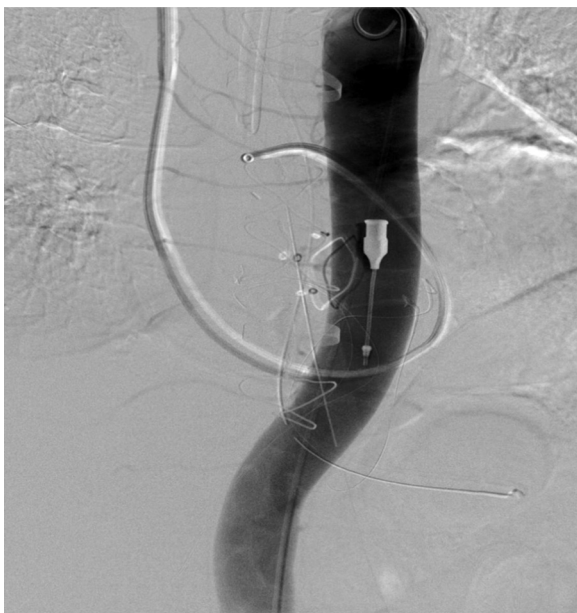

Fig. 2. Cannula noted in the distal thoracic aorta.

Due to the fixed position of the cannula, we felt it was imperative to rule out an unidentified aortic abnormality at this location. Our initial arterial access was upsized from a 5-French sheath to a 9-French sheath. An 8-French intravascular ultrasound (IVUS) catheter (Volcano Corporation, San Diego, CA) was then used to evaluate the descending thoracic aorta. No aortic abnormality was identified that may have prevented the caudal migration of the cannula. We surmised, then, that the cannula was lodged obliquely between the anterior and posterior aortic walls.

A tri-lobed snare, EN Snare® (Merit Medical Systems, South Jordan, UT) was used to grasp the cannula at its tip and withdraw it into the distal aorta. At the aortic bifurcation, the cannula rotated 180 degrees. This rotation led to the cannula becoming temporarily lodged on the aortic bifurcation. In order to dislodge the cannula and allow retraction into the right iliac system, we advanced and rotated the snare. These maneuvers allowed further rotation of the cannula and successful withdrawal into the right iliac system. Due to its large size, the irrigating cannula could not be retrieved further than the distal external iliac artery (Fig. 3). The olive tip measures 45 mm in length and 5.5 mm in width. The cannula was successfully

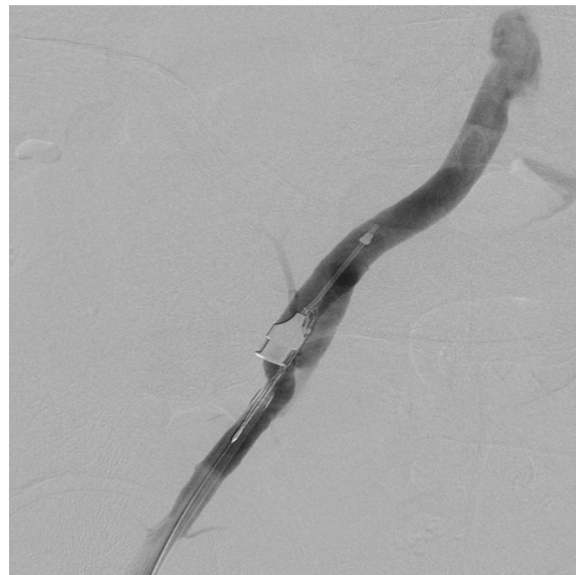

Fig. 3. Cannula noted in right external iliac artery.

removed through a transverse arteriotomy in the distal right external iliac artery. The patient's postoperative course was uneventful. He was discharged to a skilled nursing facility and had no adverse vascular complications noted on post-operative follow up.

3. Discussion

As the use of endovascular techniques and procedures have risen, so have the reports of intravascular foreign bodies [3]. Our report highlights an endovascular approach to retrieve an unusual aortic foreign body lost after open cardiac surgery. Following our review of the literature, we believe this to be the only such case of an intra-aortic irrigation cannula successfully retrieved by an endovascular means.

Similar to our case, Basoor et al. described the endovascular retrieval of a migrated patent foramen ovale occluder from the descending thoracic aorta [4]. This case, while similar in some respect, differs from ours as the authors found it was necessary to use both a 5.5-French multipurpose biopsy forcep (Cordis Corporation, a Johnson & Johnson company; Bridgewater, NJ) as well as an Amplatz GooseNeck™ snare (ev3 Peripheral Vascular, part of Covidien; Plymouth, Minn) to remove a large intra-aortic foreign body. We believe that our case, along with the report from Basoor et al., highlights that an endovascular snare is the preferred tool for intra-aortic foreign body extraction. This is also emphasized by the reports of others that have shown the snare to be useful in the retrieval of other, more common, foreign bodies such as fractured port catheters, introducer fragments, microcoils, dislocated stents, fragments of guidewires, pacemaker transducers, and vena cava filters [5–9].

Prior to these reports, the majority of the literature focused on the open surgical extraction of pedicle spinal fixation screws from the thoracic aorta [10]. One unique case involved endovascular stent graft exclusion followed by extraction via a left anterolateral fourth intercostal space thoracotomy [11]. While interesting as it allowed extraction without aortic cross clamping, this approach still subjected the patient to the morbidity associated with a thoracotomy. In our case, open extraction would have required a thoraco-abdominal incision to access the descending thoracic aorta and removal of the irrigation cannula. This would not only increase the potential morbidity of the case but also add substantial health care costs.

Lastly, we feel it important to mention that after the case, we discovered that a 22-French sheath would have been able to accommodate the irrigation cannula. In retrospect, a double-ProGlide (Abbott Vascular, Abbott Park, Illinois) preclose technique followed by insertion of a long 22-French sheath insertion may have allowed successful extraction of the cannula percutaneously, thus avoiding a groin incision.

4. Conclusion

Endovascular retrieval of intravascular foreign bodies is minimally invasive, relatively simple, and carries minimal morbidity compared to conventional open surgical techniques. This unusual case of a thoracic aortic foreign body demonstrates the importance of a working knowledge of endovascular techniques and instruments necessary for safe and effective extraction of atypical intravascular foreign bodies.

Please note this case report follows the CARE guidelines [12].

Conflict of interest

No conflict of interest.

Funding

None.

Ethical approval

This case report was approved by the IRB.

Author contribution

Biju K. Thomas: Study concept, data collection, data interpretation, writing paper.

James R. Elmore: Study concept, data collection, data interpretation, writing paper.

Robert P. Garvin: Study concept, data collection, data interpretation, writing paper.

Evan J. Ryer: Study concept, data collection, data interpretation, writing paper.

Consent

Consent was obtained from patient.

Guarantor

Dr. James R. Elmore MD.

References

- [1] U.S. Federal drug administration [Internet]. Silver Spring: FDA Public Health Notification: Unretrieved Device Fragments. Updated December 2, 2010 <http://www.fda.gov/MedicalDevices/Safety/AlertsandNotices/PublicHealthNotifications/ucm062015.htm> (accessed 12.08.11).
- [2] Megan I. Carroll, Sadaf S. Ahanchi, Jung H. Kim, Jean M. Panneton, Endovascular foreign body retrieval, *J. Vasc. Surg.* 57 (2) (2013) 459–463.
- [3] M.A. Schechter, P.J. O'Brien, M.W. Cox, Retrieval of iatrogenic intravascular foreign bodies, *J. Vasc. Surg.* 57 (January (1)) (2013) 276–281.
- [4] A.S. Basoor, J.F. Cotant, A.R. Halabi, M. DeGregorio, H. Chughtai, K.C. Patel, Minimally invasive retrieval of patent foramen ovale closure device after device migration to the descending aorta, *J. Vasc. Surg.* 57 (January (1)) (2013) 276–281.
- [5] K. Koseoglu, M. Parildar, I. Oran, A. Memis, Retrieval of intravascular foreign bodies with goose neck snare, *Eur. J. Radiol.* 49 (3) (2004) 281–285 [PubMed].
- [6] J.C. Liu, H.S. Tseng, C.Y. Chen, M.S. Chern, S.C. Ko, J.H. Chiang, C.Y. Chang, Percutaneous retrieval of intravascular foreign bodies: experience with 19 cases, *Kaohsiung J. Med. Sci.* 18 (10) (2002) 492–499 [PubMed].
- [7] A. Gabelmann, S. Kramer, J. Gorich, Percutaneous retrieval of lost or misplaced intravascular objects, *AJR Am. J. Roentgenol.* 176 (6) (2001) 1509–1513 [PubMed].
- [8] J.H. Jang, S.I. Woo, D.H. Yang, S.D. Park, D.H. Kim, S.H. Shin, Successful coronary stent retrieval from the ascending aorta using a gooseneck snare kit, *Korean J. Intern. Med.* 28 (July (4)) (2013) 481–485, <http://dx.doi.org/10.3904/kjim.2013.28.4.481>.
- [9] Wolf L. Guerrieri Wolf, R. Scaffa, D. Maselli, L. Weltert, S. Nardella, M. Di Roma, R. De Paulis, F. Tomai, Intraaortic migration of an epicardial pacing wire: percutaneous extraction, *Ann. Thorac. Surg.* 96 (July (1)) (2013) e7–e8, <http://dx.doi.org/10.1016/j.athoracsur.2012.12.056>.
- [10] H.K. Sandhu, K.M. Charlton-Ouw, A. Aizzadeh, A.L. Estrera, H.J. Safi, Spinal screw penetration of the aorta, *J. Vasc. Surg.* 57 (June (6)) (2013) 1668–1670.
- [11] B.D. Colvard, J.E. Anaya-Ayala, C.J. Smolock, A.B. Lumsden, M.J. Reardon, M.G. Davies, Hybrid approach for removal of an errant intra-vascular pedicle spinal fixation screw in the thoracic aorta, *J. Vasc. Surg.* 56 (July (1)) (2012) 201–204.
- [12] J. Gagnier, G. Kienle, D.G. Altman, D. Moher, H. Sox, D.S. Riley, the CARE group, The CARE guidelines: consensus-based clinical case report guideline development, *J. Clin. Epidemiol.* 67 (1) (2015) 46–51.

Open Access

This article is published Open Access at sciedirect.com. It is distributed under the [IJSCR Supplemental terms and conditions](#), which permits unrestricted non commercial use, distribution, and reproduction in any medium, provided the original authors and source are credited.