

Contents lists available at [ScienceDirect](http://www.elsevier.com/locate/TJEM)

Turkish Journal of Emergency Medicine

journal homepage: <http://www.elsevier.com/locate/TJEM>

Case report

A rare cause of emergency department visit: *Euphorbia helioscopia* contact dermatitisIbrahim Hakan Bucak ^{a,*}, Habip Almıs ^a, Birgul Tepe ^b, Mehmet Turgut ^a^a Department of Pediatrics, Adiyaman University, Adiyaman, Turkey^b Department of Dermatology, Adiyaman University, Adiyaman, Turkey

ARTICLE INFO

Article history:

Received 15 August 2015

Received in revised form

15 October 2015

Accepted 6 November 2015

Available online 13 October 2016

Keywords:

Contact dermatitis

Emergency departments

Euphorbia

Clinic visit

Water

ABSTRACT

Emergency department visits due to dermatologic disease is quite rare. *Euphorbia helioscopia* is a widely distributed plant in rural areas. *E. helioscopia* related contact dermatitis (Irritant contact dermatitis or allergic contact dermatitis) are known however only a few case reported in literature. We are reporting on three patients with contact dermatitis from *E. helioscopia*. Irritant contact dermatitis was occurred only one of these cases. This case refused to wash face with water. We recommend washing the face with water after contact with *E. helioscopia*.

Copyright © 2016 The Emergency Medicine Association of Turkey. Production and hosting by Elsevier B.V. on behalf of the Owner. This is an open access article under the CC BY-NC-ND license (<http://creativecommons.org/licenses/by-nc-nd/4.0/>).

1. Introduction

Emergency department (ED) visits due to dermatologic disease is quite rare and prevalence is about 3%.¹ Skin and subcutaneous infection are the most common diagnosis of dermatologic diseases in ED.² Contact dermatitis caused by plants and plant products is a frequently encountered condition in daily life. This contact leads to a reaction on the skin called irritant contact dermatitis (ICD) and allergic contact dermatitis (ACD).³ Only a few case reports have been reported with contact dermatitis by *Euphorbia helioscopia* (EH) in the literature.^{4,5} In this case report we want to share our experience with EH contact dermatitis in ED.

2. Case presentations

Three relative four-year-old girls were admitted to our emergency department with facial redness and bullae. The girls had played with EH in a rural area (Fig. 1A). It was determined that they plucked the plant's leaf and they drew cream out of the leaf. Two of

the girls washed their faces with tap water immediately after contact with the sap. There was facial redness in only these two cases (Figs. 1B and 2C). The third girl refused to wash immediately, but she washed her face after fifteen minutes from contact. Large bullous lesions were observed on her left cheek extending to the left chin (Fig. 2D). Laboratory results were in the normal range. No systemic or topical treatment was implemented. All lesions healed without a trace in ten days.

3. Discussion

E. helioscopia is a widely distributed plant in rural areas. Some articles report that it is used in traditional treatments.⁶ The structure of 12-Deoxyphorbol-13-phenylacetal-20-acetate is responsible for chemical irritation.^{4,7} Contact dermatitis caused by EH has not been reported as the reason for admission to ED. There is no information about what needs to be done in contact with EH. A remarkable point in this case report is that ICD developed in only one patient because she refused to wash her face with water. Washing the affected area with water is necessary after initial contact with EH. Cleaning the affected skin and using protective products are recommended for ICD and ACD treatment.⁸ Low-potency topical corticosteroids, oral antihistamines, and systemic steroids may be required in severe cases.^{8,9} All lesions regressed without topical and systemic treatments in these three cases.

* Corresponding author. Altınşehir Mah 30143 Sk. Ayg Sitesi A-blok No: 9, Adiyaman, Turkey.

E-mail address: ihbucak@hotmail.com (I.H. Bucak).

Peer review under responsibility of The Emergency Medicine Association of Turkey.

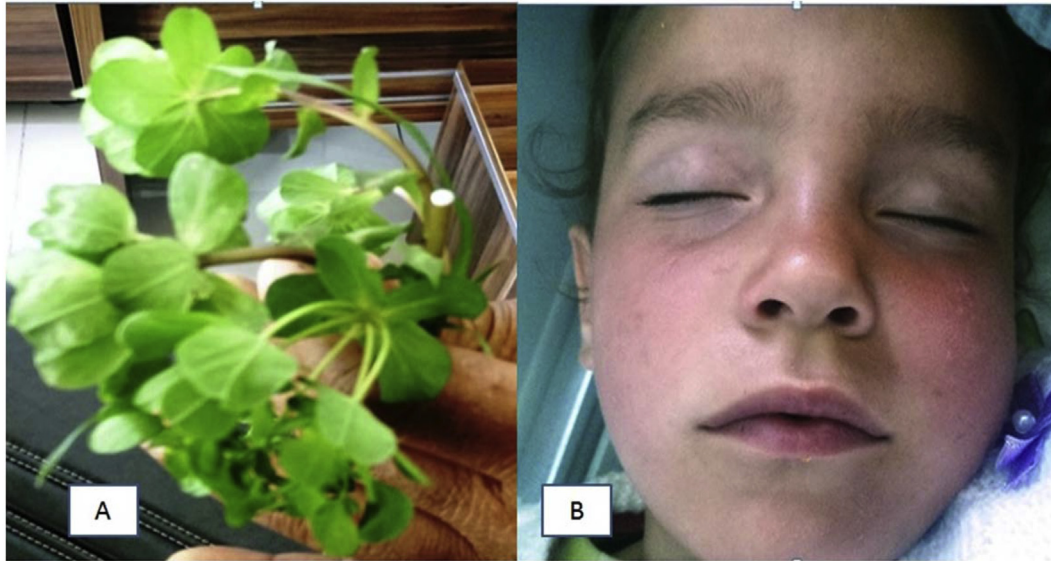


Fig. 1. A: *Euphorbia helioscopia* plant. B: The facial redness of patient.

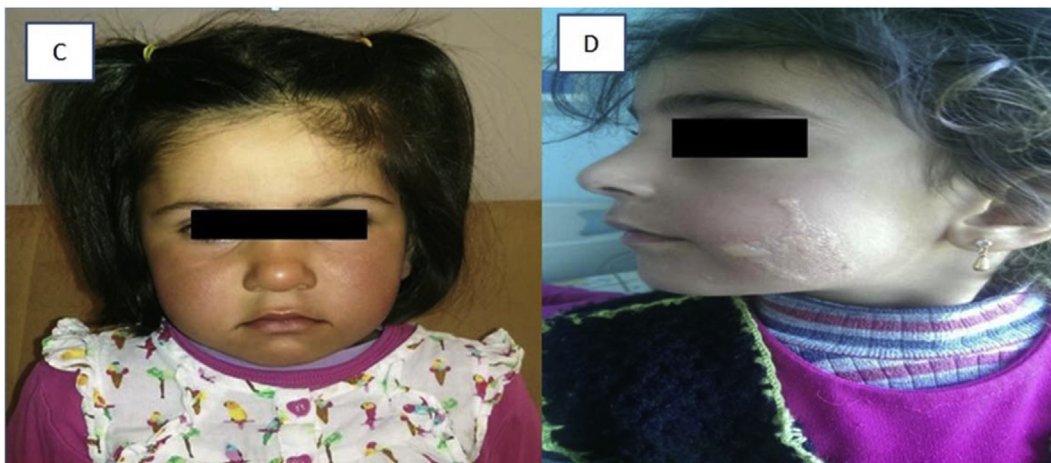

Fig. 2. C: The facial redness of patient. D: Large bullous lesions on left cheek extending to the left chin.

More information should be given to people to protect themselves from EH in rural areas. If there is short time passed to contact with EH before admission to the ED, contact surface can be washed with water. There is no need any drugs for treatment of EH contact dermatitis. Further studies are needed for the first intervention of EH contact dermatitis treatment.

Conflicts of interest

The author declares no conflict of interest.

References

[1]. Peart JM, Sharma P, Kovarik CL, et al. Prevalence of dermatologic disease in an urban emergency department: a cross-sectional study. *J Am Acad Dermatol.*

- 2015;72(5):920–921.
- [2]. Baibergenova A, Shear NH. Skin conditions that bring patients to emergency departments. *Arch Dermatol.* 2011;147(1):118–120.
- [3]. Hannuksela M. Skin contact reactions caused by plants. *Duodecim.* 2009;125:1398–1406.
- [4]. Schmidt RJ, Evans FJ. Skin irritants of the sun spurge (*Euphorbia helioscopia* L.). *Contact Dermat.* 1980 Apr;6:204–210.
- [5]. Almiş H, Bucak IH, Tekin M, et al. Acute irritant bullous contact dermatitis caused by *Euphorbia helioscopia*. *Contact Dermat.* 2015;72:184–185.
- [6]. Barla A, Birman H, Kültür Ş, et al. Secondary metabolites from *Euphorbia helioscopia* and their vasodepressor activity. *Turk J Chem.* 2006;30:325–332.
- [7]. Webster GL. Plant dermatitis. Irritant plants in the spurge family (Euphorbiaceae). *Clin Dermatol.* 1986;4:36–45.
- [8]. Püttgen KB, Cohen BA. Neonatal dermatology. In: Cohen BA, ed. *Pediatric Dermatology.* 4th ed. Philadelphia: Elsevier Saunders Inc; 2013:29–31.
- [9]. Morelli JG. Contact dermatitis. In: Kleigman RM, Stanton BF, St Geme JW, Schor NF, Behrman RE, eds. *Nelson Textbook of Pediatrics.* 19th ed. Philadelphia: Elsevier Saunders Inc; 2011:647–651.