

Emphysematous and xanthogranulomatous pyelonephritis: rare diagnosis

Authors

Lya Duarte Ramos¹
 Marinus de Moraes Lima²
 Maurício de Carvalho³
 Geraldo Bezerra da Silva Júnior²
 Elizabeth De Francesco Daher²

¹Division of Internal Medicine, Universidade do Sul de Santa Catarina, Florianópolis, Santa Catarina, Brazil

²Department of Internal Medicine, School of Medicine, Universidade Federal do Ceará, Fortaleza, Ceará, Brazil

³Division of Internal Medicine, Hospital de Clínicas, Universidade Federal do Paraná, Curitiba, Paraná, Brazil

Submitted on: 06/20/2009
 Approved on: 11/14/2009

Correspondence to:

Dra. Elizabeth De Francesco Daher
 Rua Vicente Linhares, nº 1198
 Fortaleza – CE – Brazil
 CEP: 60270-135.
 Phone: +55-85-32249725
 Phone (Fax): +55-85-32613777
 E-mail: ef.daher@uol.com.br,
 geraldobezerrajr@yahoo.com.br

The corresponding author has received financial support from the Conselho Nacional de Desenvolvimento Científico e Tecnológico – CNPq.

ABSTRACT

Pyelonephritis is a pyogenic infection of renal parenchyma that involves the renal pelvis. It is generally of easy diagnosis. The present case report aims to describe two different manifestations of this infection: xanthogranulomatous pyelonephritis and emphysematous pyelonephritis, which have poor prognosis and require a more effective treatment. The two cases were women in the fiftieth and sixtieth decade of life, with diabetes mellitus and history of weight loss. The diagnosis of the renal infection was established through computed tomography and the treatment was based in surgical procedure, with favorable outcome.

Keywords: xanthogranulomatous pyelonephritis, emphysematous pyelonephritis, urinary tract infection, nephrostomy, nephrectomy, surgery.

[Braz J Infect Dis 2010;14(4):374-376]©Elsevier Editora Ltda. Este é um artigo Open Access sob a licença de [CC BY-NC-ND](http://creativecommons.org/licenses/by-nc-nd/4.0/)

INTRODUCTION

Pyelonephritis is a pyogenic infection of renal parenchyma that involves the renal pelvis.¹ It generally begins through an ascending infection that affects renal tubules, interstitium, glomeruli and vessels. The acute form manifests with fever and lumbar pain, which can be associated with inflammatory symptoms of the bladder. The chronic forms are the result of cicatricial effects and repeated infections, can present as an insidious disease and can lead to end-stage renal disease.¹

The diagnosis of pyelonephritis is easy in the majority of cases, but there are unusual presentations that make diagnosis more difficult. The aim of this study was to present two hard to diagnose unusual cases of pyelonephritis (xanthogranulomatous pyelonephritis and emphysematous pyelonephritis).

CASE REPORT

Case 1

A 60-year-old woman was admitted to the emergency room with complaints of epigastric pain, vomiting, asthenia and weight loss for three weeks, complicated by digestive tract

hemorrhage (hematemesis and melena), myalgia, obtundation and loss of consciousness. She had history of diabetes mellitus, with irregular use of glibenclamide, and smoking. At physical examination, she was confuse, with jaundice (2+/4+), blood pressure 100/40 mmHg, pulse 188 bpm, respiratory rate 28 rpm, temperature 36.5 °C, and distended abdomen, painful at palpation. Laboratory tests showed Ht 25.9%, Hb 9.2g/dL, WBC 43,800/mm³, with 78% neutrophils, creatinine 2.9 mg/dL, urea 84.7 mg/dL, glicemia > 500 mg/dL, LDH 2,141 mg/dL, and no electrolyte abnormality. Abdomen x-ray showed the presence of air in the renal topography (Figure 1). An abdominal ultrasound and CT scan showed bilateral emphysematous pyelonephritis, with no evidence of urinary stone obstruction (Figure 2). After antibiotic therapy the patient underwent left nephrectomy and had a favorable outcome.

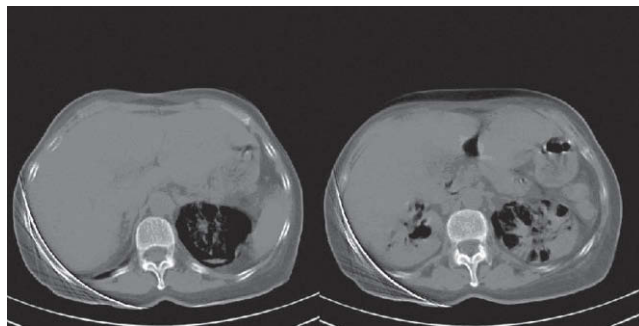
Case 2

A 48-year-old woman was admitted to the emergency room with a history of lumbar pain for two weeks, associated with asthenia, macroscopic hematuria and severe weight loss (15 kg in three months). She also had diabe-

Figure 1: Abdomen plain x-ray shows the presence of air in both renal topography, more evident in the left side.

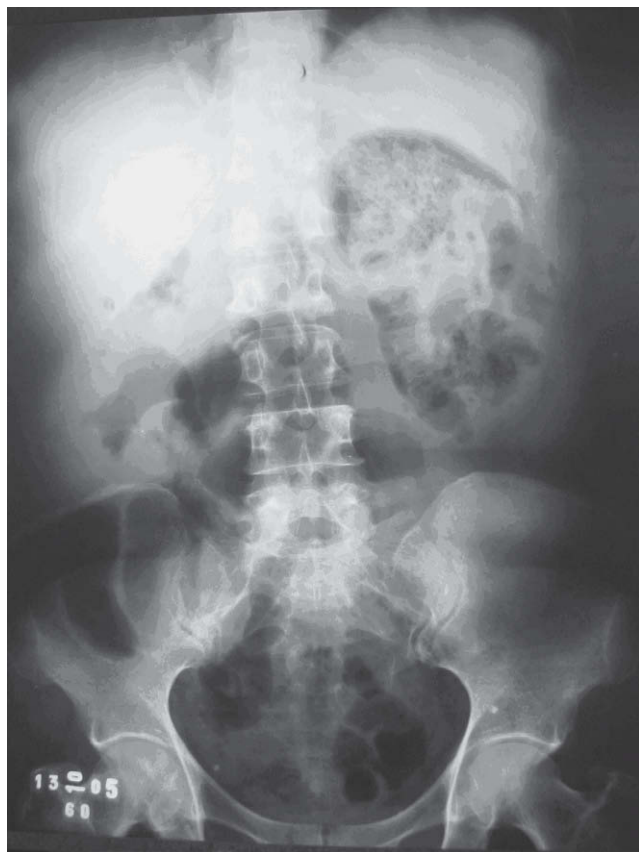

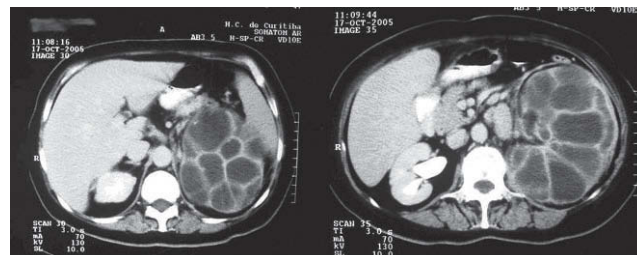Figure 2: CT scan showing bilateral emphysematous pyelonephritis.



tes mellitus treated with metformin, hypertension treated with losartan, and renal lithiasis. At physical examination, she was conscious, pale (3+/4+), with blood pressure 120/70 mmHg, pulse 120 bpm, respiratory rate 18 rpm and temperature 36.5 °C. Her abdomen was distended and had a palpable mass in the left hypocondrium and flank. Laboratory tests showed Ht 20%, Hb 6.3 g/dL, WBC 21,700/mm³, with 77% neutrophils, platelets 637,000/mm³, creatinine 1.3 mg/dL, urea 34 mg/dL, glicemia 199 mg/dL, albumin 2.7 g/dL, with no electrolyte abnormality. The patient received blood transfusion and supportive therapy. New laboratory tests showed Ht 33.7%, Hb 11.3 g/dL, WBC 21,700/mm³,

platelets 559,000/mm³, creatinine 1.4 mg/dL and urea 46 mg/dL. Urinalysis showed pH 6, proteinuria 2+, leukocyturia 4+, hematuria 4+ and bacteriuria. Urine culture was positive for *Escherichia coli*. For this reason levofloxacin was initiated. Abdominal ultrasound showed a staghorn stone in the left kidney, with signs of xanthogranulomatous pyelonephritis. CT scan shows the characteristic replacement of the renal tissue by several rounded, low density areas that are surrounded by an enhanced rim of contrast medium. These images correspond to dilated calyces lined with necrotic xanthomatous tissue extending into the renal parenchyma (Figure 3). She was submitted to a left nephrostomy, with drainage of 2 L of purulent secretion. After antibiotic therapy, the patient improved steadily.

Figure 3: CT scan of xanthogranulomatous pyelonephritis. There is diffuse enlargement of the left kidney and the renal tissue is replaced by multiple low-attenuated masses. The contralateral kidney is normal.



DISCUSSION

Xanthogranulomatous pyelonephritis and emphysematous pyelonephritis are two rare, atypical and severe forms of renal parenchyma infection.²⁻⁴ Emphysematous pyelonephritis was first described by Kelly and MacCullum, in 1898,⁵ and xanthogranulomatous pyelonephritis, by Schlagenhauer, in 1916, termed staphylocomycosis due to its similarity with actinomyces and the presence of *Staphylococcus*. In 1935, it was named xanthogranulomatous pyelonephritis by Oberling.^{6,7}

Xanthogranulomatous pyelonephritis is characterized by a chronic inflammatory process, with destruction of renal parenchyma, subsequently replaced by a granulomatous tissue, containing mononuclear macrophages and lipids (Xanthomam Cells).^{8,9} This clinical entity represents 1% of all renal infections. The disease is four times more frequent among women between the fiftieth and sixtieth decades of life, but can occur at any age.^{10,11} In the majority of cases the disease is unilateral, and the right kidney is more often involved. Bilateral cases are thought to be fatal.^{8,10} Patients with xanthogranulomatous pyelonephritis commonly have diabetes or immunodepression.^{3,8}

Emphysematous pyelonephritis is a necrotizing infection of the renal parenchyma characterized by the production of gas in the intra- and peri-renal tissues.^{12,13} It is

believed that high levels of glucose, in association with inadequate perfusion, lead to a favorable environment for the growth of anaerobic organisms. This disease affects individuals of all ages, but women are six times more likely to be affected.^{5,12,13}

Many conditions are responsible for the pathogenesis of both diseases, including urinary tract obstruction due to kidney stones, ineffective treatment of urosepsis, renal ischemia, lymphatic obstructions, abnormalities in the lipids metabolism and abnormal immune response.^{9,12}

Xanthogranulomatous pyelonephritis is associated with renal stones in 75-86% of cases. The most common associated infectious agents are *Proteus* and *E. coli*, which are responsible for 30-40% of cases.⁸ Approximately 10% of patients have negative cultures.² In emphysematous pyelonephritis, the most common agents are *P. mirabilis*, *E. coli*, and *K. pneumoniae*.^{5,12,13}

Xanthogranulomatous pyelonephritis is most frequently misdiagnosed as renal carcinoma due to its clinical presentation and radiographic appearance.¹⁴ Evidence of chronic urinary tract infection and CT scan findings usually make it easier to differentiate these disorders. Although rarely, the two disorders can occur together. Xanthogranulomatous pyelonephritis must also be distinguished histologically from two other inflammatory conditions, namely renal parenchymal malakoplakia and megalocytic interstitial nephritis.¹⁵

CT scan is now the best tool to diagnose these infections, and it is also important to establish the presence and extension of extra-renal involvement.^{4,8,9,12,16} The most frequent findings in the CT scan are calculi, hydronephrosis, kidney enlargement and hypodense areas, with parenchyma destruction.^{4,12,13} Other diagnostic methods that can be used in these conditions are voiding cystourethrogram, ultrasound and renal scintigraphy.^{4,10,12,16}

The gold-standard therapy for both infections is nephrectomy, which is total in the majority of cases. Circumjacent inflammatory tissues should be removed. In rare cases, partial nephrectomy can be successfully performed.^{2,4,6,8,12,13,16} Nephrostomy before nephrectomy can be considered a method that facilitates surgery, because it allows a reduction in renal mass and favors the access to the kidney at the time nephrectomy is done.^{2,5,12}

Antibiotics alone are not effective for these infections, but should be initiated before surgical procedure in order to control the infectious process and avoid systemic involvement (sepsis).^{2,4,12}

In conclusion, xanthogranulomatous pyelonephritis is an unusual variant of chronic pyelonephritis. Most cases occur in the setting of obstruction due to infected renal stones. Affected patients usually have massive destruction of the kidney due to granulomatous tissue; the appearance may be confused with renal malignancy.

REFERENCES

1. Goldman L, Bennett J. Cecil Tratado de Medicina Interna. 21st Ed. Rio de Janeiro: Guanabara-Koogan, 2001.
2. Leoni AF, Luque A, Sambuelli RH, Valverde JC. Pielonefritis xantogranulomatosa asociada a flora poli microbiana. Rev Panam Infectol 2004; 6:23-7.
3. Punekar SV, Kinne JS, Rao SR, Madiwale C, Karhadkar SS. Xanthogranulomatous pyelonephritis presenting as emphysematous pyelonephritis: a rare association. J Postgrad Med 1999; 45:125.
4. Lim CH, Kim WB, Yon Su Kim *et al*. Bilateral emphysematous pyelonephritis with perirenal abscess cured by conservative therapy. J Nephrol 2000; 13:155-8.
5. Shetty S *et al*. Emphysematous Pyelonephritis. Department of Urology, W. Beaumont Hospital 2006; 1:1-10.
6. D'ippolito G, Tockechi D. Tomografic aspects of xanthogranulomatous pyelonephritis and related complications. São Paulo Med J 1996; 114:1091-6.
7. Filho HNV, Filho WAF, Souza HAM, Leal T, Tenório AL. Pielonefrite xantogranulomatosa. J Pediatria (Rio J) 1994; 70:302-4.
8. Alam A, Chander BN, Joshi DP. Xanthogranulomatous pyelonephritis: diagnosis using computer tomography. Med J Armed Forces India 2004; 60:86-8.
9. Quinn FMJ, Dick AC, Corbally MT, McDermott MB, Guiney EJ. Xanthogranulomatous pyelonephritis in childhood. Arch Dis Child 1999; 81:403-86.
10. Eastham J, Ahlering T, Skinner E. Xanthogranulomatous pyelonephritis: clinical findings and surgical considerations. Urology 1994; 43:295-9.
11. Príncipe P, Costa L. Infecção do tracto urinário. Rev Port Clin Geral 2005; 21:219-25.
12. McGorry DM, Kroser J, Taylor LT, Howard Lewis H, Gabale D. Emphysematous Pyelonephritis Presenting as an Acute Abdomen. Infect Urol 1999; 12:162-5.
13. Jain SK, Agarwal N, Chaturvedi SK. Emphysematous pyelonephritis: a rare presentation. J Postgrad Med 2000; 46:31-2.
14. Hortling N, Layer G, Albers P, Schild HH. Xanthogranulomatous pyelonephritis with septic lung metastases and infiltration of the colon. Difficult preoperative differential pulmonary hypernephroma metastasis diagnosis. Aktuelle Radiol 1997; 7:317.
15. al-Sulaiman MH, al-Khader AA, Mousa DH *et al*. Renal parenchymal malacoplakia and megalocytic interstitial nephritis: clinical and histological features. Report of two cases and review of the literature. Am J Nephrol 1993; 13:483.
16. Kim JC. US and TC findings of xanthogranulomatous pyelonephritis. Clin Imaging 2001; 25:118-21.