



## Case report

## Unexplained entry dyspareunia secondary to metallic needle

Yi-Jen Chen<sup>a,b,j</sup>, Ben-Shian Huang<sup>a,b,c,j</sup>, Wen-Hsun Chang<sup>d,e,f</sup>, Shun-Fen Chen<sup>d</sup>, Shu Yu<sup>f</sup>, Peng-Hui Wang<sup>a,b,c,g,h,i,\*</sup>

<sup>a</sup> Department of Obstetrics and Gynecology, Taipei Veterans General Hospital, Taipei, Taiwan

<sup>b</sup> Department of Obstetrics and Gynecology, National Yang-Ming University School of Medicine, Taipei, Taiwan

<sup>c</sup> Department of Obstetrics and Gynecology, National Yang-Ming University Hospital, Ilan, Taiwan

<sup>d</sup> Department of Nursing, Taipei Veterans General Hospital, Taipei, Taiwan

<sup>e</sup> Institute of Hospital and Health Care Administration, National Yang-Ming University School of Medicine, Taipei, Taiwan

<sup>f</sup> Department of Nursing, National Yang-Ming University, Taipei, Taiwan

<sup>g</sup> Institute of Clinical Medicine, Taipei Veterans General Hospital, Taipei, Taiwan

<sup>h</sup> Immunology Center, Taipei Veterans General Hospital, Taipei, Taiwan

<sup>i</sup> Infection and Immunity Research Center, National Yang-Ming University, Taipei, Taiwan

## ARTICLE INFO

## Article history:

Received 18 April 2012

Received in revised form

10 August 2012

Accepted 12 August 2012

Available online 29 September 2012

## Keywords:

Dyspareunia

Foreign body

Metallic needle

## ABSTRACT

Chronic and persistent dyspareunia is always challenging for the selection of adequate diagnostic management and therapeutic decision-making. A 72-year-old woman had a 53-year history of chronic and persistent entry dyspareunia. After appropriate diagnostic measures, including ultrasonography, plain film, and computed tomography, the patient underwent removal of a detected metallic needle from the perineum.

Copyright © 2012, The Asia-Pacific Association for Gynecologic Endoscopy and Minimally Invasive Therapy. Published by Elsevier Taiwan LLC. All rights reserved.

## Introduction

Postpartum dyspareunia may be very common, although the true incidence is rarely discussed. Robson et al<sup>1</sup> interviewed 119 British women before and after delivery. They found that persistent discomfort and pain were prominent sequela in 40% of women at 3 months, 18% at 6 months, and 8% at 1 year after delivery, respectively. Many theories have been presented to explain the mechanism of postpartum dyspareunia including episiotomy tenderness, vaginal atrophy, and low estrogen levels.<sup>2</sup> An embedded foreign body in the perineum causing postpartum dyspareunia has never been reported before. Herein, an unusual clinical presentation of postpartum dyspareunia is reported to emphasize the importance of history and useful imaging and/or assistant tools in aiding the identification of the cause of postpartum dyspareunia.

## Case report

A 72-year-old, gravida 6, para 6, woman had entry dyspareunia since her first vaginal delivery. A midwife had delivered the first baby at home when the patient was 19 years of age (in 1949). Severe vaginal lacerations were noted. The midwife tried to repair the defects, but failed to complete the procedure because of inadequate anesthesia. During the procedure, a surgical needle was lost. The midwife searched for the lost surgical needle, but it was not found. The perineal wound was left alone and the wound healed unremarkably.

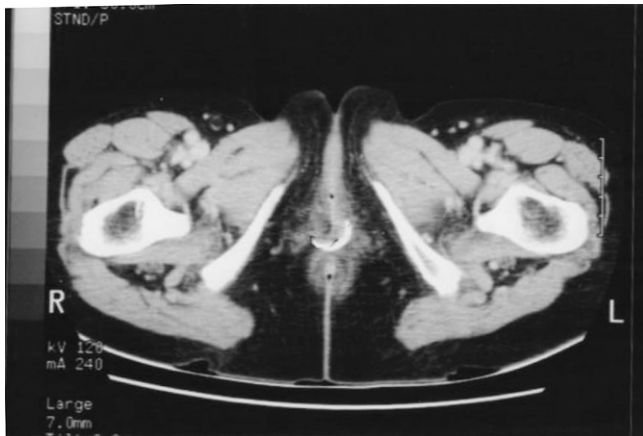
Since then, the patient has had entry dyspareunia. However, she could have sexual activity and was able to vaginally deliver five more babies smoothly. Menopause occurred in 1983 and she received hormone replacement therapy. This entry dyspareunia had bothered her persistently, both before and after menopause. Although she visited many physicians, none could help her. Finally, the patient was referred to our hospital.

Physical examination revealed unremarkable findings. Trans-abdominal, transvaginal, and transperineal ultrasound failed to detect any abnormalities. Computed tomography (CT) scans showed a metallic needle about 2 cm long in the postvaginal wall near the introitus (Fig. 1). The patient underwent surgery to remove the needle and her dyspareunia disappeared after surgical treatment.

\* Corresponding author. Department of Obstetrics and Gynecology, Taipei Veterans General Hospital, 201, Section 2, Shih-Pai Road, Taipei 112, Taiwan.

E-mail address: phwang@vghtpe.gov.tw (P.-H. Wang).

<sup>j</sup> Both authors contributed equally.



**Fig. 1.** Computed tomography scan of the lower vaginal area. There is a metallic needle in the postvaginal wall near the introitus.

## Discussion

For this woman, dyspareunia resulted from inappropriate management and inadequate anesthesia for perineal lacerations. In addition, the possibility of an embedded foreign body in the perineal wound was neglected. That is because the diagnosis of a foreign body as the cause of dyspareunia is sometimes difficult to detect during routine clinical examinations. Ultrasonography is less invasive and more readily available to identify various kinds of gynecologic problems<sup>3</sup> than other imaging modalities and it seems to be useful in identifying the cause of the dyspareunia. However, in this case, ultrasonography provided us with little information. In contrast, plain radiographs and CT scans might be more useful in localizing lesions,<sup>4</sup> but are rarely used by the majority of physicians.

The above mentioned points seem to be arguable since many articles have shown that ultrasonography provides important information on the depth, size, and anatomic relationship with surrounding structures.<sup>5,6</sup> We failed to use ultrasonography as a tool to identify this radio-opaque metallic needle, which could have been easily diagnosed by many imaging tools, including ultrasonography. There are many causes contributing to this failure.

Among these, two major critical points should be emphasized. First, the acts of our omission created these dangers.<sup>7</sup> Second, chronic complaints and non-specific symptoms are always challenging for the selection of adequate diagnostic management and therapeutic decision-making.<sup>5</sup> Third, we used an inappropriate transducer (vaginal probe) in this case. Broadband high-frequency (7–20 MHz) linear-array transducers can improve the accuracy of clinical assessment of musculoskeletal disorders, since these transducers provide better spatial resolution but are more suitable for evaluating superficial structures.<sup>8</sup>

We present this rare cause of dyspareunia to emphasize the early use of plain radiographs or other modern imaging tools, such as CT, in evaluating unexplained entry dyspareunia. Of course, careful history evaluation might avoid an extra expense.

## Acknowledgments

This work was supported in part by grants from the Veterans General Hospitals University System of the Taiwan Joint Research Program (VGHUST99-G4), Taipei Veterans General Hospital (V99C1-085, V100C-054, V101C1-128, V101E4-004, and V101E5-006), and the National Science Council (NSC 99-2314-B-010-009-MY3), Taiwan.

## References

1. Robson KM, Brant HA, Kumar R. Maternal sexuality during first pregnancy and after childbirth. *Br J Obstet Gynaecol.* 1981;88:882–889.
2. Goetsch MF. Postpartum dyspareunia. *J Reprod Med.* 1999;44:963–968.
3. Lee KC, Huang CY, Wang PH. Parasitic peritoneal leiomyomatosis mimicking intra-abdominal abscess with hematoma. *Taiwan J Obstet Gynecol.* 2012;51:115–116.
4. Wilkes RA, Seymour N. Dyspareunia due to exostosis formation after pelvic fracture. *Br J Obstet Gynaecol.* 1993;100:1050–1051.
5. Mohammadi A, Chasemi-Rad M, Khodabakhsh M. Non-opaque soft tissue foreign body: sonographic findings. *BMC Med Imaging.* 2011;11:9.
6. Will U, Eger H, Hartmut S, Meyer F. “Metallic taste”: search for the needle in a haystack (exemplary diagnostic measures and successful minimal invasive endoscopic treatment of a needle-like copper-containing foreign body in the gastric wall). *BMJ Case Rep.* 2009;2009. pii: bcr08.2008.0815 [Epub 2009 Apr 7].
7. Sun HD, Huang BS, Chao HT, Ng HT, Wang PH. Tuberculosis peritonitis. *Taiwan J Obstet Gynecol.* 2012;51:1–2.
8. Martinoli C, Bianchi S, Dahmane M, Pugliese F, Bianchi-Zamorani MP, Valle M. Ultrasound of tendons and nerves. *Eur Radiol.* 2002;12:44–55.