

iMAGE

LETTERS TO THE EDITOR

Fluoroscopy-Guided Aortic Root Imaging for TAVR

“Follow the Right Cusp” Rule

Transcatheter aortic valve replacement (TAVR) has extended the treatment options for inoperable patients with symptomatic, severe aortic stenosis (1). The safety and proficiency of this procedure depend upon proper imaging during the selection process and intraoperatively. Recently, the 2012 Expert Consensus Document on Transcatheter Aortic Valve Replacement (1) established a systematic pre-operative imaging protocol for patients undergoing TAVR. By contrast, the best intraoperative imaging to guide precise and safe positioning and deployment of transcatheter bioprostheses still remains a matter of some debate. New software for intraoperative 3-dimensional transesophageal echocardiography (TEE) (1) and rotational computed tomography (CT) (2) have been developed, pointing to more reliable aortic root reconstruction. Notwithstanding, the lack of validation of these techniques as well as several logistic limitations (as in the case of CT) or clinical restrictions (as in the case of TEE) (1) impede large-scale usage.

To date, fluoroscopy still represents the mainstay for intraoperative imaging in patients undergoing TAVR. The determination of optimal orthogonal projections of the aortic root is pivotal for the exact positioning of the bioprostheses with respect to the surrounding structures, and it should require limited contrast load (1). Here, we describe a simple rule—“follow the right cusp”—to define the perpendicular annulus plane by fluoroscopy and to obtain the alignment of the right cusp between the left and the noncoronary cusps. We describe the key elements of this rule in the context of normal (Fig. 1A) and “horizontal” aortic root anatomy (Fig. 2A).

In the case of TAVR in patients with normal aortic root anatomy, the first step is to identify the right cusp, which serves as a reference (Fig. 1B). If the right cusp is placed behind the noncoronary cusp or the left cusp, the C-arm must be rotated to a right anterior oblique (RAO) or left anterior oblique (LAO) angulation, respectively. If the right cusp appears higher or lower than the ideal plane intercepting other cusps, the x-ray beam should be angulated cranial (CRA) or caudal (CAU), respectively. A step-by-step approach would be as follows: a pigtail catheter is placed in the right cusp as a reference, and a LAO 10° CRA 10° aortogram is performed (Fig. 1B, panel I), because it generally ensures a proper aortic root image for TAVR (3). If the right cusp is located on the “right” side behind the noncoronary cusp (Fig. 1B, panel II), the C-arm must be lead to a RAO projection in order to follow the right cusp. After the projection view has been changed, the right cusp will appear in the middle, but still deeper than the other cusps. Once again, follow the right cusp by turning the C-arm clockwise to the CAU direction

(Fig. 1B, panel III). After alignment is obtained, providing that the most caudal attachments of all 3 of the aortic leaflets result in 1 axial image, successful TAVR can be performed (Fig. 1B, panel IV).

A similar method can be used in those cases presenting horizontal aortic root morphology. The right cusp should be selected as a reference, as stated in the preceding text (Fig. 2B). If the right cusp appears behind the left cusp or the noncoronary cusp, the x-ray beam angulation must be switched to a CRA or a CAU position, accordingly. If the right cusp appears higher or lower as compared with the ideal plane intercepting the other cusps, the C-arm must be rotated to a RAO or LAO angulation, respectively. A step-by-step approach would be as follows: a reference aortogram is performed as described for the normal anatomy (Fig. 2B, panel I). If the right cusp is located behind the noncoronary cusp, the C-arm must be

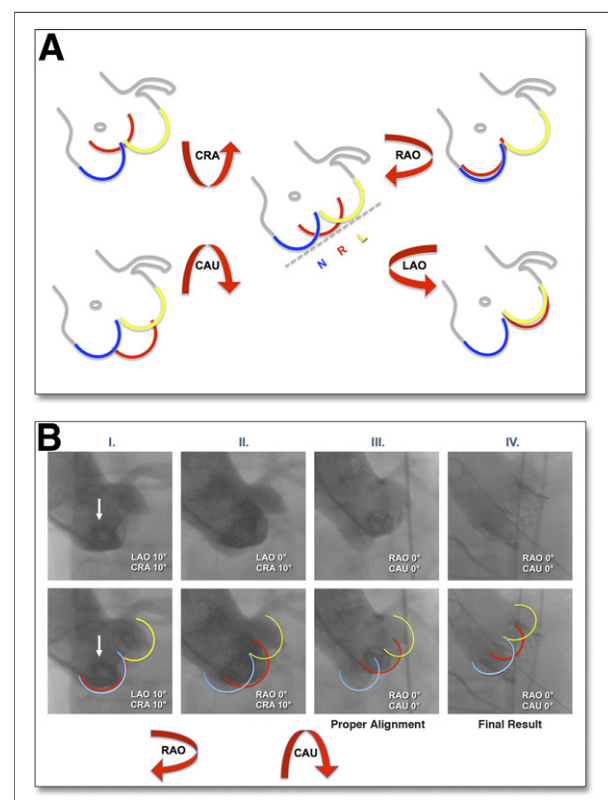


Figure 1. Suggested Scheme and Real-World Application of the Rule in Normal Aortic Root Anatomy

(A) Schematic illustration of the “follow the right cusp” rule pointing to the proper alignment in the case of normal aortic root anatomy. (B) Example of normal aortic root anatomy: images are provided without (upper images) and with (lower images) a schematic overlay. The white arrow indicates the pigtail catheter. Panels I through III show fluoroscopy-guided alignment of the aortic plane; panel IV shows the final result. CAU = caudal; CRA = cranial; L = left cusp; LAO = left anterior oblique; N = noncoronary cusp; R = right cusp; RAO = right anterior oblique.

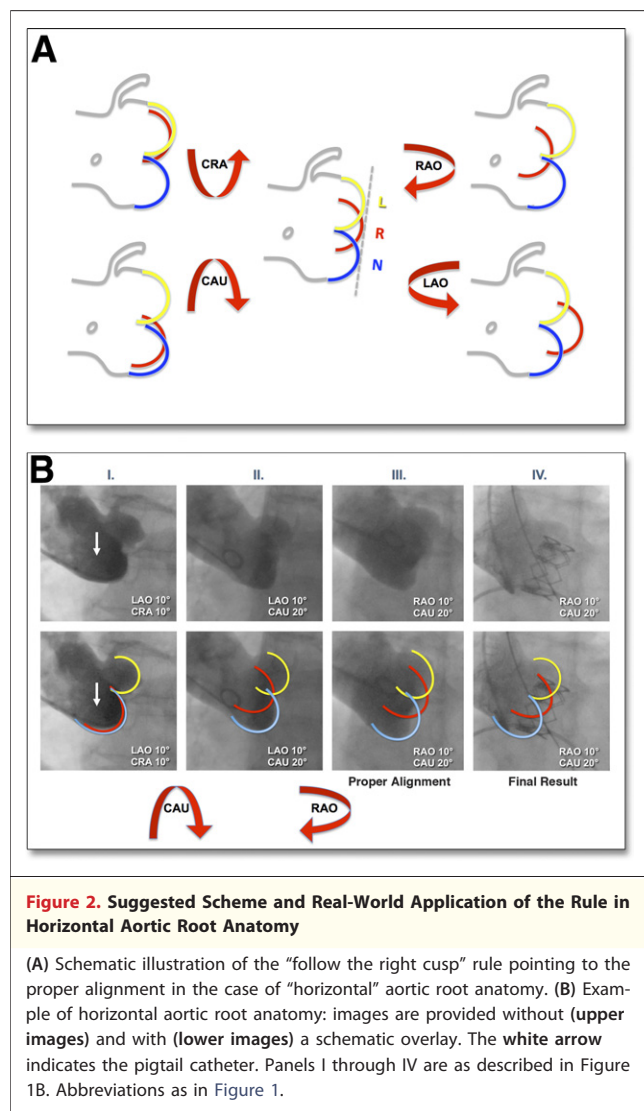


Figure 2. Suggested Scheme and Real-World Application of the Rule in Horizontal Aortic Root Anatomy

(A) Schematic illustration of the “follow the right cusp” rule pointing to the proper alignment in the case of “horizontal” aortic root anatomy. (B) Example of horizontal aortic root anatomy: images are provided without (upper images) and with (lower images) a schematic overlay. The white arrow indicates the pigtail catheter. Panels I through IV are as described in Figure 1B. Abbreviations as in Figure 1.

moved in a CAU direction in order to follow the right cusp (Fig. 2B, panel II). According to fluoroscopy, the right cusp will appear in the middle, but higher than the other cusps. Once again, follow the right cusp by turning the C-arm counterclockwise in the RAO projection (Fig. 2B, panel III). After alignment is obtained, successful TAVR can be performed with the 3 leaflets in line (Fig. 2B, panel IV).

A fluoroscopy-guided approach to TAVR may have several potential advantages as compared with other imaging techniques that are currently under consideration. First, it allows precise valve positioning without the limitations of calcium-related or device-related artifacts, as with TEE (4). On the contrary, fluoroscopy may rely on severe aortic valve calcifications as anatomic references for exact bioprostheses deployment (5) and for measurement of the distance of the surrounding structures with respect to the valve plane. Second, fluoroscopy reduces the contrast medium and total radiation load with respect to

intraoperative CT scans (2). Finally, no general anesthesia or rapid pacing is necessary, as in the case of TEE and intraprocedural CT, respectively (1).

The follow the right cusp rule is intended as a useful tool that allows proper fluoroscopy-guided aortic root alignment. This permits simplification of TAVR procedures. Fluoroscopy-guided TAVR may overcome clinical and procedural caveats associated with an ultrasound-based approach (5) and without the expense of higher radiation and contrast load as in the case of intraoperative CT (2).

Trials evaluating the merits and pitfalls of fluoroscopy-guided TAVR in comparison with other intraoperative imaging techniques will help to define an evidence-based paradigm for TAVR procedures.

Albert M. Kasel, MD,* Salvatore Cassese, MD,
 Alexander W. Leber, MD, Wolfgang von Scheidt, MD,
 Adnan Kastrati, MD

*Deutsches Herzzentrum, Technische Universität, Lazarettstrasse 36,
 Munich, Germany. E-mail: markus.kasel@googlemail.com

<http://dx.doi.org/10.1016/j.jcmg.2012.06.014>

Please note: Dr. Kasel is a proctor for Edwards Lifesciences. Dr. Leber has received research funding and lecture fees from Edwards Lifesciences and Medtronic. All other authors have reported that they have no relationships relevant to the contents of this paper to disclose.

REFERENCES

- Holmes DR Jr., Mack MJ, Kaul S, et al. 2012 ACCF/AATS/SCAI/STS expert consensus document on transcatheter aortic valve replacement. *J Am Coll Cardiol* 2012;59:1200–54.
- Leipsic J, Gurvitch R, Labounty TM, et al. Multidetector computed tomography in transcatheter aortic valve implantation. *J Am Coll Cardiol Img* 2011;4:416–29.
- Cribier A, Litzler PY, Eltchaninoff H, et al. Technique of transcatheter aortic valve implantation with the Edwards-Sapien heart valve using the transfemoral approach. *Herz* 2009;34:347–56.
- Kapadia SR, Schoenhagen P, Stewart W, Tuzcu EM. Imaging for transcatheter valve procedures. *Curr Probl Cardiol* 2010;35:228–76.
- Durand E, Borz B, Godin M, et al. Transfemoral aortic valve replacement with the Edwards SAPIEN and Edwards SAPIEN XT prosthesis using exclusively local anesthesia and fluoroscopic guidance: feasibility and 30-day outcomes. *J Am Coll Cardiol Intv* 2012;5:461–7.

Determination of the Aortic Annulus Plane in CT Imaging—A Step-by-Step Approach

Transcatheter aortic valve replacement (TAVR) is increasingly used to treat severe aortic stenosis in patients with high operative mortality. Accurate determination of aortic annulus dimensions is necessary in order to appropriately select prosthesis size, or to exclude patients from the procedure if no suitable prosthesis is available. While echocardiography is the most commonly used