

Successful stent graft repair of multiple thoracoabdominal mycotic aortic aneurysms in the presence of Kommerell diverticulum and complicated by aorto-esophageal fistula

Debra S. T. Chong, MBBS, MRCS,^{a,b} Hamish Hamilton, FRCS,^a Jason Constantinou, MD, FRCS,^a Meryl Davis, FRCS,^a Muntzer Mughal, FRCS,^{b,c} and Krasnodar Ivancev, MD, PhD,^a *London, United Kingdom*

We describe the management of a woman who presented with synchronous mycotic aortic aneurysms of the aortic arch in the presence of Kommerell diverticulum, the distal thoracic, and the juxtarenal aorta. A staged stent graft repair was undertaken due to rapid expansion of the aneurysms, which involved placement of multiple thoracic quadruple-fenestrated and infrarenal bifurcated stent grafts. Despite complications of an aorto-esophageal fistula and transitory spinal cord ischemia, she has been managed successfully and is doing well at 36 months. This case illustrates that stent graft repair of mycotic aneurysms can offer a successful treatment option in selected patients. (*J Vasc Surg Cases* 2015;1:197-200.)

Mycotic aortic aneurysms (MAAs) present many challenges to treatment. Open surgical repair of these aneurysms, considered to be the radical treatment for removing the infected segment of the aorta, is associated with poor outcomes. Endovascular repair offers a more promising modality. We describe our successful management of such a complex case. Formal consent for the publication of this case report was obtained from the patient.

CASE REPORT

A 54-year-old Caucasian woman presented with right-sided sciatic nerve pain, generalized weakness, lethargy, and weight loss. There was no history of fever or recent travel abroad. A urinary tract infection positive for *Escherichia coli* was diagnosed and appropriate antibiotic therapy initiated.

Seven years earlier she presented with acute renal failure and hypertension with bilateral hydronephrosis. Computed tomography (CT) at that time revealed a small 2.5-cm diameter abdominal aortic

aneurysm with biopsy specimen-proven retroperitoneal fibrosis treated with tamoxifen and prednisolone for 6 months, with a return to normal renal function. She failed to attend follow-up. Of note, her father had died of a ruptured abdominal aortic aneurysm at age 59 years.

CT angiography (CTA) revealed multilevel thoracic and abdominal aneurysms. This included an aneurysm at the origin of an aberrant right subclavian artery constituting a Kommerell diverticulum measuring 6.5 cm, with a 4.7-cm-diameter aneurysm in the distal thoracic aorta, and a juxtarenal 3.8-cm-diameter abdominal aortic aneurysm, with multiple enlarged lymph nodes suggestive of an infective or inflammatory process.

Positron emission tomography using 18F-fluorodeoxyglucose revealed an uptake suggestive of aortitis or mycotic aneurysms and discitis at the level of L3 and L4. Rheumatology and infectious diseases advice was gained, and due to the dual pathology, she was commenced on antibiotic therapy with intravenous piperacillin and tazobactam and high-dose steroids (prednisolone >30 mg). These antibiotics were replaced 7 days with ceftriaxone to facilitate long-term regimen.

Blood investigations at the initial presentation revealed a white cell count of $35 \times 10^9/L$ (high) with a neutrophilia and a C-reactive protein of 384 mg/dL (high). Rheumatoid factor was raised at 23 IU/mL, C3 was 225 IU/mL, and C4 was 28 IU/mL. Results of the remaining autoimmune and viral screen were negative. Despite multiple blood cultures, these remained negative.

She developed pain 1 week later, and a repeat CTA revealed expansions in the size of the saccular aneurysm of the Kommerell diverticulum from 6.5 to 7.7 cm, of the fusiform thoracic aneurysm from 4.7 to 6.6 cm, and of the juxtarenal component from 3.8 to 4.4 cm (Fig 1). The treatment options were discussed with the patient, and after anesthesia input, an endovascular option was deemed to be lower risk than an open thoracoabdominal repair, taking into account her borderline preoperative cardiac and respiratory status.

She underwent bilateral carotid-subclavian bypasses using Dacron (DuPont, Wilmington, Del) 6-mm grafts to preserve

From the Department of Vascular Surgery, Royal Free London NHS Foundation Trust,^a the Division of Surgery and Interventional Science, University College London,^b and the Upper Gastro-Intestinal Unit, University College London Hospitals NHS Foundation Trust.^c

Author conflict of interest: K.I. receives royalties and holds patents with Cook Medical.

Correspondence: Debra S. T. Chong, MBBS, MRCS, Department of Vascular Surgery, Royal Free London NHS Foundation Trust, Pond St, London, NW3 2QG, United Kingdom (e-mail: d.chong@ucl.ac.uk).

The editors and reviewers of this article have no relevant financial relationships to disclose per the Journal policy that requires reviewers to decline review of any manuscript for which they may have a conflict of interest.

2352-667X

Copyright © 2015 The Authors. Published by Elsevier Inc. on behalf of the Society for Vascular Surgery. This is an open access article under the CC BY-NC-ND license (<http://creativecommons.org/licenses/by-nc-nd/4.0/>).

<http://dx.doi.org/10.1016/j.jvsc.2015.05.003>

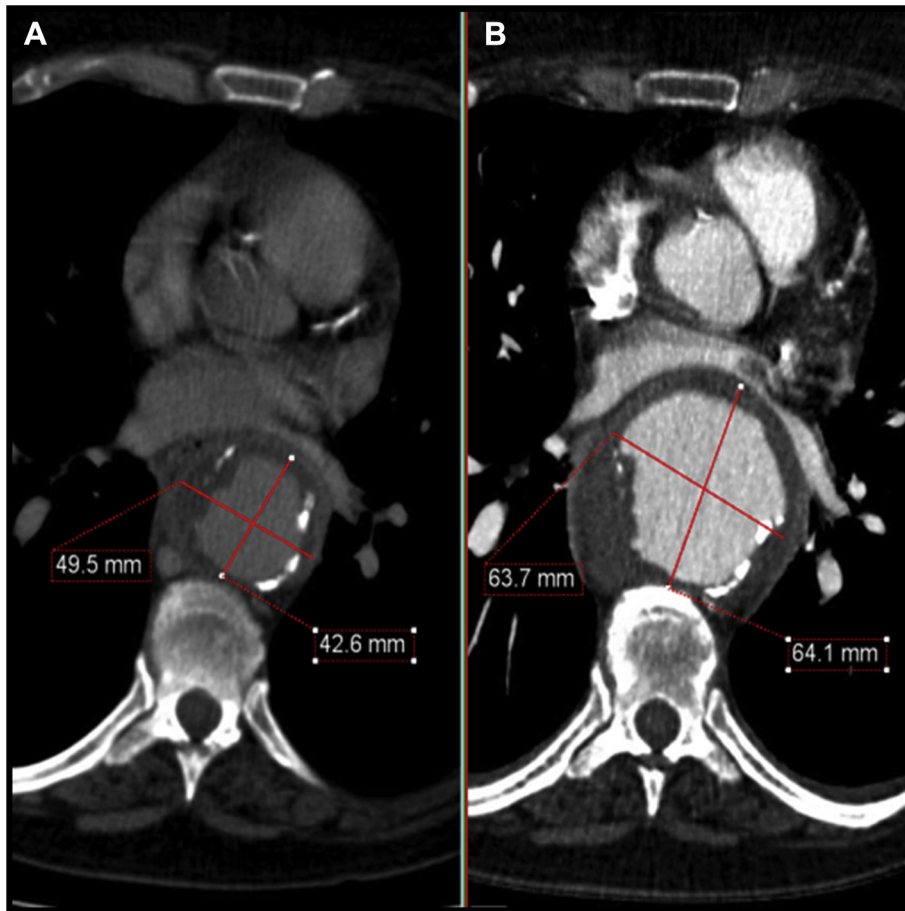


Fig 1. Cross-sectional images: (A) Initial computed tomography angiography (CTA) demonstrates the thoracic component of the mycotic aortic aneurysms (MAAs). B, The CTA 1 week later showed rapid expansion.

arterial flow to the upper extremities, with deployment of Zenith TX2 thoracic stent grafts (Cook Medical, Bloomington, Ind), followed by bilateral subclavian artery embolizations bilaterally with Amplatzer plugs (St. Jude Medical, St. Paul, Minn).

A CTA 1 week later revealed further enlargement (from 4.4 to 5.4 cm) of the juxtarenal aneurysm, necessitating surgery with a quadruple-fenestrated device and an infrarenal bifurcated stent graft (Cook Medical). The fenestrated device was used off-the-shelf, having been customized for another patient (Fig 2) and modified on the table.

She made a good recovery and was discharged home 27 days after her initial presentation. Six days later she was readmitted with lower limb weakness, urinary and fecal incontinence, and spinal cord ischemia secondary to hypotension as a consequence of diarrhea and dehydration. Intravenous fluids, inotropic support, and cerebrospinal fluid drainage resulted in a speedy recovery ≤ 24 hours.

One month later she presented with a 1-week history of sweating, malaise, and chest, shoulder, and back pain. CTA demonstrated gas within the thoracic aortic sac, and a Gastrografin (Bracco Diagnostics Inc, Princeton, NJ) swallow and esophagogastrroduodenoscopy revealed an aorto-esophageal fistula 30 cm from the incisors. Steroids were withdrawn. An emergency cervical esophagostomy, feeding

jejunostomy, and venting gastrostomy was performed. Mediastinitis, with no pleural contamination, was noted at surgery.

Esophageal reconstruction was conducted successfully 2 months later using a stomach conduit based on the greater curvature and tunnelled retrosternally. A hand-sewn cervical esophago-gastric anastomosis restored the alimentary tract. A subsequent CTA demonstrated satisfactory stent graft positioning, with patent visceral arteries and complete collapse of the aneurysms, which were considered to have drained via the aorto-esophageal fistula.

She presented again 7 months with sepsis requiring intravenous antibiotics. CTA identified a new fluid collection around the distal thoracic stent grafts, not deemed to require drainage. Dysphagia and loss of weight were also noted due to an anastomotic stricture, which was successfully dilated at esophagogastrroduodenoscopy.

A follow-up CTA at 30 months showed unchanged good results. Forty months after presentation, she remains well and has returned to normal activities of daily living. She remains on life-long antibiotics and regular surveillance.

DISCUSSION

This case highlights the complex nature of treating patients with MAAs, especially in patients in whom open

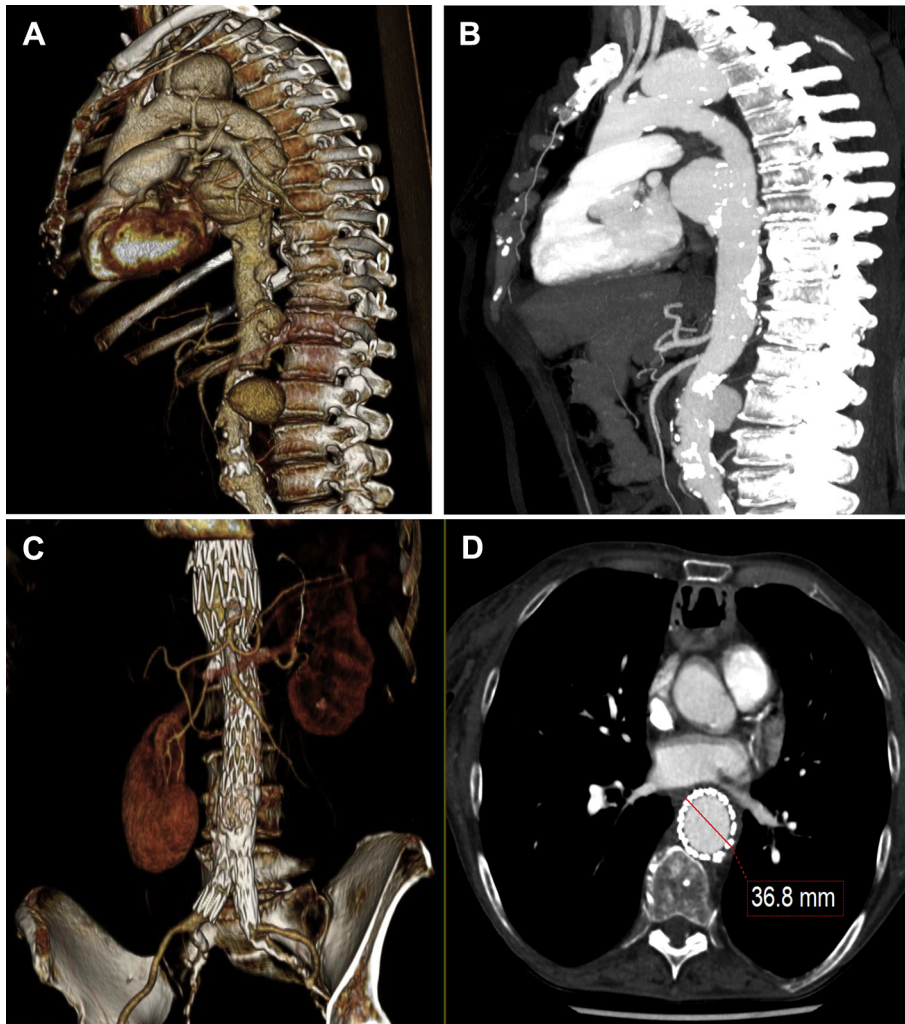


Fig 2. Computed tomography angiograms (CTAs) before stenting show multiple mycotic aortic aneurysms (MAAs) in (A) three-dimensional and in (B) maximum intensity pixel reconstructions. C, A three-dimensional CTA at 30 months shows patency of all the visceral vessels after quadruple-fenestrated stent graft repair. D, A CTA cross-sectional image at 30 months at the same level as Fig 1 shows a complete reduction in the size of the aneurysm.

surgery is deemed high risk. In this patient, extensive endovascular procedures were undertaken.

It is important to highlight the dichotomy of the diagnosis in this case and differentiating between an inflammatory and infective etiology. No positive blood cultures were identified in this patient, hence the dual therapy.

Semba et al¹ published a series of three patients in whom an endovascular approach was undertaken for infected thoracic aneurysms. This modality in the presence of infection remains controversial. Other groups have also shown that endovascular stenting in the presence of a mycotic aneurysm does not equate to poor outcomes, despite not removing the infected aneurysms.²⁻⁴

In the treatment of MAAs, a period of targeted antibiotic therapy is advocated to allow sepsis suppression

(with negative blood cultures and normal inflammatory markers) and optimization preoperatively resulting in better outcomes.⁵ However, patients with MAAs often present as an emergency, which may preclude a period of antibiotic therapy before surgery. Concurrent therapy with other agents, such as steroids, as in this patient, can also contribute to adverse effects, including poor healing and development of an aorto-esophageal fistula.

A systematic review looked at the predictive factors and outcomes for MAAs treated with endovascular stent grafting⁵ and concluded that factors such as age ≥ 65 years, rupture on presentation, association with aortoenteric or aortobronchial fistulae, and fever at the time of operation were positive predictive factors for persistent infection. The 12-month survival rate for patients with no evidence of persistent infection at the time of operation

was 94%, whereas survival for the cohort with persistent infection at the time of surgery was 39%.⁵ The administration of antibiotics for >1 week and adjunctive procedures, such as surgical débridement or percutaneous drainage, contributed to a better outcome.

Historically, endoluminal repair of MAAs was considered a bridging procedure before open surgery. However, a recent international collaboration to elucidate the durability of stent grafts in the treatment of MAAs⁶ reported good short-term outcome (91% survival at 30 days), but fatal infection-related complications were high in the first postoperative year (19%). Cessation of antibiotic therapy is strongly correlated with fatal infection-related complications.

CONCLUSIONS

An endovascular approach is valid in high-risk patients. However, fastidious monitoring is mandatory because of the unpredictable nature of MAAs. Careful planning and surveillance are imperative to achieve good outcomes.

We acknowledge the clinical support and expertise of the Rheumatology Team and Infectious Diseases Team at the Royal Free London National Health Service

Foundation Trust, as well as the Upper Gastrointestinal Team at University College London Hospitals National Health Service Foundation Trust, in particular, Borzoueh Mohammadi, for his clinical input.

REFERENCES

1. Semba CP, Sakai T, Slonim SM, Razavi MK, Kee ST, Jorgensen MJ, et al. Mycotic aneurysms of the thoracic aorta: repair with use of endovascular stent-grafts. *J Vasc Interv Radiol* 1998;9:33-40.
2. Clough RE, Black SA, Lyons OT, Zayed HA, Bell RE, Carrell T, et al. Is endovascular repair of mycotic aortic aneurysms a durable treatment option? *Eur J Vasc Endovasc Surg* 2009;37:407-12.
3. Sedivy P, Spacek M, El Samman K, Belohlavek O, Mach T, Jindrak V, et al. Endovascular treatment of infected aortic aneurysms. *Eur J Vasc Endovasc Surg* 2012;44:385-94.
4. Sörelus K, Mani K, Björck M, Nyman R, Wanhainen A. Endovascular repair of mycotic aortic aneurysms. *J Vasc Surg* 2009;50:269-74.
5. Kan CD, Lee HL, Yang YJ. Outcome after endovascular stent graft treatment for mycotic aortic aneurysm: a systematic review. *J Vasc Surg* 2007;46:906-12.
6. Sörelus K, Mani K, Björck M, Sedivy P, Wahlgren CM, Taylor P, et al. Endovascular treatment of mycotic aortic aneurysms: a European multicenter study. *Circulation* 2014;130:2136-42.

Submitted Mar 20, 2015; accepted May 15, 2015.