

Contents lists available at [ScienceDirect](http://www.sciencedirect.com)

American Journal of Ophthalmology Case Reports

journal homepage: <http://www.ajocasereports.com/>

Case report

High-resolution dacryoscopy for observation for pediatric lacrimal duct obstruction



Nozomi Matsumura^{a, *}, Satoshi Goto^b, Shin Yamane^c, Takeshi Fujita^a, Maiko Inoue^c, Mikio Inamura^d, Kazuaki Kadonosono^c

^a Department of Ophthalmology, Kanagawa Children's Medical Center, Japan

^b Department of Ophthalmology, The Jikei University School of Medicine, Katsushika Medical Center, Japan

^c Department of Ophthalmology, Yokohama City University, Department of Ophthalmology and Micro-technology, Japan

^d Inamura Eye Clinic, Japan

ARTICLE INFO

Article history:

Received 28 November 2015

Accepted 18 March 2016

Available online 21 March 2016

Keywords:

Dacryoscopy

Pediatric

Lacrimal duct obstruction

Congenital nasolacrimal duct obstruction

Endoscope

Down syndrome

ABSTRACT

Purpose: The aim of this study was to describe high-resolution dacryoscopy findings for nasolacrimal duct obstruction (NLDO) in three representative pediatric cases with different etiologies.

Observations: In a case of congenital NLDO, a mucosal membranous obstruction was observed at the distal end of the nasolacrimal duct (NLD), and a slit-shaped opening of the NLD was observed after perforation. In a case of acquired NLDO secondary to an adenoviral infection, a membranous obstruction was observed at the proximal NLD. In a case of NLDO with chronic dacryocystitis in a patient with Down syndrome, diffuse fibrous obstruction was observed.

Conclusion and importance: High-resolution dacryoscopy enables a clearer visualization of pediatric lacrimal duct obstructions, leading to an improved understanding of their features.

© 2016 The Authors. Published by Elsevier Inc. This is an open access article under the CC BY-NC-ND license (<http://creativecommons.org/licenses/by-nc-nd/4.0/>).

1. Introduction

Congenital nasolacrimal duct obstruction (CNLDO) is the most common cause of pediatric lacrimal duct obstruction [1]. The presence of the membrane covering the opening of the lacrimal duct is thought to cause CNLDO [2–4]. Some reports have described the use of dacryoscopy to observe abnormalities in patients with CNLDO [5–7]. However, dacryoscopy images have often been unclear because of technical limitations. High-resolution dacryoscopy was launched for commercial use in Japan in 2013. The image quality that can be obtained has been significantly improved. Here, we report three representative cases of pediatric nasolacrimal duct obstruction (NLDO) with different causes, as observed using high-resolution dacryoscopy.

2. Material and method

All the subjects were treated at the Kanagawa Children's Medical Center, Yokohama City. Four hundred and forty-four children

with lacrimal disease in a total of 584 eyes visited our institution between January 2011 and September 2015. A total of 217 eyes in 185 children who underwent lacrimal surgery during the study period were included. One hundred and forty-seven eyes in 131 children underwent office-based nasolacrimal duct probing. Office-based probing was performed in children with CNLDO between the ages of 6 and 12 months. The procedure was performed under topical anesthesia using a metal probe. Dacryocystorhinostomy (DCR) was performed for 1 eye, and other lacrimal surgery was performed for 14 eyes in 11 children. Dacryoscopy examinations and probing were performed in a total of 59 eyes in 46 children between the ages of 1 and 12 years old (mean 57.8 ± 55.0 months) during the study period. We obtained approval for this study from our Institutional Review Board. Informed consent was obtained from a guardian of each child.

We performed dacryoscopy under general anesthesia at a surgical facility using a commercial scope (RUIDO FT-203F MD10 [10000 elements]; FiberTech Co., Ltd., Tokyo, Japan). The scope consisted of a probe with an outer diameter of 0.9 mm (20-gauge) and a viewing angle of 60°. The images were displayed on a monitor. After the dilatation of the punctum, a dacryoscopy probe was inserted through the punctum into the lacrimal duct. Saline was injected through the water channel to obtain a better view.

* Corresponding author. Department of Ophthalmology, Kanagawa Children's Medical Center 2-138-4 Mutsukawa, Minami-ku, Yokohama 232-8555, Japan.

E-mail address: kcmceycare@gmail.com (N. Matsumura).

2.1. Findings

2.1.1. Case report 1

A 20-month-old girl with epiphora and mucopurulent discharge from her right eye since infancy visited for a consultation. She had never undergone either lacrimal duct probing or irrigation. She did not have either a systemic syndrome or a family history of lacrimal duct obstruction. A fluorescein disappearance test demonstrated a delayed clearance in the right eye. We diagnosed her as having CNLDO. A dacryocystography was performed under general anesthesia, and a position of obstruction located at the distal end of the nasolacrimal duct was identified (Fig. 1A).

Dacryoscopic images of the obstruction revealed an obstruction with a smooth and slightly concave surface that was slightly reddish and dark in color (Fig. 1B). We perforated the obstruction using the tip of the dacryoscope. Because the obstruction was membranous, it was relatively easy to perforate. After perforation, a slit-shaped opening in the nasolacrimal duct was visible (Fig. 1C and D).

2.1.2. Case report 2

A 9-year-old boy with epiphora and mucopurulent discharge from his right eye was seen as a consultation. His symptoms began after an epidemic keratoconjunctivitis (EKC) infection, which he experienced at the age of 4 years. The virus responsible for the keratoconjunctivitis had been confirmed using a SAS™ Adeno Test. He had never undergone either lacrimal duct probing or irrigation. A fluorescein disappearance test demonstrated a delayed clearance in the right eye. We diagnosed him as having acquired lacrimal duct obstruction secondary to an adenoviral infection. A dacryocystographic image showed an obstruction was located in the proximal nasolacrimal duct (NLD) (Fig. 2A). The dacryoscopic examination revealed a membranous obstruction that was slightly reddish and dark in color at the proximal NLD (Fig. 2B). We perforated the membranous obstruction using the tip of the dacryoscope. After perforation, a normal lumen in the nasolacrimal duct with multiple mucous folds was visible (Fig. 2C).

2.1.3. Case report 3

An 8-year-old boy with Down syndrome and epiphora and mucopurulent discharge from his right eye was seen as a consultation. His symptoms had started at the age of 4 years, without any trigger. He had not undergone either lacrimal duct probing or irrigation. A fluorescein disappearance test demonstrated a delayed clearance in the right eye. We diagnosed him as having primary acquired lacrimal duct obstruction with dacryocystitis. A dacryocystographic image showed a proximal nasolacrimal duct with a tapered appearance (Fig. 3A). The lacrimal duct was examined

using a dacryoscope, and the lumen was found to be covered with white widespread fibrotic tissue (Fig. 3B). A dimple was present at the distal end of the obstruction (Fig. 3C). We perforated the dimple and attempted to remove the white fibrotic tissue but were unable to remove all the tissue (Fig. 3D). The diffuse fibrous obstruction was continued from the proximal end to the distal end of the nasolacrimal duct.

3. Discussion

High-resolution dacryoscopy allows a clearer visualization of the lumen of entire lacrimal drainage system, leading to an understanding of specific details of the pediatric lacrimal duct obstructions. This is the first report to describe the findings of pediatric lacrimal duct obstructions arising from diverse causes, as evaluated using a high-resolution dacryoscope. Dacryoscopy enabled successful and safe examinations of pediatric lacrimal duct obstruction in all the cases. The findings for typical CNLDO, as described above, were consistent with previous histological reports [3,4]. Findings revealing simple CNLDO were observed in 27 of the 59 eyes (46%) in our dacryoscopic examination. In East Asia, acquired lacrimal duct obstruction in children is most commonly caused by EKC [8,9]. The location of membranous obstruction in patients with acquired lacrimal duct obstruction secondary to viral infection was revealed to be different from that of typical CNLDO. In children with Down syndrome, complicated lacrimal outflow abnormalities have been reported [10–13]. No observations of lacrimal ducts using dacryoscopy have been reported in this patient population. Widespread obstruction of the NLD is a rare finding in pediatric patients and may be caused by chronic inflammation.

The present study revealed that various types of lacrimal duct obstruction, other than typical CNLDO, are not uncommon in the pediatric population. Sasaki T. and colleagues classified primary NLDO in adults based on the site of obstruction, as evaluated using dacryoscopy [14]. They suggested that differences in the sites of obstruction may be related to differences in the etiologies. Dacryoscopy might be useful for understanding differences in the etiology of obstructions, leading to the selection of preferred surgical procedures based on the endoscopic findings. Previously reported studies showed that a significant percentage of pediatric DCR cases had an etiology other than typical CNLDO [15]. Our study revealed that dacryoscopy was very helpful for diagnosing the features of pediatric lacrimal duct obstruction, enabling the selection of patients with simple NLDO who could be treated with probing with or without the placement of a stent and the selection of other patients requiring DCR. Although an initial investment is necessary to perform dacryoscopy, specific disposable

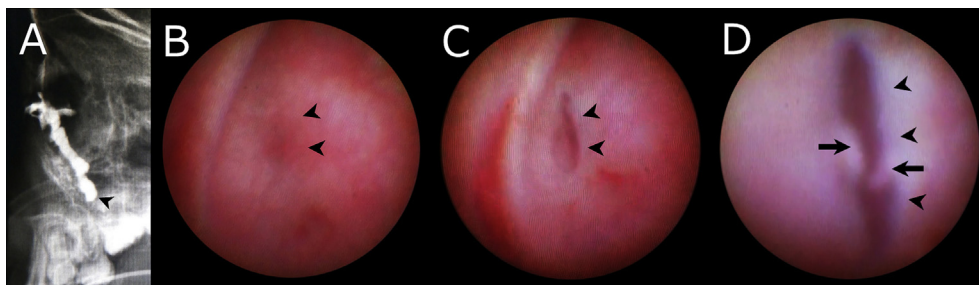


Fig. 1. Findings for a typical congenital nasolacrimal duct obstruction (Case1). **A**, Dacryocystographic image (lateral view). The obstruction was located at the distal end of the nasolacrimal duct (NLD) (arrowhead). **B**, Dacryoscopic image before perforation. A membranous obstruction that was dark in color (arrowhead) is visible. **C**, Dacryoscopic image obtained after perforation. An opening of the NLD is visible (arrowhead). **D**, Region located closer to the opening of the NLD. A slit-shaped opening of the NLD (arrowhead) with a torn membrane (arrow) is visible.

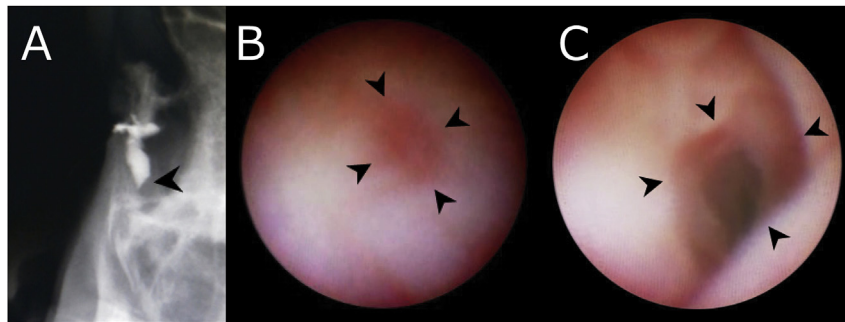


Fig. 2. Findings for a case of acquired NLDO caused by epidemic keratoconjunctivitis (Case 2). **A**, Dacryocystographic image (lateral view). The obstruction is located in the proximal NLD (arrowhead). **B**, Dacryoendoscopic image before perforation. A membranous obstruction with dark in color (arrowhead) is visible. **C**, Dacryoendoscopic image after perforation. A normal lumen in the NLD with multiple mucous folds is visible (arrowhead).

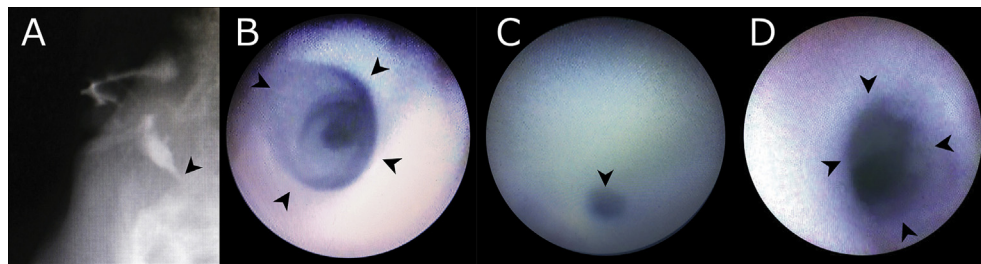


Fig. 3. Findings for a primary acquired lacrimal duct obstruction in a patient with dacryocystitis and Down syndrome (Case 3). **A**, Dacryocystographic image (lateral view). The obstruction is located in the proximal nasolacrimal duct (arrowhead). **B**, Dacryoendoscopic image of the obstruction site observed from the proximal side. Fibrous tissue gradually narrowing the nasolacrimal duct (arrowhead). **C**, Dacryoendoscopic image before perforation, located in the distal end of the obstruction. A dimple, representing the concave part of the fibrous obstruction, is visible (arrowhead). **D**, Dacryoendoscopic image after perforation. The inner wall is still coated with white fibrous tissue (arrowhead).

supplies are not required. Direct observation of the lacrimal lumen during probing is likely to enable greater precision, thus enabling, more successful and safer probing. Improving the success rate of probing and appropriate case selection for DCR should enable the overall, cost-effectiveness of this procedure to be realized.

Because the diameter of a dacryoendoscope is relatively small, the image quality is limited, even when a high-resolution endoscope is used. However, further improvements in instrumentation as technology progresses may enable more accurate examinations of the lacrimal duct lumen, and the further accumulation of cases is necessary.

4. Conclusions

High-resolution dacryoendoscopy enables a clearer visualization of pediatric lacrimal duct obstructions, leading to an improved understanding of their features. The dacryoendoscopy revealed that different etiologies of NLDO exhibit different visible pathologies.

References

- [1] J.D. Young, C.J. MacEwen, Managing congenital lacrimal obstruction in general practice, *BMJ* 315 (1997) 293–296, <http://dx.doi.org/10.1136/bmj.315.7103.293>.
- [2] M.K. Kapadia, S.K. Freitag, J.J. Woog, Evaluation and management of congenital nasolacrimal duct obstruction, *Otolaryngol. Clin. North Am.* 39 (2006) 959–977, <http://dx.doi.org/10.1016/j.otc.2006.08.004>.
- [3] D. Sevel, Development and congenital abnormalities of the nasolacrimal apparatus, *J. Pediatr. Ophthalmol. Strabismus* 18 (5) (1981) 13–19.
- [4] J.V. Cassaday, Developmental anatomy of nasolacrimal duct, *AMA Arch. Ophthalmol.* 47 (1952) 141–158.
- [5] H. Sasaki, T. Takano, A. Murakami, Direct endoscopic probing for congenital lacrimal duct obstruction, *Clin. Exp. Ophthalmol.* 41 (2013) 729–734, <http://dx.doi.org/10.1111/ceo.12108>. Epub 2013 Apr 29.
- [6] K. Mullner, E. Bodner, G.E. Mannor, Endoscopy of the lacrimal system, *Br. J. Ophthalmol.* 83 (1999) 949–952, <http://dx.doi.org/10.1136/bjo.83.8.949>.
- [7] K. Kato, K. Matsunaga, Y. Takashima, et al., Probing of congenital nasolacrimal duct obstruction with dacryoendoscope, *Clin. Ophthalmol.* 8 (2014) 977–980, <http://dx.doi.org/10.2147/OPTH.S60377> eCollection 2014.
- [8] K. Nagashima, “Silicone-octopus repair” of lacrimal obstruction in children, *Ophthalmic Surg.* 14 (1983) 766–769.
- [9] K.Y. Kay, K.I. Woo, J.H. Kim, et al., Acquired nasolacrimal duct obstruction in children, *Jpn. J. Ophthalmol.* 51 (2007) 437–441, <http://dx.doi.org/10.1007/s10384-007-0478-6>.
- [10] D.K. Coats, K.M. MaCreery, D.A. Plager, et al., Nasolacrimal outflow drainage anomalies in Down's syndrome, *Ophthalmol.* 110 (2003) 1437–1441, [http://dx.doi.org/10.1016/S0161-6420\(03\)00410-X](http://dx.doi.org/10.1016/S0161-6420(03)00410-X).
- [11] G.T. Lueder, Treatment of nasolacrimal duct obstruction in children with trisomy 21, *J. AAPOS* 4 (2000) 230–232, <http://dx.doi.org/10.1067/mpa.2000.105272>.
- [12] S.J.A. Yuen, C. Oley, T.J. Sullivan, Lacrimal outflow dysgenesis, *Ophthalmol.* 111 (2004) 1782–1790, <http://dx.doi.org/10.1016/j.ophtha.2004.02.011>.
- [13] G.D. Markowitz, L.F. Handler, J.A. Katowitz, Congenital euryblepharon and nasolacrimal anomalies in a patient with Down syndrome, *J. Pediatr. Ophthalmol. Strabismus* 31 (1994) 330–331.
- [14] T. Sasaki, Y. Nagata, K. Sugiyama, Nasolacrimal duct obstruction classified by dacryoendoscopy and treated with inferior meatal dacryorhinotomy. Part I: positional diagnosis of primary nasolacrimal duct obstruction with dacryoendoscope, *Am. J. Ophthalmol.* 140 (2005) 1065–1069, <http://dx.doi.org/10.1016/j.ajo.2005.07.038>.
- [15] A.Y. Nemet, A. Fung, P.A. Martin, et al., Lacrimal drainage obstruction and dacryocystorhinotomy in children, *Eye* 22 (2008) 918–924, <http://dx.doi.org/10.1038/sj.eye.6702769>.