

Original Article

Feasibility and accuracy of a new mobile electrocardiography device, ER-2000[®], in the diagnosis of arrhythmia



Yae Min Park^a, Dae In Lee^b, Hwan Cheol Park^c, Jaemin Shim^b, Jong-Il Choi^b,
Hong Euy Lim^b, Sang Weon Park^b, Young-Hoon Kim, MD^{b,*}

^a Cardiology Division, Gachon University Gil Medical Center, Incheon, Republic of Korea

^b Cardiology Division, Korea University Anam Hospital, Seoul, Republic of Korea

^c Cardiology Division, Hanyang University Guri Hospital, Guri, Republic of Korea

ARTICLE INFO

Article history:

Received 25 September 2014

Received in revised form

1 December 2014

Accepted 10 December 2014

Available online 13 January 2015

Keywords:

Arrhythmia

ER-2000[®]

12-Lead electrocardiogram (ECG)

ABSTRACT

Background: We performed this study to evaluate the feasibility and accuracy of a new mobile electrocardiography (ECG) device, ER-2000[®], in detecting cardiac arrhythmia, by comparing it to a 12-lead ECG used as the gold standard.

Methods: Mode 1 of ER-2000[®] was recorded using three electrodes with cables attached to the anterior chest wall, and mode 2 was recorded using the side chest channel and finger channel. Standard 12-lead ECG was used to record with a speed of 25 mm/s, simultaneously.

Results: Seventeen patients with complaints of palpitation were enrolled. Twelve-lead ECG revealed normal sinus rhythm in three patients, sinus tachycardia in one, atrial fibrillation (AF) in two, atrial tachycardia (AT) in one, first degree atrioventricular block in one, pacing rhythm in two patients who underwent permanent pacemaker implantation, AF with intermittent ventricular pacing in one, complete right bundle branch block in one, J-wave elevation in one, narrow QRS tachycardia in one, atrial premature beat (APB) in one, ventricular premature beat (VPB) in one, and narrow QRS tachycardia with intermittent aberrant conduction in one. Rhythm diagnosis obtained by the two different modes of ER-2000[®] was correlated with that obtained by the 12-lead ECG in all patients except in one in whom ER-2000[®] showed one APB while 12-lead ECG showed sinus rhythm. R-R interval was accurately recorded despite the detailed morphology of QRS, and T-wave was somewhat modified with the use of ER-2000[®]. A pacing blip detected by 12-lead ECG was not detected by ER-2000[®] despite a similar wide QRS duration in the paced QRS.

Conclusions: A rhythm strip obtained using ER-2000[®] is accurate in diagnosing arrhythmia, despite some differences in the detailed morphology of the QRS and T-wave, and the pacing spike compared to those obtained by the 12-lead ECG.

© 2015 Japanese Heart Rhythm Society. Published by Elsevier B.V. All rights reserved.

1. Introduction

Cardiac arrhythmia is a serious heart condition causing morbidity and mortality. Twelve-lead electrocardiography (ECG) remains the gold standard for the diagnosis of arrhythmias. However, intermittent arrhythmia may not be detected using standard ECG. Twenty-four-hour to 7-day Holter monitoring increases the chance of arrhythmia diagnosis [1], and implantable loop recorders are especially suitable for identifying undetected sources of a suspected cardiac syncope or arrhythmia when cardiac events are infrequent

[2,3]. However, limitations exist, delaying both the diagnosis of arrhythmia and treatment decisions.

ER-2000[®] (Boryung Soo & Soo Ltd., Seoul, Republic of Korea) is a portable wireless ECG monitor that provides a real-time rhythm strip by two different methods. We performed this study to evaluate the feasibility and accuracy of ER-2000[®] in the remote detection of arrhythmia by comparing it to the current gold standard, 12-lead ECG. We hypothesized that the arrhythmia detection rate using ER-2000[®] is comparable to that of a 12-lead ECG.

2. Materials and methods

2.1. Patients

Seventeen patients with complaints of palpitation were enrolled in this study.

* Correspondence to: Division of Cardiology, Korea University Medical Center, 126-1 Anam-Dong 5Ga, Seongbuk-Gu, Seoul 136-705, Republic of Korea.
Tel.: +82 2 920 5445; fax: +82 2 927 1478.

E-mail address: yhkim@unitel.co.kr (Y.-H. Kim).

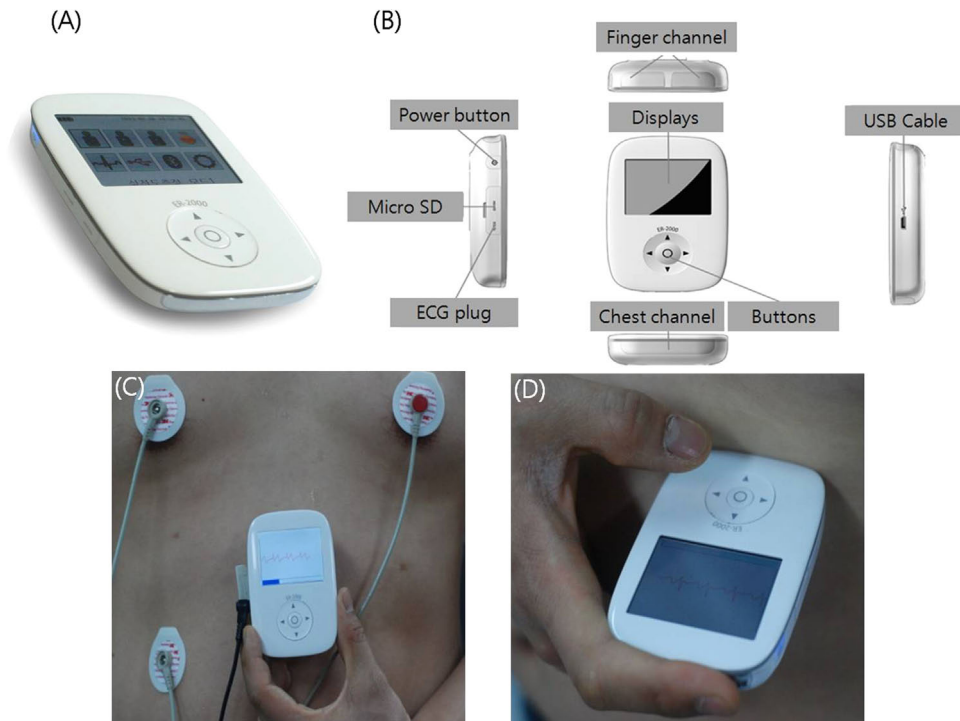


Fig. 1. The mobile ECG device, ER-2000[®] is a pocket sized ($64 \times 95 \times 22 \text{ mm}^3$), battery-powered device that weighs 106 g (A). Detailed structure and composition of ER-2000[®]; (B) mode 1 is recorded using three ECG electrodes that are attached to the anterior chest wall (C), and mode 2 is recorded using side chest channel and finger channel (D). ECG=electrocardiography.

2.2. ER-2000[®] and 12-lead electrocardiography analysis

The mobile ECG device ER-2000[®] is a pocket-sized ($64 \times 95 \times 22 \text{ mm}^3$), battery-powered device that weighs 106 g (Fig. 1A and B). There are two different modes for recording an ECG rhythm strip with the ER-2000[®]. Mode 1 uses three ECG electrodes that are attached to the anterior chest wall (Fig. 1C), and mode 2 uses the side chest channel and finger channel (Fig. 1D). The data obtained can be transmitted by USB cable, micro SD, or Bluetooth. The ER-2000[®] can record a real-time continuous cardiac rhythm strip for up to 2500 h. In this study, patients were instructed to push the record button when they believed they were experiencing a cardiac symptom.

The standard 12-lead ECG data were recorded on a piece of paper at a speed of 25 mm/s simultaneously, and compared with that recorded by the ER-2000[®]. The rhythm strips obtained from the ER-2000[®] and the 12-lead ECG were read in random order by two independent investigators who were blinded to patients' medical history and clinical characteristics, and rhythm status was compared. From the 12-lead ECG data, one lead with the most similar QRS vector and amplitude was chosen to compare the detailed morphologies of P, QRS, and T-wave with those obtained by mode 1 of ER-2000[®].

2.3. Statistical analysis

The primary endpoint was the diagnosis of arrhythmia, or rhythm status, using the ER-2000[®] compared with the 12-lead ECG. The secondary endpoints included consistency of obtained data in the heart rate, R-R intervals, and the morphologies and amplitudes of P, QRS, and T-wave.

3. Results

Twelve-lead ECG revealed normal sinus rhythm in three patients, sinus tachycardia in one, atrial fibrillation (AF) in two,

atrial tachycardia (AT) in one, first degree atrioventricular block in one, pacing rhythm in two who underwent permanent pacemaker implantation, AF with intermittent ventricular pacing in one, complete right bundle branch block (RBBB) in one, J-wave elevation in one, narrow QRS tachycardia in one, atrial premature beat (APB) in one, ventricular premature beat (VPB) in one and narrow QRS tachycardia with intermittent aberrant conduction in one. Significant findings comparing the data obtained by ER-2000[®] and 12-lead ECG are summarized in Table 1.

The accuracy of rhythm diagnosis obtained by the two different modes of ER-2000[®] was accurate compared to that obtained by the 12-lead ECG in all patients, except in patient 3 in whom ER-2000[®] showed one APB while 12-lead ECG showed sinus rhythm (Fig. 2). P-wave was clearly identified by using ER-2000[®] and the morphology was similar with that in the 12-lead ECG in most cases. Even fibrillatory wave was well matched in patients with AF (Fig. 3). AT can also be diagnosed correctly by inverted P-wave morphology obtained by using ER-2000[®]. The P-wave was inverted in II, III, and aVF, and positive in aVR and aVL in patient 7 who showed atrial tachycardia on 12-lead ECG. The P-wave was also clear and inverted in mode 1 of ER-2000[®]. Unfortunately, AT was terminated during recording by mode 2 of ER-2000[®] (Fig. 4). However, P-wave was unclear in mode 1 and mode 2 of ER-2000[®] while first degree AV block was shown in patient 8 on 12-lead ECG (see online Supplementary Fig. S1). Therefore, the diagnosis of a first degree AV block might be missed on ER-2000[®].

Lead II (35.3%) followed by lead V4 (23.5%) among 12 leads showed the most similar QRS pattern with the rhythm strip obtained using mode 1 of ER-2000[®]. QRS morphology was usually similar; however, amplitude of R- or S-waves was different in four patients. Paced QRS duration was similar and notching was present in both methods; however, QRS polarity was different. Mode 1 of ER-2000[®] revealed rSR', qR, and QR patterns in patients with ventricular pacing rhythm (patients 9, 10, and 11, respectively), while 12-lead ECG revealed QS patterns in all patients. In addition, pacing spike was not visible on ER-2000[®]. A representative example

Table 1
Significant findings comparing ER-2000[®] and 12-lead ECG.

	Rhythm diagnosis		HR, R-R interval	Most similar QRS among 12 leads	P-wave morphology	QRS-morphology	T-wave morphology	Significant findings
	12-Lead ECG	ER-2000 [®]						
Pt. 1 (Fig. S3)	SR	SR	60 bpm, same	V4	Similar	Similar	Terminal portion of the T-wave was negatively inverted than the baseline in ER-2000 [®] .	
Pt. 2	SR	SR	78 bpm, same	V4	Similar	Similar	Similar	
Pt. 3 (Fig. 2)	SR	Mode 1; SR with APB Mode 2; SR	87 bpm, same except one APC in mode 1 of ER-2000 [®]	II	Similar	Similar	Similar	
Pt. 4	Sinus tachycardia	Sinus tachycardia	103 bpm, same	V4	P-wave onset was not clearly separated from the end of T-wave in ER-2000 [®] .	S-wave was deeper in ER-2000 [®] than lead V4 (6 mV vs. 3 mV).	Similar	
Pt. 5 (Fig. 3)	AF	AF	60 bpm, same	aVF	Similar fibrillatory wave was well observed in ER-2000 [®] .	The R-wave amplitude was similar but the S-wave was deeper than aVF (7.0 mV vs. 2.0 mV).	The terminal portion of T-wave in ER-2000 [®] was negatively inverted than the baseline.	
Pt. 6	AF	AF	93 bpm, same	V3	Similar fibrillatory wave was well observed in ER-2000 [®] .	Similar	The terminal portion of T-wave in ER-2000 [®] was negatively inverted than the baseline	
Pt. 7 (Fig. 4)	AT	Mode 1; AT Mode 2; SR	Mode 1; 95 bpm Mode 2; 54 bpm, same	aVL	The P-wave was inverted in mode 1 of ER-2000 [®] . The P-wave was inverted in II, III, and aVF, and positive in aVR and aVL.	Similar	Similar	
Pt. 8 (Fig. S1)	SR with 1st degree AV block	SR	97 bpm, same	V3	P-wave was not clearly identified in ER-2000 [®] .	R/S ratio was similar; however, the R (7 mV vs. 15 mV) and S (7 mV vs. 11 mV) amplitudes were smaller than V3.	The terminal portion of T-wave was negatively inverted in mode 1 of ER-2000 [®]	The diagnosis of a 1st degree AV block can be missed in ER-2000 [®] because of unclear p-wave.
Pt. 9 (Fig. 5)	V pacing rhythm	V pacing rhythm	72 bpm, same	II	Similar	The paced QRS duration was similar. Both had similar notching; however, the morphology was rSR' in ER-2000 [®] while QS pattern in lead II.	T-wave morphology was different because of rSR' QRS pattern in ER-2000 [®] .	No pacing spike was seen before QRS wave in ER-2000 [®] .
Pt. 10	A and V pacing rhythm	A and V pacing rhythm	50 bpm, same	II	Similar	The paced QRS duration was similar; however, the morphology was qR in ER-2000 [®] while QS pattern in lead II.	T-wave was not well distinguished in mode 1 of ER-2000 [®] .	A and V pacing spike was not visible in ER-2000 [®] .
Pt. 11	AF with intermittent V pacing	AF with intermittent V pacing	104 bpm, same	V4	Similar fibrillatory wave was well observed in ER-2000 [®] .	Paced QRS morphology was QR in ER-2000 [®] while QS pattern in lead V4.	T-wave morphology was different because of QR morphology in ER-2000 [®] .	The pacing spike before the wide QRS morphology was not

Table 1 (continued)

	Rhythm diagnosis		HR, R-R interval	Most similar QRS among 12 leads	P-wave morphology	QRS-morphology	T-wave morphology	Significant findings
	12-Lead ECG	ER-2000 [®]						
Pt. 12 (Fig. S2)	SR with RBBB	Mode 1; SR with RBBB Mode 2; SR	58 bpm, same	V2	Similar	The morphology was Rs in ER-2000 [®] while Rsr' pattern in lead V2 despite similar QRS widening.	The ST-segment was elevated in ER-2000 [®] .	detected in ER-2000 [®] .
Pt. 13 (Fig. 6)	SR with J-wave elevation	SR with J-wave elevation	62 bpm, same	III	Similar	Similar	Similar	J-wave was much smaller than that of lead III (1.5 mV vs. 4.5 mV).
Pt. 14 (Fig. 7)	NQT	NQT	120 bpm, same	II	The P-wave was not well visualized in both methods.	The QRS duration and the R-wave amplitude were similar, but S (4 mV vs. 2 mV) wave was deeper than lead II. QRS alternans is obvious in both methods.	Similar	
Pt. 15	SR with frequent APBs	SR with frequent APBs	72 bpm, same	V4	The P-wave polarity was positive in ER-2000 [®] and positive in aVR and V1, while negative in lead II, III, and aVF. The P-wave in V4 was isoelectric. The P-wave in ER-2000 [®] was clearly visible when 12-lead ECG showed a clear P-wave during APBs.	Similar	T-wave amplitude was lower than V4 (3 mV vs. 6 mV) and terminal portion of the T-wave was negatively inverted than the baseline in ER-2000 [®] .	
Pt. 16 (Fig. 8)	SR with frequent VPBs	SR with frequent VPBs	76 bpm, same	II	Similar	Similar	The terminal portion of T-wave was negatively inverted in ER-2000 [®] during SR.	
Pt. 17 (Fig. S4)	NQT with intermittent aberrant conduction	NQT with intermittent aberrant conduction	120 bpm, same	II	The P-wave was suspected at the end of QRS-wave in both methods.	The aberrant conduction beat was obvious in both methods due to a wide QRS and different QRS morphology compared with the sinus beats.	Similar except after aberrant conduction	

A=atrial; AF=atrial fibrillation; APB=atrial premature beat; AT=atrial tachycardia; AV=atrioventricular; ECG=electrocardiography; NQT=narrow QRS tachycardia; Pt=patient; RBBB=right bundle branch block; SR=sinus rhythm; V=ventricular; VPB=ventricular premature beat.

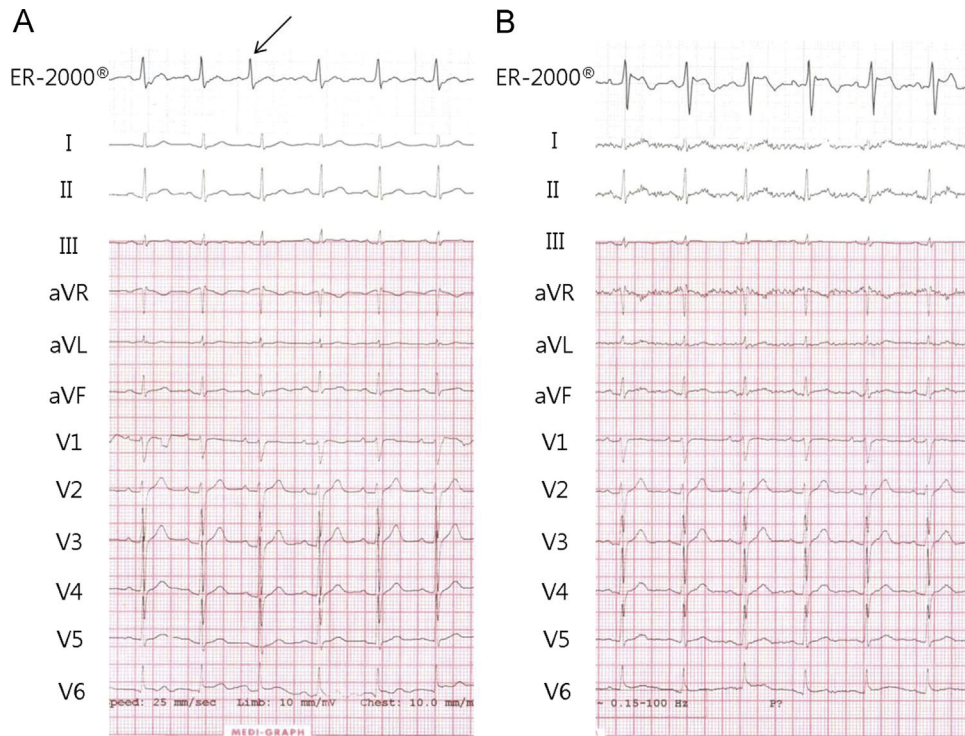


Fig. 2. Twelve-lead ECG and rhythm strip obtained by mode 2 (B) reveal sinus rhythm, while mode 1 (A) of ER-2000[®] shows one APB (arrow) in patient 3. APB=atrial premature beat; ECG=electrocardiography.

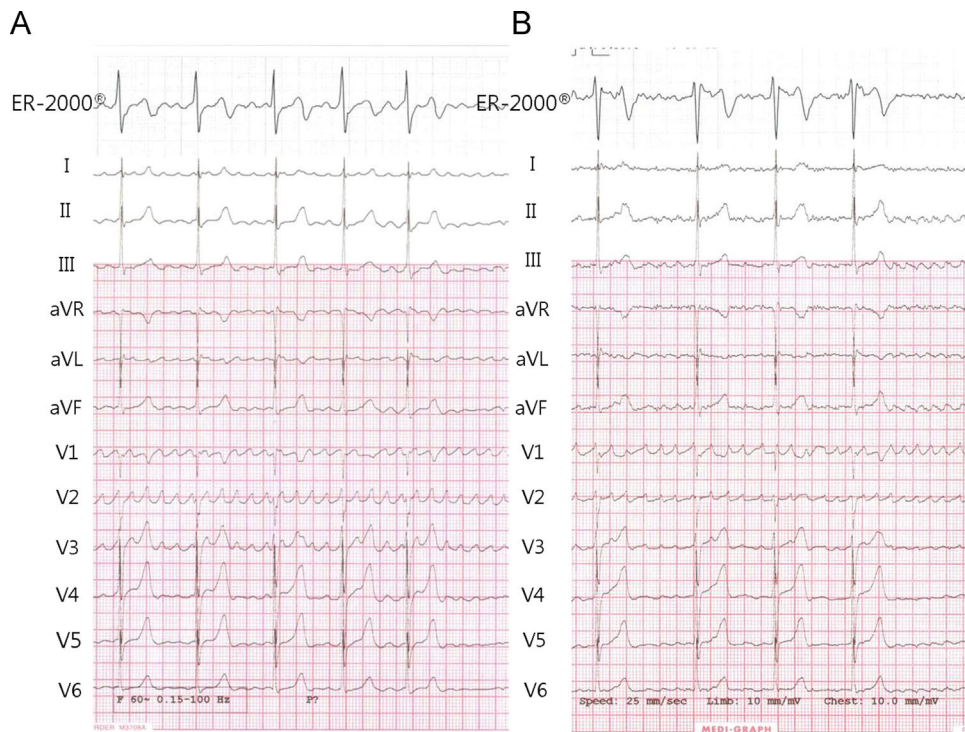


Fig. 3. Twelve-lead ECG shows AF rhythm. Both rhythm strips obtained by mode 1 (A) and mode 2 (B) of ER-2000[®] reveal similar fibrillatory wave with same R-R intervals in patient 5. AF=atrial fibrillation; ECG=electrocardiography.

of ventricular pacing rhythm is shown in Fig. 5. This patient (patient 9) underwent implantation of VVI mode pacemaker and 12-lead ECG showed ventricular pacing rhythm with dissociated P-wave. In patients with RBBB (patient 12), the rhythm strip obtained using

mode 1 of ER-2000[®] revealed similar QRS widening; however, the rhythm strip obtained by mode 2 of ER-2000[®] did not show definite QRS widening. The morphology was Rs in mode 1 of ER-2000[®] but Rsr' pattern in lead V2 despite similar QRS widening

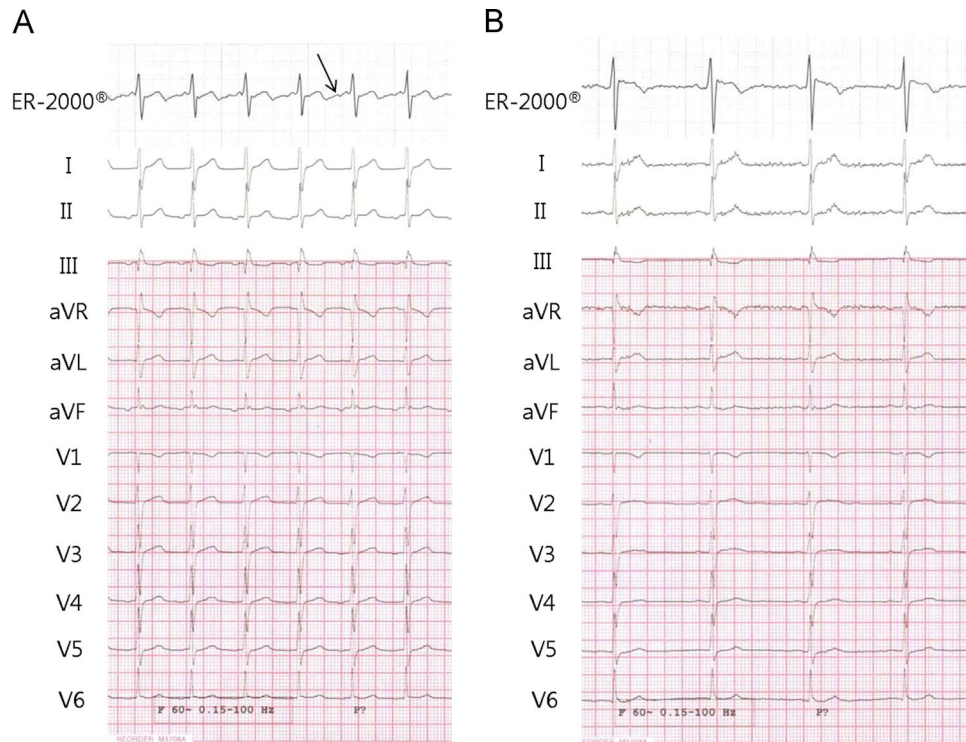


Fig. 4. Twelve-lead ECG shows sinus rhythm with ectopic P-wave and rhythm strip obtained by mode 1 (A) of ER-2000[®] reveals clear and inverted P-wave (arrow) in patient 7. Atrial tachycardia was terminated during taking rhythm strip by mode 2 of ER-2000[®] (B). AT=atrial tachycardia; ECG=electrocardiography.

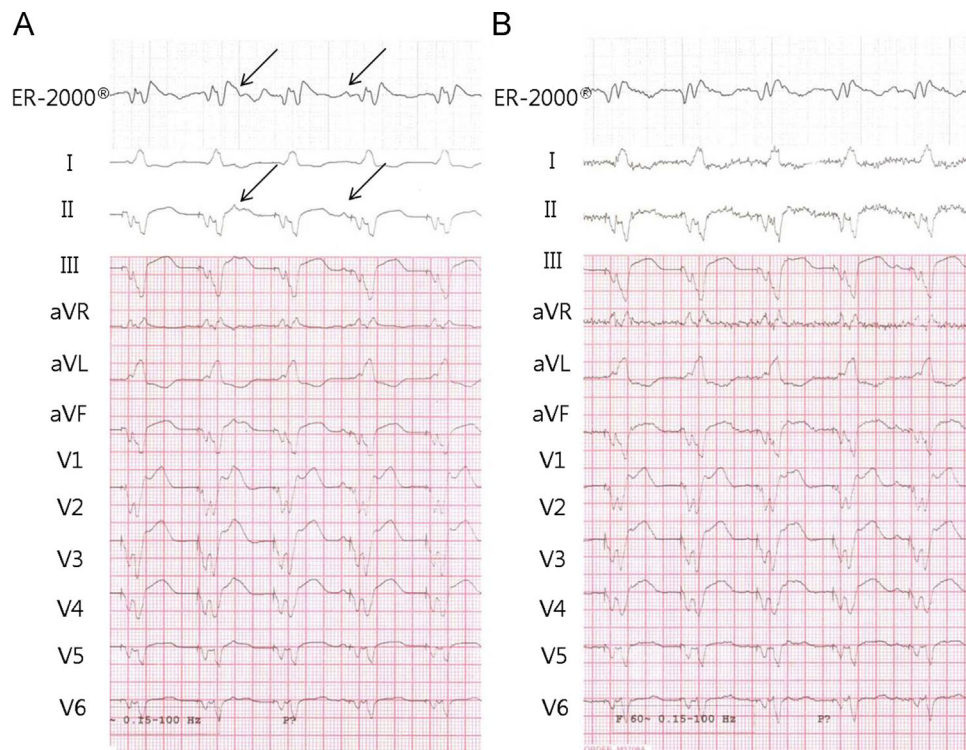


Fig. 5. Twelve-lead ECG shows ventricular pacing rhythm with dissociated P-waves (arrows) in patient 9. Both rhythm strips obtained by mode 1 (A) and mode 2 (B) of ER-2000[®] show similar wide QRS duration, and both have similar notching; however, the morphology is rSR' in ER-2000[®] and QS pattern in lead II. The pacing spike is not visible in ER-2000[®]. ECG=electrocardiography.

(see online [Supplementary Fig. S2](#)). J-wave elevation was obviously observed in mode 1 of ER-2000[®]; however, the J-wave was much smaller than that of lead III (1.5 mV vs. 4.5 mV). J point elevation

was significant in lead III (4.5 mV), but not observed on using ER-2000[®]. The rhythm strip obtained by using mode 2 of ER-2000[®] showed incomplete RBBB with coved-type ST elevation such as the

Brugada pattern (Fig. 6). The R-R interval was accurate in patients with narrow QRS tachycardia with a heart rate of 120 beats per minute and QRS alternans is obvious in data obtained by both

methods (Fig. 7). Coupling interval of VPB obtained using both methods was the same and VPB was differentiated from sinus rhythm by wide QRS morphology (Fig. 8).

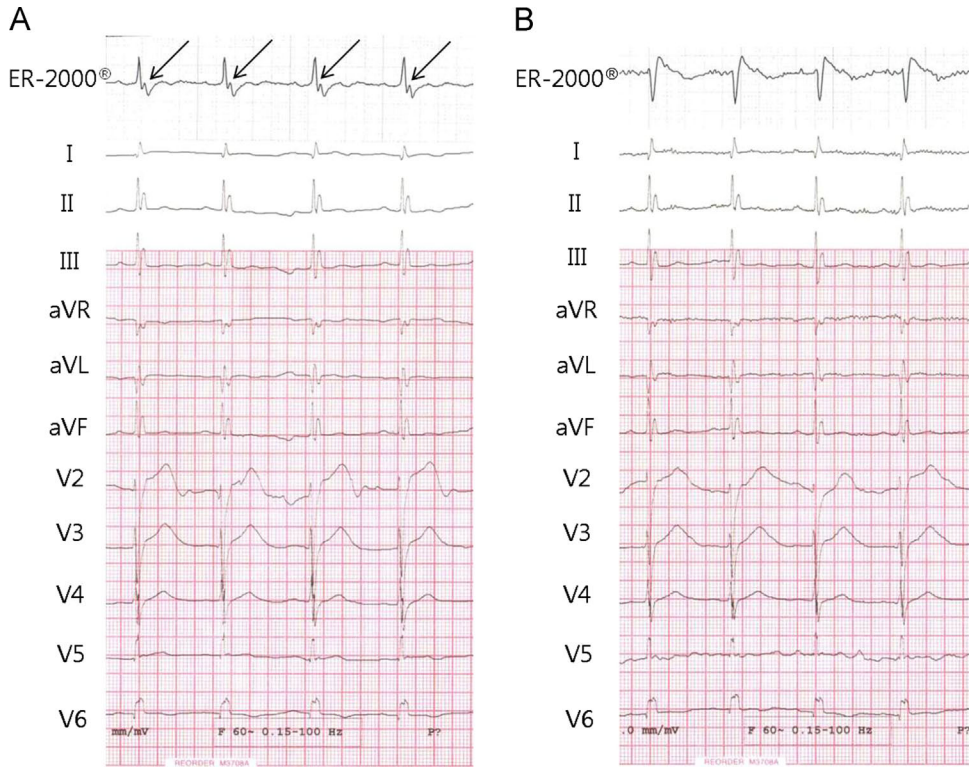


Fig. 6. Twelve-lead ECG shows sinus rhythm with significant J-wave elevation in inferior leads in patient 13. The rhythm strip of mode 1 (A) also reveals J-wave elevation (arrows); however, the rhythm strip obtained by mode 2 (A) of ER-2000[®] shows incomplete right bundle branch block with coved type ST elevation such as Brugada pattern. ECG=electrocardiography.

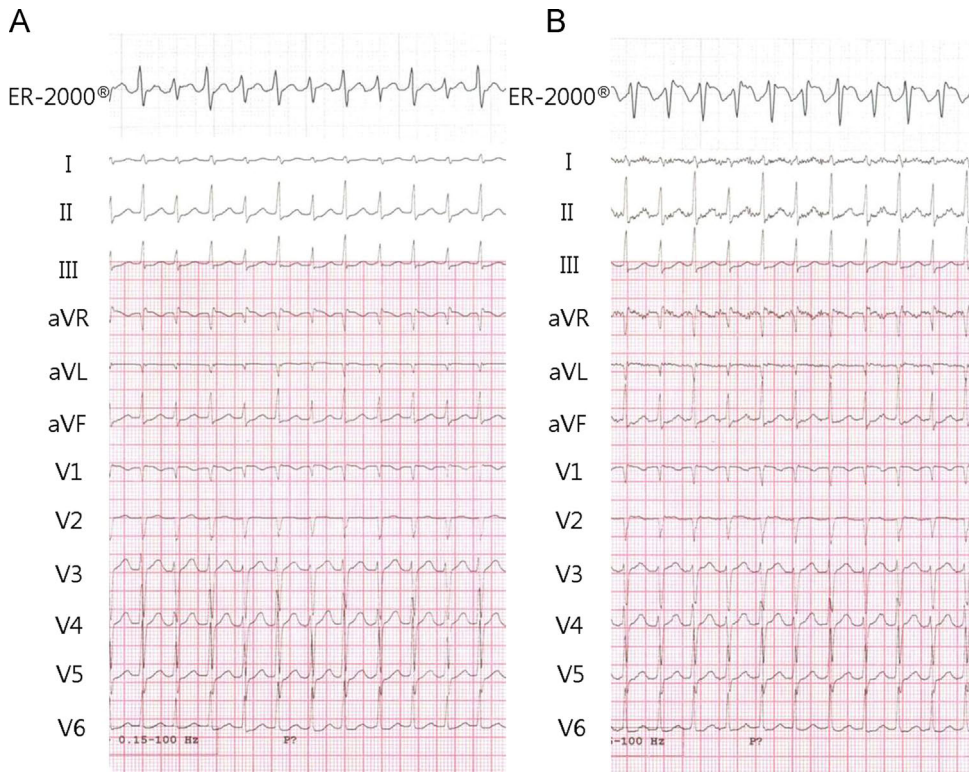


Fig. 7. Twelve-lead ECG shows narrow QRS tachycardia with a heart rate of 120 beats per minute. Rhythm strips obtained by mode 1 (A) and mode 2 (B) of ER-2000[®] reveal narrow QRS tachycardia with the same heart rate and R-R intervals in patient 14. QRS alternans is obvious in both methods. ECG=electrocardiography.

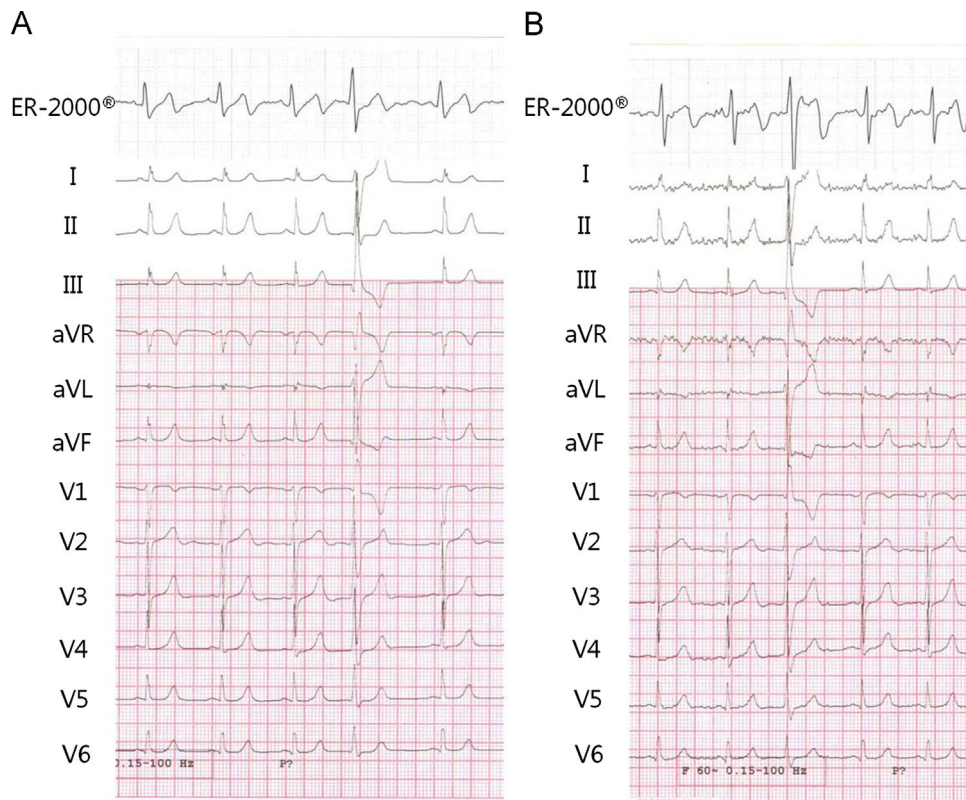


Fig. 8. Twelve-lead ECG shows sinus rhythm with frequent VPBs in patient 16. Both rhythm strips of mode 1 (A) and mode 2 (B) ER-2000[®] reveal the same heart rate and exact coupling interval of VPBs. ECG=electrocardiography; VPBs=ventricular premature beats.

T-wave was similar in seven patients. The terminal portion of the T-wave was negatively inverted compared with that at baseline in five patients on using ER-2000[®]. Representative example of sinus rhythm with T-wave discordance is shown in online [Supplementary Fig. S3](#). T-wave morphology was different after wide QRS complex, which resulted from pacing or bundle branch block or aberrant conduction, because the polarity of wide QRS complex was usually different (see online [Supplementary Fig. S4](#)).

4. Discussion

This study demonstrates that the accuracy of remote arrhythmia detection by ER-2000[®] is comparable to that of the standard 12-lead ECG. Lead II followed by lead V4 of the 12 leads are most comparable to the rhythm strip obtained by mode 1 of ER-2000[®]. However, the pacing blip was not well visualized. The exact QRS amplitude and T-wave morphology are modified especially after wide QRS complex compared to those of 12-lead ECG.

ER-2000[®] has significant potential advantages over the conventional methods of detecting arrhythmia. Conventional methods include 12-lead ECG, Holter ECG, and other event monitoring systems. With ER-2000[®], patients can carry the device with them and record rhythm strip conveniently and quickly whenever they experience symptoms related to cardiac arrhythmia. As such, the system has strong potential to increase the probability of detecting arrhythmias and help with disease management. Twenty-four-hour Holter monitoring has increasingly been utilized as a routine investigation for occult paroxysmal AF in patients with stroke and transient ischemic attack. However, its clinical utility remains controversial because the reported yield of 24-h Holter monitoring for detection of paroxysmal AF varies widely with ranges from 1% to 12% [1,4,5]. Therefore, outpatient cardiac telemetry with monitoring > 21 days significantly increased the detection rate in a

previous study [6]. ER-2000[®] can record real-time continuous ECG data for up to 2500 h. A long-term remote ECG monitoring offered by ER-2000[®] allows clarification of symptoms suggestive for arrhythmia, including occult paroxysmal AF, increasing the detection rate.

Remote AF detection by a previously reported event recorder is predominantly accomplished by R-R interval analysis, because atrial signal recognition with conventional monitoring devices is difficult. As a result, some patients with organized AF or atrial flutter might be misdiagnosed. CardioBlip is a recently developed device using a portable wireless event recorder and provides signal reconstruction of a 12-lead waveform using 5 leads. Its potential for accurate assessment of atrial activity was demonstrated [7]. Furthermore, ER-2000[®] clearly visualized similar atrial activity during AF rhythm compared to 12-lead ECG, and P-wave was clearly shown even during AT or APBs. Additionally, there was good concordance with respect to ventricular activity, suggesting that ER-2000[®] is also useful in detecting ventricular arrhythmia. ER-2000[®] can record a cardiac rhythm strip more simply, and can even record without connecting electrodes. Although the ER-2000[®] provides only one rhythm strip, the detection rate of a rhythm status was excellent. Although QRS and T-wave morphologies were slightly different, it did not affect the diagnosis of arrhythmia.

The primary limitation of ER-2000[®] is that there is only one lead presentation. Therefore, we could not perform a lead-by-lead analysis, and only the most similar lead was selected for comparison. QRS voltages were somewhat higher in V2-4 leads than in mode 1 of ER-2000[®]. Some discrepancy in QRS vector and amplitude might result from the simple method of connecting only three electrodes at the anterior chest, and the difference in electrode position. However, there was good overall concordance in QRS morphology, QRS directionality, and QRS duration. Pacing spike was not well visualized; however, we detected a pacing rhythm with similar wide QRS morphology. Major representative

arrhythmias, including AF, AT, APBs, VPBs, and pacing rhythm that can cause palpitation, were well represented in both modes of ER-2000[®]. Most of all, we acquired 12-lead ECG and ER-2000[®] data simultaneously, allowing a direct comparison of the rhythm status. This pilot study demonstrates the accuracy and feasibility of ER-2000[®] in detecting arrhythmias. Limitations of the study include small sample size; however, we validated at least one case among each kind of major arrhythmias. Finally, while each mode of ER-2000[®] was recorded with 12-lead ECG simultaneously, modes 1 and 2 of ER-2000[®] had to, by definition, be taken separately.

ER-2000[®] provides the clinician with a rapid and accurate assessment of a patient's arrhythmia, improving clinical decision making and clinical outcomes. Further large-scale study is warranted to confirm the accuracy of ER-2000[®]. Furthermore, the efficacy and usefulness of ER-2000[®] should be examined under specific conditions, such as in patients with stroke or transient ischemic attack suspected to have paroxysmal AF, in diagnosing asymptomatic episodes of AF recurrence after catheter ablation, or for the diagnosis of arrhythmia causing syncope.

Conflict of interest

All authors and Boryung Soo & Soo Ltd. have no conflicts of interest.

Acknowledgments

This study was supported by a research grant from Boryung Soo & Soo Ltd., Seoul, Korea.

Appendix A. Supporting information

Supplementary data associated with this article can be found in the online version at <http://dx.doi.org/10.1016/j.joa.2014.12.003>.

References

- [1] Alhadramy O, Jeerakathil TJ, Majumdar SR, et al. Prevalence and predictors of paroxysmal atrial fibrillation on Holter monitor in patients with stroke or transient ischemic attack. *Stroke* 2010;41:2596–600.
- [2] Kabra R, Gopinathannair R, Sandesara C, et al. The dual role of implantable loop recorder in patients with potentially arrhythmic symptoms: a retrospective single-center study. *Pacing Clin Electrophysiol* 2009;32:908–12.
- [3] Zimetbaum P, Kim KY, Ho KK, et al. Utility of patient-activated cardiac event recorders in general clinical practice. *Am J Cardiol* 1997;79:371–2.
- [4] Koudstaal PJ, van Gijn J, Klootwijk AP, et al. Holter monitoring in patients with transient and focal ischemic attacks of the brain. *Stroke* 1986;17:192–5.
- [5] Rem JA, Hachinski VC, Boughner DR, et al. Value of cardiac monitoring and echocardiography in TIA and stroke patients. *Stroke* 1985;16:950–6.
- [6] Miller DJ, Khan MA, Schultz LR, et al. Outpatient cardiac telemetry detects a high rate of atrial fibrillation in cryptogenic stroke. *J Neurol Sci* 2013;324:57–61.
- [7] Vukajlovic D., Bojovic B., Hadzievski L. et al. Wireless remote monitoring of atrial fibrillation using reconstructed 12-lead ECGs. *Conf Proc IEEE Eng Med Biol Soc* 2010;2010:1113–18.