



Multiple hepatic sclerosing hemangioma mimicking metastatic liver tumor successfully treated by laparoscopic surgery: Report of a case



Masaki Wakasugi^{a,*}, Shigeyuki Ueshima^a, Mitsuyoshi Tei^a, Masayuki Tori^a, Ken-ichi Yoshida^b, Masahiko Tsujimoto^b, Hiroki Akamatsu^a

^a Department of Surgery, Osaka Police Hospital, Osaka, Japan

^b Department of Pathology, Osaka Police Hospital, Osaka, Japan

ARTICLE INFO

Article history:

Received 14 January 2015

Accepted 20 January 2015

Available online 21 January 2015

Keywords:

Hepatic sclerosing hemangioma

Laparoscopic liver resection

Metastatic liver tumor

ABSTRACT

INTRODUCTION: Hepatic sclerosing hemangioma is a very rare benign tumor, characterized by fibrosis and hyalinization occurring in association with degeneration of a hepatic cavernous hemangioma. We report here a rare case of multiple hepatic sclerosing hemangioma mimicking metastatic liver tumor that was successfully treated using laparoscopic surgery.

PRESENTATION OF CASE: A 67-year-old woman with multiple liver tumors underwent single-incision laparoscopic sigmoidectomy under a diagnosis of advanced sigmoid cancer with multiple liver metastases. Examination of surgical specimens of sigmoid colon revealed moderately differentiated adenocarcinoma invading the serosa, and no lymph node metastases. Serum levels of carcinoembryonic antigen and carbohydrate antigen 19-9 remained within normal limits throughout the course. Two months after sigmoidectomy, the patient underwent laparoscopic partial hepatectomy of S1 and S6 of the liver and cholecystectomy. Histopathological examination showed that the tumors mainly comprised hyalinized tissue and collagen fibers with sporadic vascular spaces on hematoxylin and eosin-stained sections, yielding a diagnosis of multiple hepatic sclerosing hemangioma. No evidence of recurrence has been seen as of 21 months postoperatively.

DISCUSSION: Differentiating multiple sclerosing hemangiomas from metastatic liver tumors was quite difficult because the radiological findings were closely compatible with liver metastases. Laparoscopic hepatectomy provided less blood loss, a shorter duration of hospitalization, and good cosmetic results.

CONCLUSION: Sclerosing hemangioma should be included among the differential diagnoses of multiple liver tumors in patients with colorectal cancer. Laparoscopic hepatectomy is useful for diagnostic therapy for undiagnosed multiple liver tumors.

© 2015 The Authors. Published by Elsevier Ltd. on behalf of Surgical Associates Ltd. This is an open access article under the CC BY-NC-ND license (<http://creativecommons.org/licenses/by-nc-nd/4.0/>).

1. Introduction

Hepatic sclerosing hemangioma is a very rare benign tumor, characterized by fibrosis and hyalinization occurring in association with degeneration of a hepatic cavernous hemangioma [1]. Because the radiological features can resemble those of hepatic malignancies such as metastatic liver cancer, intrahepatic cholangiocarcinoma (IHCC), or fibrolamellar hepatocellular carcinoma (FLC), definitive preoperative diagnosis may be difficult, particularly in cases showing multiple tumors. Laparoscopic hepatectomy has become a useful method of diagnostic therapy for patients with liver tumors with the progress of surgical techniques and laparoscopic devices [2]. We report here a rare case of multiple hepatic

sclerosing hemangioma mimicking metastatic liver tumor that was successfully treated using laparoscopic surgery.

2. Case presentation

A previously healthy 67-year-old woman presented with blood in the stool. Colonoscopy showed a type 2 sigmoid cancer. Examination of biopsy specimens revealed moderately differentiated adenocarcinoma. Serum levels of carcinoembryonic antigen (CEA) and carbohydrate antigen (CA)19-9 were 1.8 ng/mL and 5 U/mL, respectively. Computed tomography (CT) showed a ring-enhancing 28 mm exophytic lesion arising from S6 of the liver (Fig. 1a). No additional hepatic lesions were identified on CT. On dynamic contrast-enhanced magnetic resonance imaging (MRI), T1-weighted imaging showed a signal-hypointense mass in S6 (Fig. 1b). After contrast enhancement, the mass showed a similar enhancement pattern to that seen on dynamic CT. T2-weighted imaging showed a mass with heterogeneous signal intensity. A

* Corresponding author at: Department of Surgery, Osaka Police Hospital 10-31 Kitayama-cho, Ten-noujiku, Osaka, Osaka 543-0035, Japan. Tel.: +81 6 6775 6051; fax: +81 6 6775 6051.

E-mail address: wakasugi@oph.gr.jp (M. Wakasugi).

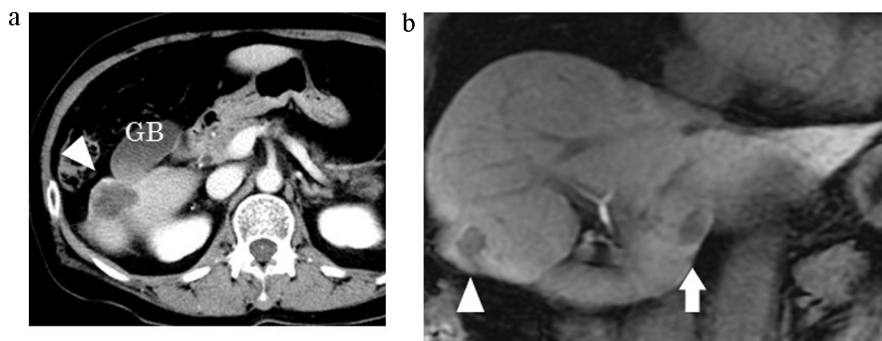


Fig. 1. Imaging results. (a) Computed tomography shows a ring-enhancing 28-mm exophytic lesion (arrowhead) arising from S6 of the liver. GB, gallbladder. (b) Contrast-enhanced magnetic resonance imaging shows a signal-hypointense mass in S6. A similar small nodule (arrow) is apparent in S1.

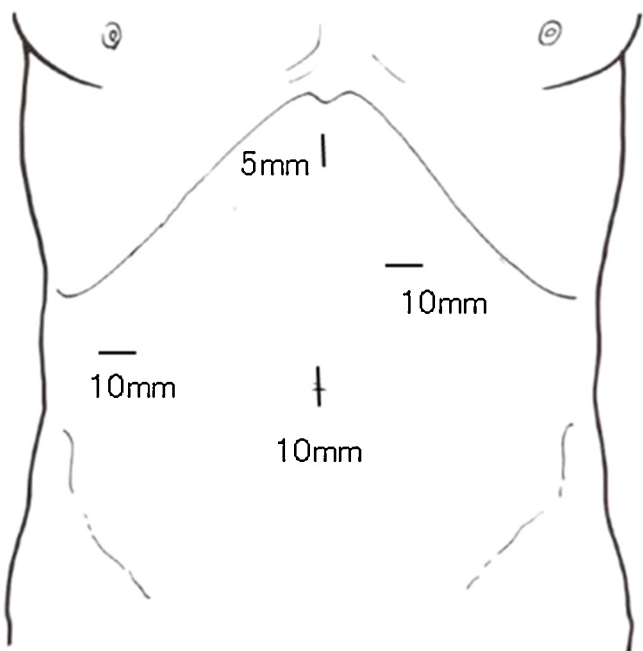


Fig. 2. Port site for laparoscopic surgery.

similar small nodule 11 mm in diameter was also detected in S1 (Fig. 1b). These findings led to a diagnosis of advanced sigmoid cancer with multiple liver metastases. The patient first underwent single-incision laparoscopic sigmoidectomy in April 2013. Examination of surgical specimens revealed moderately differentiated adenocarcinoma invading the serosa, with no lymph node metastases. Serum levels of CEA and CA19-9 remained within normal limits throughout the course. CT showed no changes in tumor size. In June 2013, the patient underwent laparoscopic partial hepatectomy

of S1 and S6, and cholecystectomy. She was placed in a supine position with legs apart. A 12 mm blunt tip trocar for a 10 mm flexible scope was placed at the umbilicus, through which carbon dioxide gas was delivered. Pneumoperitoneum was controlled to a pressure of 8 mm Hg. An additional three trocars were located as shown in Fig. 2. Intraoperative laparoscopic observation showed two well-demarcated, white tumors on the surface of S1 and S6 (Fig. 3). The lesser omentum was sectioned and the hepatoduodenal ligament was encircled by tape to be used as a tourniquet for complete interruption of blood inflow to the liver, only if necessary. After laparoscopic cholecystectomy was performed, partial hepatectomy of S1 and S6 was performed using laparoscopic coagulation shears, an ultrasound surgical aspirator, and a vessel-sealing device, considering the possibility that these liver tumors represented metastases from the sigmoid colon cancer. The operative time was 345 min. Blood loss was minimal. Histopathological examination showed that the tumors mainly comprised hyalinized tissue and collagen fibers with sporadic vascular space on sections stained with hematoxylin and eosin, yielding a diagnosis of multiple hepatic sclerosing hemangioma (Fig. 4). The postoperative course was uneventful and the patient was discharged on postoperative day 8. No evidence of recurrence has been seen during the 21 months of follow-up.

3. Discussion

The clinical course of this patient suggests two important clinical issues. First, sclerosing hemangioma should be included among the differential diagnoses of multiple liver tumors in patients with colorectal cancer. Sclerosing hemangioma is a rare type of hepatic hemangioma composed of abundant acellular hyalinized tissue in which small vessels are occasionally seen [1]. Only 17 resected cases, including the present case, with detailed information on patients with hepatic sclerosing hemangioma have been reported in the English literature (Table 1) [3–17]. To the best of our knowledge, this report is the first to describe multiple hepatic sclerosing

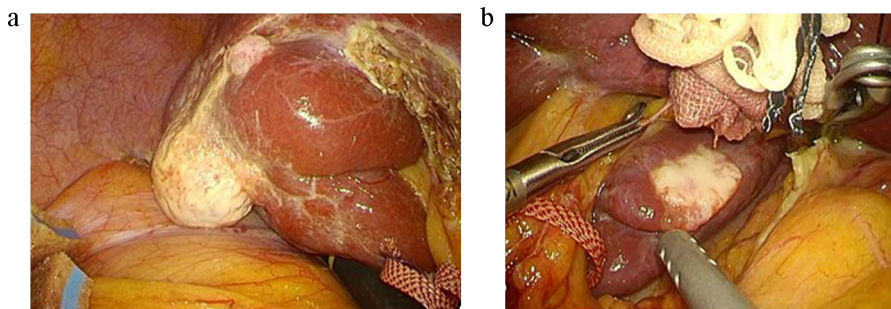


Fig. 3. Intraoperative laparoscopic observation. Two well-demarcated, white tumors are apparent on the surface of S6 (a) and S1 (b).

Table 1
Cases of resected hepatic sclerosing hemangioma in the English literature.

Year	Author	Age/sex	Location	Size (mm)	CT	MRI (T1/T2)	Preoperative diagnosis	Operation
1986	Takayasu et al. [3]	62 F	S6	50	RE	NA	NA	partial hepatectomy
1992	Haratake et al. [4]	65 F	S8	26	RE	NA	metastasis HCC	subsegmentectomy
1995	Cheng et al. [5]	NA	S7	30	RE	low/ Slightly high	malignant tumor	liver resection
1995	Shim et al. [6]	41 F	S5/6	130	Partly Filled in	NA	angiosarcoma	right lobectomy
2000	Yamashita et al. [7]	67 F	S4	50	RE	High/high	metastasis	partial hepatectomy
2001	Aibe et al. [8]	67 F	S4	40	Delayed Enhancement	High/high	metastasis	partial hepatectomy
2005	Lee et al. [9]	65 F	S5/6/7	55	RE	Low/moderate	HCC, IHCC, atypical hemangioma	right hemihepatectomy
2008	Mori et al. [10]	77 F	S5/6	95	RE	Low/high	IHCC FLC	right hepatectomy
2008	Choi et al. [11]	63 M	right lobe	45	Multifocal patchy Enhancement	low/ Intermediate	HCC, IHCC, atypical hemangioma	right lobectomy
2009	Lauder et al. [12]	72 M	S7	NA	Mild contrast Enhancement	NA	metastasis	partial hepatectomy
2009	Lauder et al. [12]	84 M	S4	NA	Hypodense	NA	metastasis	partial hepatectomy
2010	Jin et al. [13]	52 M	S6	21	RE	low/ Slightly high	HCC hemangioma	partial hepatectomy
2011	Papafragkakis et al. [14]	52 F	S6	75	Intralesional Enhancement	NA	NA	laparoscopic resection
2012	Yamada et al. [15]	75 M	S8	8	RE	Low Slightly high	metastasis	partial hepatectomy
2013	Song et al. [16]	63 F	S2/3	91	RE	NA	NA	lateral segmentectomy
2013	Shimada et al. [17]	63 M	S8	10	RE	Low Slightly high	atypical hemangioma metastasis, HCC	segmentectomy
2015	Wakasugi	67 F	S1, S6	11, 28	RE	Low/hetero	metastasis	laparoscopic

RE, ring enhancement. NA, not available. IHCC, intrahepatic cholangiocarcinoma. HCC, hepatocellular carcinoma. FLC, fibrolamellar hepatocellular carcinoma.

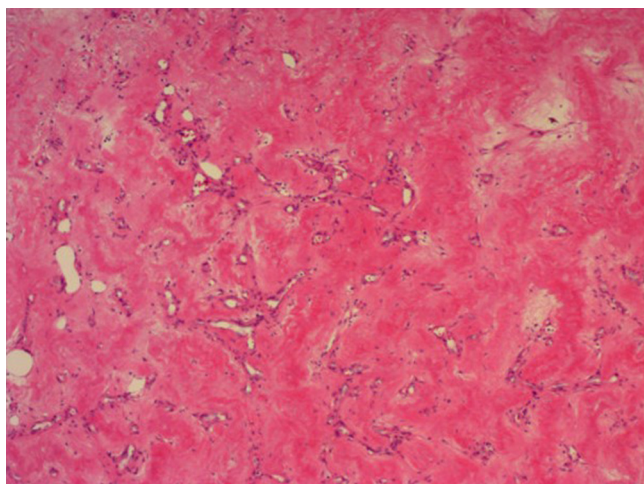


Fig. 4. Pathological examination. The tumors mainly comprise hyalinized tissue and collagen fibers with sporadic vascular spaces on sections stained with hematoxylin and eosin.

hemangiomas treated by laparoscopic surgery. A review of previously reported cases revealed that sclerosing hemangioma tends to occur more frequently in women than in men (6 men, 10 women), and occurs most frequently in middle to elder age, with a median age of 65 years (range, 41–84 years). Previous reports have shown no frequent location in the liver, with a median size of 42.5 mm (range, 8–130 mm). Enhanced CT showed the ring-like pattern of enhancement characteristic of adenocarcinoma in 11 (65%) of 17 cases. The MRI findings of sclerosing hemangioma were also very different from typical cavernous hemangioma, appearing low on T1-weighted imaging and high on T2-weighted imaging, categorized as non-specific, and still not excluding adenocarcinoma. Such radiological findings might lead to a preoperative diagnosis

of hypovascular adenocarcinoma, including metastatic liver cancer, hepatocellular carcinoma (HCC), IHCC, and FLC. In our case, differentiating the lesions from metastatic liver tumors was quite difficult, because the radiological findings were closely compatible with liver metastases and multiple tumors were evident. An elevated level of CEA in peripheral blood is a strong indicator of hepatic metastasis from colorectal cancer. Tartter et al. [18] described the sensitivity and specificity of CEA elevation to >5 ng/ml in patients with liver metastasis from colorectal cancer as 81% and 72%, respectively. Conversely, in our patient, the CEA level remained within normal limits during the course. PET/CT was not performed in this case, but could have detected the likely benign nature of this sclerosing hemangioma. The sensitivity and specificity of PET/CT in patients with recurrent colorectal cancer have been reported as 97% and 76%, respectively [19]. However, PET provides insufficient anatomical information, although this lack of information has improved with the integration of CT into PET. MRI provides additional accuracy to liver contrast-enhanced CT in the assessment of a patient's suitability for hepatic resection.

The second important clinical point is that laparoscopic hepatectomy is useful as a diagnostic therapy for undiagnosed multiple liver tumor. Fine-needle biopsy can differentiate sclerosing hemangioma from colorectal metastasis, but can potentially lead to rupture [20] or seeding of cancer cells. We believe that surgical resection of suspected colorectal metastases in the present patient was safe, and provided both a diagnosis and a solution to cancer therapy. With the progress of surgical techniques and devices, laparoscopic hepatectomy has become a realizable option for patients with liver tumors. Iwashashi et al. [2] reported that blood loss was significantly less with laparoscopic hepatectomy than with open hepatectomy, and the hospital stay with laparoscopic hepatectomy tended to be shorter. Regarding long-term outcomes, they found no significant differences in overall or disease-free survival between the laparoscopic and open hepatectomy groups. The pathological findings in this case indicate that our patient did not

need surgical intervention, but laparoscopic partial hepatectomy provided less blood loss, a shorter duration of hospitalization, and good cosmetic results, and also proved useful in diagnostic therapy.

4. Conclusion

Sclerosing hemangioma should be included among the differential diagnoses of multiple liver tumors in patients with colorectal cancer. Laparoscopic hepatectomy is useful for diagnostic therapy for undiagnosed multiple liver tumors.

Conflict of interest

Masaki Wakasugi and the other co-authors have no conflict of interest to declare.

Funding

None.

Ethical approval

Written informed consent was obtained from the patients for the information to be included in our manuscript. Her information has been de-identified to the best of our ability to protect his privacy.

Author contributions

Each author participated in writing the manuscript and all agreed to accept equal responsibility for the accuracy of the content of the paper.

References

- [1] N.A. Shepherd, G. Lee, Solitary necrotic nodules of the liver simulating hepatic metastases, *J. Clin. Pathol.* 36 (1983) 1181–1183.
- [2] S. Iwahashi, M. Shimada, T. Utsunomiya, S. Imura, Y. Morine, T. Ikemoto, et al., Laparoscopic hepatic resection for metastatic liver tumor of colorectal cancer: comparative analysis of short- and long-term results, *Surg. Endosc.* 28 (2014) 80–84.
- [3] K. Takayasu, N. Moriyama, Y. Shima, Y. Muramatsu, T. Yamada, M. Makuuchi, et al., Atypical radiographic findings in hepatic cavernous hemangioma: correlation with histologic features, *AJR Am. J. Roentgenol.* 146 (1986) 1149–1153.
- [4] J. Haratake, A. Horie, Y. Nagafuchi, Hyalinized hemangioma of the liver, *Am. J. Gastroenterol.* 87 (1992) 234–236.
- [5] H.C. Cheng, S.H. Tsai, J.H. Chiang, C.Y. Chang, Hyalinized liver hemangioma mimicking malignant tumor at MR imaging, *AJR Am. J. Roentgenol.* 165 (1995) 1016–1017.
- [6] K.S. Shim, J.M. Suh, Y.S. Yang, J.G. Kim, S.J. Kang, J.S. Jeon, et al., Sclerosis of hepatic cavernous hemangioma: CT findings and pathologic correlation, *J. Ko. Med. Sci.* 10 (1995) 294–297.
- [7] Y. Yamashita, M. Shimada, K. Taguchi, T. Gion, H. Hasegawa, T. Utsunomiya, et al., Hepatic sclerosing hemangioma mimicking a metastatic liver tumor: report of a case, *Surg. Today* 30 (2000) 849–852.
- [8] H. Aibe, H. Honda, T. Kuroiwa, K. Yoshimitsu, H. Irie, T. Tajima, et al., Sclerosed hemangioma of the liver, *Abdom. Imaging* 26 (2001) 496–499.
- [9] V.T. Lee, M. Magnaye, H.W. Tan, C.H. Thng, L.L. Ooi, Sclerosing haemangioma mimicking hepatocellular carcinoma, *Singapore Med. J.* 46 (2005) 140–143.
- [10] H. Mori, T. Ikegami, S. Imura, M. Shimada, Y. Morine, H. Kanemura, et al., Sclerosed hemangioma of the liver: report of a case and review of the literature, *Hepatol. Res.* 38 (2008) 529–533.
- [11] Y.J. Choi, K.W. Kim, E.Y. Cha, J.S. Song, E. Yu, M.G. Lee, Case report: sclerosing liver haemangioma with pericapillary smooth muscle proliferation: atypical CT and MR findings with pathological correlation, *Br. J. Radiol.* 81 (2008) e162–165.
- [12] C. Lauder, G. Garcea, H. Kanhere, G.J. Maddern, Sclerosing haemangiomas of the liver: two cases of mistaken identity, *HPB Surg.* (2009), <http://dx.doi.org/10.1155/2009/473591>.
- [13] S.Y. Jin, Sclerosed hemangioma of the liver, *Ko. J. Hepatol.* 16 (2010) 410–413.
- [14] H. Papafragkakis, M. Moehlen, M.T. Garcia-Buitrago, B. Madrazo, E. Island, P. Martin, A case of a ruptured sclerosing liver hemangioma, *Int. J. Hepatol.* (2011), <http://dx.doi.org/10.4061/2011/942360>.
- [15] S. Yamada, M. Shimada, T. Utsunomiya, Y. Morine, S. Imura, T. Ikemoto, et al., Hepatic sclerosed hemangioma which was misdiagnosed as metastasis of gastric cancer: report of a case, *J. Med. Invest.* 59 (2012) 270–274.
- [16] J.S. Song, Y.N. Kim, W.S. Moon, A sclerosing hemangioma of the liver, *Clin. Mol. Hepatol.* 19 (2013) 426–430.
- [17] Y. Shimada, Y. Takahashi, H. Iguchi, H. Yamazaki, H. Tsunoda, M. Watanabe, et al., A hepatic sclerosed hemangioma with significant morphological change over a period of 10 years: a case report, *J. Med. Case Rep.* 7 (2013) 139, <http://dx.doi.org/10.1186/1752-1947-7-139>.
- [18] P.I. Tartter, G. Slater, I. Gelernt, A.H. Aufses Jr., Screening for liver metastasis from colorectal cancer with carcinoembryonic antigen and alkaline phosphatase, *Ann. Surg.* 193 (1981) 357–360.
- [19] S. Dighe, H. Blake, M.D. Koh, I. Swift, A. Arnaout, L. Temple, et al., Accuracy of multidetector computed tomography in identifying poor prognostic factors in colonic cancer, *Br. J. Surg.* 97 (2010) 1407–1415.
- [20] Y.M. Shin, Sclerosing hemangioma in the liver, *Ko. J. Hepatol.* 17 (2011) 242–246.

Open Access

This article is published Open Access at sciedirect.com. It is distributed under the [IJSCR Supplemental terms and conditions](#), which permits unrestricted non commercial use, distribution, and reproduction in any medium, provided the original authors and source are credited.