

Contents lists available at [ScienceDirect](http://ScienceDirect.com)

## Journal of Pediatric Surgery CASE REPORTS

journal homepage: [www.jpascasereports.com](http://www.jpascasereports.com)

## GIST with a twist: An extra-luminal pedunculated gastric GIST presenting with tumor torsion and hemoperitoneum



Tiffany C. Kittmer<sup>a</sup>, Anna C. Shawyer<sup>b,\*</sup>, Jorge J. Zequeira<sup>b</sup>, Karen A. Bailey<sup>b</sup>

<sup>a</sup>McMaster University, Department of Surgery, Division of General Surgery, Hamilton, ON, Canada

<sup>b</sup>McMaster University, Department of Surgery, Division of Pediatric Surgery, McMaster Children's Hospital, Hamilton, ON, Canada

### ARTICLE INFO

#### Article history:

Received 27 June 2013

Received in revised form

24 July 2013

Accepted 24 July 2013

#### Key words:

Gastrointestinal stromal tumor

Hemoperitoneum

Tumor torsion

### ABSTRACT

Gastrointestinal stromal tumors (GIST) are rare mesenchymal tumors. Most present with nonspecific symptoms. We present a case of a 17-year-old male with sudden abdominal pain. Imaging revealed a hypodense mass inferior to the stomach. Serial blood work showed a decreasing hemoglobin level. In the operating room a pedunculated, torqued, hemorrhagic mass on the anterior surface of the stomach was resected. Pathology confirmed a GIST, c-kit positive with involved margins. The patient was started on imatinib. Pediatric GISTs are different than adult GISTs; the majority are c-kit negative (wild-type) and typically indolent. Despite a high recurrence rate, aggressive resection of pediatric GIST is generally not indicated. This pediatric GIST was c-kit and PDGFR exon 18 mutation positive and thus was treated according to the National Comprehensive Cancer Network (NCCN) guidelines (for adults).

© 2013 The Authors. Published by Elsevier Inc. Open access under [CC BY license](http://creativecommons.org/licenses/by/4.0/).

Gastrointestinal stromal tumors (GISTs) are mesenchymal tumors of the gastrointestinal tract derived from myenteric ganglion cells. They are rare in the pediatric population (1.4% of GISTs), typically affecting adults over 40 years of age [1]. GISTs occur most commonly in the stomach, but may be found anywhere along the gastrointestinal tract, mesentery or omentum. The most common pediatric presentation is anemia from gastrointestinal blood loss; other presentations include abdominal pain or an acute abdomen, distension, a palpable mass or an incidental finding on imaging [2,3].

### 1. Case report

A 17-year-old boy presented to the pediatric emergency department with non-bilious emesis and sudden onset, right-sided colicky abdominal pain radiating to the chest. His abdomen was diffusely tender but without signs of peritonitis. Blood-work revealed a leukocytosis of  $24.8 \times 10^9/L$  and a normal hemoglobin level (135 g/L). An abdominal ultrasound to rule out appendicitis demonstrated a large amount of complex ascites. A subsequent

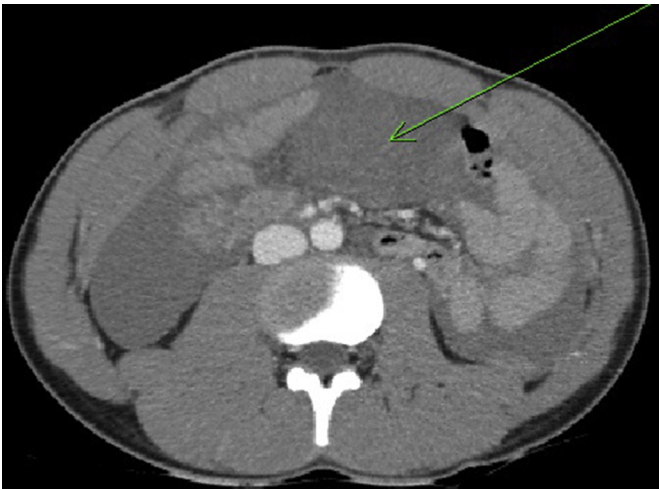
computed tomographic scan (CT) of the abdomen and pelvis demonstrated a  $4 \times 9$  cm hypodense mass in the central abdomen, inferior to the stomach and ascites (Figs. 1 and 2). The CT did not delineate the origin of the mass; magnetic resonance imaging was not readily available.

The differential diagnosis included lymphoma or a mesenchymal tumor. The investigations were completed late in the evening; since he was hemodynamically stable he was consented for surgery the next day (diagnostic laparoscopy, biopsy and possible resection). However, repeat blood-work early the next morning revealed a decreasing hemoglobin level and he was transferred urgently to the operating room. Upon entry into the abdomen, dark, bloody ascites spilled out, and the case was promptly converted to a laparotomy. After packing all 4 quadrants, a systematic review of the abdomen was carried out. The source of the bleeding was a mobile, pedunculated mass arising from the greater curvature of the stomach which was ischemic from torsion around its stalk (Fig. 3). The rest of the abdominal cavity was normal, including an assessment of all peritoneal surfaces. There were no palpable hepatic lesions or peritoneal/omental implants. There were no enlarged, palpable, lymph nodes. The tumor was amputated at the base of its stalk, well beyond the tumor itself, and the stump was imbricated. The patient had an uncomplicated recovery from surgery.

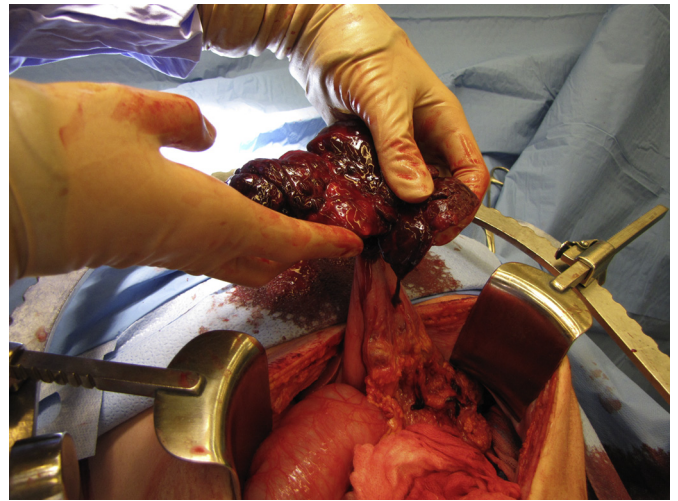
Pathology demonstrated an 11 cm  $\times$  8 cm  $\times$  3.2 cm gastrointestinal stromal tumor with spindle cell and epithelioid morphology and necrosis secondary to torsion. It was diffusely CD34 positive,

\* Corresponding author. Pediatric General Surgery, McMaster Children's Hospital, 1200 Main Street W., HSC-Room 4E2, Hamilton, ON, Canada L8N 3Z5. Tel.: +1 905 521 2100x75231; fax: +1 905 521 9992.

E-mail address: [shawyeac@mcmaster.ca](mailto:shawyeac@mcmaster.ca) (A.C. Shawyer).



**Fig. 1.** Axial CT image of mass abutting the stomach.



**Fig. 3.** Intra-operative image of torted, pedunculated, hemorrhagic mass arising from the stomach.

and focally c-kit positive. The margin was positive, and molecular testing was positive for DOG1 and a mutation in PDGFRA exon 18.

The patient was referred on to the adult regional cancer center, where imatinib treatment was initiated. A follow-up CT scan showed thickening at the previous resection site along the greater curvature of the stomach and with the positive margin at the initial surgery, a distal partial gastrectomy was performed. Again, there was no evidence of metastatic disease noted at laparotomy. Pathology revealed scar tissue with no evidence of malignancy. His follow-up CT scans and gastroscopy show no evidence of disease. He is now 10 months since his presentation,

and continues to do well. He is followed by the adult oncology service.

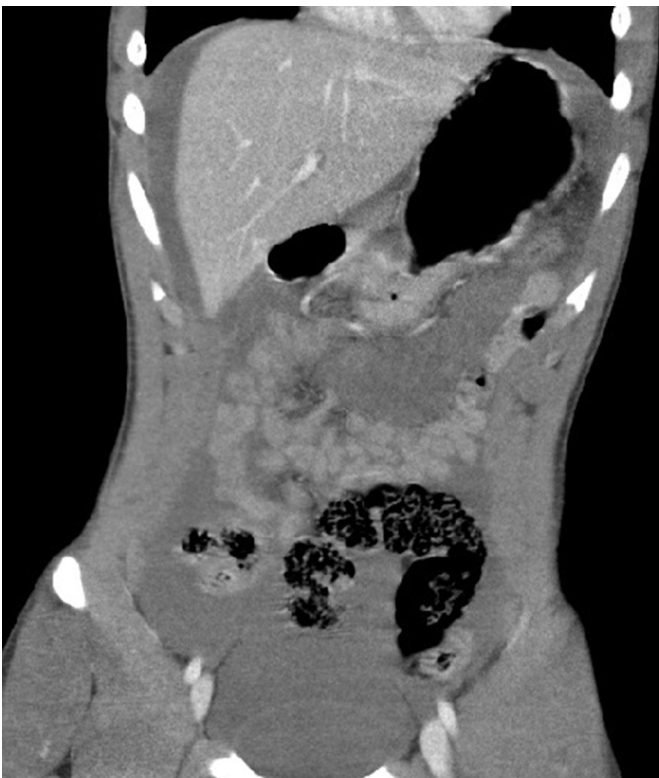## 2. Discussion

A focused PubMed search was undertaken using the terms GIST, pediatric, pedunculated, gastric/stomach stromal tumor, hemoperitoneum and torsion. There are case reports of gastric GISTs resulting in hemoperitoneum, generally presenting with acute abdominal pain [4–14], or with hypovolemic shock [14–16]. An omental GIST presenting with hemoperitoneum has been reported [17], and epigastric pain from a torted gastric GIST [18].

In contrast to the distribution in adults, pediatric GISTs are more common in females, more likely to have a wild-type mutation, and are more likely to present with multifocal tumors and lymph node metastases [19]. Pediatric GISTs generally are more indolent [19]. There is no consensus on the treatment for wild-type pediatric GISTs given the evidence for imatinib resistance [20]. The current recommendation is surgical treatment with the addition of alternative tyrosine kinase inhibitor therapy in select cases [20]. The recommendation for pediatric GISTs with c-kit positivity or PDGFR mutations however, is according to the NCCN guidelines for adults with the same findings [20]. The pathology of our patient is in keeping with an adult-type GIST and he was thus treated accordingly.

## 3. Conclusion

This 17-year old boy had an unusual presentation of an uncommon tumor: a torted, ischemic GIST causing hemoperitoneum. GISTs, which are often exophytic, can be pedunculated and may thus be at risk of torsion. Tumor rupture has been described as a source of hemoperitoneum, and tumor necrosis from the ischemia of torsion may result in significant bleeding into the peritoneal cavity [4–14]. Pediatric GISTs are typically characterized by a wild-type mutation rather than the classical c-kit or PDGFR mutations seen in adult GISTs. This patient's tumor was more of the adult-type (c-kit positive and mutation detected in PDGFR exon 18), and thus he was referred to the adult oncology service. His treatment has followed the adult GIST guidelines of resection and tyrosine kinase inhibitor therapy.



**Fig. 2.** Coronal CT image of mass abutting the stomach.

## Acknowledgment

The authors would like to thank Janet Rowe for her assistance in editing the manuscript.

## References

- [1] Prakash S, Sarran L, Socci N, DeMatteo RP, Greco AM, Maki RG, et al. Gastrointestinal stromal tumors in children and young adults: a clinicopathologic, molecular, and genomic study of 15 cases and review of the literature. *J Pediatr Hematol Oncol* 2005;27:179–87.
- [2] Benesch M, Wardelmann E, Ferrari A, Brennan B, Verschuur A. Gastrointestinal stromal tumors (GIST) in children and adolescents: a comprehensive review of the current literature. *Pediatr Blood Cancer* 2009;53:1171–9.
- [3] Janeway KA, Weldon CB. Pediatric gastrointestinal stromal tumor. *Semin Pediatr Surg* 2012;21:31–43.
- [4] de Juan Ferré A, Gutiérrez L, Garicano F, Malaxetxebarria S, Fernández F. Haemoperitoneum as an indicator of GIST. *Anticancer Drugs* 2012;23(suppl): S10–2.
- [5] Chen L, Li Z, Sun Y, Qin X. Spontaneous hemoperitoneum secondary to a ruptured gastric stromal tumour. *Dig Liver Dis* 2012;44:e15.
- [6] Costi R, Le Bian A, Creuze N, Prevot S, Cauchy F, Violi V, et al. Hemoperitoneum caused by a ruptured GIST located in the posterior gastric wall managed by endoscopic diagnosis and laparoscopic treatment: case report and literature review. *Surg Laparosc Endosc Percutan Tech* 2011;21:e316–8.
- [7] Lee GW, Kim YS, Kim SG, Ko BM, Lee MS, Cho KS, et al. Spontaneous rupture of a gastric stromal tumor causing hemoperitoneum. *Gut Liver* 2010;4: 278–82.
- [8] Bae JM, Kim SW. Hemoperitoneum due to ruptured gastric gastrointestinal stromal tumor. *Korean J Gastroenterol* 2009;54:123–5.
- [9] Freeman BB, Critchlow JF, Cohen S, Edlow JA. Spontaneous intraperitoneal hemorrhage as the initial presentation of a gastrointestinal stromal tumor: a case report. *Int J Emerg Med* 2010;3:53–6.
- [10] Sprenger T, Liersch T, Rothe H, Schulze FP, Homayounfar K, Ghadimi BM, et al. Extramural gastric GIST manifested by spontaneous perforation with acute intraabdominal bleeding and haemoperitoneum. *Zentralbl Chir* 2010;135:75–8.
- [11] Cheon YK, Jung IS, Cho YD, Kim JO, Lee JS, Lee MS, et al. A spontaneously ruptured gastric stromal tumor with cystic degeneration presenting as hemoperitoneum: a case report. *J Korean Med Sci* 2003;18:751–5.
- [12] Epstein MG, Pasquetti AF, Costa SV, Favaro MD, Contrucci Filho O, Ribeiro Junior MA. Hemoperitoneum secondary to gastric GIST negative for c-KIT and positive for antibody anti-DOG1. *Einstein (Sao Paulo)* 2012;10:377–9.
- [13] Pera M, Sáenz A, Fernández-Cruz L. Hemoperitoneum due to a ruptured gastric stromal tumor. *Dig Surg* 1999;16:248–9.
- [14] Kim TH, Choi SC, Choi CS, Nah YH. Hemoperitoneum secondary to a ruptured gastric stromal tumor. *Gastrointest Endosc* 2006;63:1066–7.
- [15] Fisco V, Portale G, Isoardi R, Frigo F, Migliorini G. Spontaneous rupture of giant gastric GIST presenting as hemoperitoneum and mimicking cavernous liver angioma. *Tumori* 2009;95:233–5.
- [16] Bucher P, Poletti PA, Myit S, Morel P. Spontaneous rupture of a gastrointestinal stromal tumour associated with life-threatening nontraumatic hemoperitoneum. *Can J Surg* 2008;51:E38–9.
- [17] Murayama Y, Yamamoto M, Iwasaki R, Miyazaki T, Saji Y, Doi Y, et al. Greater omentum gastrointestinal stromal tumor with PDGFRA-mutation and hemoperitoneum. *World J Gastrointest Oncol* 2012;4:119–24.
- [18] Slim R, Smayra T, Tohme C, Samaha E, Yaghi C, Sayegh R. Unusual etiology of epigastric pain. *J Emerg Med* 2011;40:e93–5.
- [19] Miettinen M, Sobin L, Lasota J. Gastrointestinal stromal tumors of the stomach: a clinicopathologic, immunohistochemical, and molecular genetic study of 1765 cases with long-term follow-up. *Am J Surg Pathol* 2005;29: 52–68.
- [20] Janeway KA, Pappo A. Treatment guidelines for gastrointestinal stromal tumors in children and young adults. *J Pediatr Hematol Oncol* 2012;34:S69–72.