



# Upper extremity acute compartment syndrome during tissue plasminogen activator therapy for pulmonary embolism in a morbidly obese patient

Serkan Tuna<sup>a</sup>, Tahir Mutlu Duymus<sup>b</sup>, Serhat Mutlu<sup>b,\*</sup>, Ismail Emre Ketenci<sup>a</sup>, Ayhan Ulusoy<sup>a</sup>

<sup>a</sup> Department of Orthopaedics, Haydarpasa Numune Training Research Hospital, Istanbul, Turkey

<sup>b</sup> Department of Orthopaedics, Kanuni Sultan Suleyman Training and Research Hospital, Istanbul, Turkey

## ARTICLE INFO

### Article history:

Received 2 October 2014  
Received in revised form 11 January 2015  
Accepted 13 January 2015  
Available online 15 January 2015

### Keywords:

Compartment syndrome  
Fasciotomy  
Morbid obesity  
tPA

## ABSTRACT

**INTRODUCTION:** Deep vein thrombosis (DVT) and pulmonary embolism (PE) are more frequently observed in morbidly obese patients. Tissue plasminogen activator (tPA) is a thrombolytic agent which dissolves the thrombus more rapidly than conventional heparin therapy and reduces the mortality and morbidity rates associated with PE. Compartment syndrome is a well-known and documented complication of thrombolytic treatment. In awake, oriented and cooperative patients, the diagnosis of compartment syndrome is made based on clinical findings including swelling, tautness, irrational and continuous pain, altered sensation, and severe pain due to passive stretching. These clinical findings may not be able to be adequately assessed in unconscious patients.

**PRESENTATION OF CASE:** In this case report, we present compartment syndrome observed, for which fasciotomy was performed on the upper right extremity of a 46-year old morbidly obese, conscious female patient who was receiving tPA due to a massive pulmonary embolism.

**DISCUSSION:** Compartment syndrome had occurred due to the damage caused by the repeated unsuccessful catheterisation attempts to the brachial artery and the accompanying tPA treatment. Thus, the bleeding that occurred in the volar compartment of the forearm and the anterior compartment of the arm led to acute compartment syndrome (ACS). After relaxation was brought about in the volar compartment of the forearm and the anterior compartment of the arm, the circulation in the limb was restored.

**CONCLUSION:** As soon as the diagnosis of compartment syndrome is made, an emergency fasciotomy should be performed. Close follow-up is required to avoid wound healing problems after the fasciotomy.

© 2015 The Authors. Published by Elsevier Ltd. on behalf of Surgical Associates Ltd. This is an open access article under the CC BY-NC-ND license (<http://creativecommons.org/licenses/by-nc-nd/4.0/>).

## 1. Introduction

The muscle groups and fascial structures in the extremities form separate compartments. When the interstitial pressure in these compartments exceeds the capillary perfusion pressure, the circulation is disturbed and acute compartment syndrome occurs. This leads to a decrease in the oxygenated blood volume and to the accumulation of waste products, resulting in pain and peripheral sensorial loss. The process causes ischemia in the muscles and nerves.

Data from the Royal Infirmary of Edinburgh indicate the incidence of compartment syndrome as 3.1/100.000 [1]. In a healthy patient, the compartmental pressure at rest varies between 0 and 10 mm. Hargens et al. described actual compartmental pressures above 30 mm Hg as compartment syndrome and recommended that fasciotomy be applied [2].

Compartment syndrome is typically observed subsequent to extremity fractures and traumas. Other causes include burns, intoxications, haemorrhages, autoimmune vasculitis, drug use, etc. In terms of drug use, isolated cases of compartment syndrome following thrombolytic therapy have been reported in literature [3,4]. Major indications of thrombolytic drug use are deep vein thrombosis (DVT) and pulmonary embolism (PE). In this case report, the relationship between tPA treatment, unsuccessful arterial catheterisation attempts, and acute compartment syndrome observed in the upper extremity of a 46-year old morbidly obese

\* Corresponding author at: Atakent Mahallesi, Turgut Ozal Caddesi, No:1, Postal Code: 34303 Kucukcekmece/Istanbul, Turkey. Tel.: +90 532 762 76 16; fax: +90 212 571 47 90.

E-mail address: [serhatmutlu@hotmail.com](mailto:serhatmutlu@hotmail.com) (S. Mutlu).

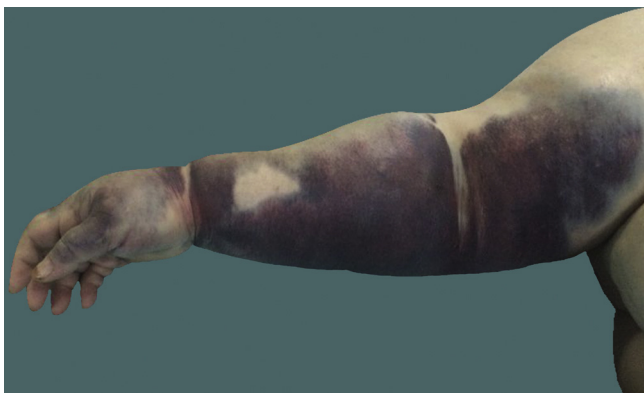

Fig. 1. Preoperative view of the upper right extremity.

(BMI >40 kg/m<sup>2</sup>) and conscious female patient diagnosed with massive pulmonary embolism and receiving tPA, are presented in the light of the data in literature.

## 2. Presentation of case

A 46-year old female patient was admitted to the emergency room in an unconscious state after a sudden attack of tachycardia and dyspnea. The morbidly obese patient with a BMI of 85 kg/m<sup>2</sup> (240 kg weight and 168 cm height) had a history of weight gain that had increased within the last three years following her divorce, due to a sedentary lifestyle, diabetes mellitus (DM), hypertension (HT), hypothyroidism, and sleep disorders. Her next of kin reported that she did not receive regular treatment for these conditions. The physical examination, laboratory tests, ECG and radiological assessments performed in the emergency room revealed a high troponin level, right bundle branch block in the ECG, negative T-waves in the V1–V4 chest derivations, enlarged right ventricular outflow tract in the echocardiography with preserved left ventricular functions, hypotension, 90% oxygen saturation and normal chest X-ray. The patient was diagnosed with pulmonary embolism and admitted to the emergency room where she was started on PE therapy. Since the catheterisation effort through the right brachial artery was unsuccessful, 100 mg of standard-dose tPA therapy was administered through the left brachial artery. At the end of the thrombolytic therapy, heparin treatment was started at a dose of 1000 IU/h and the dose was adjusted up to 2000 IU/h based on the aPTT and AST (SGOT) results. The patient was observed to be haemodynamically stable and clinically relaxed during the early phase following the thrombolytic treatment.

When swelling, tautness, pain and ecchymoses were observed in the upper right extremity at the 4th hour of the thrombolytic therapy, the heparin treatment was stopped and the treatment was continued with low-molecular weight heparin. Following orthopedic consultation, based on the massive swelling in the upper right extremity, taut skin, paresthesia in the fingers, and increased pain with passive movements, which was unresponsive to the analgesic treatment, the clinical diagnosis of compartment syndrome was reached. An urgent surgical intervention was planned (Fig. 1). Under general anesthesia, a fasciotomy on the volar aspect of the forearm reaching above the elbow was performed. The abductor compartment of the hand, the carpal tunnel and Guyon's canal were loosened and the median and ulnar nerves were relieved. The muscles and nerves in the superficial and deep compartments were decompressed through the drainage of the massive hematoma, which spread upwards and downwards from around the brachial artery. The anterior compartment of the arm was relaxed through the incision that continued medially above the elbow (Fig. 2). After the bleeding control and thorough irrigation, the skin was closed

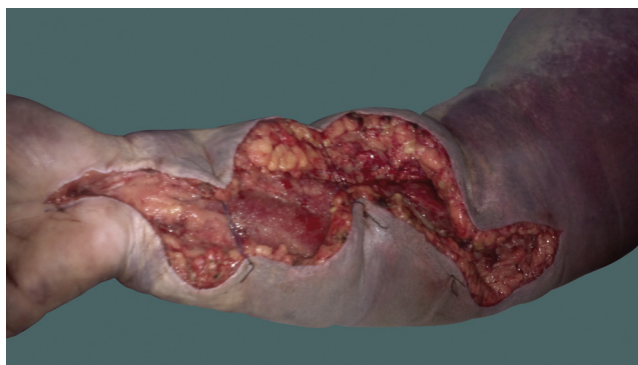


Fig. 2. Postoperative view of the upper right extremity.

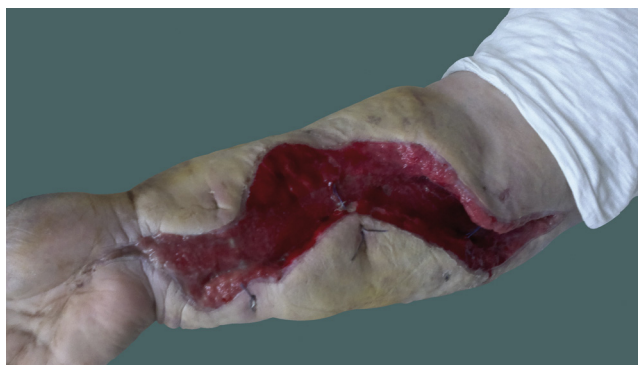

Fig. 3. Postoperative view of the upper right extremity (15 days after surgery).

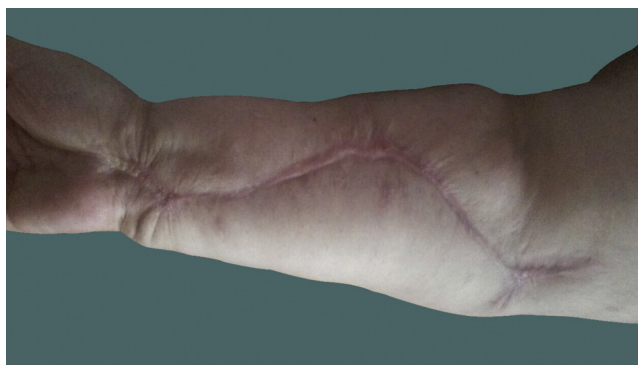

Fig. 4. Postoperative view of the upper right extremity (3 months after surgery).

with approximation sutures. The dressings were changed using rifamycin sodium ampoule and nitrofurazone 0.2% pomade. The patient, whose pain, numbness, swelling and tautness rapidly subsided after the operation, was followed up through daily dressing changes. As infection symptoms such as purulent discharge, fever and bradycardia were observed in the fasciotomy area during the follow-up, the patient underwent repeated debridements and was started on antibiotic treatment. When the patient's infection was brought under control and her general condition became stable, the fasciotomy area was closed on the 15th day without using any grafts (Fig. 3). During the follow-up visit in the 3rd postoperative month, the hand, wrist and elbow ranges of motion were full, and the neurological and motor power examinations were normal (Fig. 4). The patient gave informed consent for the data concerning her case to be submitted for publication.

### 3. Discussion

As the use of thrombolytic therapy has become more common in the treatment of myocardial infarction (MI) and PE, acute compartment syndrome (ACS) has been reported as a rare complication of thrombolytic therapy [5].

Acute compartment syndrome occurs when the interstitial pressure rises within the closed osseous fascial compartments. Due to trauma, a tight cast or clothing, internal bleeding or ischemia, the tight compartments swell and the perfusion of the tissue is reduced. If this chain of events causing ischemia in the tissue cannot be reversed through the decompression of the compartment, it may lead to skin necrosis [6]. As a result, scarring and Volkman's contracture are observed in the extremity, and the myoglobin released in the circulation due to the cell destruction may lead to kidney dysfunction, which may even prove fatal [7].

The diagnosis of compartment syndrome is based on the suspicious clinical signs and symptoms. The most prominent symptom of muscle and bone ischemia is a persistent, progressive pain that cannot be relieved with immobilisation [8]. The pain is aggravated by passively stretching the muscle. As the nerve ischemia gradually develops, the pain subsides [9]. Loss of sensation is the second most important symptom and points to nerve ischemia. The third most important finding is the loss or weakening of muscle power, which is difficult to assess. Finally, the most important finding is the tautness and hardness observed during palpation of the area subjected to the trauma [8]. The loss of the pulse is observed in the later phases and is associated with a negative prognosis [10].

McQueen et al. emphasized that the most important factor in the early diagnosis of acute compartment syndrome is the awareness and vigilance of the nurses and medical personnel [11]. This high awareness and vigilance is especially important in preventing any complications associated with compartment syndrome which may occur secondary to thrombolytic treatment in intubated patients. In the patient subject of this case report, the vigilance of the intensive care doctors and the request for orthopaedic consultation were important factors leading to the diagnosis.

In radiological and cadaver studies, McCarthy et al. found the volar compartment of the forearm to be the most suitable and safe place for pressure measurement [12]. According to that study, the safest point is the area between the flexor carpi radialis and palmaris longus tendons. Inserted through this point, the catheter is placed into the deep volar compartment of the forearm without damaging the vascular and neural structures. In cases with suspected compartment syndrome where the clinical assessment is inadequate for a diagnosis, the intracompartmental pressure may be measured. For these measurements, there are devices with catheters connected to a transducer such as The Stryker Quick Pressure Monitor Instrument, the Manometric IV pump method, the Whitesides infusion technique and the slit catheter technique. Reliable and accurate measurements have been reported to have been obtained with the Stryker Instrument and the IV pump method. At normal rest status, compartment pressure is 0–10 mm Hg. In literature, it has been reported that in the presence of positive clinical findings, compartment pressure may exceed 30 mm Hg and if the duration of the raised pressure is not known or the patient is unconscious, fasciotomy is recommended. Whitesides et al. recommended fasciotomy if the difference between measured compartment pressure and diastolic pressure falls to 10–30 mm Hg [13–16]. In addition, less invasive techniques such as laser Doppler flowmetry, 99Tcm-methoxy-isobutryl isonitrile scintigraphy, and non-invasive near-infrared spectroscopy have also been described [17]. However, they are not actively used for diagnosis of compartment syndrome as yet. On the other hand, MRI is not sensitive enough for the diagnosis of compartment syndrome. In the patient reported here, the clear clinical symptoms and

findings left no place for doubt. The patient was conscious, oriented and cooperative and the diagnosis of compartment syndrome was made based on these symptoms and signs without requiring any additional examination methods.

Cases of ACS that occur following blood withdrawal for the arterial blood gas analysis have usually been associated with anticoagulant therapy. In literature, cases of ACS have been reported in the forearm of patients who received rtPA therapy for PE and underwent blood withdrawal from the radial artery for blood gas analysis during the follow-up [18].

Similar to the current patient, Badge R. et al., reported a case of ACS in a 78-year old unconscious male patient diagnosed with massive PE, who was treated with tPA through the arterial route. As repeated attempts were made to administer thrombolytic treatment through the right radial artery of the patient, ACS was observed to develop in his right forearm [3]. In the current patient, during the repeated arterial catheterisations, blood leaked out of the insertion points through the influence of the tPA, resulting in compartment syndrome in the whole upper limb. Due to the relatively young age and morbid obesity of the patient, and that the compartment syndrome involved the whole upper extremity, this case is unique in character and to the best of our knowledge, no similar patient has been reported in literature.

In patients with massive PE, unstable hemodynamics and reduced right ventricular function, thrombolytic therapy achieves a more rapid lysis of the thrombus compared to the conventional heparin treatment [19]. In the elderly, bleeding after thrombolytic treatment is more frequently observed [20]. Both in the elderly and in morbidly obese patients with various medical problems, bleeding around the insertion points to the blood vessels should be considered and care should be taken to work less traumatically.

When compartment syndrome is diagnosed, it is of the utmost importance to act rapidly to perform an adequate fasciotomy to decompress the compartment. If the diagnosis and decompression are delayed longer than 8 h, the muscle and nerves within the compartment incur irreversible damage [6]. In a study by Vaillancourt et al. of patients where ACS developed, muscle necrosis associated with ischaemia was determined in the first 3 h in 36% of the patients and a safe time interval was reported to be the first 3 h. However, in the same study, fasciotomy was applied to 11 patients within 24 h and it was reported that no muscle necrosis had developed [21]. The period of maximum muscular ischaemic tolerance in compartment syndrome can be considered to vary depending on etiological reasons and the affected extremity. When there is delayed diagnosis, there is irreversible muscle and tissue damage. When this situation is prolonged, delayed treatment leads to calcific myonecrosis in the extremity muscles and even Volkman's ischaemic contracture, which is a rarely seen complication but is a permanent deformity. [7]. In the current patient, as soon as the compartment syndrome was diagnosed, the fasciotomy was performed. No muscle necrosis was observed during the fasciotomy.

In the patient reported here, fasciotomy was performed on the superficial and deep volar compartments of the forearm. The abductor compartment, carpal tunnel and Guyon's canal in the hand were released. The fasciotomy was not continued towards the posterior compartment. In this patient, compartment syndrome had occurred due to the damage caused by the repeated unsuccessful catheterisation attempts to the brachial artery and the accompanying tPA treatment. Thus, the bleeding that occurred in the volar compartment of the forearm and the anterior compartment of the arm led to the ACS. After relaxation was brought about in the volar compartment of the forearm and the anterior compartment of the arm, the circulation in the limb was restored.

Fasciotomy is the gold standard for the prevention and treatment of ACS. However, an open wound may cause significant



mortality. To date, various methods have been described for wound repair following fasciotomy and of these, the most frequently used is the split-thickness skin grafting method [22]. However, this technique requires an additional operation and has the disadvantages of a longer hospital stay and potential graft failure. Another method of vacuum-assisted closure has been reported to have high average daily costs and an increased need for skin grafting [23]. In a study by Bengezi et al., by applying continuous elevation after fasciotomy, oedema in the extremity was reduced and with the subsequent application of primary wound repair, successful results were obtained [24]. In the current case, the elevation method was used. When a reduction in oedema and sufficient skin elasticity were noted in the daily monitoring, primary closure was applied. The elevation method was selected as costs are low and application is simple in comparison with the above-mentioned data in literature. However, a study combining VAC and the elevation method could show a lower risk of infection and by resolving oedema more quickly could enable earlier primary closure.

#### 4. Conclusion

In cases of swelling, tautness, and severe and continuous pain in the extremities, which cannot be relieved through immobilisation, compartment syndrome should be considered. In cases of elderly or morbidly obese patients with various medical problems, thrombolytic therapy and repeated traumatic catheterization attempts in the extremities, either individually or in combination, may lead to bleeding. Although rare, this condition may cause compartment syndrome in the upper limbs. As soon as the diagnosis of compartment syndrome is made, an emergency fasciotomy should be performed. Close follow-up is required to avoid wound healing problems after the fasciotomy.

#### Conflicts of interest

No conflict of interest was declared by the authors.

#### Funding

The authors declared that this study has received no financial support.

#### Consent

Written informed consent was obtained from patient who participated in this case.

#### Authors contribution

ST, TD, SM, IK, and AU were involved in the conception, design and interpretation.

ST, TD and SM wrote the manuscript.

ST, IK, AU and SM collected data, reviewed relevant published reports and provided the images.

All authors read and approved the final manuscript.

#### References

- [1] M.M. McQueen, P. Gaston, C.M. Court-Brown, Acute compartment syndrome. Who is at risk? *J. Bone Joint Surg. Br.* 82 (2000) 200–203.
- [2] A.R. Hargens, D.A. Schmidt, K.L. Evans, M.R. Gonsalves, J.B. Cologne, S.R. Garfin, et al., Quantitation of skeletal-muscle necrosis in a model compartment syndrome, *J. Bone Joint Surg. Am.* 63 (4) (1981) 631–636.
- [3] R. Badge, M. Hemmady, 2011, Forearm Compartment Syndrome following Thrombolytic Therapy for Massive Pulmonary Embolism: A Case Report and Review of Literature, Hindawi Publishing Corporation Case Reports in Orthopedics Volume, Article ID 678,525, 4 doi: 10.1155/2011/678525
- [4] A. Reuben, E. Clouting, Compartment syndrome after thrombolysis for acute myocardial infarction, *Emerg. Med. J.* 22 (1) (2005) 77.
- [5] T.R. Yip, B.M. Demaerschalk, Forearm compartment syndrome following intravenous thrombolytic therapy for acute ischemic stroke, *Neurocrit. Care* 2 (1) (2005) 47–48.
- [6] R.B. Heppenstall, An update in compartment syndrome investigation and treatment, *Orthop. J.* 10 (1997) 49–57.
- [7] R. Volkmann, Ischämische Muskellähmungen und -kontrakturen [Ischemic muscle paralysis and contractures], *Zentralbl. Chir.* 8 (1881) 801–803.
- [8] S.A. Rowland, Fasciotomy the treatment of compartment syndrome, in: D.P. Green (Ed.), *Operative Hand Surgery*, 66, 1993, pp. 1–94.
- [9] S.J. Mubarak, A.R. Hargens, Acute compartment syndromes, *Surg. Clin. North Am.* 63 (1983) 539–565.
- [10] R. Kosir, F.A. Moore, J.H. Selby, C.S. Cocanour, R.A. Kozar, E.A. Gonzalez, S.R. Todd, Acute lower extremity compartment syndrome (ALECS) screening protocol in critically ill trauma patients, *J. Trauma* 63 (2007) 268–275.
- [11] M.M. McQueen, P. Gaston, C.M. Court-Brown, Acute compartment syndrome, *J. Bone Joint Surg. Series B* 82 (2) (2000) 200–203.
- [12] D.M. McCarthy, D.G. Sotereanos, J.D. Towers, C.A. Britton, J.H. Herndon, A cadaveric and radiologic assessment of catheter placement for the measurement of forearm compartment pressures, *Clin. Orthop. Relat. Res.* 312 (1995) 266–270.
- [13] A. Uliasz, J.T. Ishida, J.K. Fleming, L.G. Yamamoto, Comparing the methods of measuring compartment pressures in acute compartment syndrome, *Am. J. Emerg. Med.* 21 (2) (2003) 143–145.
- [14] S.J. Mubarak, A.R. Hargens, Acute compartment syndromes, *Surg. Clin. North Am.* 63 (3) (1983) 539–565.
- [15] C. Willy, J. Sterk, H.U. Völker, C. Sommer, F. Weber, O. Trentz, H. Gerngross, Acute compartment syndrome: results of a clinico-experimental study of pressure and time limits for emergency fasciotomy, *Unfallchirurg* 104 (5) (2001) 381–391.
- [16] T.E. Whitesides, T.C. Haney, K. Morimoto, H. Harada, issue pressure measurements as a determinant for the need of fasciotomy, *Clin. Orthop. Relat. Res.* 113 (1975) 43–51, PMID: 1192674 [PubMed - indexed for MEDLINE].
- [17] W.M. Reisman 1, M.S. Shuler, T.L. Kinsey, A.L. Cole, T.E. Whitesides Jr, M.G. Davila, E.K. Smith, T.J. Moore, Relationship between near infrared spectroscopy and intra-compartmental pressures, *J. Emerg. Med.* 44 (2) (2013) 292–298.
- [18] K. Bisarya, S. George, S. El Sallakh, Acute compartment syndrome of the forearm following blood gas analysis postthrombolysis for pulmonary embolism, *ePlasty* (2013), March 7.
- [19] G. Thabut, D. Thabut, R.P. Myers, B.B. Chabert, R.M. Chahla, H. Mal, M. Fournier, Thrombolytic therapy of pulmonary embolism: a meta-analysis, *J. Am. Coll. Cardiol.* 40 (9) (2002) 1660–1667.
- [20] N. Meneveau, J.P. Bassand, F. Schiele, Y. Bouras, T. Anguenot, Y. Bernard, R. Schultz, Safety of thrombolytic therapy in elderly patients with massive pulmonary embolism: a comparison with nonelderly patients, *J. Am. Coll. Cardiol.* 22 (4) (1993) 1075–1079.
- [21] C. Vaillancourt, I. Shrier, A. Vandal, M. Falk, M. Rossignol, A. Verneq, D. Somogyi, Acute compartment syndrome: how long before muscle necrosis occurs, *CJEM Can. J. Emerg. Med.* 6 (3) (2004) 147–154.
- [22] J. Zannis, J. Angobaldo, M. Marks, A. DeFranzo, L. David, J. Molnar, L. Argenta, Comparison of fasciotomy wound closures using traditional dressing changes and the vacuum-assisted closure device, *Ann. Plast. Surg.* 62 (4) (2009) 407–409.
- [23] D. Kakagia, E.J. Karadimas, G. Drosos, A. Ververidis, G. Trypsiannis, D. Verettas, Wound closure of leg fasciotomy: comparison of vacuum-assisted closure versus shoelace technique. A randomised study, *Injury* 45 (5) (2014) 890–893.
- [24] O. Bengezi, A. Vo, Elevation as a treatment for fasciotomy wound closure, *Can. J. Plast. Surg.* 21 (3) (2013) 192–194.

#### Open Access

This article is published Open Access at [sciedirect.com](http://sciedirect.com). It is distributed under the [IJSCR Supplemental terms and conditions](#), which permits unrestricted non commercial use, distribution, and reproduction in any medium, provided the original authors and source are credited.