




Available online at  
 ScienceDirect  
[www.sciencedirect.com](http://www.sciencedirect.com)

Elsevier Masson France  
 EM|consulte  
[www.em-consulte.com](http://www.em-consulte.com)

**Orthopaedics  
& Traumatology**  
 Surgery & Research

## ORIGINAL ARTICLE

# Femoral deficiency reconstruction using a hydroxyapatite-coated locked modular stem. A series of 43 total hip revisions

R. Philippot<sup>a,b,\*</sup>, F. Delangle<sup>a</sup>, F.-X. Verdot<sup>a</sup>, F. Farizon<sup>a</sup>, M.-H. Fessy<sup>a</sup>

<sup>a</sup> EA 4338, laboratoire de physiologie de l'exercice, Saint-Étienne, France

<sup>b</sup> Department of Orthopaedics and Traumatology, Pavillon 1–3, Bellevue Hospital, 25, boulevard Pasteur, 42055 Saint-Étienne cedex 2, France

Accepted: 9 September 2008

**KEYWORDS**

Revision total hip replacement;  
 Interlocking fixation;  
 Modular stem

**Summary**

**Introduction.** – We report a continuous prospective series of patients operated on for total hip prosthesis femoral component loosening involving a bone defect. Reconstruction was performed using a hydroxyapatite-coated locked modular stem. The study's objective was to assess medium term clinical and X-ray results obtained with this original concept.

**Materials and methods.** – The patients included received a REEF® (DePuy) femoral implant for aseptic loosening or loosening associated with a periprosthetic fracture. Implantation was systematically accompanied by an extended trochanteric osteotomy (ETO). Patients were followed up prospectively by clinical and X-ray examination. Their loosening was graded at inclusion according to Vives' classification as revised by SOFCOT in 1999. Analysis focused on actuarial implant survivorship, dislocation and the bone/implant interface.

**Results.** – Forty-three hips were included: mean follow-up was 58.2 months (12–92) and mean age at surgery was 72.4 years (37–94). The main indications were severe bone loss rated grade III ( $n = 15$ ) or IV ( $n = 16$ ) according to the SOFCOT classification. There was one long-term failure, involving implant fracture secondary to nonunion of the femoral shaft. Mean Postel and Merle d'Aubigné (PMA) clinical assessment score increased from six preoperatively to 14.5 at end of follow-up. X-ray analysis found no stem migration by end of follow-up. There was consistent consolidation of the ETO around the stem, except in one case of stem fracture which evolved into tight nonunion. In terms of metaphyseal integration, five patients showed radiolucency without evolution over follow-up, and eight had severe calcar cortical atrophy at end of follow-up. Mean 5-year actuarial survivorship was  $97.7 \pm 2.3\%$ , with a 2% incidence of dislocation.

**Discussion.** – The complications rate was low, and results were comparable with those reported in the literature. The study confirmed the interest of the extended trochanteric osteotomy exposure and the effectiveness of the hydroxyapatite-coated interlocked modular stem concept

\* Corresponding author.

E-mail address: [r.philippot@yahoo.fr](mailto:r.philippot@yahoo.fr) (R. Philippot).

in the treatment of hip prosthesis loosening with femoral bone loss (involving or not the cortex). On analysis, the one case of failure does not proscribe the surgical technique employed. Implant osseointegration was difficult to analyze. The extent of the surgical approach and of its corresponding sequels, combined with the complexity of adjusting the implant, however, restrict this surgical option indications to level III and IV cases of femoral loosening.

Level of evidence: level IV; therapeutic study.

© 2009 Elsevier Masson SAS. All rights reserved.

## Introduction

Total hip replacement revision for aseptic loosening is frequently performed but may induce difficulties related to the approach to remove the former implants and the incidence and severity of bone loss. The literature describes various reconstruction techniques, with variable outcome: cemented implants [1,2], allograft [3,4], and cementless implants, with or without hydroxyapatite coating [5,6,7]. As the ongrowth potential of hydroxyapatite coatings depends on both bone interface quality and on implant stability, certain authors recommend distal interlocking [8,9].

Our department has been using the REEF® (DePuy) femoral revision implant since April 1999 for hip prosthesis revision in case of severe femoral bone loss. This is a modular, cementless implant, entirely coated in hydroxyapatite, distally interlocked and introduced via a transfemoral approach (extended trochanteric osteotomy [ETO]). The present continuous prospective total hip replacement revision study assessed clinical and radiological results, to highlight the strong and weak points of this original concept.

## Materials and methods

### Inclusion criteria

This single-center prospective study concerned a continuous, homogeneous series of patients included from April 1999 to April 2004.

All cases of total hip prosthesis revision involving a REEF® (DePuy) femoral implant during the study period were included, with two indications: aseptic loosening with severe (grade III or IV [10]) bone loss, or loosening associated with periprosthetic fracture. Cases involving tumor or reimplantation secondary to deep infection were excluded.

### Implants and surgical technique

Femoral revision systematically used the same REEF® (DePuy) implant. This is a modular femoral reconstruction system with distal interlocking, comprising a trochanter base plate with the implantable part coated in hydroxyapatite, which is available in two heights and is positioned in free anteversion. The metaphyseal-diaphyseal stem comprises a single part with stepwise horizontal macrostructures; the diaphyseal part, entirely hydroxyapatite-coated, is cylindrical and anatomical (sagittal curve), with vertical macrostructures and between one and three holes for distal interlocking. The implant concept is based on primary diaphyseal fixation by interlocking as a prelude to secondary

fixation by osseointegration, initial axial and rotational stability being provided by the distal interlock.

All patients were operated on in the same institution, using the same technique, although by different senior surgeons. All acetabular reconstructions included a dual-mobility cup to reduce the risk of postoperative dislocation. Preoperative planning allowed the sizes of all necessary components to be estimated, which required frontal pelvic X-ray and frontal X-ray graphs of both femurs. The proximal interlocking hole should ideally be positioned at least 5 cm under the distal aspect of ETO to ensure stability.

The approach was systematically posterolateral, associated to an extended trochanteric osteotomy (ETO) performed to make easier implant and cement removal. This bony approach had to conserve bone vascularization while enabling the entire loose implant, cement and granuloma to be removed. A hole was bored in the diaphyseal shaft and the stem introduced into the femoral canal. This enabled the neck to be tested for length and anteversion to adjust the definitive implant. The metaphyseal-diaphyseal stem was then impacted to the level determined by these tests. Interlocking was performed using a sighting frame. After another check on length and anteversion, the trochanter base plate was fixed onto the stem by a Morse taper and connection screw. Femoral bone reconstruction was continued around the prosthetic support by fixing the femoral flange of ETO using wiring to hold the receptor bone flush against the HA-treated implant surface. There were no femoral bone grafts. The postoperative rehabilitation protocol imposed 45 days' non-weight-bearing, followed by gradual resumption of weight-bearing with use of two canes until the third month.

### Follow-up

In this prospective study, patients were followed up clinically and radiologically at 6 weeks, 3 months, 6 months and then annually. All included patients were assessed by Merle d'Aubigné (PMA) scoring [11], preoperatively and at final follow-up, except in case of periprosthetic fracture, where the PMA score was estimated retrospectively from preoperative clinical observations.

Frontal pelvis and frontal and lateral hip and femur X-rays were taken at each consultation.

At inclusion, femoral loosening was assessed on Vives' classification [10] as modified by SOFCOT in 1999 [12]; this is a reproducible classification which is more complete than that of Paprosky [13] and avoided resorting to Bethea et al.'s classification [14] for periprosthetic fractures. Loss of acetabular substance was assessed on the SOFCOT classification [10].

During follow-up, the bone/implant interface was analyzed by Gruen zone [15], studying edges, reactive lines, pedestals, osteolyses and calcar femoral reactions to determine metaphyseal and diaphyseal osseointegration. Heterotopic ossifications were classified according to Brooker et al. [16].

Femoral component migration, considered significant when greater than 5 mm, was determined with respect to a fixed landmark on each stem: either the lesser trochanter, when present ( $n = 14$ ), or else the wiring ( $n = 29$ ). X-ray monitoring further allowed analysis of ETO consolidation, and of any femoral stress shielding, whether or not associated with thigh pain [17].

## Statistical analysis

A Student *t* test for matched series was performed for each patient's preoperative and end-of-follow-up status, with a significance threshold set at  $p \leq 0.001$ . End-of-follow-up femoral implant survivorship was analyzed actuarially [18] ( $CI > 95\%$ ), with failure defined as reintervention for aseptic femoral stem loosening.

Dislocation at end of follow-up was studied by recording all incidents of implant dislocation.

## Results

### Population

Over the study period, 162 femoral revisions were performed in the department. Hundred and five involved KAR® (DePuy) hydroxyapatite-coated cementless straight stems, and the other 57 REEF® stems. Finally, 43 patients (= 43 REEF® stems) met the above-mentioned inclusion criteria, after exclusion of 12 repeat implantations secondary to deep infection and two hip replacements secondary to tumor.

Mean age at surgery was 72.4 years (37–94); 33 female, ten male; mean follow-up was 58.2 months (12–92).

Initial etiology was as follows: hip osteoarthritis ( $n = 22$ , 49%), post-traumatic hip osteoarthritis ( $n = 8$ , 19%), osteonecrosis ( $n = 6$ , 15%), congenital hip dislocation ( $n = 6$ , 15%) and rheumatoid arthritis ( $n = 1$ , 2%).

Indications for femoral component revision were: aseptic loosening ( $n = 26$ , 60%), loosening secondary to periprosthetic fracture ( $n = 16$ , 38%), plus one case of recurrent dislocation of a Bousquet's screwed stem with a badly positioned base plate which could not be removed, requiring an ETO for extraction. Revision concerned cemented implants in 17 cases and cementless implants in 26. The intervention was the first arthroplasty revision in 19 cases, the second in 14, and the third or more in ten. In 26 cases (60%), revision was bipolar.

In terms of acetabular bone loss and type of cup used for revision, 12 grade-II cases were managed with a cementless Sunfit® or Novae E® (SERF) megacup, eight grade-III cases by allograft and a Stick® (SERF) cup cemented in a Kerboul reinforcement device, six grade-IV cases by allograft and a Stick® (SERF) cup cemented into a customized SERF support ring.

In terms of femoral bone loss, according to SOFCOT 1999 score there were: one grade 0 (screwed stem), two grade I

with one associated fracture, nine grade II with three associated fractures, 15 grade III with three associated fractures, and 16 grade IV with eight associated fractures. Peroperative reassessment in some cases changed the preoperative grade: five grade II cases became grade III and eight grade III cases became grade IV following femoral shaft preparation and former implant removal.

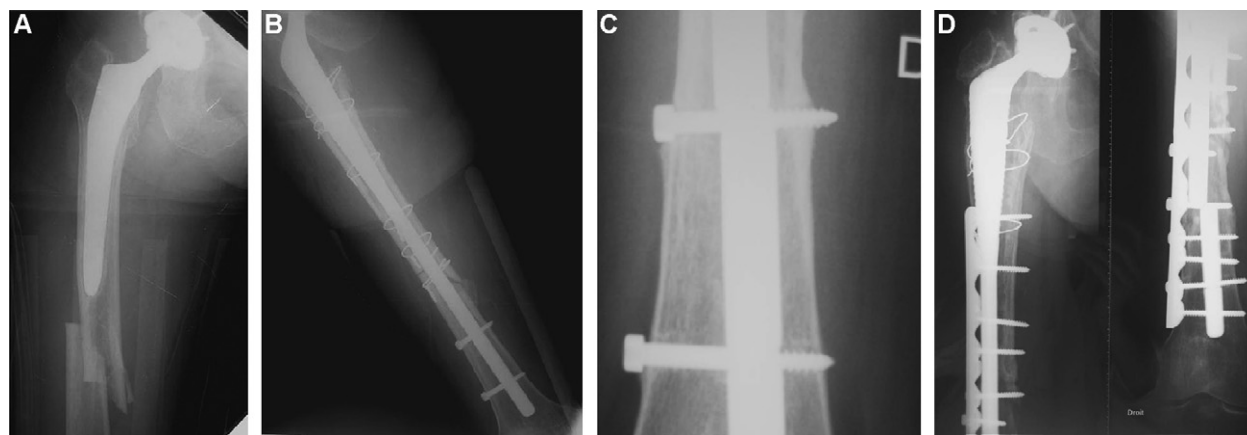
## Peroperative complications

There were two peroperative complications: one case of sciatic palsy, with complete recovery at 1 year; and one supracondylar fracture sustained during arthroplasty reduction and fixed by blade-plate that healed but required subsequent ablation of the plate.

## Early and late postoperative complications

There were nine early and late postoperative complications:

- one patient had prosthesis dislocation at 2 months, requiring reintervention to adjust the position and length of the bearing components; at end of follow-up, there remained 2% dislocation;
- there were three cases of deep infection. Two infected hips were treated by early joint irrigation and exchange of the bearing components; both patients received parenteral antibiotics adapted to the sensitivity of bacteria detected in the peroperative samples for three weeks, followed by 3 months' per os until the inflammation factors (CRP, VS, NFS) returned to normal levels; there was no recurrence. The third patient presented severe implant infection at 4 months, requiring ablation and i.v. antibiotics for 6 weeks followed by 6 weeks' oral antibiotics before a new REEF® (DePuy) stem could be implanted; at 18 months, there had been no recurrence;
- one patient, with cup dislocation secondary to a fall at 1 month, had simple acetabular revision without sequelae;
- there was one fracture of the lateral cortex of the ETO without dislocation, secondary to a fall at 6 months, managed orthopedically; consolidation was incomplete, leaving tight malunion without functional impact;
- there was one fracture of the greater trochanter secondary to a fall, requiring surgical revision to reduce and set the fracture by a trochanteric claw plate;
- there was one fatigue fracture of the stem at 2 years, with nonunion at the fracture site (Fig. 1); this late complication was managed in a different institution by plate osteosynthesis and graft, allowing consolidation without replacing the implant, which showed perfect fixation. This last case was considered as a failure, explained by occult femoral nonunion; this represents a 2% rate of aseptic loosening at end of follow-up for the series as a whole;
- there was one periprosthetic fracture without loosening at 3 years, managed by plate osteosynthesis.



**Figure 1** Mechanical failure due to femoral nonunion and stem rupture. A. Periprosthetic fracture with cementless revision stem, bone loss rated Sofcot 1999 grade II. B. Early post-op AP view. C. REEF® stem fatigue fracture at proximal locking screw, at 24 months. D. Plate osteosynthesis of non united peri-prosthetic fracture.

**Table 1** Pre-operative and end of follow-up Postel Merle d'Aubigné score.

PMA Score	Pain	Mobility	Walking ability	Total
Pre-operative	1.2	2.7	2.1	6
End of follow-up	5.5	5.2	3.8	14.5
Significant difference	$p < 0.001$	$p < 0.001$	$p < 0.01$	$p < 0.001$

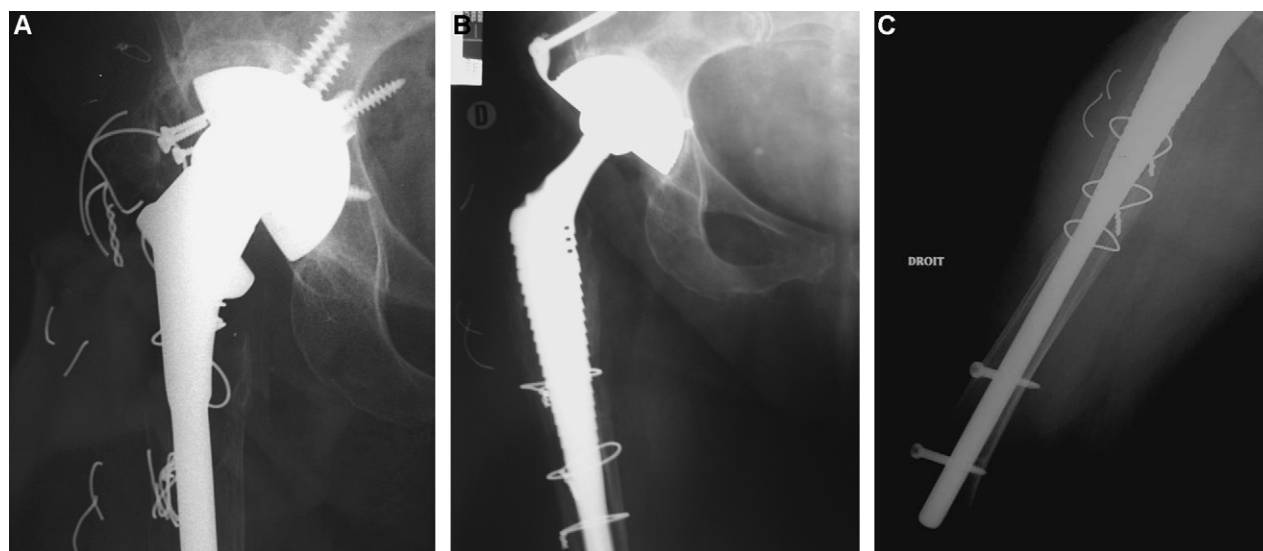
### Clinical results

Seventeen patients had died by end of follow-up; nine were more than 80 years old, and showed loosening associated with femoral fracture. The prosthesis was in place at the time of death in all 17 cases; the PMA score recorded was that obtained at the last follow-up consultation. The mean PMA score for the series was six preoperatively and 14.5 at end of follow-up ( $p < 0.001$ ; see [Table 1](#)). The most significant gains on PMA components were for the pain and

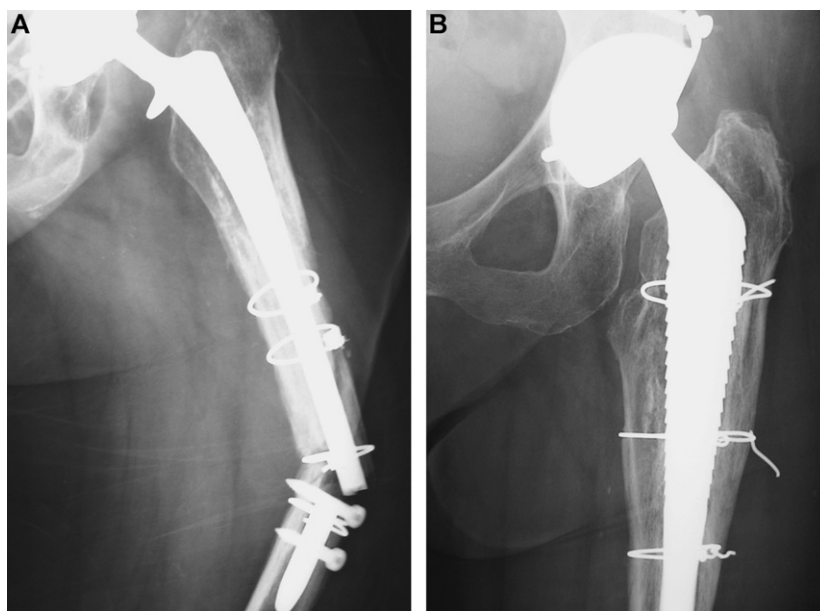
mobility scores, which respectively rose from 1.2 to 5.5 and from 2.7 to 5.2 ([Table 1](#)). At end of follow-up, there were four cases of thigh pain, not associated with any stress shielding or radiolucency abnormality on X-ray. There were no cases of pain around the distal interlocking screw.

### X-ray results

X-ray analysis (see [Figs. 2–4](#)) found no significant stem migration ( $> 5$  mm) at end of follow-up. The ETO was



**Figure 2** Favorable evolution at 5 years' FU. A. Bipolar loosening of a cementless stem, bone loss rated Sofcot grade IV. B. Frontal X-ray view at 5 years. C. Profile X-ray view at 5 years.



**Figure 3** Management of periprosthetic fracture and rupture of a cementless revision stem. A. Bone loss rated Sofcot grade II. B. Favorable evolution at 5 years' FU.

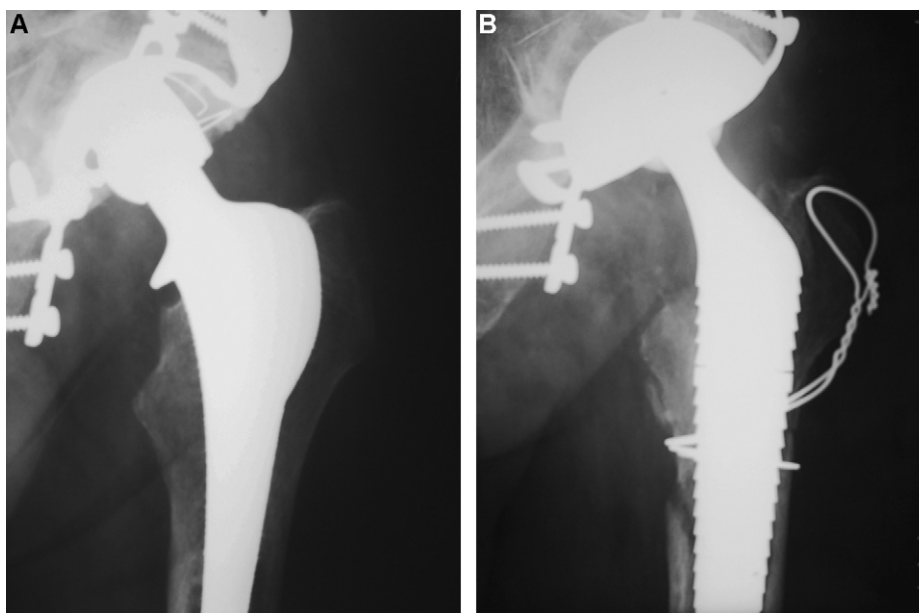
consistently consolidated around the stem except in one case of stem fracture evolving to tight nonunion. Analyzing metaphyseal osseointegration found five cases of radiolucency in Gruen zones one, two, seven and 14 with no evolution over follow-up, and eight cases of severe calcar atrophy. There was no stress shielding or equivalent phenomenon at end of follow-up, indicating good secondary implant osseointegration. There were no screw fractures. At end of follow-up, one hip showed grade IV ossification, four grade III, nine grade II and 14 grade I.

### Statistical results

Five-year actuarial implant survivorship with failure defined by surgical revision for aseptic femoral implant loosening was  $97.7\% \pm 2.3\%$  (CI > 95%). With one case of dislocation at end of follow-up, the final dislocation rate was 2%.

### Discussion

The present series confirmed the findings of Vidalain [19] that the REEF® (DePuy) implant provides an adapted solution



**Figure 4** Management of peroperative periprosthetic fracture sustained during revision of a cementless stem. A. Pre-op X-ray, bone loss rated Sofcot grade I. B. Satisfactory check-up at 52 months, with consolidation of the extended trochanteric osteotomy.

for the most complex cases of femoral arthroplasty revision, thanks to its modular design, original interlocking system and its hydroxyapatite coating.

### Interest of femoral osteotomy

We took the option of extended trochanteric osteotomy, with results indicating good flange consolidation, complete removal of cement and a reduction in the rate of peroperative complications (with just one peroperative fracture). This confirms Migaud et al.'s. [20] report to the 1999 SOFCOT Symposium on femoral revision of aseptic hip replacement that femoral osteotomy enabled complete extraction (95% vs 83% with an endofemoral approach) of cement and granuloma, thus avoiding distal cortical perforation and reducing the risk of peroperative fracture, especially in cases of SOFCOT grade III or IV [12] and gave consistent consolidation (< 1% nonunion vs 20% for trochanter osteotomy).

Thus, the ETO not only provides peroperative exposure but also has biological qualities, stimulating osteogenesis and thus metaphyseal reconstruction; it allows bone adaptation to the stem and, exceptionally, to adjust gluteus medius tension [21].

### Interest of implant

We took the option of an interlocking implant, enhancing rotational stability and reducing distal stem migration. There was no significant stem migration at end of follow-up, and fixation was permanent in 98% of cases. This confirms Kim et al.'s [9] findings at a minimum 3 years' FU with a surface-treated interlocked stem. Mahomed et al. [8] showed interlocking, by enhancing rotational stability by 320% and axial stability by 230%, to be effective against the rotational micromovements implicated by Harris et al. [22] and Chandler et al. [23] in femoral loosening.

Implant fixation was completed by the total hydroxyapatite coating, with only very little nonevolutive radiolucency. The coating has proved useful and reliable in primary hip replacement, and seems equally adapted and effective in revision, due to its osteoconductive properties.

The modularity is an important feature, enabling peroperative adaptation to bone damage which tends to be underestimated in the preoperative plan. Femoral length, offset and anteversion can be varied, and exposure is facilitated in case of isolated acetabulum revision [24]. It also ensures good filling of the metaphysis, thereby promoting lasting biological fixation [25].

### Limitations of the technique

The approach by systematic femoral osteotomy increases surgery time and generally requires long implants so as to bridge the femoral flange.

Our follow-up was too short to draw any definitive conclusion as to the secondary fixation obtained with hydroxyapatite. Radiography was unable to confirm perfect osseointegration of the implant in the prepared bone. Careful study of the X-ray images revealed areas of trabeculae, indicating osseointegration; but little can be said about the

areas without bone/implant contact. Secondary fixation was probably discrete and staggered, and certainly not continuous. A more long-term study would be needed to replicate Langlais et al.'s. [26] findings, with regard to metaphyseal regeneration following revision with hydroxyapatite-coated prostheses, of a 70% contact surface between the hydroxyapatite coating and the osseous neoformation, with cortical thickness growing over time.

Although we appreciate the implant's modularity, this does raise the risk of fretting corrosion and thus of friction couple wear [27]. However, Christie et al. [28] recently reported comparable osteolysis rates in series using a modular cementless stem and in other arthroplasty revision series, with no complications associated with modularity as such. The medium-term follow-up in the present series does not warrant any conclusion as to osteolysis by fretting corrosion.

### Alternatives recommended in the literature

The main alternative to the present technique as regards fixation is cementing, which has shown its limitations with high rates of recurrent loosening –20% for Kempf et al. [1] on 5 years' FU— although results were better using second-generation cements, with 11% recurrent loosening on 6 years' FU. Finally, it has been shown that, in repeated cemented revision, the rate of repeated revision increases with the degree of bone damage [29]. Moreover, cement does not solve the problem of metaphyseal bone defect, even if a recent study did find enhanced bone capital on X-ray in 61% of cases, using a cemented modular stem [30].

Given such disappointing results, certain authors have recommended femoral reconstruction by allograft. The "Exeter" technique reported by Gie et al. [3] consists in cementing a standard stem in a bed of impacted cancellous graft; at 3 years' FU, there was 21.4% stem distal migration in excess of 5 mm. On the other hand, two histological analyses of this impacted graft technique found 100% graft integration [31,32]. Migaud et al.'s. [4] results, on a series with 84% grade II-III bone loss on the SOFCOT classification, were both interesting and promising: at 83 months' FU, there was just one case of recurrent loosening on X-ray (see Table 2). With the same technique on cadavers, Malkani et al. [33] studied rotational and axial implant stability, and reported immediate stability and recovery of proximal femoral integrity. Courpied and Postel [34] recommend bulk cortical allograft for femoral reconstruction, to restore bone capital and provide immediate mechanical reinforcement of the femur. At 4 years and 10 months' FU, Charrois et al. [35] found only three cases of repeat loosening in 18 reconstructions, including 16 grade IV on the SOFCOT classification. There were, however, more complications (30% greater trochanter nonunion), and there are limitations to the use of such allografts: the need for a bone-tissue bank able to provide the requisite quality and quantity of graft, the slight but serious risk of recipient contamination, and the question of the long-term outcome for irradiated grafts.

Since 1986, Wagner [5] has been recommending a reconstruction stem based on the press-fit concept. It ensures good primary stability by elective diaphyseal fixation, irrespective of metaphyseal damage. However, although

**Table 2** Comparative tables for the various published series.

Type of femoral implant	Migaud et al. [4]	Charrois et al. [36]	Boisgard et al. [37]	Kim et al. [9]	Present series
	Impacted cancellous allograft protected by metallic endomedullar mesh	Bulk bone allograft implanted in open femur	Wagner® prosthesis, press-fit stem, non-HAP coated, cementless	Bicontact® prosthesis, non-HAP coated stem, distal interlocking	REEF® prosthesis, total HAP coating, distal interlocking
Patients	19	18	52	68	43
Mean age	58	61	70	52	72
Mean FU	83	58	44	40	54
Deaths	2	0	5	1	17
Pre-op PMA	9.8	9.2	10.5	10.9	6
End-FU PMA	16.3	16.3	14.6	15.9	14.5
Grade I	0	0	0	0	5%
Grade II	11%	0	10%	7%	21%
Grade III	73%	11%	46%	34%	35%
Grade IV	15%	89%	44%	59%	39%
Complications	10	8	12	18	8
Sinkage	0	0	4	0	0
Repeat	1	5	2	0	1
Failure	0	2	2	0	1

medium-term results were good in terms of implant stability, Wagner’s stems have been found to cause thigh pain, sometimes associated with stress shielding and loss of bone capital. A recent medium-term (44 months) assessment of Wagner prostheses (see Table III) found a significant rate of claudication and dislocation due to the design (145° neck valgus) and frequently unequal lower-limb length due to distal migration which is difficult to control [36].

With the same aim of securing a primary anchorage in a healthy area, Vives et al. [37] developed the concept of a temporary long, smooth interlocked stem for use during metaphyseal reconstruction, to be followed by a standard implant to convert to the primary design. In point of fact, the initial assembly often proved reliable enough for secondary revision to be superfluous, and came to be considered as a definitive implant. Moreland et al. [38] demonstrated the clear superiority of their long, coated press-fit stem with diaphyseal anchorage compared to cemented stems [39,40,41] or stems with metaphyseal fixation [42,43] in terms of survivorship, but at the price of much more thigh pain and stress shielding than with the present interlocked stem.

Among all of these techniques or philosophies regarding a variety of kinds of femoral loosening, we opted for a concept combining the advantages of a femoral flange, distal interlocking and a hydroxyapatite-coated stem. Although the clinical results look good, it is difficult to demonstrate complete metaphyseal osseointegration with this kind of implant; thus, it is rather the incidence of negative signs, such as fracture, which indicates the success or failure of the method. Moreover, the magnitude of the surgical approach, and thus of the sequelae, as well as the complexity of adjusting the implant, are such as to focus indication exclusively on grade III and IV femoral loosening.

### Conclusion

Although this prospective study has a short follow-up, femoral surgical revision with diaphyseal fixation by distal interlocking provided good quality primary rotational and axial stability, which is a prerequisite for secondary fixation. It represents a technique of choice in case of grade III or IV bone loss on the SOFCOT scale or of femoral fracture secondary to prosthetic loosening. The present series of 43 patients found the technique to be reliable and reproducible; patients recovered a functional and pain-free joint; and the femoral flange enhanced metaphyseal bone capital without grafting. The stem’s total hydroxyapatite coating doubtless contributed to the good results, with a low complications rate and just one failure. In this era of cementless first-intention treatment, this little developed but promising attitude requires confirmation over a long-term follow-up.

### References

- [1] Kempf JF, Hutten D, Giraud P, Henky P, Schvingt E. Résultats des rescelllements fémoraux. *Rev Chir Orthop* 1989;75:48–52.
- [2] Rubash HE, Harris WH. Revision of nonseptic loose, cemented femoral components using modern cementing techniques. *J Arthroplasty* 1988;3:241–8.

- [3] Gie GA, Linder L, Ling RS, Simon JP, Sloof T, Timperley AJ. Impacted cancellous allografts and cement for revision total hip arthroplasty. *J Bone Joint Surg Br* 1993;73:14–21.
- [4] Migaud H, Jardin C, Fontaine C, Pierchon F, D'herbomez O, Duquenois A. Reconstruction fémorale par des allogreffes spongieuses impactées et protégées par un treillis métallique au cours de révisions de prothèses totales de hanche. Dix-neuf cas au recul moyen de 83 mois. *Rev Chir Orthop* 1997;83:360–7.
- [5] Wagner H. Revisions prothese für das Hüftgelenk. *Ortopäde* 1989;75:25–60.
- [6] Trikha SP, Siongh S, Rayhnam OW, Lewis JC, Mitchell PA, Edge aj. Hydroxyapatite-ceramic-coated-femoral stems in revision hip surgery. *J Bone Joint Surg Br* 2005;87:1055–60.
- [7] Raman R, Kamath RP, Parikh A, Angus pd. Revision of cemented hip arthroplasty using a hydroxyapatite-ceramic-coated femoral component. *J Bone Joint Surg Br* 2005;87:1061–7.
- [8] Mahomed N, Schatzker J, Hearn T. Biomechanical analysis of a distally interlocked press-fit femoral total hip arthroplasty. *J Arthroplasty* 1993;8:129–32.
- [9] Kim YK, Kim HJ, Song WS, Yoo JJ. Experience with the Bicon-tact revision stems with distal interlocking. *J Arthroplasty* 2004;19:27–34.
- [10] Vives P, De Lestang M, Paclot R, Cazeneuve JR. Le descellement aseptique: définitions, classifications. *Rev Chir Orthop* 1989;75:9–31.
- [11] Merle D'aubigne R. Cotation chiffrée de la fonction de la hanche. *Rev Chir Orthop* 1970;56:481–6.
- [12] Migaud H, Ala Eddine T, Demondion X, Jardin C, Laffargue P, Dujardin F, et al. Classification des pertes de substance: reproductibilité des classifications et groupements lésionnels. *Rev Chir Orthop* 2000;86:38–42.
- [13] Paprosky WG, Lawrence WJ, Cameron H. Femoral defect clas-sification: clinical application. *Orthop Rev* 1990;19:9–16.
- [14] Bethea JS, De Andrade JR, Fleming LL, Lindenbaum LL, Welch RB. Proximal femoral fractures following total hip arthroplasty. *Clin Ortop* 1982;170:95–106.
- [15] Gruen TA, Mcneice GM, Amstutz HC. Modes of failure of cemented stem-type femoral components: a radiographic anal-ysis of loosening. *Clin Orthop Relat Res* 1979;141:17–27.
- [16] Brooker AF, Bowerman JW, Robinson RA, Riley LH. Ectopic ossification following total hip replacement. Incidence and a method of classification. *J Bone Joint Surg Am* 1973;55:1629–32.
- [17] Engh CA, Bobyn JD, Glassman AH. Porous-coated hip replace-ment. The factors governing bone ingrowth, stress shielding, and clinical results. *J Bone Joint Surg Am* 1987;69:45–55.
- [18] Lettin AW, Ware HS, Morris RW. Survivorship analysis and confi-dence intervals. An assessment with reference to the Stanmore total knee replacement. *J Bone Joint Surg Br* 1991;73:729–31.
- [19] Vidalain JP. Advantages of a modular interlocked ha coated stem in revisions with major bone deficiencies. *J Bone Joint Surg Br* 2001;83:112.
- [20] Migaud H, Gueguen G, Duhamel A. Reprise fémorale dans les arthroplasties de la hanche. Avantages et inconvénients des abords osseux extensifs. *Rev Chir Orthop* 2000;86:69–72.
- [21] Picault C. Voie d'abord transfémorale pour l'ablation d'implant et le remplacement par la prothèse à verrouillage distal tempo-raire. Monographie impact. Charnoz : les Hortensias. 1993.
- [22] Harris WH, Mulroy RD, Maloney WJ, et al. Intraoperative mea-surement of rotational stability of femoral components of total hip arthroplasty. *Clin Ortop* 1991;266:119–21.
- [23] Chandler HP, Ayres DK, Tan RC, et al. Revision total hip replacement using the S-ROM femoral component. *Clin Ortop* 1995;130:319–22.
- [24] Hozack WJ, Mesa JJ, Rothman RH. Head-neck modularity for total hip arthroplasty. Is it necessary? *J Arthroplasty* 1996;11:397–9.
- [25] Massin P, Geais L, Astoin E, et al. The anatomic basis for the concept of lateralized femoral stem: a frontal plane radiographic study of the proximal femur. *J Arthroplasty* 2000;15:93–101.
- [26] Langlais F, Portillo M, Ropars M, Marin M, Gedoin JE, Thomazeau H. Régénération métaphysaire après reprise par prothèse totale de hanche recouverte d'hydroxyapatite. *Rev Chir Orthop* 2004;90:578.
- [27] Collier JP, Maylor MB, Jensen RE, et al. Mechanisms of failure of modular prostheses. *Clin Ortop* 1992;285:129–39.
- [28] Christie MJ, Deboer DK, Tingstad EM, et al. Clinical experi-ence with a modular cementless femoral component in revision total hip arthroplasty: 4- to 7-year results. *J Arthroplasty* 2000;15:840–8.
- [29] Hutten D, Bouabdallah N, Bassaine M, Wodecki ph. Reprise fémorale dans les arthroplasties de la hanche. Le rescelle-ment simple: jusqu'où aller? *Rev Chir Orthop* 2000;86:72–4.
- [30] Crawford SA, Siney PD, Wroblewski BM. Revision of failed total hip arthroplasty with a proximal femoral modular cemented stem. *J Bone Joint Surg Am* 2000;82:684–8.
- [31] Ling RSM, Timperley AJ, Linder L. Histology of cancellous impaction grafting in the femur. A case report. *J Bone Joint Surg Br* 1993;75:693–6.
- [32] Nelissen RGHM, Bauer TW, Weidenhielm LRA, Legolvan DP, Mikhael WEM. Revision hip arthroplasty with the use of cement and impaction grafting. Histological analysis of four cases. *J Bone Joint Surg Br* 1995;77:351–6.
- [33] Malkani, Arthur L, Voor, Michael J, Fee, Kirk A, et al. Femoral component revision using impacted morsellised cancellous graft: a biomechanical study of implant stability. *J Bone Joint Surg Br* 1996;78:973–8.
- [34] Courpied JP, Postel M. Allogreffes massives pour reconstruc-tion de la diaphyse fémorale. *Rev Chir Orthop* 1989;75:53–4.
- [35] Charrois O, Kerboul L, Vastel L, Courpied JP, Kerboul M. Recon-struction fémorale par allogreffe massive implantée dans un fémur ouvert. Résultats à moyen terme de 18 reconstructions. *Rev Chir Orthop* 2000;86:801–8.
- [36] Boisgard S, Moreau PE, Tixier H, Levai JP. Reconstruction osseuse, inégalité de longueur des membres, taux de luxa-tion de 52 prothèses de Wagner, en révision d'arthroplasties totales de hanche au recul moyen de 44 mois. *Rev Chir Orthop* 2001;87:147–54.
- [37] Vives P, Plaquet JL, Leclair A, Blejwas D, Filloux JF. Tige de reprise verrouillée pour descellement de PTH. Conception, résultats préliminaires. *Acta Orthop Belg* 1992;58:28–35.
- [38] Moreland JR, Martin A, Moreno A. Cementless femoral revision arthroplasty of the hip, minimum 5 years follow-up. *Clin Ortop* 2001;393:194–201.
- [39] Callaghan JJ, Salvati EA, Pellici PM, Wilson PD, Ranawats CS. Results of revision for mechanical failure after cemented total hip replacement. *J Bone Joint Surg Am* 1985;67:1047–85.
- [40] Mulroy WF, Harris WH. Revision total hip arthroplasty with use of so-called second generation cementing techniques for aseptic loosening of the femoral component: a fifteen-year-average follow-up study. *J Bone Joint Surg Am* 1996;78:325–30.
- [41] Kershaw CJ, Atkins RM, Dodd CAF, et al. Revision total hip arthroplasty for aseptic failure: a review of 276 cases. *J Bone Joint Surg Am* 1991;73B:564–8.
- [42] Berry DJ, Harmsen WS, Ilstrup D, et al. Survivorship of unce-mented proximally porous-coated femoral components. *Clin Ortop* 1998;319:168–77.
- [43] Woolson ST, Delaney TJ. Failure of a proximally porous-coated femoral prosthesis in revision total hip arthroplasty. *J Arthro-plasty* 1995;10:S22–8.