Orthopaedics & Traumatology: Surgery & Research (2012) **98**, 450—454

Available online at
SciVerse ScienceDirect
www.sciencedirect.com

Elsevier Masson France
EM|consulte
www.em-consulte.com/en

TECHNICAL NOTE

Early correction of paediatric malunited distal metaphyseal radius fractures using percutaneous callus osteoclasis (''Calloclasis'')

Y. Lefevre, J.-M. Laville*, F. Boullet, F. Salmeron

Department of Pediatric Surgery, F. Guyon Regional Hospital Center, 97405 Saint-Denis, France

Accepted: 21 November 2011

KEYWORDS
Callus osteoclasis;
Radius fractures;
Malunion;
Child wrist fracture

Summary
Introduction: Closed reduction of secondary displacements of distal metaphyseal radius fractures is an easy procedure only when performed within the first ten to fifteen days post-trauma, prior to the occurrence of malunion. When a hard bony callus prevents proper reduction, an open osteotomy is generally advocated.
Hypothesis: We suggest the use of a less invasive technique which aims at correcting early malunion when closed reduction is made impossible: the percutaneous callus osteoclasis.
Materials and methods: Callus osteoclasis consists in a series of multiple bone-drilling in a postage stamp pattern performed under image intensifier using a large diameter pin, at a distance from the growth plate. Once the bone has been weakened, reduction is obtained by using the pin as an intrafocal lever. The pin is then pushed through the opposite cortex to ensure postero-lateral stabilization.
Results: Twenty-one patients were managed using this technique and reported good results with no complications.
Discussion: This technique offers a low aggressive management of malunions and may be performed within two to six weeks after trauma.
Level of evidence: Level IV. Multicenter retrospective study.

Introduction

Fractures of the distal metaphyseal radius are the most common fractures occurring in children and adolescents [1]. Various orthopaedic or surgical treatment options are available which indications depend on the child age, fracture pattern and possible displacement [2—4]. Among these treatments, plaster cast immobilization after reduction or

* Corresponding author. Tel.: +33 2 62 90 54 90, fax: +33 0 26 26 90 54 98.
E-mail address: chir.infantile.fguyon@chu-reunion.fr (J.-M. Laville).

1877-0568/$ – see front matter © 2012 Elsevier Masson SAS. All rights reserved.
doi:10.1016/j.otsr.2011.11.012

not, increases the risk of secondary displacement or even malunion if not corrected prior to bone healing. Spontaneous remodeling of malunited fractures in children demonstrates limitations related to the patient age and gender. Therefore, angular deformities are only considered acceptable when the amount of residual growth is expected to provide a satisfactory correction. Classically, two treatment options are available in the management of secondary displacements: the first one is fracture reduction in the presence of a soft bony callus that is within about 15 days after fracture. The second one is open osteotomy when older malunions with mature callus prevent proper reduction [5]. This last option is usually delayed to provide optimal local remodeling process.

We suggest a small invasive surgical technique which has not been described in the literature yet and aims at correcting malunion when simple reduction cannot be performed anymore. It usually involves patients who were not assessed during plaster cast immobilization and were reviewed between the 15th and 45th day. The interest of this technique was evaluated through the analysis of a multicenter retrospective series of patients.

Materials and methods

Four centers (CHR F.Guyon Réunion, CHU de Bordeaux 2, CHU Robert-Debré Paris, CHU de La Timone Marseille) were involved in the recruitment of patients with malunion of the distal radius identified between two and six weeks after fracture and having required the use of this surgical technique. Our study included displaced non-reduced fractures or secondary displaced fractures in an imperfectly molded plaster cast, which were not detected early enough. Were excluded from this study successful closed reductions having required or not stabilization through percutaneous pinning. Surgeries were retrospectively assessed with radiographic measurement of distal radius displacements in the coronal and sagittal planes. The results were first registered at the time of secondary displacement or neglected fracture diagnosis then during the immediate postoperative period and at last follow-up. Mobilities were compared to the healthy side. Since most radiographs did not include the hand, accurate evaluation of bone age was not possible.

Operative Technique: surgery performed under image intensifier systematically starts with an attempt at closed reduction, mostly for most recent fractures. In case the closed reduction should fail, percutaneous calloclasis will aim at correcting deformity and providing stabilization through intrafocal osteosynthesis by means of a single wire with postero-lateral entry point, orientated in the axis of the bisector of the two posterior and lateral pins used in the conventional Kapandji's technique [6].

Through a small incision made on the postero-lateral aspect of the wrist, slightly proximal to the fracture site, the subcutaneous tissues are dissociated using Halstedt forceps to allow the insertion of a Kirchner wire of about 22 mm in diameter. Calloclasis consists in multiple postage stamp-type perforations carried out in the bony callus (Fig. 1A and B). Once the callus has been sufficiently weakened, the wire is then introduced across the fracture line (Fig. 1C) and reduction is facilitated through a lever manoeuver (Fig. 1D). The wire is then inserted obliquely into the opposite cortex to provide postero-lateral stabilization (Fig. 1E). The osteosynthesis is deeply inserted and protected for a 5-week period of wrist immobilization in the neutral position. The wire is then removed under local anaesthesia after 5 weeks.

In case of malunion secondary to a Salter grade II epiphyseal fracture (epiphyseal displacement with metaphyseal fragment), calloclasis may be considered if performed into the periosteal callus and at a distance from the growth cortex.

Results

This study (Table 1) included 21 patients (15 boys and six girls) of mean age at surgery 11.5 years (range, 7 to 14 years). Nineteen patients had a fracture of the distal one-quarter of the radius and two had a Salter grade II injury. The mean follow-up of the study was 15.8 months (range, 5 to 34 months).

At the time of diagnosis, the mean posterior tilt was 25° (range, 8 to 72°) and the mean radial inclination was 9° (range, 0 to 25°). This treatment was suggested when one of the two measurements revealed an angulation which could not allow spontaneous remodeling through the growth process [7—13]. Deviations exceeding 30° after 8 years old, 20° after 10 and 15° after 13 were not tolerated.

The mean time between initial trauma and calloclasis was 25.8 days (range, 15 to 45 days). All patients were operated according to the described technique with the wire left in place and wrist immobilization in an ante-brachio-palmar cast in the neutral position.

The mean residual posterior tilt after healing was 1.2° (range, 0 to 5°) and radial inclination 1.3° (0° to 3°) (Fig. 2).

No short or long term intra- or postoperative complications were observed. At one-year follow-up, none of the two patients with malunion associated with epiphyseal displacement required technique-related epiphysiodesis.

No loss of mobility exceeding 5° when compared to the healthy side was reported.

Discussion

Many studies have tried to determine the most acceptable degree of displacement after healing and thus the indications for orthopaedic and surgical treatments. The patient age is considered a discriminating factor and should be modulated according to patient gender, since stoppage of the distal physeal growth process occurs around 15 years old (12—15) in girls and 16 years (14—19) in boys. These limitations are thus restrictive for patients older than 8 and more adapted to children less than 8 years of age [7—12].

In children younger than 8, angulation is expected to resolve spontaneously through bone remodeling and growth. Various clinical series report satisfactory results when residual angulation ranges from 15° to 20° in these young children [13,14]. However, Larsen et al. [15] report that malunion exceeding 18° in children older than 11 cannot be corrected spontaneously. According to Houshian et al. [16], malunions secondary to Salter and Harris grade II epiphyseal displacement remodel systematically in children younger

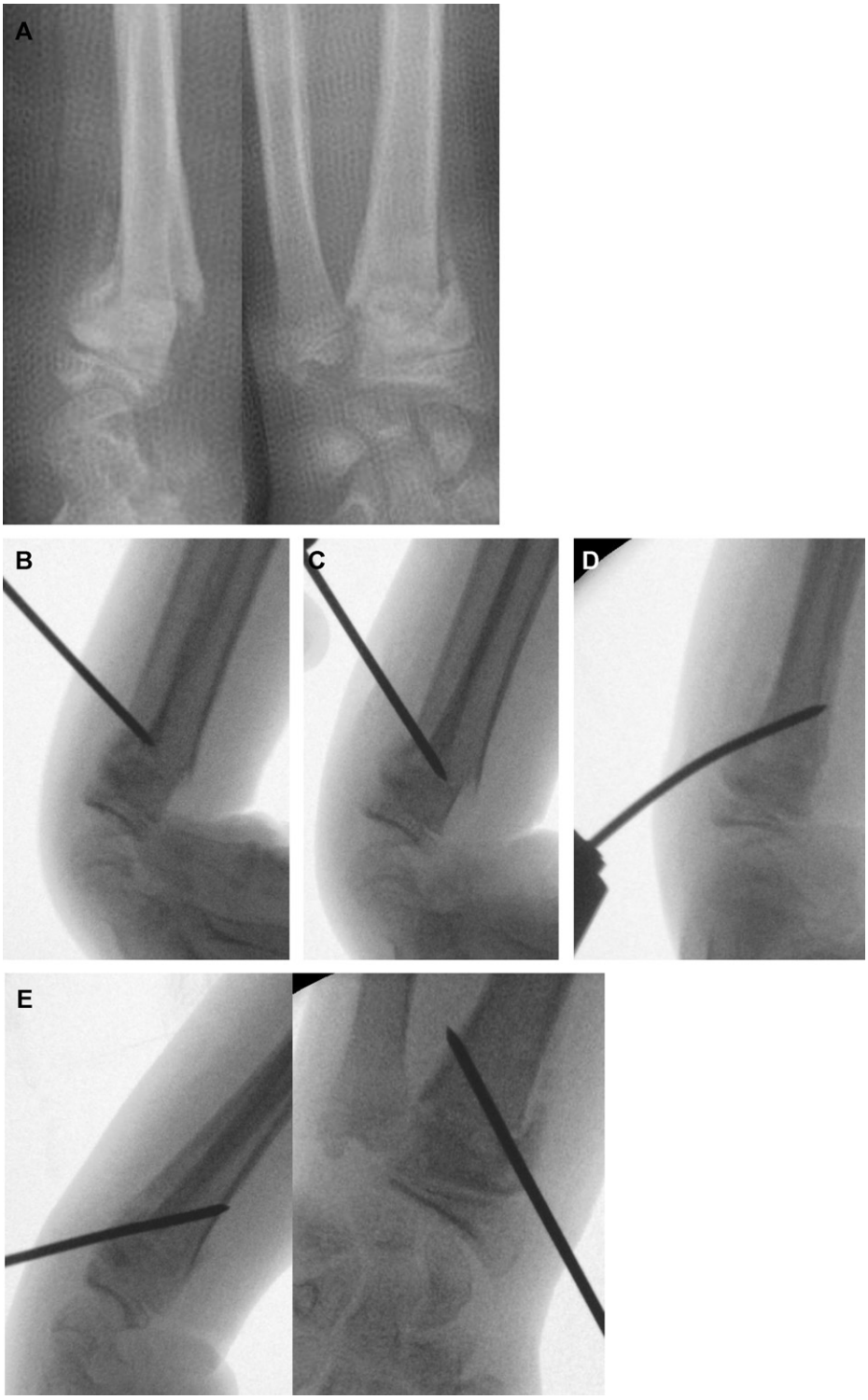

Figure 1 The Calloclasis technique.
A. Malunion at Day 22. B. Postage stamp-type perforations of bone callus. C. Intrafocal insertion of the pin. D. Closed reduction. E. Stabilization through penetration of the opposite cortex.

than 10 but the authors do not establish a highest acceptable limit in older children.

On the other hand, translation results in satisfactory functional recovery [9] but a poorer prognosis is logically reported in the presence of associated angular deformities.

Our series involves fractures having required secondary correction. According to the literature, an open osteotomy would have been advocated in such a case. This is an invasive option with a significant risk of non-union despite adapted screw plate or pin fixation and possible cancellous bone graft

Table 1 List of the clinical cases describing the type of malunion, time to surgery related to the fracture pattern and the results.

	Age (years)	Type	Time (days)	Lateral angle Preoperative (°)	AP angle Preoperative (°)	Lateral angle Postoperative (°)	AP angle Postoperative (°)	Follow-up Months	Lateral angle Final (°)	AP angle Final (°)
1	13	Transverse	24	22		4	2	16	2	2
2	7	Transverse	21	72	2	5	0	12	0	0
3	10	Transverse	28	28	0	-5	0	17	0	0
4	12	S Harris 2	25	20	10	5	0	12	0	0
5	12	S Harris 2	34	8	20	6	0	14	2	0
6	14	Transverse	39	20	4	5	2	12	2	2
7	13	Transverse	18	15	18	0	0	11	0	0
8	9	Transverse	15	38	0	6	0	36	0	0
9	9	Transverse	45	35	10	5	2	34	2	0
10	14	Transverse	19	16	12	2	0	30	2	0
11	8	Transverse	15	40	3	5	3	28	0	0
12	13	Transverse	20	19	5	5	3	19	3	3
13	14	Transverse	35	10	19	0	5	15	0	3
14	13	Transverse	21	18	10	0	5	14	0	4
15	7	Transverse	30	42	7	5	0	13	1	0
16	10	Transverse	21	28	15	0	5	13	0	3
17	14	Transverse	20	20	5	5	6	10	5	5
18	13	Transverse	27	27	4	5	0	8	4	0
19	14	Transverse	45	24	0	3	0	7	3	0
20	10	Transverse	17	20	18	0	3	5	0	1
21	13	Transverse	23	13	25	0	5	5	0	5
Mean	12		25.8	25.5	9.1	2.9	2	15.8	1.2	1.3

Figure 2 Example of valgus malunion at Day 28 and final result after calloclasis and osteosynthesis.

[17—19]. Calloclasis was thus suggested as an alternative treatment to osteotomy since it is a small-invasive and easy to perform technique.

The principle of percutaneous osteoclasy had been suggested by Blackburn et al. [18] in children aged 4 to 15 in the correction of malunions after fractures of both bones of the forearm. This technique was also advocated in the correction of severe rotational deformities of both bones of the forearm by Lin et al. [20]. The technique used in our series does not address to the bone itself but only to the fracture callus which explains the neologism ''calloclasis''.

The risks are similar to those reported with intrafocal percutaneous Kapandji's pinning technique [6]. Subcutaneous tissues should be carrefully retracted to reduce

the risk of injury to the sensitive branch of the radial nerve and a mild force must be applied while perforating to protect the tissues when in contact with the opposite cortex.

This technique may also be used in the treatment of malunion secondary to epiphyseal displacement on condition that the entry point of the pin is carefully located on the periosteal callus and at a distance from the physis under radioscopic control, for preservation of germ cells. No physeal lesion secondary to this technique was reported at one-year follow-up.

Once calloclasis has been performed, cast immobilization to maintain fracture reduction appears sufficient. Therefore, the pin may not be systematically left in place after reduction. Such strategy was not applied in our series.

Percutaneous calloclasis was used for the correction of severe malunions of the distal radius with posterior tilt sometimes associated with valgus displacement of the fragment. These displacements may be treated by percutaneous intrafocal pinning.

We do not consider percutaneous calloclasis a suitable option in the management of anterior displacements due to the risks associated with the percutaneous anterior approach.

This is an early correction technique since it is performed immediatly after unsuccessful closed reduction. Bone callus plasticity is exploited since the callus has been weakened by the multiple perforations thus avoiding the use of complete osteotomy. Calloclasis is an easy procedure when performed early. Therefore, it should not be performed after two months since callus perforation will be more challenging. In such a case, correction should be delayed [21].

In our study, this technique achieved satisfactory correction of deformity with a maximum residual displacement of 5° and final mobilities being comparable with the contralateral side in all cases. Calloclasis may be performed between the 15th and 45th day after fracture when malunion exceeds 30° at the age of 8, 25° at 10 and 15° at 13, these limitations being modulated according to the gender and bone age of the child.

Conclusion

Percutaneous ''Calloclasis'' appears to be a simple and reliable technique specifically adapted to the early correction of fractures of the lower quarter of the radius in children and adolescents with malunion associated with posterior tilt or valgus deformity and for which remodeling was not expected to provide satisfactory correction.

Disclosure of interest

The authors declare that they have no conflicts of interest concerning this article.

References

[1] Rodriguez-Merchan EC. Pediatric skeletal trauma. A review and historical perspective. Clin Orthop Relat Res 2005;432:8—13.
[2] Stutz C, Mencio GA. Fractures of the distal radius and ulna: metaphyseal and physeal injuries. J Pediatr Orthop 2010;30(2):S85—9.
[3] Do TT, Strub WM, Foad SL, Mehlman CT, Crawford AH. Reduction versus remodeling in pediatric distal forearm fractures: a preliminary cost analysis. J Pediatr Orthop B 2003;12:109—15.
[4] Wilkins KE. Principles of fracture remodelling in children. Injury 2005;36:S-A3—11.
[5] Ring D. Treatment of the neglected distal radius fracture. Clin Orthop Relat Res 2005;431:85—92.
[6] Kapandji A. L'ostéosynthèse par double embrochage intrafocal: traitement fonctionnel des fractures non articulaires de l'extrémité inférieure du radius. Ann Chir 1976;30:903—8.
[7] Roberts JA. Angulation of the radius in children's fractures. J Bone Joint Surg Br 1986;68:751—4.
[8] Price CT, Flynn JM. Management of fractures. In: Morrissy R, Weinstein S, editors. Paediatric Orthopaedics. Philadelphia: Lippincott Williams and Wilkins; 2006. p. 1431—525.
[9] de Pablos J, Tejero A. Fractures of the shoulder, upper limb and hand. In: Benson M, Fixsen JA, MacNicol MF, et al., editors. Children's Orthopaedics' and Fractures. London: Churchill Livingstone; 2002. p. 609—32.
[10] Noonan KJ, Price CT. Forearm and distal radius fractures in children. J Am Acad Orthop Surg 1998;6:146—56.
[11] Herring JA. Fractures of the forearm. In: Herring JA, editor. Tachdjian's Paediatric Orthopaedics. Philadelphia: W.B. Saunders; 2002. p. 2218—46.
[12] Rang MP, Stearns P, Chambers H. Radius and Ulna. In: Wenger D, Pring M, editors. Rang's Children's Fractures. Philadelphia: Lippincott Williams and Wilkins; 2005. p. 135—50.
[13] Gasco J, de Pablos J. Bone remodeling in malunited fractures in children. Is it reliable? J Pediatr Orthop B 1997;6:126—32.
[14] Johari AN, Sinha M. Remodeling of forearm fractures in children. J Pediatr Orthop B 1999;8:84—7.
[15] Larsen E, Vittas D, Torp-Pedersen S. Remodeling of angulated distal forearm fractures in children. Clin Orthop 1988;237:190—5.
[16] Houshian S, Holst AK, Larsen M, Torfing T. Remodeling of Salter-Harris Type II epiphyseal plate injury of the distal radius. J Pediatr Orthop 2004;24:472—6.
[17] Ring D, Roberge C, Morgan T, Jupiter JB. Osteotomy for malunited fractures of the distal radius: a comparison of structural and nonstructural autogenous bone grafts. J Hand Surg [Am] 2002;27:216—22.
[18] Blackburn N, Ziv I, Rang M. Correction of the malunited forearm fracture. Clin Orthop Relat Res 1984;188:54—7.
[19] Fernandez DL. Correction of post traumatic wrist deformity in adults by osteotomy, bone grafting and internal fixation. J Bone Joint Surg 1982;64A:1164—78.
[20] Lin HH, Strecker WB, Manske PR, Schoenecker PL, Seyer DM. A surgical technique of radioulnar osteoclasis to correct severe forearm rotation deformities. J Pediatr Orthop 1995;15:53—8.
[21] Price CT. Acceptable alignment of forearm fractures in children: open reduction indications. J Pediatr Orthop 2010;30:S82—4.