



ELSEVIER

Kidney Research and Clinical Practice

journal homepage: <http://www.krcp-ksn.com>
 Contents lists available at ScienceDirect



Case Report

A new connecting technique in partial replantation of a ruptured peritoneal dialysis catheter



Yaeni Kim¹, Prashant C. Dheerendra², Yong-Soo Kim^{1,3,*}

¹ Division of Nephrology, Department of Internal Medicine, The Catholic University of Korea, Seoul St. Mary's Hospital, Seoul, Korea

² Division of Nephrology, Department of Internal Medicine, Narayana Hrudayalaya Hospital, Bangalore, India

³ Section of Interventional Nephrology, Department of Internal Medicine, The Catholic University of Korea, Seoul St. Mary's Hospital, Seoul, Korea

ABSTRACT

Article history:

Received 17 March 2014

Received in revised form

13 May 2014

Accepted 4 June 2014

Available online 25 July 2014

Keywords:

Catheter

End-stage renal disease

Peritoneal dialysis

Replantation

Peritoneal dialysis catheter ruptures have been managed by immediate removal and subsequent reinsertion of the catheter which inevitably entails interruption in peritoneal dialysis and a need for vascular access. A 36-year-old man on continuous ambulatory peritoneal dialysis complaining of dialysate leakage was found to have a small rupture near the outer cuff of the peritoneal dialysis catheter. Rather than employing the traditional method of exchanging the whole catheter, a partial replantation procedure to salvage the still-functioning conduit was performed. Two peritoneal dialysis adaptors were used to connect the end of the remaining old catheter to a new extraperitoneal segment of a new catheter and a piece of a transfer set to connect the adaptors. A novel, yet simple and safe, means of partial peritoneal dialysis catheter replantation when managing catheter injuries is suggested.

© 2014. The Korean Society of Nephrology. Published by Elsevier. This is an open access article under the CC BY-NC-ND license (<http://creativecommons.org/licenses/by-nc-nd/4.0/>).

Introduction

Peritoneal dialysis (PD) catheter rupture is rare, but can occur traumatically or spontaneously. When the rupture occurs close or proximal to the exit site, catheter removal with simultaneous reinsertion of a new catheter is the conventional management. However, this requires an interruption in PD and subsequent hemodialysis (HD) catheter insertion for temporary transfer to HD. Therefore, partial replantation of the catheter instead of removal of the whole catheter has been suggested [1–3]. In previous reports of partial replantation, medical adhesive glue or a specific endoluminal connector was used to connect the remaining part of the old catheter to the extraperitoneal segment of a new catheter. In this report, partial replantation using two PD adaptors and part of a

transfer set as a new connecting technique in a patient with a spontaneously ruptured catheter is introduced.

Case report

A 36-year-old man on continuous ambulatory peritoneal dialysis (CAPD) visited an outpatient clinic because of dialysate leakage from the exit site. He began CAPD after surgical implantation of a double-cuff standard swan neck catheter through a paramedian incision in 2005. He had a history of spontaneous PD catheter rupture 7 months earlier. The rupture site was 2 cm distal to the exit site, and a new PD adaptor was connected to the catheter after cutting it at the level of the rupture site. Although the adaptor was located very close to the exit site, CAPD was maintained with the catheter (Fig. 1). At the time of his visit, a small rupture was discovered posteriorly near the outer cuff when the catheter was pulled away from the exit site (Fig. 2). Peritoneal fluid leakage was easily discernible from the rupture site without pericatheter

* Corresponding author. Department of Internal Medicine, The Catholic University of Korea, Seoul St. Mary's Hospital, 222 Banpo-Daero, Seocho-gu, Seoul 137-701, Korea.
 E-mail address: kimcmc@catholic.ac.kr (Y Kim).

leakage, edema, redness, or tenderness at the exit site. The patient was not febrile, nor did he complain of abdominal pain. The PD fluid was clear without laboratory findings of peritonitis. The catheter tip was appropriately positioned inside the pelvic cavity and the catheter function was excellent. Because

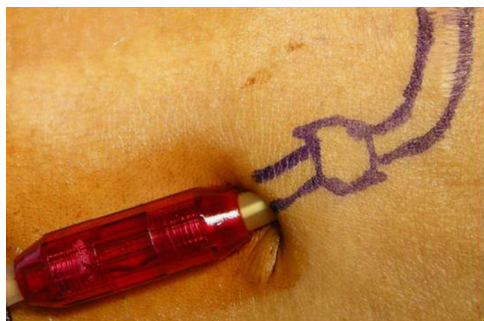

Figure 1. A new PD adaptor was located near the exit site because of previous spontaneous rupture. PD, peritoneal dialysis.

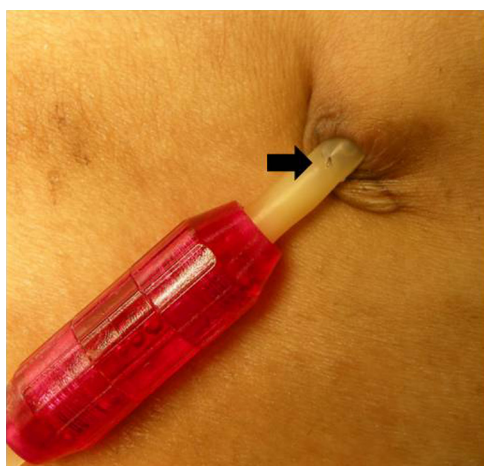


Figure 2. Rupture of the catheter on the posterior side near the outer cuff (arrow).

the catheter rupture site was located between the exit site and the outer cuff, it was decided to rescue the inner conduit and perform a salvage procedure rather than the radical removal and exchange of the whole catheter.

Partial replantation of the catheter was performed under local anesthesia with 1% lidocaine. A longitudinal skin incision from the exit site along the catheter and dissection were carried out to expose the outer cuff and tunnel (Fig. 3A). Then, the catheter was cut proximally to the rupture site and the outer cuff (Fig. 3B). We used two PD adaptors to connect the end of the remaining old catheter to a new extraperitoneal segment of a new catheter (Catheter Adaptor Luer Lock; Fresenius Medical Care Deutschland GmbH, Bad Homburg, Germany). Because we could not directly connect the two PD adaptors, a piece of a transfer set (Stay Safe catheter extension Luer Lock 25 cm; Fresenius Medical Care Deutschland GmbH) was placed between the PD adaptors (Figs. 3C, D and 4). After connecting the old and new catheters, the skin incision was extended downward from the old exit site in order to implant the two PD adaptors into the tunnel to leave 1 cm of tunnel between the exit site and the end of the distal PD adaptor (Fig. 3E). After checking the catheter function using saline irrigation, the wound was closed in layers (Fig. 3F). The patient promptly restarted CAPD after surgery and was discharged on the 2nd




Figure 4. Diagram of the connecting devices. The arrow denotes the part of the transfer set.

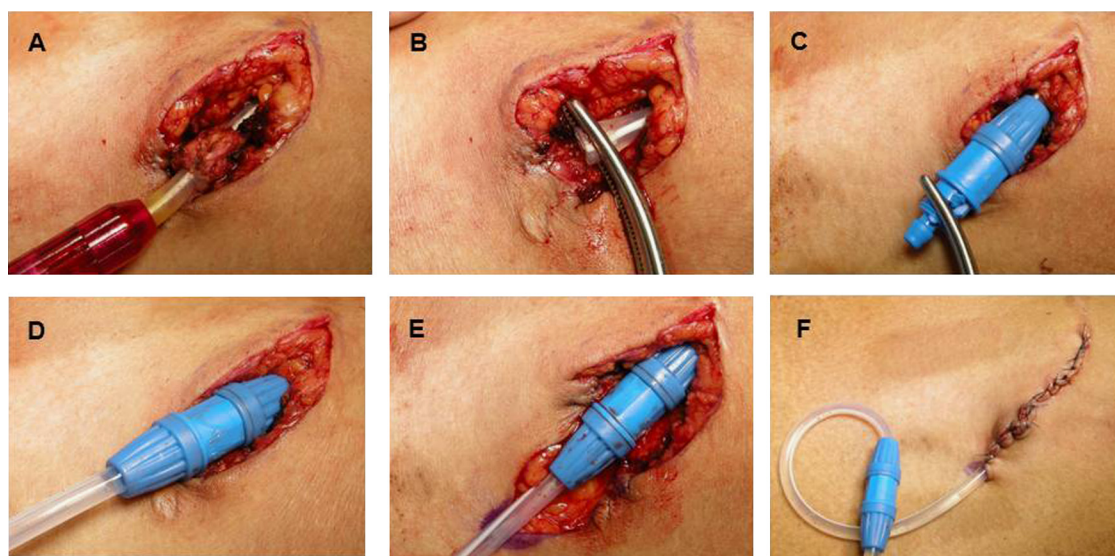


Figure 3. Surgical partial replantation technique. (A) A skin incision was made to expose the outer cuff and tunnel. (B) The catheter was cut proximally to the rupture site and the outer cuff. (C, D) The two catheters were connected using two PD adaptors and a part of a transfer set. (E) The skin incision was extended from the old exit site downward to make a new exit site. (F) The wound was closed in layers and the catheter was connected to a PD adaptor and the transfer set. PD, peritoneal dialysis.

postoperative day. Over 6 months of follow up, the catheter function was excellent and there was no evidence of peritonitis, exit site infection, or dialysate leakage.

Discussion

Few cases of spontaneous rupture of a PD catheter have been reported. All cases with a rupture near the exit site were managed by radical removal of the old catheter and reinsertion of a new catheter [4,5]. This catheter exchange may be complicated by hemorrhage, peritoneal leakage, or malposition of the catheter associated with the surgery, and interruption of PD and HD catheter insertion are required for temporary transfer to HD. Therefore, we sought to address the application of partial replantation (replacement of the extraperitoneal segment of the catheter) of a PD catheter, which has been performed in patients with intractable exit-site/tunnel infection to salvage the still-functioning conduit.

In previous reports of partial replantation, a medical adhesive glue or a specific endoluminal connector was used to connect the remaining part of the old catheter to the extraperitoneal segment of a new catheter. In early reports [1,2], a stenting tube (a segment of siliconized tube taken from an infusion extension set) was inserted into the inner lumen of both catheters, and an adhesive silicone type A glue was used to seal the interfaces between the catheters and the stenting tube. The authors indicated that the length of the stenting tube is very important, because a tube that is too short increases the risk of leakage or disconnection, and a tube that is too long protrudes and causes the patient discomfort. Furthermore, the adhesive material may induce a chemical reaction with some types of catheters. An endoluminal connector was used to connect two catheters in another report [3]. Dialysate leakage due to a defective connection occurred in one out of seven patients, and that connector is no longer commercially available.

In our case, we used two PD adaptors and a part of a transfer set, which were inexpensive and easily accessible because they are kept in the PD unit at all times. The part of the transfer set was detachable and could be connected to a PD adaptor using its Luer Lock design, enabling the connection of the two catheters between two PD adaptors. This new connecting technique was easy to do and there was no dialysate

leakage or disconnection. These devices have been demonstrated to be safe by standardized tests, including intradermal reactivity, cytotoxicity, hypersensitivity, systemic toxicity, hemocompatibility, hemolysis, and sterility studies. All of these biologic evaluations were executed by the Korea Testing Laboratory under the official request of the Korean Food and Drug Administration. However, long-term follow up of the patient is needed to evaluate the biological safety of this procedure. Furthermore, this procedure should not be performed in the same subcutaneous tunnel in a case with concomitant tunnel infection. Therefore, we would recommend this salvage technique in a case of ruptured PD catheter without tunnel infection.

In conclusion, partial PD catheter replantation is a simple, safe, and effective salvage procedure for patients with catheter injury. Our new connecting technique using PD adaptors and part of a transfer set is a novel means of partial PD catheter replantation.

Conflict of interest

The authors have no conflict of interest.

References

- [1] Chao SH, Tsai TJ: Partial replantation of Tenckhoff catheters to treat intractable exit-site/tunnel infection. *J Am Soc Nephrol* 7: 1085–1087, 1996
- [2] Wu YM, Tsai MK, Chao SH, Tsai TJ, Chang KJ, Lee PH: Surgical management of refractory exit-site/tunnel infection of Tenckhoff catheter: technical innovations of partial replantation. *Perit Dial Int* 19:451–454, 1999
- [3] Clouâtre Y, Cartier P, Charbonneau R, Déziel C, Allard M, Madore F: Outpatient CAPD catheter salvage for persistent exit-site/tunnel infection. *Nephrol Dial Transplant* 15:231–234, 2000
- [4] Riu S, Ruiz CG, Martinez-Vea A, Peralta C, Oliver JA: Spontaneous rupture of polyurethane peritoneal catheter. A possible deleterious effect of mupirocin ointment. *Nephrol Dial Transplant* 13:1870–1871, 1998
- [5] Agarwal S, Gandhi M, Kashyap R, Liebman S: Spontaneous rupture of a silicone peritoneal dialysis catheter presenting outflow failure and peritonitis. *Perit Dial Int* 31:204–206, 2011