JACC Vol. 5, No. 5
May 1985:1075–86



# Activation Mapping in Patients With Coronary Artery Disease With Multiple Ventricular Tachycardia Configurations: Occurrence and Therapeutic Implications of Widely Separate Apparent Sites of Origin

LAWRENCE E. WASPE, MD, FACC, RICHARD BRODMAN, MD, SOO G. KIM, MD, FACC, JEFFREY A. MATOS, MD, DEBRA R. JOHNSTON, RN, GALE M. SCAVIN, BS, JOHN D. FISHER, MD, FACC

*Bronx, New York*

**Catheter or intraoperative activation mapping studies, or both, were performed in 17 patients with coronary artery disease with two to four distinct configurations of ventricular tachycardia, resistant to a mean of 12.1 ± 6.0 antiarrhythmic drug trials per patient. Mapping studies were performed to guide anticipated surgical ablation of arrhythmias. Activation map data were adequate to determine sites of origin of 30 (64%) of 47 observed tachycardia configurations. These 30 ventricular tachycardias (26 observed clinically) were mapped to 22 separate endocardial sites of origin. Sites of origin of distinct tachycardias were identical or closely adjacent (within 3 cm) in six patients and widely separate (≥4 cm) in eight patients (47% of the group). Activation maps were not adequate to determine sites of origin of 17 (36%) of the 47 tachycardias, including all configurations in three patients.**

**Fifteen patients underwent surgery for control of ventricular tachycardia: aggressive, map-guided endocardial resection (mean 26.5 ± 14.2 cm$^2$) in 12 patients with identified sites of tachycardia origin and extensive resection of visible endocardial scar (2 patients) or encircling endocardial ventriculotomy (1 patient) in those in whom the sites of origin of all clinical tachycardias remained undetermined. Two inoperable patients were treated with amiodarone. During postoperative electrophysiologic tests (11 of 13 surgical survivors), ventricular tachyarrhythmias were initially uninducible in only 4 of 11 patients. However, in two patients only nonclinical arrhythmias (ventricular flutter) were induced. Six (21%) of 29 clinical tachycardias whose sites of origin were either not determined or not resected (right septum or papillary muscle) remained inducible in five patients. Using previously ineffective antiarrhythmic drugs, initially inducible arrhythmias became uninducible (two patients), or harder to induce than preoperatively (five patients). As a result of surgical resections alone or in combination with previously ineffective drugs (and amiodarone in two inoperable patients), there were no recurrences of ventricular tachycardia in 14 (93%) of 15 patients discharged during 19.0 ± 14.3 months of follow-up study.**

**Thus, activation mapping may commonly reveal separate apparent sites of origin for clinically observed, morphologically distinct, highly drug-refractory ventricular tachycardias in patients with coronary artery disease with multiple tachycardia configurations. Extensive surgical resection of identified sites of origin may be required to ablate arrhythmias in these patients. Tachycardias whose sites of origin are not identified or resected may remain inducible. However, aggressive surgical excisions may alter regions involved in the genesis or maintenance of these arrhythmias because they become more difficult to induce postoperatively, more amenable to drug therapy and do not recur.**

***(J Am Coll Cardiol 1985;5:1075–86)***

From the Department of Medicine, Division of Cardiology, Cardiac Arrhythmia Service, and the Department of Surgery, Cardiothoracic Division, Montefiore Medical Center, Montefiore/Moses Division, and the Albert Einstein College of Medicine, Bronx, New York. This study was presented in part at the 56th Scientific Sessions of the American Heart Association, Anaheim, California, November 1983. Manuscript received July 24, 1984; revised manuscript received December 4, 1984, accepted December 20, 1984.

Address for reprints: Lawrence E. Waspe, MD, Cardiac Arrhythmia Service, Division of Cardiology, Montefiore Medical Center, 111 East 210th Street, Bronx, New York 10467.

Studies of epicardial and endocardial activation during sustained ventricular tachycardia suggest that ventricular tachycardia associated with coronary artery disease originates near the endocardial surface, along the border of an area of previous infarction (1–5). Not uncommonly, two or more morphologically distinct tachycardia configurations are observed in patients with recurrent ventricular tachycardia (5–8). It has been suggested (3,5,7,9) that such morphologically distinct tachycardias almost always arise from the same or

©1985 by the American College of Cardiology

0735-1097/85/$3.30

JACC Vol. 5, No. 5
May 1985:1075–86

closely adjacent endocardial sites, and that different electrocardiographic configurations may be due to changes in exit location from a single reentrant circuit. One implication of this is that only limited surgical excisions need to be performed to ablate drug-resistant ventricular tachycardia, even in patients with more than one tachycardia configuration (3,5,7).

We performed catheter and intraoperative activation mapping in a selected group of coronary artery disease patients with multiple distinct configurations of recurrent ventricular tachycardia. These patients were particularly refractory to treatment with antiarrhythmic drugs and underwent mapping studies in anticipation of surgical ablation of their arrhythmias. Our purpose was to determine whether activation mapping of multiple, morphologically distinct, highly drug refractory tachycardias in patients with coronary artery disease would reveal widely separate sites of origin more commonly than previously reported (3,7,9); this would imply that more extensive surgical excisions might be necessary to abolish arrhythmias in these patients.

## Methods

**Patient selection (Table 1).** Twenty-two patients referred to the Montefiore Medical Center for evaluation of recurrent ventricular tachycardia were refractory to treatment with multiple antiarrhythmic drugs and underwent mapping studies in anticipation of surgical treatment of their arrhythmia. Of these 22 patients, 17 (77%) who had more than one distinct configuration of ventricular tachycardia observed clinically and induced during programmed stimulation studies constituted the study group.

There were 15 men and 2 women in the group, who ranged in age from 40 to 71 years (mean 58). All patients had coronary artery disease (mean 2.3 ± 0.9 coronary arteries with ≥50% reduction in lumen diameter) and had had one or more episodes of myocardial infarction 2 months to 23 years before referral. A left ventricular aneurysm was present in 12 patients. The remaining patients had akinetic areas demonstrated by left ventricular angiography. One patient had undergone previous aneurysmectomy, and one patient had a large posterior pseudoaneurysm. Angiographic left ventricular ejection fraction ranged from 16 to 46% (mean 32 ± 10).

**Electrocardiographic configurations.** From two to four distinct electrocardiographic configurations of ventricular tachycardia occurred spontaneously in each patient and were induced in the electrophysiology laboratory using standard programmed stimulation techniques (10). Morphologically distinct ventricular tachycardias were defined as separate episodes of monomorphic ventricular tachycardia, demonstrating QRS configurations clearly different from each other in leads I, II, aVF and $V_1$ or frontal plane axes, alone or in combination, different by 90° or more. Ventricular tachycardia configurations were classified as follows (Table 2): right bundle branch block when the QRS complex was positive in $V_1$ and left bundle branch block when the QRS was negative in this lead. The frontal plane axis of ventricular

**Table 1.** Patient Data

| Case | Age (yr) | MI Location | Aneurysm Site | EF (%) | Drug Trials* Single | Drug Trials* Combination | Indication for Mapping† |
|---|---|---|---|---|---|---|---|
| 1 | 56 | ASMI | Anteroseptal | 41 | 9 | 10 | Med Refrac VT |
| 2 | 68 | ASMI | Apical | 27 | 5 | 3 | Med Refrac VT |
| 3 | 52 | IWMI | Inferoseptal | 31 | 7 | 13 | Med Refrac VT |
| 4 | 63 | ASMI | Apical | 20 | 7 | 7 | Med Refrac VT |
| 5 | 61 | IWMI and ASMI | Apical | 24 | 8 | 14 | Med Refrac VT |
| 6 | 63 | ASMI and SEMI | Apical | 24 | 6 | 3 | Med Refrac VT |
| 7 | 40 | ASMI | Prior Anx | 43 | 3 | 2 | Severe CAD |
| 8 | 55 | ASMI and IWMI | Apicoseptal | 46 | 8 | 7 | Med Refrac VT |
| 9 | 65 | IWMI | Inferior (pseudo) | 32 | 1 | 0 | Pseudoaneurysm |
| 10 | 55 | IWMI | None | 45 | 5 | 4 | Med Refrac VT |
| 11 | 55 | IWMI | None | 45 | 7 | 4 | Med Refrac VT |
| 12 | 49 | ASMI | Apical | 19 | 6 | 5 | Med Refrac VT |
| 13 | 71 | ASMI | Anteroseptal | 41 | 4 | 2 | Med Refrac VT |
| 14 | 57 | ASMI | Anteroseptal | 16 | 4 | 4 | Med Refrac VT |
| 15 | 66 | ASMI | Anteroseptal | 25 | 6 | 4 | Med Refrac VT |
| 16 | 52 | ASMI and IWMI | None | — | 8 | 10 | Med Refrac VT |
| 17 | 52 | ASMI | Apicoseptal | 37 | 8 | 11 | Med Refrac VT |

*Number of single antiarrhythmic drugs and drug combinations which failed to prevent ventricular tachycardia initiation during serial electropharmacologic testing (see Methods section for drugs tested). †Mapping studies were performed for ventricular tachycardia that was refractory to treatment with a minimum of four single drugs plus two drug combinations (medically refractory ventricular tachycardia) or in anticipation of urgent cardiac surgery for other reasons (severe coronary disease or pseudoaneurysm) after less complete medical trials (see text). Anx = aneurysmectomy; ASMI = anteroseptal myocardial infarction; CAD = coronary artery disease; EF = left ventricular ejection fraction; IWMI = inferior wall myocardial infarction; Med Refrac VT = medically refractory ventricular tachycardia; MI = myocardial infarction; Pseudo = pseudoaneurysm; SEMI = subendocardial myocardial infarction.

tachycardia was classified as normal when leads I, II and aVF were positive. A left axis was assigned when lead I was positive or isoelectric and leads II and aVF were negative. A right axis was ascribed to tachycardias with a negative complex in lead I and positive complexes in leads II and aVF, and an extreme left axis was assigned to tachycardias with negative complexes in leads I, II and aVF (axis of $-90°$ to $-180°$).

**Electrophysiologic studies.** These involved the insertion of two multipolar electrode catheters through percutaneous introducers into the subclavian and femoral veins. One catheter was positioned in the right ventricular apex and the other across the tricuspid valve to record the His bundle potential. Programmed ventricular stimulation included scanning diastole with one to three ventricular extrastimuli 1 ms in duration at four times diastolic threshold during sinus rhythm and ventricular pacing at cycle lengths of 600 to 425 ms. If extrastimuli failed to induce ventricular tachycardia, bursts of rapid ventricular pacing (10 beats) were delivered at cycle lengths of 500 to 200 ms. If this failed to initiate ventricular tachycardia, the entire protocol was repeated at a second right ventricular site (usually the outflow tract).

In all of the patients, induction of ventricular tachycardia was accomplished by scanning diastole with one to three extrastimuli in the right ventricle during sinus rhythm or ventricular pacing. In all patients, ventricular tachycardias that had been observed clinically were inducible in the laboratory, and either 12 lead electrocardiograms or recordings from at least four surface leads (I, II, aVF and $V_1$) were obtained for comparison with the configurations of tachycardias induced during mapping studies (Fig. 1).

*Previous drug therapy.* Before mapping studies, electropharmacologic testing demonstrated that ventricular tachycardias remained refractory to treatment after a mean of $12.1 \pm 6.0$ trials (range 1 to 22) with different conventional and experimental antiarrhythmic drugs, used singly and in combination. Standard drugs tested included lidocaine, pro-

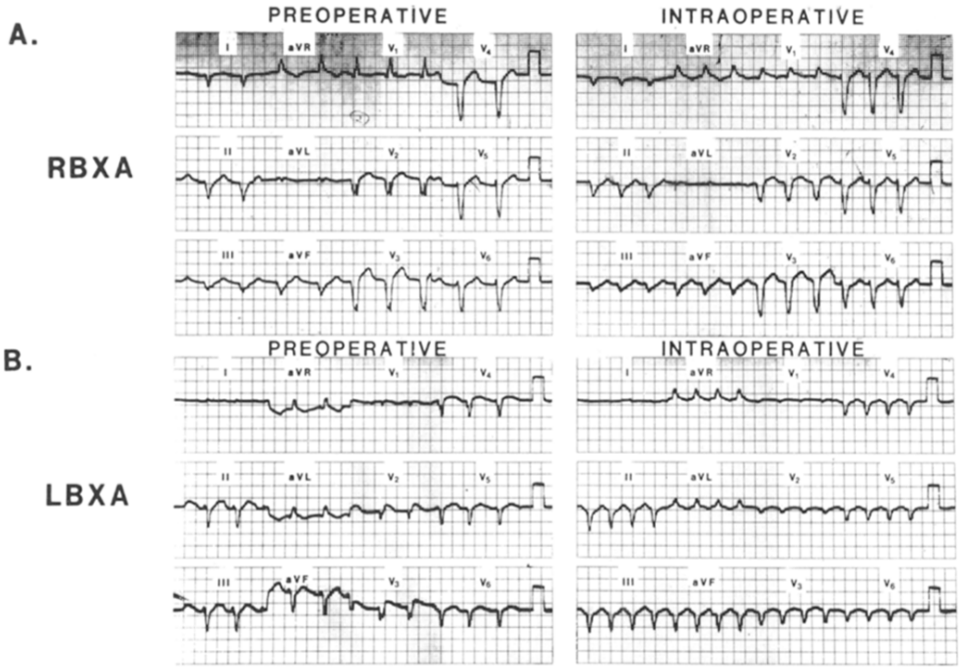


**Figure 1.** Patient 15. Twelve lead electrocardiograms of this patient's two clinically observed ventricular tachycardia configurations obtained on no medications before surgery and at intraoperative mapping. **A, Left.** Preoperative 12 lead electrocardiogram recorded during spontaneous ventricular tachycardia of right bundle branch block-extreme left ($-120°$) axis configuration (RBXA). Tachycardias with a frontal plane axis of $-90°$ to $-180°$ were classified as having an extreme left axis (XA, see text). **Right.** A nearly identical ventricular tachycardia configuration was induced during intraoperative activation mapping with the chest open and the patient on normothermic cardiopulmonary bypass. There were minor differences in R wave height ($V_1$ and $V_4$) and in amplitude of a QRS complex deflection ($V_2$ and $V_3$) in the precordial leads recorded at surgery compared with the recording obtained preoperatively. In addition, the tachycardia rate was faster at surgery. **B, Left.** Preoperative 12 lead electrocardiogram recorded during spontaneous ventricular tachycardia of left bundle branch block-extreme left ($-90°$) axis configuration (LBXA). **Right.** Ventricular tachycardia of a nearly identical configuration was induced intraoperatively. Compared with the electrocardiogram obtained before surgery, the initial R wave in leads II, III and aVF and the Q wave in aVL were slightly smaller and the QRS amplitude in all precordial leads was less. Once again, the ventricular tachycardia rate was faster at surgery.

cainamide, quinidine, disopyramide, propranolol, phenytoin and bretylium. The experimental agents used were aprindine, bethanidine, mexiletine and tocainide.

**Indications for mapping studies (Table 1).** In the majority of the group (15 of 17 patients), mapping studies were performed to guide anticipated surgery for ventricular tachycardia that was refractory to medical therapy. Patients were classified as having medically refractory ventricular tachycardia if one or more tachycardia configurations remained inducible after electropharmacologic testing with a minimum of four single drugs plus two drug combinations. Mapping studies were performed in two patients after less complete medical trials in preparation for arrhythmia surgery during urgent cardiac surgery for other reasons. All patients gave written informed consent before performance of electrophysiologic testing, mapping studies and arrhythmia surgery.

**Catheter mapping studies.** Endocardial catheter mapping was performed during laboratory-induced ventricular tachycardia in four patients, in whom at least one tachycardia configuration was hemodynamically well tolerated. One quadripolar catheter with an interelectrode distance of 0.5 cm (6 Fr USCI) was inserted percutaneously into the femoral artery and advanced to the left ventricle under fluoroscopic guidance. An additional quadripolar catheter was inserted percutaneously into the femoral vein and positioned initially at the right ventricular apex. Catheter positions were verified by multiple plane fluoroscopy. Bipolar electrograms were recorded during each morphologically distinct ventricular tachycardia using an electrode pair with a 1 cm interelectrode distance, from up to 10 sites in the right ventricle and 19 sites (mean = 14) in the left ventricle (Fig. 2). Using this scheme, adjacent mapping sites were approximately 2 to 2.5 cm apart.

**Intraoperative mapping studies.** Intraoperative activation mapping of ventricular tachycardias was performed in all but two patients (Patients 16 and 17). Mapping studies were performed after institution of complete normothermic cardiopulmonary bypass (perfusate temperature 37.5°C). One to two unipolar stainless steel epicardial electrodes (Win-Hirsch Associates) were inserted in the right ventricle to provide a reference electrogram and to perform electrical stimulation. In eight patients, a USCI hexapolar catheter with a 1 cm interelectrode distance was positioned preoperatively at the right ventricular apex and used both for stimulation and recording of a right ventricular reference electrogram during mapping studies.

*After initiation of ventricular tachycardia by programmed stimulation*, bipolar electrograms were recorded with a specially designed probe from 39 to 53 preselected epicardial sites on both ventricles. The probe used for activation mapping consisted of two copper electrodes 1 mm in diameter, with an interelectrode distance of 5 mm, which were supported in a hand-held section of rubber insulation tubing.

*After completion of epicardial mapping, the left ventricle was incised through the aneurysm or infarct.* If spontaneous ventricular tachycardia was not present after ventriculotomy, attempts were made to induce ventricular tachycardia by programmed stimulation. Left ventricular endocardial mapping of ventricular tachycardia was performed under direct vision with the hand-held probe. Bipolar electrograms were recorded from 12 to 62 left ventricular endocardial sites in concentric circumferential rings (Fig. 3). Mapping was first performed at the apparent border of the aneurysm or infarct scar and viable-appearing myocardium. Twelve recordings approximately 1 cm apart were obtained around the circumference of this margin. Subsequently, 12 equally spaced circumferential recordings were obtained at 1 cm incremental distances from this scar-myocardium border, initially on the scar and then on the myocardium. The actual distance between adjacent mapping sites in any one circum-

**Figure 2.** Endocardial mapping sites in the right (RV) and left (LV) ventricles used during preoperative catheter-map studies.

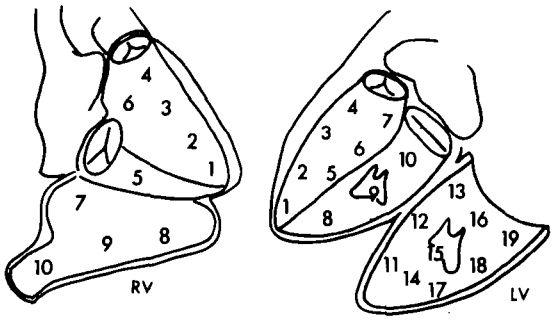


**Figure 3.** Schema used for intraoperative endocardial mapping. The heart (**left**) is viewed from the surgeon's perspective, looking through an apical left ventriculotomy incision. Anatomic sites in the left ventricle are presented schematically on a mapping grid (**right**). During ventricular tachycardia, bipolar electrograms were initially recorded at 12 equally spaced positions (approximately 1 cm apart) around the margin of the scar and viable myocardium (scar edge). Subsequently, circumferential recordings were obtained in 1 cm increments (**mapping grid rings**) on the scar and then on normal-appearing myocardium. ANT = anterior surface; APM = anterior papillary muscle; AV = aortic valve; INF = inferior surface; LAT = lateral surface; MV = mitral valve; PPM = posterior papillary muscle; SEPT = septum.

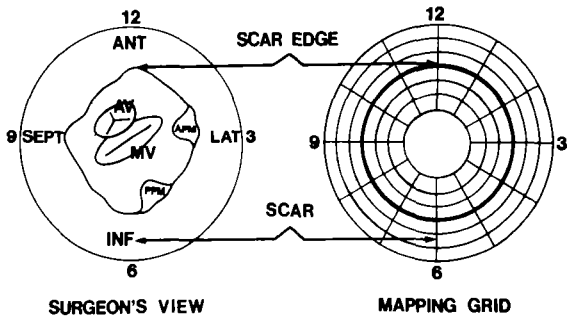

ferential ring ranged from 0.5 to 1.5 cm. Efforts were made to induce and map each tachycardia configuration that had been observed clinically and induced during preoperative electrophysiologic studies.

*Twelve lead electrocardiograms of ventricular tachycardias induced during electrophysiologic testing and mapping studies* were obtained with a Hewlett-Packard three channel electrocardiographic recorder (1505A Sanborn series). Before median sternotomy, precordial leads $V_1$ to $V_3$ were sutured to the patient's skin and leads $V_4$ to $V_6$ were obtained using adhesive electrodes. During mapping studies, surface leads I, II, aVF and $V_1$ were recorded simultaneously with reference and map electrograms, and displayed on the oscilloscope of an Electronics for Medicine Physiologic Recorder (VR-12). A permanent recording was obtained on an eight channel ink jet recorder (Siemens-Elema Mingograf) at a paper speed of 100 mm/s. Electrograms were filtered at 30 to 500 Hz. Occasionally, a simultaneous band pass of 1 to 5,000 Hz was used to help clearly identify the largest rapid deflection of a local electrogram.

**Definitions.** *Local activation time at each mapping site* was defined as the time from the onset of the surface QRS to the time at which the largest rapid deflection of the local bipolar electrogram crossed the isoelectric line. Local activation time was presumed to be indeterminate when a fragmented electrogram without a clearcut largest deflection was recorded.

*The site of origin of ventricular tachycardia*, determined on the basis of catheter or intraoperative mapping, or both, was arbitrarily defined as the site of earliest recorded electrical activity in late diastole before surface QRS onset during ventricular tachycardia (2,3,9,11–13).

*Morphologically distinct ventricular tachycardias in a single patient* were arbitrarily defined as having separate sites of origin when activation map-determined sites of origin were at least 4 cm apart (5,7,13). Tachycardias with sites of origin less distant were assumed to originate from the same arrhythmogenic area.

**Surgical treatment.** On the basis of data obtained during catheter or intraoperative mapping studies, or both, surgical procedures designed to excise or isolate sites of ventricular tachycardia origin were performed in 15 patients. Patients 16 and 17 were not operative candidates because of poor left ventricular function. Surgical therapy consisted primarily of localized map-guided resection of left ventricular endocardial regions identified as sites of ventricular tachycardia origin (7,11,14). Excisions extended 1 to 2 cm beyond each identified site of origin and involved a minimal area of 8 $cm^2$. Resection of an apparent site of origin was not performed when earliest electrical activity during ventricular tachycardia was recorded on a papillary muscle or on the right side of the interventricular septum. Resections at these sites might have resulted in the additional surgical complexities of mitral valve replacement or excision in both ventricles. More extensive resections of visible left ventricular endocardial scar (8) or an encircling endocardial ventriculotomy (15,16), at least 5 mm in depth at the border of remaining endocardial scar, were performed when the sites of origin of one or more clinical ventricular tachycardia configurations could not be identified in a patient.

**Postoperative evaluation and follow-up study.** Postoperatve electrophysiologic evaluation was performed 10 to 24 days after surgery. The programmed stimulation protocol was the same as that used to induce ventricular tachycardia during preoperative studies. If any clinical tachycardia configuration remained inducible with the patient on no antiarrhythmic medication, serial electropharmacologic testing was performed to suppress inducibility. Ventricular tachycardia was defined as uninducible if no more than six repetitive responses were elicited during the entire stimulation protocol at two right ventricular sites.

*Eight patients underwent postoperative angiographic and hemodynamic catheterization.* All patients had continuous electrocardiographic monitoring for at least 1 week after surgery. After discharge, patients were followed up in an outpatient clinic or by contact with private physicians for symptomatic or 24 hour Holter monitor recording recurrences of ventricular tachycardia.

**Statistical analysis.** Group data are presented as the mean ± SD. The Student's *t* test for paired data was used to assess the significance of differences in quantitative data obtained during preoperative and postoperative cardiac catheterization.

## Results

**Mapping studies (Table 2).** Among the 17 patients, 43 distinct configurations of ventricular tachycardia (2 to 4 per patient) had occurred spontaneously and were reproducibly initiated during electrophysiologic tests before mapping studies (*clinical tachycardias*). At the time of catheter or intraoperative mapping studies, 34 (79%) of these 43 tachycardia configurations were inducible. In addition, four other tachycardia configurations that had not been observed clinically, were induced in Patients 6 and 15 at intraoperative mapping (*nonclinical tachycardias*). Thus, catheter or intraoperative activation mapping, or both, were undertaken for a total of 38 of 47 observed ventricular tachycardia configurations (up to 4 tachycardias mapped per patient).

*Sites of origin of ventricular tachycardias.* The data obtained by activation mapping (39 to 53 epicardial and 12 to 62 endocardial sites) were adequate to determine the site of origin of 30 (64%) of the total 47 distinct tachycardia configurations. Twenty-three of these tachycardias were mapped intraoperatively and 7 tachycardias were localized by catheter mapping. During ventricular tachycardia, earliest electrical activation always occurred on the endocardial surface from 5 to 85 ms before onset of the surface QRS. Among

**Table 2.** Mapping Data

| Case | Clinical VT Configurations | Mapped VT* | Site of EEA† | EEA Timing (ms)‡ | Map-Assigned Site of VT Origin§ | Number of Identified Sites of VT Origin (Minimum) |
|---|---|---|---|---|---|---|
| 1 | LBLA | NI | Indeterminate | — | Indeterminate | Indeterminate |
| | RBXA | NI | Indeterminate | — | Indeterminate | |
| 2 | RBRA | RBRA | 1E, Basal anterior | −60 | 1 | 2 |
| | RBLA | RBLA(CL) | 6, Inferoapex | −25 | 2 | |
| 3 | LBNA | NI | Indeterminate | — | Indeterminate | |
| | RBXA | RBXA | 7E, Mid-inferior | −50 | 1 | 1 |
| | LBLA | NI | Indeterminate | — | Indeterminate | |
| 4 | RBLA | RBLA | 6S, Inferoapex | −15 | 1 | |
| | RBNA | NI | Indeterminate | — | Indeterminate | 2 |
| | LBLA | LBLA | 11E, Basal septum | −10 | 2 | |
| 5 | RBRA | NI | Indeterminate | — | Indeterminate | |
| | RBXA | RBXA | 1S, Anterior | −70 | 1 | 2 |
| | LBLA | LBLA | 9E, Mid-septum | −40 | 2 | |
| 6 | RBRA | NI | Indeterminate | — | Indeterminate | |
| | LBLA | LBLA(CL) | Mid-septum (RV) | −10 | 1 | |
| | | LBXA‖ | 8E, Mid-septum | −80 | 1 | 2 |
| | | RBXA‖ | 2E, Anterolateral | −40 | 2 | |
| 7 | RBLA | RBLA | 1S, Anterior | −80 | 1 | 1 |
| | RBXA | RBXA | 1S, Anterior | −80 | 1 | |
| 8 | LBLA | LBLA | 9SS, Mid-septum | −45 | 1 | 1 |
| | RBXA | NI | Indeterminate | — | Indeterminate | |
| 9 | RBXA | RBXA¶ | Inderterminate | — | Indeterminate | Indeterminate |
| | LBLA | LBLA¶ | Indeterminate | — | Indeterminate | |
| 10 | LBLA | LBLA | 6S, Apical septum | −20 | 1 | 1 |
| | RBRA | NI | Indeterminate | — | Indeterminate | |
| 11 | RBXA | RBXA | 5E, Inferoapex | −20 | 1 | 1 |
| | RBRA | RBRA** | Indeterminate | — | Indeterminate | |
| | LBNA | LBNA** | Indeterminate | — | Indeterminate | |
| | LBLA | LBLA** | Indeterminate | — | Indeterminate | |
| 12 | LBLA | LBLA | 7E, Apical septum | −35 | 1 | |
| | LBRA | LBRA | 2S, Anterolateral | −70 | 2 | 2 |
| | RBRA | RBRA | 1E, Anterior | −50 | 2 | |
| | RBLA | RBLA | 12E, Anterior | −80 | 2 | |
| 13 | LBLA | LBLA | 11E, Basal septum | −85 | 1 | |
| | RBNA | RBNA | 10E, Basal septum | −40 | 1 | 1 |
| 14 | LBLA | LBLA¶ | Indeterminate | — | Indeterminate | |
| | RBRA | RBRA¶ | Indeterminate | — | Indeterminate | Indeterminate |
| 15 | RBXA | RBXA | 4E, Inferolateral | −15 | 1 | |
| | LBXA | LBXA | 8E, Mid-septum | −45 | 2 | 2 |
| | | RBRA‖ | 8E, Mid-septum | −65 | 2 | |
| | | RBNA‖ | 10E, Basal septum | −40 | 2 | |
| 16 | RBRA | RBRA(CL) | Inferolateral (LV) | −5 | 1 | |
| | LBLA | LBLA(CL) | Mid-septum (RV) | −5 | 2 | 2 |
| | RBLA | RBLA** | Indeterminate | — | Indeterminate | |
| 17 | RBXA | RBXA(CL) | Inferoapex | −5 | 1 | |
| | RBLA | RBLA(CL) | Inferoapex | −5 | 1 | 2 |
| | RBRA | RBRA(CL) | Anterolateral | −20 | 2 | |

*The electrocardiographic configurations of mapped ventricular tachycardias (VT) are listed. Tachycardias were mapped by endocardial and epicardial activation sequence at surgery or by endocardial activation in the catheterization laboratory (CL). NI indicates that ventricular tachycardia (clinically observed configuration) could not be induced during mapping studies. †The site of earliest endocardial activation (EEA) during ventricular tachycardia is noted according to region of left ventricular endocardium (unless otherwise indicated as right ventricular endocardium) and, where applicable, according to number on the schematic circumferential map of the left ventricular endocardial surface (Fig. 3). Letters next to numbers indicate site of tachycardia origin in relation to the scar-viable myocardium edge: E = at the scar-myocardium border, S = 1 cm from E on scar and SS = 2 cm from E on scar. For some mapped tachycardias, the site of earliest endocardial activation is further described as occurring on the basal (toward the atrioventricular valves), middle (mid) or apical aspect of the septal, anterior, lateral or inferior walls. ‡In relation to surface QRS onset during ventricular tachycardia. §Ventricular tachycardias mapped to areas ≥4 cm apart on the basis of earliest endocardial activation were assumed to originate from different sites of origin (arbitrarily numbered 1 or 2). Tachycardias mapped to regions less distant from each other were assumed to originate from the same arrhythmogenic area (see text). ‖Tachycardia configuration observed only during mapping studies (nonclinical ventricular tachycardia). ¶Endocardial activation spanned entire cardiac cycle. Therefore, localization of the site of origin of ventricular tachycardia on the basis of "earliest" activation was not possible (see text). **Activation mapping was incomplete because only nonsustained ventricular tachycardia could be induced during map studies. CL = activation mapping performed in catheterization laboratory; EEA = earliest endocardial activation; LA = left axis; LB = left bundle branch block; LV = left ventricle; NA = normal axis; NI = not inducible; RA = right axis; RB = right bundle branch block; RV = right ventricle; VT = ventricular tachycardia; XA = extreme left (−90° to −180°) axis.

tachycardias mapped under direct vision at surgery, earliest activation occurred at the border of endocardial infarct scar and normal-appearing myocardium or within 2 cm of this border on the scar.

*Twenty-two sites of origin were determined for the 30 adequately mapped ventricular tachycardia configurations.* Sites of origin were found to be on the left side of the interventricular septum for 11 tachycardias, on the right side of the interventricular septum for 2 catheter-mapped tachycardias, on the anterior left ventricular endocardial surface for 6 tachycardias, on the lateral left ventricular endocardial surface for 5 tachycardias and on the inferior endocardial surface of the left ventricle for 6 tachycardias.

*Single versus multiple sites of origin.* In six patients, activation mapping of ventricular tachycardias revealed only a single or closely adjacent (within 3 cm) site or sites of origin. In eight patients (47%), activation maps demonstrated two widely separate sites of origin (≥4 cm apart) for morphologically distinct ventricular tachycardias (Fig. 4 and 5). Up to three distinct tachycardia configurations were found to have the same or closely adjacent sites of origin (Patients 12 and 15). In some instances (Patients 6 and 15), sites of origin of clinically observed tachycardias appeared to be identical to or closely adjacent to sites of origin of tachycardias induced only during map studies (nonclinical tachycardias).

*Difficulties in mapping studies (Table 2).* Difficulties were encountered in obtaining catheter or intraoperative activation maps for 17 (36%) of the 47 tachycardia configurations. We were unable to determine the site of origin of at least one configuration of ventricular tachycardia in 11 patients. The sites of origin of all clinical tachycardia configurations were indeterminate in three of these patients (Patients 1, 9 and 14). The most frequently encountered problems were inability to induce ventricular tachycardia during intraoperative mapping (nine tachycardia configurations in seven patients) and inability to complete activation maps when only nonsustained ventricular tachycardia could be induced (three tachycardias at intraoperative mapping in Patient 11 and one tachcyardia configuration during catheter mapping in Patient 16). In addition, no site of earliest activation could be determined for four ventricular tachycardia configurations in Patients 9 and 14, in whom the surface QRS onset was indistinct or endocardial activation spanned the entire cardiac cycle.

*Thus, separate apparent sites of origin were found for morphologically distinct ventricular tachycardias in 8 of 17 patients* (22 of the 30 successfully mapped tachycardias). The 47% incidence of multiple ventricular tachycardia origin sites in this group is a minimal number, because at least one tachycardia configuration remained unmapped in 11 patients.

**Surgical treatment (Table 3).** On the basis of data obtained during mapping studies, 15 patients underwent surgical procedures for control of ventricular tachycardia. Map-guided left ventricular endocardial resections (7,11,14) were performed in 12 patients, in whom the sites of origin of one or more ventricular tachycardia configurations were determined (Fig. 6). Excision of additional visible left ventricular endocardial scar was performed in seven of these patients, in whom the site of origin of at least one ventricular tachycardia configuration remained unidentified. The resulting

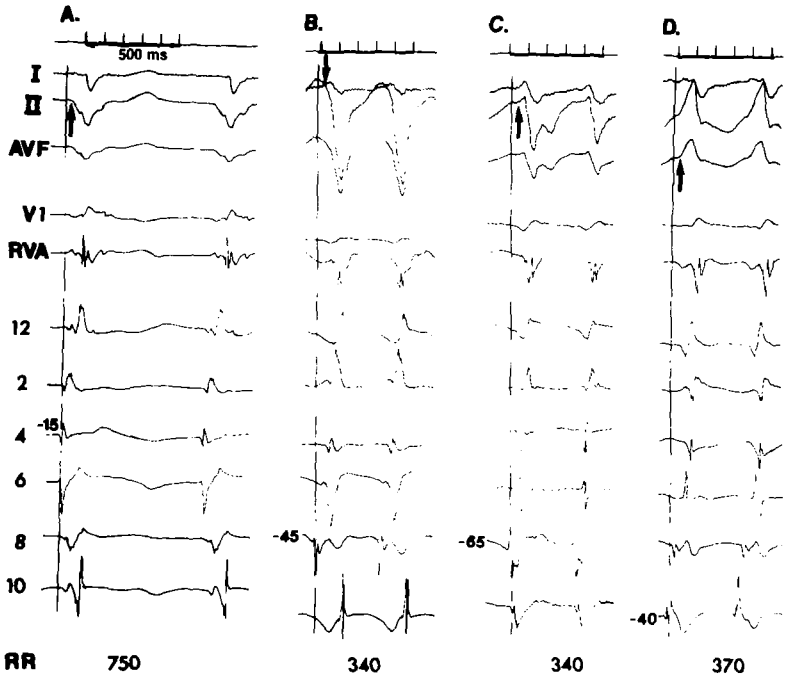


**Figure 4.** Patient 15. Endocardial activation maps obtained during intraoperative mapping of this patient's four distinct ventricular tachycardia configurations (Table 3). For each tachycardia configuration, surface leads I, II, aVF and $V_1$ are displayed with a right ventricular reference electrogram (RVA) and selected local electrograms recorded from sites 2 cm apart around the circumference of the left ventricular endocardial scar edge (Fig. 3). The timing of each local electrogram (largest rapid deflection) is standardized with respect to onset of the surface QRS (**arrows**). Earliest recorded electrical activation (**vertical lines**) during mapping of the patient's two clinical ventricular tachycardia configurations (**A** and **B**) occurred 15 and 45 ms before surface QRS onset, respectively, at widely separate (4 cm) endocardial sites (sites 4 and 8). Ventricular tachycardia configurations **C** and **D** were observed only during intraoperative mapping ("nonclinical" tachycardias). Earliest activation during tachycardias **C** and **D** occurred at endocardial sites 8 and 10, which were within 2 cm of each other and closely adjacent (≤2 cm) to the site of earliest activation (site of origin) of clinical tachycardia configuration **B**. RR = ventricular tachycardia cycle length in ms.

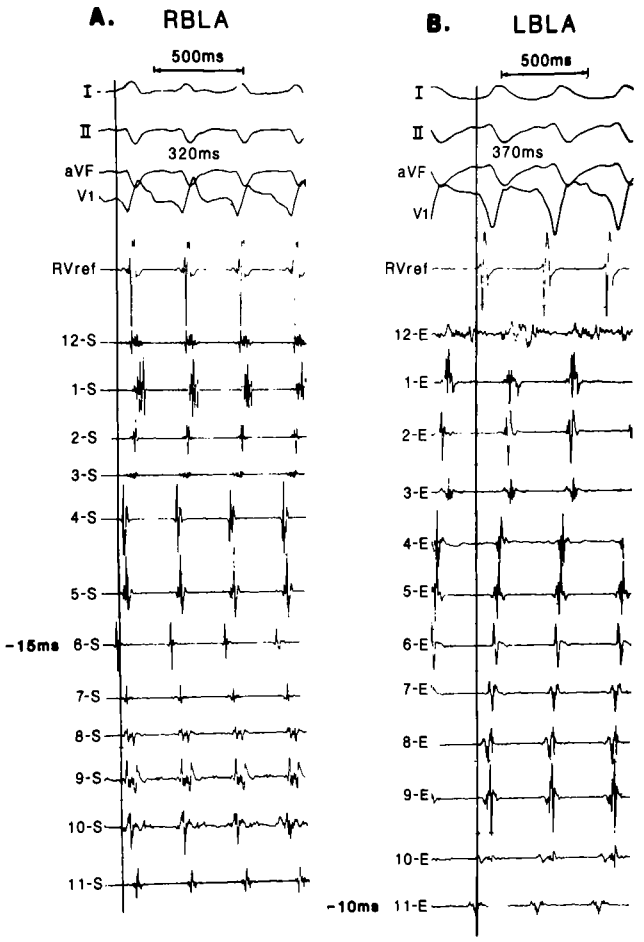


**Figure 5.** Patient 4. Intraoperative endocardial activation maps of two of this patient's three clinically observed ventricular tachycardia configurations (Table 3). Surface leads I, II, aVF and $V_1$ are displayed with a right ventricular reference electrogram (RV ref) and local electrograms recorded at 12 sites 1 cm apart around the circumference of the left ventricular endocardial surface (Fig. 3). The timing of each local electrogram (largest rapid deflection) is standardized with respect to surface QRS onset (**vertical lines**). **A**, Ventricular tachycardia of right bundle branch block-left axis (RBLA) configuration. Earliest activation was recorded 15 ms before surface QRS onset on the inferior aspect of the left ventricular endocardial scar (site 6-S) 1 cm from the border of the scar and normal-appearing myocardium. **B**, Ventricular tachycardia of left bundle branch block-left axis (LBLA) configuration. The earliest recorded discrete electrogram during this tachycardia occurred 10 ms before surface QRS onset on the anterior-basal aspect of the interventricular septum at the endocardial scar edge (site 11-E). Continuous fragmented electrical activity (for which no local activation time could be assigned) was recorded 1 cm away on the scar edge at site 12-E. Thus, the sites of origin of these morphologically distinct tachycardias (sites of earliest presystolic electrical activity during ventricular tachycardia) were found to lie at widely separate endocardial locations (5 cm apart). The site of origin of one other clinical ventricular tachycardia configuration (right bundle branch block-normal axis) was not determined because this tachycardia could not be induced at intraoperative mapping. E = circumferential mapping sites at the border of endocardial scar and normal-appearing myocardium; S = circumferential mapping sites on left ventricular endocardial scar, 1 cm from the scar edge.

endocardial resections in this group were extensive, extending to a depth of 3 to 8 mm and involving areas of 8 to 48 $cm^2$ (mean 26.5 ± 14.2). The mean weight of tissue excised was 11.8 ± 8.4 g. Regions identified as sites of origin of ventricular tachycardia were not resected when localized on the right side of the interventricular septum (Patient 6) or at the base of a papillary muscle (Patient 11). In Patients 4, 7, 13 and 15, endocardial resection was supplemented by a shallow endocardial ventriculotomy 5 mm in depth (16) to isolate any remaining areas of scar in the left ventricle (Fig. 6).

*Of three patients in whom the sites of origin of all clinical tachycardia configurations remained undetermined*, Patients 1 and 14 underwent extensive resection of most of the visible left ventricular endocardial scar and Patient 9 underwent deep encircling endocardial ventriculotomy (15) along the border of the entire scarred region in the left ventricle. Patients 16 and 17, who were inoperable because of poor left ventricular function, were treated empirically with amiodarone and type I antiarrhythmic drugs. Among the 15 surgically treated patients, left ventricular aneurysmectomy was performed in 11 patients, and 11 patients received a mean of 2.3 ± 0.7 coronary artery bypass grafts.

*Operative and postoperative results.* The 30 day operative mortality was 13% (two patients): Patient 13 died of progressive circulatory failure and Patient 15 died as a result of perioperative coronary spasm (17,18). During postoperative cardiac catheterization in 8 of 13 surgical survivors, left ventricular ejection fraction remained unchanged from preoperative values (28 ± 11% before surgery versus 30 ± 10% after surgery) and left ventricular end-diastolic pressure decreased from 24 ± 5 to 17 ± 5 mm Hg ($p < 0.02$).

**Postoperative electrophysiologic studies (Table 3).** Eleven of 13 operative survivors underwent programmed ventricular stimulation 10 to 24 days after surgery. Ventricular tachyarrhythmias were uninducible after surgery in only 4 of 11 patients. However, in two patients only nonclinical arrhythmias were induced (ventricular flutter). Six (21%) of 29 clinical ventricular tachycardia configurations remained inducible in five patients. These tachycardia configurations were ones for which sites of origin could not be determined (four tachycardias in three patients) or whose sites of origin were not resected (right septum or base of a papillary muscle in two patients). Aggressive resection of identified sites of ventricular tachycardia origin prevented postoperative induction of these tachycardia configurations. During serial drug testing after surgery in patients with inducible ventricular tachyarrhythmias, previously ineffective antiarrhythmic agents rendered ventricular tachycardia uninducible (two patients) or harder to induce (requiring more extrastimuli) and slower and better tolerated than during preoperative testing on the same medications (five patients). Thus, surgery may have altered regions essential for ventricular tachycardia maintenance in these patients because their arrhythmias became more drug-responsive.

**Table 3.** Treatment and Follow-Up Study

| Case | Number of Identified Sites of VT Origin | Surgical Procedure* | | Postoperative EPS† | | Long-Term Drug Therapy‡ | Follow-Up (mo) | Clinical Outcome |
|---|---|---|---|---|---|---|---|---|
| | | Area of ER | Area of EEV | Without Drugs | Serial Drugs | | | |
| 1 | Indeterminate | Septum (6 to 12) | None | VFL | VFL | DPH&P | 29 | Death, sudden |
| 2 | 2 | Septum (6 to 1) | None | No VT | — | None | 37 | No VT |
| 3 | 1 | Inferior and septum (5 to 8) | None | VT:LBNA LBLA | VT:LBNA LBLA | Amio | 37 | No VT |
| 4 | 2 | Anterolateral (11 to 2) and inferior (5 to 7) | Remaining scar | No VT | — | None | 29 | No VT |
| 5 | 2 | Septum (6 to 12) and anterolateral (12 to 5) | None | No VT | — | None | 2 | Death, hepatitis; no VT |
| 6 | 2 | Septum and anterior (7 to 12) | None | VT:LBLA | No VT | PA | 21 | No VT |
| 7 | 1 | Septum (9 to 1) and anterolateral (2 to 3) | Remaining scar | — | — | Q | 17 | No VT |
| 8 | 1 | Septum (7 to 1) | None | VT:RBXA | No VT | PA | 2 | Death, CHF; no VT |
| 9 | Indeterminate | None | Entire scar (5 to 1) | — | — | None | 16 | No VT |
| 10 | 1 | Septum (6 to 8) and inferolateral (4 to 5) | None | VT:RBRA | VT:RBRA | Amio | 13 | No VT |
| 11 | 1 | Inferior (5 to 7) | None | VT:RBXA | VT:RBXA | Q&P | 11 | No VT |
| 12 | 2 | Septum (6 to 12) and anterolateral (12 to 5) | None | No VT | — | None | 11 | No VT |
| 13 | 1 | Septum (7 to 1) | Inferior (5 to 7) | — | — | — | 0 | Death, operative |
| 14 | Indeterminate | Septum (7 to 12) and anterior (12 to 3) | None | VFL | VFL | PA | 6 | No VT |
| 15 | 2 | Septum (5 to 12) | Inferolateral (3 to 4) | — | — | — | 0 | Death, operative |
| 16§ | 2 | — | — | — | — | Amio and D | 5 | No VT |
| 17§ | 2 | — | — | — | — | Amio and PA | 49 | No VT |

*Type and extent of surgical procedure performed for control of ventricular tachycardia. Areas of endocardial resection (ER) are denoted according to anatomic region of the left ventricular endocardium and according to numbers (in parentheses) on the schematic circumferential map of the endocardial surface (Fig. 3). A similar notation is used where applicable to describe regions encircled by endocardial ventriculotomy (see text for details). †The results of postoperative electrophysiologic study (EPS) are noted according to inducibility of ventricular tachyarrhythmias on no medication and during serial drug testing. Patients 7 and 9 refused postoperative electrophysiologic study (see text). ‡Patients received long-term drug therapy if drugs were required to prevent ventricular tachycardia induction or made tachyarrhythmias harder to induce or slower during postoperative electrophysiologic study, or both. Drugs were given empirically to Patients 7, 16 and 17 (see text). §Inoperable due to poor left ventricular function. Amio = amiodarone; CHF = congestive heart failure; D = disopyramide; DPH = phenytoin; EEV = encircling endocardial ventriculotomy; EPS = electrophysiologic study; ER = endocardial resection; LA = left axis; LB = left bundle branch block; NA = normal axis; P = propranolol; PA = procainamide; Q = quinidine; RA = right axis; RB = right bundle branch block; VFL = ventricular flutter; VT = ventricular tachycardia; XA = extreme left (−90° to −180°) axis.

**Follow-up (Table 3).** Fifteen patients were discharged from the hospital and followed up for a mean of 19.0 ± 14.3 months (range 2 to 49). There were three late deaths (20%) during this period. Patient 1 died of an arrhythmia recurrence at 29 months, 24 hours after stopping antiarrhythmic drugs. Patient 5 died of hepatitis 2 months after surgery and Patient 8 died of progressive congestive heart failure 2 months postoperatively. As a result of surgical procedures alone or in combination with previously ineffective antiarrhythmic medications, there were no recurrences of ventricular tachycardia in 12 (92%) of 13 operative survivors during follow-up study. In the two inoperable patients, amiodarone combined with a type I antiarrhythmic drugs suppressed arrhythmia recurrences during follow-up periods of 5 and 49 months, respectively.

## Discussion

Endocardial catheter and intraoperative activation mapping are established techniques for guiding surgical therapy of recurrent ventricular tachycardia (2–7,9,11,13,19). An assumption inherent in activation mapping is that the site of earliest presystolic electrical activation during ventricular tachycardia represents the "site of origin" of ventricular tachycardia (3–5,7,11,13,20) or a site critical to the genesis or maintenance, or both, of the arrhythmia (6,12,19,21). Practical application of this premise has come from surgical series (6,7,11,14) in which localized resection of the endocardial area of earliest activation during ventricular tachycardia has resulted in elimination of the arrhythmia.

In previous reports of activation mapping in patients with

JACC Vol. 5, No. 5
May 1985:1075–86

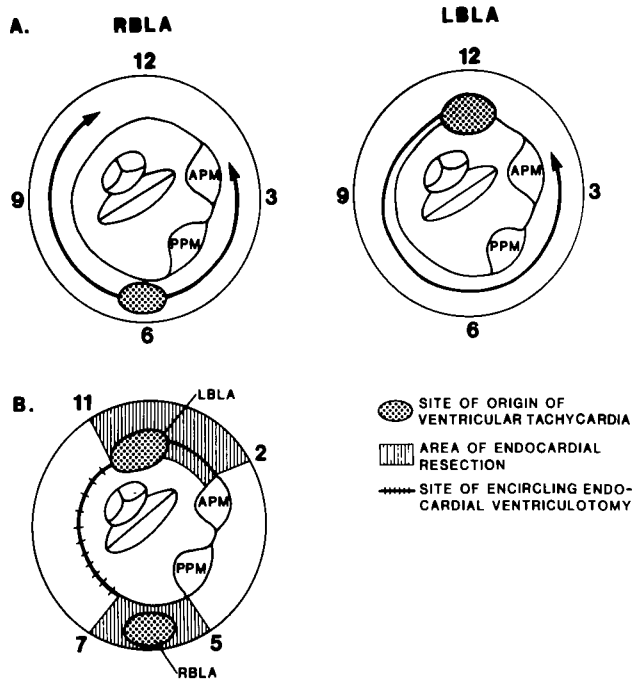


**Figure 6.** Patient 4. **A**, Schematic representation of the endocardial activation sequence recorded during intraoperative mapping of the morphologically distinct ventricular tachycardias illustrated in Figure 5 (format as in Fig. 3). **Left**, Earliest recorded electrical activity during ventricular tachycardia of right bundle branch block-left axis (RBLA) configuration occurred on the inferior surface of left ventricular endocardial scar 1 cm from the scar edge (**stippled area** indicating the site of origin). Ventricular activation then proceeded anteriorly from the site of origin in both a clockwise and counterclockwise direction (Fig. 5). **Right**, The site of origin of ventricular tachycardia of left bundle branch block-left axis (LBLA) configuration was found to lie 5 cm distant from the site of origin of the preceding tachycardia configuration on the anterior-basal aspect of the septum at the endocardial scar edge. Ventricular activation was blocked in the clockwise direction and proceeded only in a counterclockwise fashion, possibly accounting for the longer cycle length of this tachycardia (370 versus 320 ms) (Fig. 5). **B**, Diagram of the surgical procedure performed to control ventricular tachycardias in this patient (format as in Fig. 3). Resection of endocardial scar was guided by the results of activation mapping. Excisions (**striped areas**) extended up to 2 cm beyond identified sites of ventricular tachycardia origin (**stippled areas**). The total area of endocardial scar resected was 20 $cm^2$. A shallow endocardial ventriculotomy 5 cm in depth (**crossed line**) was performed at the border of remaining scar on the septum because one clinical tachycardia configuration (right bundle branch block-normal axis) could not be induced at intraoperative mapping. During postoperative electrophysiologic testing, ventricular tachycardia was completely uninducible, suggesting that all arrhythmogenic sites had been excised or isolated. APM = anterior papillary muscle; PPM = posterior papillary muscle.

ischemic heart disease with drug-resistant ventricular tachycardia (3–5,7–9), 28 to 50% of patients have demonstrated two or more distinct ventricular tachycardia configurations. In all but a few instances, the sites of origin of morphologically distinct tachycardias were found to be identical or closely adjacent (within 3 cm) in a given patient (3–5,7,9). It was suggested that different ventricular tachycardia configurations resulted from changes in the exit route of a wave front from a single reentrant circuit localized near the endocardial surface of the left ventricle, adjacent to an area of previous infarction (3,5,9). Thus, relatively localized endocardial resections were effective for controlling ventricular tachycardia (6,7,14).

In our study, a selected group of 17 patients with coronary artery disease with highly drug-refractory ventricular tachycardia underwent catheter or intraoperative activation mapping, or both, in anticipation of surgical ablation of their arrhythmias. All of these patients exhibited multiple, morphologically distinct ventricular tachycardias. We postulated that mapping studies in this group might reveal a higher incidence of widely separate (≥4 cm) apparent sites of origin for distinct tachycardia configurations than previously reported (3–5,7,9), which would imply that extensive surgical resections might be required to control ventricular tachyarrhythmias in these patients.

**Activation mapping.** Using conventional techniques of endocardial catheter and intraoperative epicardial and endocardial activation mapping (2–4,9,13,19), widely separate sites of origin were found for morphologically distinct tachycardias in 8 (47%) of 17 patients. This incidence is considerably greater than that (10 to 19%) reported by Josephson et al. (7,9), who used similar criteria (≥4 cm) to define separate sites of origin in patients with coronary artery disease undergoing activation map studies.

*The relatively frequent finding of multiple sites of ventricular tachycardia origin in our series* may reflect the particular selection of the study group. Other investigators (6,7,22,23) have performed activation mapping to guide arrhythmia surgery in 20 to 34% of patients with coronary artery disease with recurrent ventricular tachycardia. In these series, patients were refractory to treatment with two to six single antiarrhythmic agents (6,7) or to treatment with a mean of 2.8 ± 1.5 to 4.0 ± 1.8 drug trials (22,24). Our study was similar to other activation mapping series (3,4,6–8,11,14) with regard to mapping techniques, clinical status of the patients and the consistent finding of earliest activation during ventricular tachycardia on the endocardial surface within a 2 cm margin of the border of endocardial scar and normal-appearing myocardium. However, our study group represented only 11% of ischemic heart disease patients referred to our institution for evaluation of ventricular tachycardia. All patients exhibited multiple ventricular tachycardia configurations and were refractory to a mean of 12.1 ± 6.0 antiarrhythmic drug trials. Thus, the common finding of widely separate apparent sites of origin for morphologically distinct ventricular tachycardias in our patients may reflect, in part, the unique drug-refractoriness of the group.

*These mapping results were not a consequennce of inducing nonclinical ventricular tachycardia configurations during map studies*, because 26 of 30 adequately mapped tachycardias had been observed clinically. The inability to induce ventricular tachycardia at intraoperative study, an unsustained duration of ventricular tachycardia during map studies, indistinctness of surface QRS onset during rapid tachycardias or inability to distinguish sites of early activation when ventricular activation occurred throughout the cardiac cycle prevented acquisition of useful activation maps for 17 (36%) of the 47 observed tachycardia configurations. Other investigators (8,11,20) have reported a 10 to 38% incidence of these mapping problems. Because mapping difficulties prevented determination of the site of origin of one or more tachycardia configurations in 11 of the 17 patients, the 47% incidence of multiple ventricular tachycardia origin sites in this group may be a conservative interpretation of the data.

**Surgical therapy.** On the basis of mapping data indicating the frequent occurrence of widely separate sites of origin for morphologically distinct ventricular tachycardias, more extensive endocardial resections were performed to ablate arrhythmias in our group than reported in other series of map-guided arrhythmia surgery (6,7). Endocardial excisions ranged from 8 to 48 $cm^2$ (mean 26.5 ± 14.2) in the present study, compared with 8 to 25 $cm^2$ in the series of Josephson et al. (7) and 1 to 15 $cm^2$ in the series of Mason et al. (6). As in these studies (6,7), the extent of endocardial resection was determined primarily by mapping results. Resection of additional visible endocardial scar or shallow endocardial ventriculotomy (16) around the remaining scar (5 mm in depth and not requiring oversewing) was performed in patients in whom the site of origin of one or more ventricular tachycardia configurations remained undetermined.

**Postoperative inducibility.** Because of inability to map some tachycardias, and because some identified sites of origin were not resected (right septum and papillary muscle), ventricular tachyarrhythmias remained inducible in 7 of 11 patients who underwent postoperative electrophysiologic testing. However, only 6 (21%) of 29 clinical ventricular tachycardia configurations were inducible in 5 of these 11 patients (Table 3). Among patients in whom ventricular tachyarrhythmias remained inducible after surgery, only nonclinical arrhythmias (ventricular flutter) were induced in two patients, whereas clinical ventricular tachycardia configurations whose sites of origin had not been determined (four tachycardias in three patients) or whose sites of origin had not been resected (two tachycardias in two patients) were induced in the remaining patients. Thus, aggressive endocardial resection of identified sites of ventricular tachycardia origin prevented postoperative induction of these tachycardia configurations. In addition, the aggressive surgical techniques employed (endocardial resection or endocardial ventriculotomy, or both) resulted in noninducibility of several tachycardias whose sites of origin were not established at mapping studies (10 tachycardias in six patients)(Tables 2 and 3). Despite initial postoperative induction of ventricular tachyarrhythmias in some patients, surgical procedures may have altered regions essential for ventricular tachycardia genesis or maintenance because these arrhythmias were rendered more drug-responsive after surgery.

Extensive surgical resections were generally well tolerated with a 30 day operative mortality (13%) similar to that (8 to 21%) in other arrhythmia surgery series (6–8). Furthermore, these surgical procedures alone, or combined with previously ineffective antiarrhythmic drugs, prevented the clinical recurrence of ventricular tachycardia in all but one operated patient (who stopped his medications).

**Clinical implications.** Our findings suggest that activation mapping may commonly reveal widely separate apparent sites of origin for clinically observed, morphologically distinct, ventricular tachycardias in highly drug-refractory patients with coronary artery disease with multiple ventricular tachycardia configurations. These data also suggest that a large portion of the scarred endocardial region adjacent to the edge of an infarct may provide clinically important substrate for ventricular tachycardia in these patients. More extensive surgical resections may be required to ablate arrhythmias in this group than have been used in other series of patients (6,7) with less drug-refractory ventricular tachycardia. Patients tolerate extensive intraoperative mapping studies and surgical excisions. Endocardial resection of identified sites of ventricular tachycardia origin prevents the postoperative induction and clinical recurrence of these arrhythmias. Tachycardias whose sites of origin are not identified or resected may remain inducible. However, aggressive surgical excisions may alter regions involved in the genesis or maintenance of tachycardias with unidentified or unresected sites of origin because these arrhythmias become more difficult to induce postoperatively, more amenable to drug therapy and do not recur clinically.

**Limitations of study.** The site of origin of ventricular tachycardia, in this study as in others (2,3,7,9,11,13), was arbitrarily defined as the site of earliest recorded electrical activity in late diastole before surface QRS onset during ventricular tachycardia. The site of earliest recorded activation may not represent the "true" site of origin of ventricular tachycardia, which could lie in an area of dense scarring where recognizable potentials cannot be recorded or in an intramural region accessible only with plunge electrodes (1,12,21). Thus, for example, tachycardias with earliest activation recorded on the right side of the interventricular septum may have originated within the interventricular septum.

Although there is evidence that reentrant ventricular tachycardia in ischemic heart disease may be confined to a relatively small area of contiguous myocardium (5,21,25),

histologic and ultrastructural studies (26) have not defined the actual size of reentrant circuits. Therefore, definitions of what constitutes the site of origin of ventricular tachycardia and what distance between sites of earliest activation during distinct tachycardias represents separate sites of origin must be somewhat arbitrary. It is possible that in some of our patients, transmural mapping with plunge electrodes might have revealed a single intramural site of origin for morphologically distinct tachycardias whose sites of earliest recorded endocardial activity were widely separate. Because of these possibilities, and in view of the reproducibility and resolution limitations of present mapping techniques (4,5,9,12,13,20,27), the separateness of the sites of origin of ventricular tachycardias described in this study can only be considered apparent.

Further studies using mapping techniques to obtain simultaneous recordings from multiple epicardial, intramural and endocardial sites may be necessary to define more precisely the size of reentrant circuits and what actually constitutes the site of origin of ventricular tachycardia (1,12,21,27). The application of such techniques could result in a higher incidence of successful activation mapping of all observed ventricular tachycardia configurations and could permit effective surgical treatment of tachycardias with widely separate sites of origin using more limited resections.

We thank James Scheuer, MD for his thoughtful review of the manuscript and Lori Fields for her assistance in its preparation.

## References

1. Wittig JH, Boineau JP. Surgical treatment of ventricular arrhythmias using epicardial, transmural, and endocardial mapping. Ann Thorac Surg 1975;20:117–26.
2. Josephson ME, Horowitz LN, Farshidi A, Spear JF, Kastor JA, Moore EN. Recurrent sustained ventricular tachycardia: 2. Endocardial mapping. Circulation 1978;57:440–7.
3. Horowitz LN, Josephson ME, Harken AH. Epicardial and endocardial activation during sustained ventricular tachycardia in man. Circulation 1980;61:1227–38.
4. Josephson ME, Horowitz LN, Spielman SR, Greenspan AM, VandePol C, Harken AH. Comparison of endocardial catheter mapping with intraoperative mapping of ventricular tachycardia. Circulation 1980;61:395–404.
5. Josephson ME, Horowitz LN, Farshidi A, Spielman SR, Michelson EL, Greenspan AM. Recurrent sustained ventricular tachycardia: 4. Pleomorphism. Circulation 1979;59:459–68.
6. Mason JW, Stinson EB, Winkle RA, et al. Surgery for ventricular tachycardia: efficacy of left ventricular aneurysm resection compared with operation guided by electrical activation mapping. Circulation 1982;65:1148–55.
7. Josephson ME, Harken AH, Horowitz LN. Long-term results of endocardial resection for sustained ventricular tachycardia in coronary disease patients. Am Heart J 1982;104:51–7.
8. Moran JM, Kehoe RF, Loeb JM, Lichtenthal PR, Sanders JH, Michaelis LL. Extended endocardial resection for the treatment of ventricular tachycardia and ventricular fibrillation. Ann Thorac Surg 1982;34:538–52.
9. Josephson ME, Horowitz LN, Waxman HL, Spielman SR, Untereker WJ, Marchlinski FE. Role of catheter mapping in evaluation of ventricular tachycardia. In: Josephson ME, ed. Ventricular Tachycardia: Mechanisms and Management. Mount Kisco, NY: Futura, 1982:309–30.
10. Fisher JD, Cohen JL, Mehra R, Altschuler H, Escher DJW, Furman S. Cardiac pacing and pacemakers. II. Serial electrophysiologic-pharmacologic testing for control of recurrent tachyarrhythmias. Am Heart J 1977;93:658–68.
11. Horowitz LN, Harken AH, Kastor JA, Josephson ME. Ventricular resection guided by epicardial and endocardial mapping for treatment of recurrent ventricular tachycardia. N Engl J Med 1980;302:589–93.
12. Gallagher JJ, Kasell JH, Cox JL, Smith WM, Ideker RE, Smith WM. Techniques for intraoperative electrophysiologic mapping. Am J Cardiol 1982;49:221–40.
13. Josephson ME, Horowitz LN, Spielman SR, Waxman HL, Greenspan AM. Role of catheter mapping in the preoperative evaluation of ventricular tachycardia. Am J Cardiol 1982;49:207–20.
14. Josephson ME, Harken AH, Horowitz LN. Endocardial excision: a new surgical technique for the treatment of recurrent ventricular tachycardia. Circulation 1979;60:1430–9.
15. Guiraudon G, Fontaine G, Frank R, Escande G, Etievent P, Cabrol C. Encircling endocardial ventriculotomy: a new surgical treatment for life-threatening ventricular tachycardias resistant to medical treatment following myocardial infarction. Ann Thorac Surg 1978;26:438–44.
16. Brodman R, Fisher JD, Johnston DR, et al. Results of electrophysiologically guided surgery for drug resistant recurrent ventricular tachycardia and ventricular fibrillation due to coronary artery disease. J Thorac Cardiovasc Surg 1984;87:431–8.
17. Pichard AD, Ambrose J, Mindich B, et al. Coronary artery spasm and perioperative cardiac arrest. J Thorac Cardiovasc Surg 1980;80:249–54.
18. Buxton AE, Hirshfeld JW, Untereker WJ, et al. Perioperative coronary arterial spasm: long-term follow-up. Am J Cardiol 1982;50:444–51.
19. Waldo AL, Arciniegas JG, Klein H. Surgical treatment of life-threatening ventricular arrhythmias: the role of intraoperative mapping and consideration of the presently available surgical techniques. Prog Cardiovasc Dis 1981;23:247–64.
20. Mason JW, Stinson EB, Winkle RA, Oyer PE, Griffin JC, Ross DL. Relative efficacy of blind left ventricular aneurysm resection for the treatment of recurrent ventricular tachycardia. Am J Cardiol 1982;49:241–8.
21. Boineau JP, Cox JL. Rationale for a direct surgical approach to control ventricular arrhythmias: relation of specific intraoperative techniques to mechanism and location of arrhythmic circuit. Am J Cardiol 1982;49:381–96.
22. Spielman SR, Schwartz JS, McCarthy DM, et al. Predictors of the success or failure of medical therapy in patients with chronic recurrent sustained ventricular tachycardia: a discriminant analysis. J Am Coll Cardiol 1983;1:401–8.
23. Swerdlow CD, Winkle RA, Mason JW. Determinants of survival in patients with ventricular tachyarrhythmias. N Engl J Med 1983; 308:1436–42.
24. Swerdlow CD, Gong G, Echt DS, et al. Clinical factors predicting successful electrophysiologic-pharmacologic study in patients with ventricular tachycardia. J Am Coll Cardiol 1983;1:409–16.
25. Josephson ME, Horowitz LN, Farshidi A, Spielman SR, Michelson EL, Greenspan AM. Sustained ventricular tachycardia: evidence for protected localized reentry. Am J Cardiol 1978;42:416–24.
26. Fenoglio JJ Jr, Pham TD, Harken AH, Horowitz LN, Josephson ME, Wit AL. Recurrent sustained ventricular tachycardia: structure and ultrastructure of endocardial regions in which tachycardia originates. Circulation 1983;68:518–33.
27. Mason JW, Stinson EB, Winkle RA, Oyer PE. Mechanisms of ventricular tachycardia: wide, complex ignorance (editorial). Am Heart J 1981;102:1083–7.