

## Photo Essay

## Canalicular granuloma following recanalization by Sisler's trephine



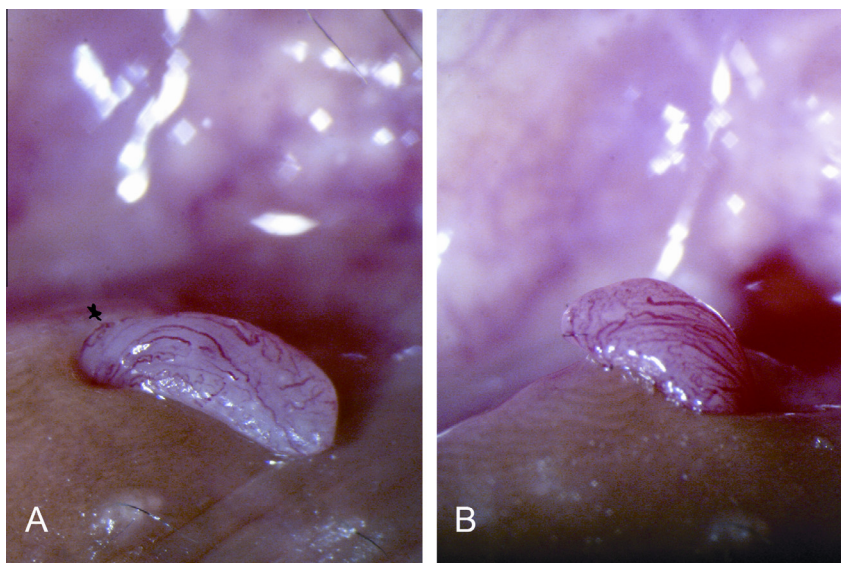
Mohammad Javed Ali

A 54-year-old male underwent a revision external dacryocystorhinostomy (DCR) along with lower canalicular recanalization using Sisler's trephine (Beaver Visitec, Franklin Lakes, NJ, USA). Trephination was performed for a proximal (3 mm) partial obstruction. A bicanalicular Crawford stent (ISCON surgicals limited, Jodhpur, India) was placed and retained for 12 weeks. After stent removal, the Functional endoscopic Dye test (FEDT) showed free flow of dye in the ostium. A week following stent removal, patient presented with a mass protruding from the lower punctum. Examination revealed a 2 mm × 2 mm, pinkish mass with numerous surface vessels and a tapering end near the posterior wall of the vertical canalculus (black star) suggesting its origin from the proximal

canalculus (Fig. 1, Panel A). Gentle displacement with a cotton tipped applicator revealed the punctum to be 360° free without any attachments to the mass (Fig. 1, Panel B). The mass was carefully excised at its tapering end followed by a course of topical steroids. At one year follow up, there was no recurrence and irrigation was patent.

### Comment

Demonstrable canalicular granuloma following trephination by Sisler's trephine<sup>1</sup> and intubation is rare and this case is of an educational value. Canalicular granulomas, papillomas and benign reactive lymphoid hyperplasia are reported



**Figure 1.** Panel A shows a granuloma with surface vascularity arising from the canalculus. Note the punctum (black star). Panel B shows the granuloma to be free from the punctum all around.

Received 29 November 2014; received in revised form 29 December 2014; accepted 12 January 2015; available online 7 February 2015.

© 2015 The Author. Production and hosting by Elsevier B.V. on behalf of Saudi Ophthalmological Society, King Saud University. This is an open access article under the CC BY-NC-ND license (<http://creativecommons.org/licenses/by-nc-nd/4.0/>).  
<http://dx.doi.org/10.1016/j.sjopt.2015.01.004>

Dacryology Service, L.V. Prasad Eye Institute, Road No. 2, Banjara Hills, Hyderabad 500034, India  
e-mail address: [drjaved007@gmail.com](mailto:drjaved007@gmail.com)

following the use of punctal plugs for dry eye patients.<sup>2-4</sup> Among these, pyogenic granulomas secondary to inappropriate sizing of punctal plugs were the most common. These have been successfully managed with excision and removal of punctal plugs.<sup>2-4</sup>

### Conflict of interest

The authors declared that there is no conflict of interest.

### References

1. Sisler HA, Allarakhia L. A new ophthalmic microtrephine. *Ophthalmic Surg* 1990;**21**:656-7.
2. Musadiq M, Mukherji S, Sandramouli S. Pyogenic granuloma following silicone punctal plugs: report of two cases. *Orbit* 2005;**24**:149-51.
3. Ahn HB, Seo JW, Roh MS, et al. Canaliculitis with a papilloma-like mass caused by a temporary punctal plug. *Ophthal Plast Reconstr Surg* 2009;**25**:413-5.
4. Han JH, Park JW, Kim SC. Reactive lymphoid hyperplasia of lacrimal canaliculus caused by a silicone plug. *Ophthal Plast Reconstr Surg* 2012;**28**:e138-139.