Injury Extra 45 (2014) 15–17

Contents lists available at ScienceDirect

Injury Extra

journal homepage: www.elsevier.com/locate/inext

Case report

Aetiology of cardiac arrest in a 'trauma patient': Exploiting trauma CT for concomitant cardiac assessment

Benjamin Clayton [a,b,*]

[a] Department of Cardiology, Derriford Hospital, Plymouth, UK
[b] University of Plymouth, UK

ARTICLE INFO

Article history:
Accepted 2 December 2013

Keywords:
Heart arrest
Ventricular fibrillation
Wounds and injuries
Tomography
X-ray computed
Diagnostic imaging
Myocardial infarction
Delayed diagnosis
Diagnosis
Differential

ABSTRACT

The widespread use of protocolised CT in trauma has the potential to expedite assessment and save lives. However, the exclusion of injury may risk overlooking other important pathology, where patients have been involved in potentially traumatic incidents because of an underlying medical problem.

This case describes a middle-aged patient who suffered an out-of-hospital cardiac arrest while driving his car. Some days after admission he was found to have an occluded left anterior descending coronary artery, which had been poorly visualised on his trauma CT.

The difficulties in identifying coronary occlusion in the critically ill patient are considered, and the utility of ECG-gated CT for cardiac evaluation and its potential impact on rapid diagnosis in trauma is discussed.

1. Introduction

The utilisation of whole-body CT in trauma is now widespread. Its use facilitates the timely and comprehensive evaluation of a critically unwell patient and ensures injuries are not missed [14]. Protocol-driven imaging is encouraged [15], to ensure rapid assessment of potentially serious injuries and expedient intervention. However, assessment of a potential trauma patient entirely by protocol may overlook important comorbidities, relevant to their admission. This case suggests the potential benefits of patient-focussed decision making with regard to imaging in trauma, specifically considering the diagnosis of important coronary artery disease.

2. Case

A 66-year old, previously fit and well man was involved in a witnessed, low-speed motor vehicle collision with a wall. Bystanders found the patient in cardiac arrest and commenced cardiopulmonary resuscitation. On the arrival of the emergency medical services the patient was in ventricular fibrillation (VF), which was successfully treated with defibrillation. The patient underwent endotracheal intubation at the scene, was appropriately immobilised, and transferred to the major trauma centre (MTC) by helicopter.

On arrival at the MTC the patient was assessed by the trauma team and found to have minor, soft tissue injuries to his face and head. Due to his physiological abnormalities of reduced Glasgow Coma Score and pre-admission cardiac arrest he was assessed as being at risk of life-threatening injuries, and underwent whole-body CT imaging. This confirmed the absence of injury but demonstrated extensive right-sided pulmonary consolidation, consistent with aspiration. The coronary arteries were poorly visualised due to blurring caused by cardiac motion (Fig. 1). An ECG demonstrated non-specific changes, with T-wave inversion inferolaterally. Cardiac troponin T was elevated at 159 ng/L.

The patient was transferred to the ICU where therapeutic hypothermia was induced. He was woken and extubated the following day. On day three he underwent invasive coronary angiography which demonstrated occlusion of the left anterior descending artery (Fig. 2) with some limited collateralisation, which was treated with percutaneous coronary intervention. Nonetheless, a subsequent cardiac magnetic resonance imaging study demonstrated evidence of segmental myocardial infarction in the mid and apical anterior wall. He was later discharged without neurological deficit.

* Correspondence to: Department of Cardiology, Derriford Hospital, Plymouth, UK. Tel.: +44 01752 432531.
E-mail address: benjamin.clayton@nhs.net

1572-3461 © 2013 Elsevier Ltd. Open access under the Elsevier OA license.
http://dx.doi.org/10.1016/j.injury.2013.12.001

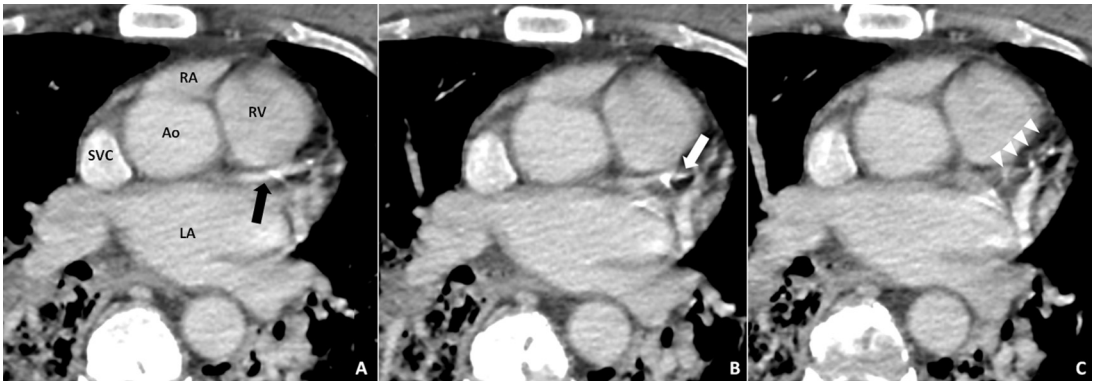

Fig. 1. Now you see it... now you don't? 3 consecutive slices through the heart from the trauma CT. Panel A: SVC – superior vena cava, RA – right atrium, RV – right ventricle, LA – left atrium, Ao – ascending aorta. The left anterior descending (LAD) artery is indicated (black arrow). Panel B: The LAD (white arrow) appears truncated here. Panel C: compared to the discernible artery in panel A, there is now a gap where the LAD should be (white arrowheads). Without ECG gating coronary motion blur makes differentiating arterial occlusion from motion artefact almost impossible.

3. Discussion

This case illustrates the importance of considering both the risk of significant injury and the aetiology of a potentially traumatic event. It emphasises the requirement for carefully considered choices based on individual patient needs, and awareness of other, potentially life threatening conditions, when managing trauma patients.

Cardiovascular disease is the commonest cause of death worldwide [16] and is highly prevalent in trauma patients [4,5]. There is frequently the possibility, therefore, that patients with trauma may also be suffering sequelae of cardiovascular disease, either as a cause or consequence of their injury. The evaluation of such patients is particularly challenging in the context of potential traumatic injury or cardiac arrest. The relative infrequency of VF as a cardiac arrest rhythm in trauma [1,8] may provide a subtle clue, particularly in patients with other cardiovascular risk factors. However other ECG changes, which in other circumstances may be diagnostic of acute myocardial infarction, may be lacking in patients resuscitated from cardiac arrest, despite ongoing myocardial ischaemia [3]. Troponin rise is sensitive to myocardial injury but poorly specific to ischaemic aetiology, although is not elevated by resuscitation efforts [9,13].

Accurate diagnosis of coronary occlusion in the acutely ill or injured patient therefore requires corroborative imaging. Cardiac catheter laboratories are well used to investigating haemodynamically unstable patients, including those in cardiac arrest. However, coronary analysis can also be achieved in many patients using CT, with the addition of 'ECG gating' to the scan protocol, whereby images are linked to the patient's ECG. The scan acquisition is either undertaken in 'chunks' through the heart, with each chunk being acquired at a specific phase in the cardiac cycle ('prospective' ECG gating), or else the scan is undertaken in the standard helical fashion with the patient's ECG recorded concurrently, and images from specific cardiac phases are subsequently extracted ('retrospective' gating).

With both methods, the result is an ability to examine images in a single, consistent phase of the cardiac cycle, usually mid-diastole. This technique allows minimisation of coronary motion, which improves image quality not only of the heart (Fig. 3) but also of other thoracic and mediastinal structures. This can be achieved for a substantially decreased radiation dose [12] or at a maintained dose with significantly improved diagnostic confidence [10]. Gated scanning only requires the attachment of ECG monitoring to the patient prior to the scan and adds a few seconds to the acquisition time.

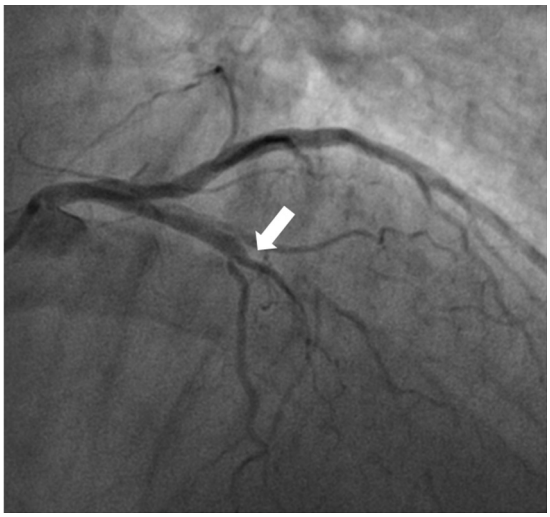

Fig. 2. Fluoroscopic coronary angiogram demonstrating mid vessel occlusion of the left anterior descending artery (white arrow).

Fig. 3. Subsequent, ECG-gated image from the same patient demonstrating the LAD artery stent (black arrowhead). The coronary arteries are now motion-free and can be readily visualised.

Although the need for expeditious assessment may risk scanning protocols becoming rigid, in the interests of saving time and ensuring simplicity, there are many examples where trauma protocols are adjusted based on patient-specific parameters; be these injury severity or mechanism [2] or concern about specific injuries [7] Crucially, the addition of ECG gating to an emergency CT protocol does not significantly affect scan times or create diagnostic delay [11] and may bring with it greater diagnostic yield, without the need for additional patient transfer or investigation.

4. Conclusion

Where patients are at high risk of life-threatening injury, prompt and comprehensive imaging can significantly increase survival [6]. However, trauma patients often have important comorbidities which may be responsible for their traumatic event or its apparent consequences, which must not be overlooked. The addition of ECG-gating to this patient's trauma CT may have provided useful information about the cause of his cardiac arrest in a more timely fashion, without compromising his trauma imaging.

Conflict of interest

The author has no conflicts of interest to declare.

References

[1] Deasy C, Bray J, Smith K, Harriss L, Morrison C, Bernard S, et al. Traumatic out-of-hospital cardiac arrests in Melbourne, Australia. Resuscitation 2012;83(4):465–70.
[2] Dinh MM, Hsiao KH, Bein KJ, Roncal S, Saade C, Chi KF, et al. Use of computed tomography in the setting of a tiered trauma team activation system in Australia. Emerg Radiol 2013 [Epub ahead of print], doi:10.1007/s10140-013-x1124.
[3] Dumas F, Cariou A, Manzo-Silberman S, Grimaldi D, Vivien B, Rosencher J, et al. Immediate percutaneous coronary intervention is associated with better survival after out-of-hospital cardiac arrest: insights from the PROCAT (Parisian Region Out of Hospital Cardiac Arrest) Registry. Circ Cardiovasc Interv 2010;3:200–7.
[4] Ferraris VA, Ferraris SP, Saha SP. The relationship between mortality and preexisting cardiac disease in 5971 trauma patients. J Trauma 2010;69(3):645–52.
[5] Ferraris VA, Bernard AC, Hyde B, Kearney PA. The impact of antiplatelet drugs on trauma outcomes. J Trauma Acute Care Surg 2012;73(2):492–7.
[6] Huber-Wagner S, Lefering R, Qvick LM, Körner M, Kay MV, Pfeifer KJ, et al. Effect of whole-body CT during trauma resuscitation on survival: a retrospective, multicentre study. Lancet 2009;373(9673):1455–61.
[7] Langner S, Fleck S, Kirsch M, Petrik M, Hosten N. Whole-body CT trauma imaging with adapted and optimized CT angiography of the craniocervical vessels: do we need an extra screening examination? AJNR Am J Neuroradiol 2008;29(10):1902–7.
[8] Leis CC, Hernández CC, Blanco MJ, Paterna PC, Hernández Rde E, Torres EC. Traumatic cardiac arrest: should advanced life support be initiated? J Trauma Acute Care Surg 2013;74(2):634–8.
[9] Müllner M, Oschatz E, Sterz F, Pirich C, Exner M, Schörkhuber W, et al. The influence of chest compressions and external defibrillation on the release of creatine kinase-MB and cardiac troponin T in patients resuscitated from out-of-hospital cardiac arrest. Resuscitation 1998;38(2):99–105.
[10] Schernthaner RE, Stadler A, Beitzke D, Homolka P, Weber M, Lammer J, et al. Dose modulated retrospective ECG-gated versus non-gated 64-row CT angiography of the aorta at the same radiation dose: comparison of motion artifacts, diagnostic confidence and signal-to-noise-ratios. Eur J Radiol 2012;81(4):e585–90.
[11] Schertler T, Glücker T, Wildermuth S, Jungius K, Marincek B, Boehm T. Comparison of retrospectively ECG-gated and nongated MDCT of the chest in an emergency setting regarding workflow, image quality, and diagnostic certainty. Emerg Radiol 2005;12:19–29.
[12] Shuman WP, Leipsic JA, Busey JM, Green DE, Pipavath SN, Hague CJ, et al. Prospectively ECG Gated CT pulmonary angiography versus helical ungated CT pulmonary angiography: impact on cardiac related motion artifacts and patient radiation dose. Eur J Radiol 2012;81(9):2444–9.
[13] Skulec R, Belohlavek J, Kovarnik T, Kolar J, Gandalovicova J, Dytrych V, et al. Serum cardiac markers response to biphasic and monophasic electrical cardioversion for supraventricular tachyarrhythmia – a randomised study. Resuscitation 2006;70(3):423–31.
[14] Smith CM, Woolrich-Burt L, Wellings R, Costa ML. Major trauma CT scanning: the experience of a regional trauma centre in the UK. Emerg Med J 2011;28:378–82.
[15] The Royal College of Radiologists. Standards of practice and guidance for trauma radiology in severely injured patients. London: The Royal College of Radiologists; 2011.
[16] World Health Organisation. World heath statistics 2012. Geneva: WHO Press; 2012.