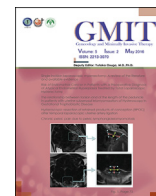

Contents lists available at [ScienceDirect](http://ScienceDirect.com)

# Gynecology and Minimally Invasive Therapy

journal homepage: [www.e-gmit.com](http://www.e-gmit.com)

## Case report

### A case of idiopathic omental hemorrhage

Toshimitsu Hosotani <sup>a,\*</sup>, Akemi Kinoshita <sup>a</sup>, Chika Hirota <sup>a</sup>, Ken Ueki <sup>a</sup>, Shinsuke Satake <sup>b</sup><sup>a</sup> Department of Obstetrics and Gynecology, Shiso Municipal Hospital, Shiso, Hyogo, Japan<sup>b</sup> Department of Surgery, Shiso Municipal Hospital, Shiso, Hyogo, Japan

#### ARTICLE INFO

##### Article history:

Received 25 November 2015

Received in revised form

17 December 2015

Accepted 4 January 2016

Available online 23 February 2016

##### Keywords:

acute abdomen

idiopathic omental hemorrhage

intraperitoneal hemorrhage

ovarian bleeding

#### ABSTRACT

With the exception of trauma, intraperitoneal hemorrhage in young women is caused by the high frequency of ectopic pregnancy and ovarian bleeding. Here, we describe a case of idiopathic omental hemorrhage, which is a rare cause of intraperitoneal hemorrhage. Intraperitoneal hemorrhage was suspected in a 38-year-old Japanese woman based on contrast-enhanced computed tomography. Her last menstrual period was 23 days prior, and ovarian bleeding was considered based on bloody ascites revealed by culdocentesis. She underwent emergency surgery for hypovolemic shock. Although both ovaries were of normal size and no abnormal findings were observed, we performed a partial omentectomy because multiple clots were attached only to the greater omentum. Post-operatively, no rebleeding occurred, and she was discharged 11 days after the surgery. Because she did not have a clear history of trauma and underlying disease, idiopathic omental hemorrhage was diagnosed.

Copyright © 2016, The Asia-Pacific Association for Gynecologic Endoscopy and Minimally Invasive Therapy. Published by Elsevier Taiwan LLC. This is an open access article under the CC BY-NC-ND license (<http://creativecommons.org/licenses/by-nc-nd/4.0/>).

## Introduction

With the exception of trauma, high frequency of ectopic pregnancy and ovarian bleeding are the most common causes of intraperitoneal hemorrhage in young women. In contrast, omental hemorrhage is rare. Omental hemorrhage is a generic term for bleeding in the abdominal cavity caused by a torn blood vessel of the omentum, or hematoma formation caused by blood accumulation in the greater omentum. Cases with unknown causes are classified as idiopathic omental hemorrhage. Here, we report the case of a 38-year-old Japanese woman who underwent laparoscopic surgery for intraperitoneal hemorrhage caused by idiopathic omental hemorrhage.

## Case report

The patient was a 38-year-old Japanese woman with a surgical history of acute appendicitis. She visited a nearby hospital complaining of vomiting, diarrhea, and pain in the lower left

abdominal area since early that morning. Ascites was detected in abdominal computed tomography (CT), and muscle guarding and an increase in white blood cells were observed. The patient transferred to our hospital for surgery with a diagnosis of acute abdomen.

The patient was 1.56 m in height and weighed 39.5 kg. At the time of being transported to our hospital, her blood pressure was 100/60 mmHg, pulse was 120 beats/minute, body temperature was 37.8°C, and she was lucid but presented an angor animi-like countenance. A physical examination revealed severe tenderness with muscle guarding over the left lower quadrant predominance. Her hemoglobin levels were 9.4 g/dL, white blood cell count was 8600 /mm<sup>3</sup>, and C-reactive protein level was 0.25 mg/dL; urinary human chorionic gonadotropin test results were negative. High-density ascites was detected in the abdominal cavity during enhanced CT performed in our hospital. Although it was thought to be intraperitoneal hemorrhage, the bleeding site was not identified, and she was referred to a gynecologist for a detailed examination. Transvaginal ultrasonography revealed that the uterus and both ovaries were of normal size, and a large volume of ascitic fluid was found in the Douglas cavum. Hemorrhage ascites was demonstrated by culdocentesis. The patient did not have a clear history of trauma, and the presence of other causative underlying diseases was ruled out by CT. Furthermore, based on the interview, intraperitoneal hemorrhage due to the

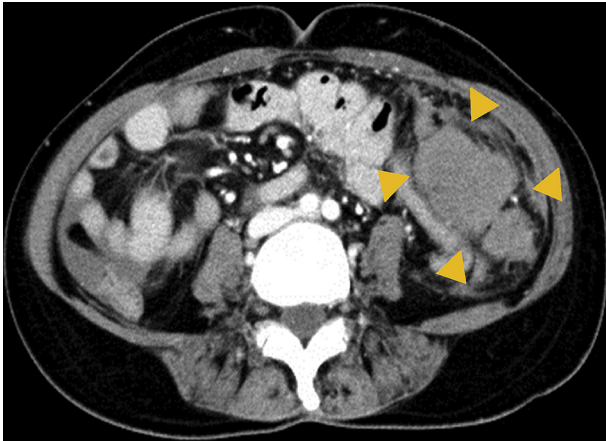
Conflicts of interest: The authors have no conflicts of interest relevant to this article.

\* Corresponding author. 93 Shikazawa, Yamasaki-cho, Shiso-city, Hyogo, 671-2576, Japan.

E-mail address: [hosso156@yahoo.co.jp](mailto:hosso156@yahoo.co.jp) (T. Hosotani).

<http://dx.doi.org/10.1016/j.gmit.2016.01.001>

2213-3070/Copyright © 2016, The Asia-Pacific Association for Gynecologic Endoscopy and Minimally Invasive Therapy. Published by Elsevier Taiwan LLC. This is an open access article under the CC BY-NC-ND license (<http://creativecommons.org/licenses/by-nc-nd/4.0/>).



**Figure 1.** Computed tomography showing a high-density area and an irregularly shaped region over the left lower quadrant (yellow arrowheads), which was diagnosed as an omental hematoma.

ovarian bleeding was diagnosed since her last menstrual period had been 23 days ago. However, a high density irregularly shaped region in the left lower quadrant was detected during a reexamination of the abdominal CT that we had performed postoperatively; therefore, we suspected hematoma of the greater omentum (Figure 1). After hospitalization, her pulse was 130 beats/minute and tachycardia continued; the hemoglobin level showed a tendency to decrease to 7.9 g/dL. Therefore, hypovolemic shock was diagnosed, and laparoscopic operation was performed.

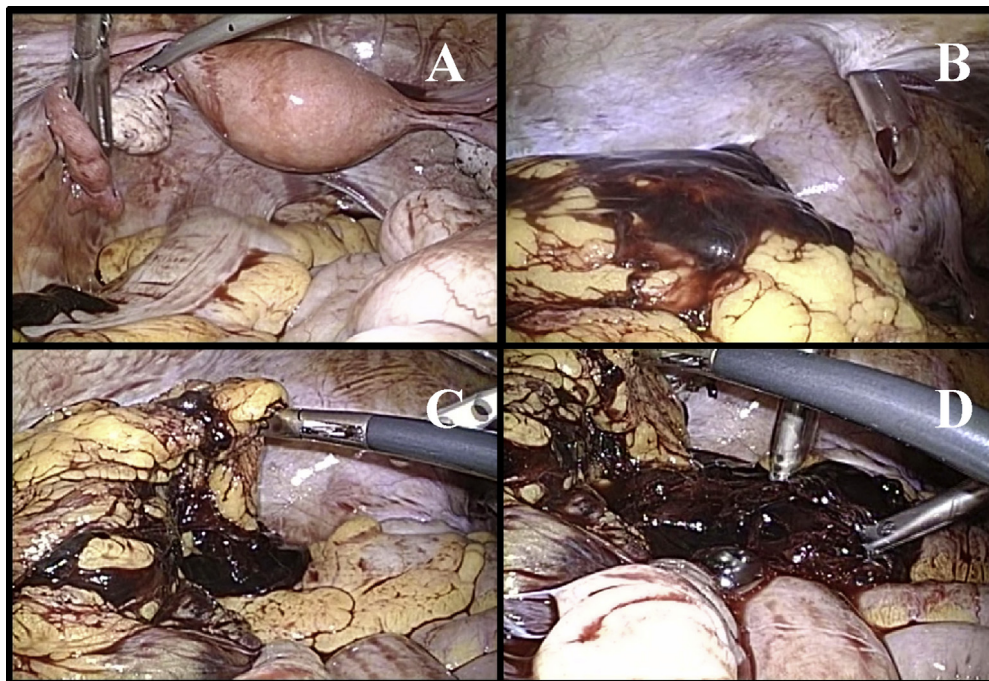
The hemorrhage ascites accumulated throughout the abdominal cavity, and the perioperative bleeding was 1.15 L. Both ovaries were of normal size, active bleeding was not detected, and no ovarian bleeding was observed (Figure 2A). On examining other

intraabdominal sites, the attachment of multiple clots was found only in the greater omentum parenchyma of the left lower quadrant (Figures 2B, 2C, and 2D). We removed the clots, but were unable to identify the bleeding site. Therefore, we made a small incision and explored the bleeding site after we had drawn the greater omentum out of the abdominal cavity. However, we estimated that we had already stopped the bleeding because we were not able to identify the bleeding site from the greater omentum. Intraoperative hemorrhage due to omental hemorrhage was diagnosed based on these intraabdominal findings, and we performed a partial omentectomy followed by fluid and transfusion therapy; however, tachycardia did not improve. A blood test was repeated during the operation, and it showed that the thyroid-stimulating hormone level was 0.01  $\mu$ U/mL and free thyroxine level was 4.43 ng/dL. Hence, we concluded that the tachycardia did not improve because of hyperthyroidism.

The postoperative course was good. Carvedilol at 5 mg/day initiated on Day 1 after surgery, and tachycardia was improved. The patient was discharged on Day 11 after surgery, and was referred to a special hospital for treatment of thyroid disease. Because she did not have a clear history of trauma or underlying disease including bleeding tendency, idiopathic omental hemorrhage was diagnosed.

## Discussion

Tamura et al<sup>1</sup> reported 56 case studies of ovarian bleeding. The average age of these patients was 23.9 years; coitus was the most common immediate cause, and the middle of the luteal phase was the most common onset time. Typical findings of transvaginal ultrasonography included a hemorrhagic corpus luteum cyst in either unilateral ovary, and evidence of bleeding around an ovary. Therefore, interviews and transvaginal ultrasonography were considered the most useful tools for diagnosis of ovarian bleeding.



**Figure 2.** Intraoperative photographs. (A) The uterus and both ovaries were normal, and no ovarian hemorrhage was observed. (B) Multiple clots attached to the omental surface. (C, D) Multiple clots accumulated in the omental parenchyma and formed a hematoma.

**Table 1**  
Reported cases of idiopathic omental hemorrhage in Japan.

Case	Age (y)	Sex	Chief complaint	Examination		Preoperative diagnosis	Therapy
				CT	Angio		
1	65	M	Epigastralgia	PI	—	Intraabdominal hemorrhage	Partial omentectomy
2	25	M	Upper abdominal pain, nausea, vomiting	UD	—	Omental hemorrhage	Partial omentectomy
3	30	M	Abdominal pain	PI	UD	Omental hemorrhage	Partial omentectomy
4	40	M	Upper abdominal pain	UD	—	Omental hemorrhage	Partial omentectomy
5	30	M	Upper abdominal pain	PI	—	Intraabdominal hemorrhage	Partial omentectomy
6	20	M	Abdominal pain, diarrhea, vomiting	PI	—	Intraabdominal hemorrhage	Partial omentectomy, gastrectomy
7	27	M	Intermittent abdominal pain, nausea, fainting	PI	—	Gastrointestinal perforation	Partial omentectomy
8	36	M	Abdominal pain, back pain, left shoulder pain	PI	—	Gastrointestinal perforation	Partial omentectomy
9	30	M	Right lower abdominal pain	PI	—	Appendicitis	Partial omentectomy
10	37	M	Abdominal pain	UD	—	Omental hemorrhage	Preservation → partial omentectomy
11	44	F	Right flank pain	PI	—	Intraabdominal hemorrhage	Preservation → laparoscopic partial omentectomy
12	51	M	Epigastralgia	PI	UD	Omental hemorrhage	Laparoscopic omental vasoligation
13	17	F	Right lower abdominal pain	PI	—	Appendicitis	Laparoscopic partial omentectomy
14	31	M	Epigastralgia	PI	—	Perforated gastric ulcer	Partial omentectomy
15	58	M	Left upper abdominal pain	PI	UD	Omental hemorrhage	Arterial embolization
16	16	M	Epigastralgia	PI	UD	Omental hemorrhage	Preservation
17	32	M	Left upper abdominal pain	UD	—	Omental hemorrhage	Partial omentectomy
18	61	M	Abdominal pain, abdominal fullness	UD	—	Omental hemorrhage	Partial omentectomy
19	55	F	Upper abdominal pain, vomiting	PI	—	Intraabdominal hemorrhage	Laparoscopic omental vasoligation
20	54	M	Upper abdominal pain	PI	UD	Omental hemorrhage	Arterial embolization → partial omentectomy
Our case	38	F	Left lower abdominal pain, nausea, diarrhea	PI	—	Ovarian bleeding	Laparoscopic partial omentectomy

Angio = angiography; CT = computed tomography; PI = preoperative imaging study; UD = useful to definitive diagnosis; — = no examination.

In contrast, omental hemorrhage is rare. In most reported cases of omental hemorrhage, omental direct injury, posttraumatic omental inflammation and thrombosis,<sup>2</sup> and torsion due to post-traumatic hematomas were common traumatic factors with an omental malignant tumor,<sup>3</sup> the explosion of omental varix,<sup>4</sup> and complications during anticoagulation as nontraumatic factors. Cases with unknown etiology are classified as idiopathic omental hemorrhage.<sup>5</sup> A total of 21 cases of idiopathic omental hemorrhage or idiopathic omental hematomas, including our case, have been reported since 2001 in Japan (Table 1). In these cases, the average age of patients was 38 years, and the disease predominantly developed in men (17 cases), although the reason for this is unknown. Abdominal pain was found in all cases as a presenting symptom, and the site had an epigastric prepotent tendency. Abdominal CT was performed in all cases, and ten cases were diagnosed with omental hemorrhage or omental hematoma before treatment. Five cases were diagnosed by abdominal CT only, and leakage of the mass image of high density that indicated omental hematoma and contrast media leakage from an omental blood vessel was detected.<sup>6</sup> Because overall status was stable, the remaining five patients underwent abdominal angiography, resulting in a diagnosis of omental hemorrhage. On postoperative reexamination, an irregularly shaped region indicating omental hematoma was found in the high-density region of the abdominal CT scan of our patient. Moreover, the case that was not diagnosed with omental hemorrhage was diagnosed as intraperitoneal hemorrhage, peritonitis due to acute appendicitis, and gastrointestinal perforation. Abdominal CT was useful for a diagnosis of omental hemorrhage, and diagnostic precision was thought to be increased by adding abdominal angiography in cases where the overall status appeared stable. However, as for the treatment, surgery was chosen in most cases. We prioritized treatment because in most cases overall status was unstable due to intraperitoneal hemorrhage. As

for the operative method, a partial omentectomy was performed in 17 cases and omental vasoligation was performed in two cases. Lately, laparoscopic surgery has become increasingly popular. Only one case was treated with transarterial embolization.<sup>7</sup> The prognosis after the treatment was good in all cases, and no case showed serious complications.

Because idiopathic omental hemorrhage is rare and predominantly occurs in male patients, it was thought to be extremely rare that a gynecologist would encounter this disease. Therefore, the preoperative diagnosis was ovarian bleeding in our case. Retrospective abdominal CT indicated omental hematoma that could be diagnosed preoperatively. However, since the overall status of many patients with intraperitoneal hemorrhage is unstable, differential diagnosis is challenging. In conclusion, the timing of intervention before diagnosis of idiopathic omental hemorrhage is crucial to prevent further exacerbation.

## References

1. Tamura R, Kurabayashi T, Hata Y, et al. Clinical analysis of 56 cases of ovarian bleeding in our hospital. *Sanka to Fujinka*. 2011;78:1527–1531 [In Japanese].
2. Schottenfeld LE, Rubinstein H. Hemorrhage and thrombosis of the omentum: Their etiology in the acute abdomen. *Am J Surg*. 1941;51:449–451.
3. Dixon AY, Reed JS, Dow N, Lee SH. Primary omental leiomyosarcoma masquerading as hemorrhagic ascites. *Hum Pathol*. 1984;15:233–237.
4. Ragupathi K, Bloom A, Pai N. Hemoperitoneum from rupture omental varices. *J Clin Gastroenterol*. 1985;7:537–538.
5. Umemura H, Yasutomi M. Greater omental hemorrhage. *Bessatsu Nihonrinsho ryoikibetsushokogunshiri-zu*. 1996;223–224 [In Japanese].
6. Makita K, Midorikawa T, Yagi H, et al. A case with a diagnosis of omental hemorrhage before surgery. *Nihon Shokaki Geka Gakkai Zasshi*. 2009;42:1446–1471 [In Japanese, English abstract].
7. Tsuchiya R, Takahashi S, Takaoka T, et al. A case of idiopathic omental bleeding treated successfully with transarterial embolization. *Nihon Shokakibyo Gakkai Zasshi*. 2009;106:554–559 [In Japanese, English abstract].