

First case of epicardial ablation to coexistent J waves in the inferior leads in a patient with clinical diagnosis of Brugada syndrome



Shingo Maeda, MD,^{*} Yasuhiro Yokoyama, MD,^{*} William W. Chik, MD,[†] Kyoko Soejima, MD,[‡] Kenzo Hirao, MD^{*}

From the ^{*}Heart Rhythm Center, Tokyo Medical and Dental University, Tokyo, Japan, [†]Cardiology Department, Westmead Hospital, University of Sydney, Sydney, Australia, and [‡]Department of Cardiology, Kyorin University School of Medicine, Tokyo, Japan.

Introduction

It is well established that type 1 Brugada syndrome (BrS) is associated with ventricular fibrillation (VF).¹ Recently, Morita et al² suggested in an experimental model that radiofrequency catheter ablation applied to the right ventricular (RV) epicardium might be more effective than radiofrequency ablation applied to the endocardium in order to eliminate ventricular tachycardia in patients with BrS. In addition, Nademanee et al³ reported that the likely underlying electrophysiological mechanism in patients with BrS was a delayed depolarization involving the anterior epicardial region of the right ventricular outflow tract (RVOT). They also reported that catheter ablation over this abnormal area resulted in normalization of the electrocardiographic (ECG) characteristics of BrS and prevented ventricular tachyarrhythmias. To our knowledge, we describe here the first case report demonstrating extensive epicardial bipolar voltage abnormality in a patient with BrS and coexistent J waves that was modified by ablation with good VF control.

Case report

We describe unique mapping and ablation results obtained from a 38-year-old man with a fixed type 1 Brugada ECG pattern (Figure 1A) with clinical diagnosis of BrS because of recurrent VF episodes and multiple appropriate shocks from his implantable cardioverter-defibrillator. Extensive investigations including echocardiography, cardiac magnetic resonance imaging, and an endocardial bipolar voltage map

were essentially normal. However, an endocardial unipolar voltage map detected an abnormal low-voltage area in the perivalvular RV (Figure 2), and furthermore, a detailed epicardial bipolar voltage map identified abnormal low-voltage areas with highly fractionated electrograms located in the anterior RVOT and inferior RV epicardially (Figure 3). Epicardial ablation procedures were performed with the goal of eliminating abnormal electrograms. The ablation power setting was 20–25 W, with a temperature limited at 41°C by using an open-irrigated ablation catheter for a duration of 20–30 seconds at each target site. The amplitude of the negative T waves recorded in leads V₁ and V₂ was attenuated after epicardial ablation procedures targeting the anterior RVOT scar (Figure 1B). Furthermore, J-wave amplitudes were notably smaller in leads II and aVF, while S waves became more prominent after additional epicardial ablation procedures targeting the inferior aspect of the RV (Figure 1C). The patient has been free from any VF recurrence at 20-month clinic follow-up.

Discussion

This clinical case demonstrated the effect of epicardial ablation on coexistent J-wave morphologies recorded by the inferior leads in a patient with clinical diagnosis of BrS. Nademanee et al³ reported several important findings regarding BrS. First, abnormal delayed depolarization was observed in the anterior epicardial aspect of the RVOT. Second, this aforementioned epicardial region was likely to be implicated as an arrhythmogenic focus underlying BrS. Third, catheter ablation targeting this abnormal epicardial region of the RVOT resulted in normalization of the Brugada ECG pattern. Finally, radiofrequency ablation delivery in this epicardial region may prevent ventricular tachyarrhythmia recurrence in patients with frequent recurrent VF episodes.

Several similar features were observed in our patient, namely, a typical type 1 Brugada ECG pattern, abnormal long-duration highly fractionated late potentials recorded exclusively within abnormal regions in the epicardium, and

KEYWORDS Brugada syndrome; J wave; Epicardium; Ablation; Ventricular fibrillation

ABBREVIATIONS BrS = Brugada syndrome; ECG = electrocardiographic; RV = right ventricle/ventricular; RVOT = right ventricular outflow tract; VF = ventricular fibrillation (Heart Rhythm Case Reports 2015;1:82–84)

Address reprint requests and correspondence: Dr Shingo Maeda, 1-5-45 Yushima, Bunkyo-ku, Tokyo 113-8519, Japan. E-mail address: s-maeda@ja2.so-net.ne.jp.

KEY TEACHING POINTS

- This is the first case report illustrating extensive epicardial bipolar voltage abnormality in a patient with clinical diagnosis of Brugada syndrome and coexistent J waves that was modified by ablation and good medium-term ablation outcome.
- An endocardial unipolar voltage map detected an abnormal low-voltage area in the perivalvular right ventricle, and furthermore, a detailed epicardial bipolar voltage map identified abnormal low-voltage areas with highly fractionated electrograms located in the anterior right ventricular outflow tract and inferior right ventricle epicardially.
- Our findings of abnormal endocardial and epicardial voltages on detailed electroanatomical mapping may be further evidence that most patients with Brugada syndrome may not have a “pure” ion channel disease but that the clinical phenotype corresponding to the Brugada electrocardiographic pattern involves different degrees of pathological myocardial involvement by a (yet undefined) cardiomyopathic process.

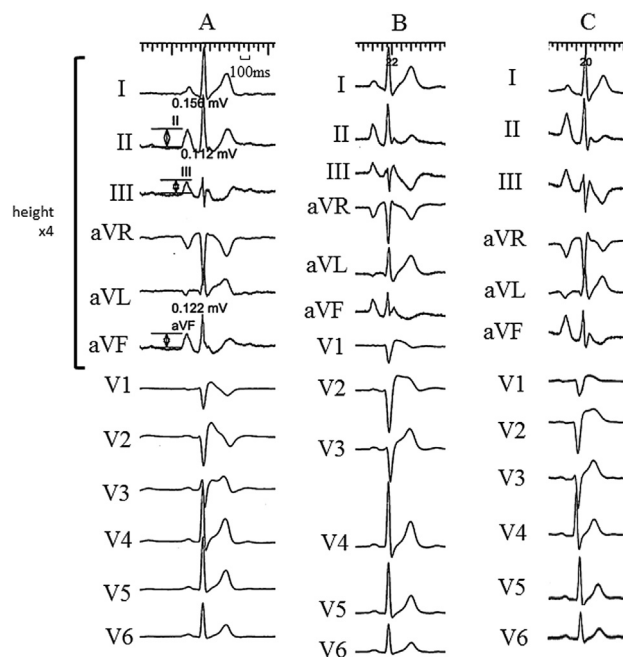


Figure 1 Electrocardiograms before and after stepwise epicardial ablation procedures: (A) before ablation, (B) after right ventricular outflow tract epicardial ablation, and (C) after inferior right ventricular epicardial ablation.

modification of the type 1 Brugada ECG pattern after ablation of the epicardial site in the anterior RVOT. Importantly, our case also differed as highlighted by the presence of abnormal epicardial potential localizations based on the pattern of low bipolar epicardial voltages that were not limited to the RVOT. Intriguingly, these abnormal voltages also extended to involve the inferior RV epicardially, while the endocardial bipolar voltages were normal. Furthermore, the amplitude of the negative T waves detected in leads V₁ and V₂ was attenuated, the J waves were evidently smaller in leads II and aVF, and S waves became more prominent after epicardial ablation procedures targeting these regions.

It has been reported that the presence of J waves in multiple leads may indicate a highly arrhythmogenic substrate in patients with BrS.⁴ On the basis of the epicardial findings in this case, coexistent J waves in BrS may indicate more extensive and heterogeneous epicardial abnormalities associated with an increased susceptibility to ventricular arrhythmias.

In addition, Catalano et al⁵ reported the presence of mild structural changes in the RV that were detectable with magnetic resonance imaging. Similarly, Frustaci et al⁶ reported evidence of concealed cardiomyopathic substrates at endomyocardial biopsy in patients with clinical phenotype of BrS. Our findings of abnormal endocardial and epicardial voltages on detailed electroanatomical mapping may be

further evidence that most patients with BrS may not have a “pure” ion channel disease but that the clinical phenotype corresponding to the Brugada ECG pattern involves different degrees of pathological myocardial involvement by a (yet undefined) cardiomyopathic process.

To our knowledge, this is the first case report illustrating extensive epicardial bipolar voltage abnormality in a patient with clinical diagnosis of BrS and coexistent J waves that was modified by ablation and good medium-term ablation outcome.

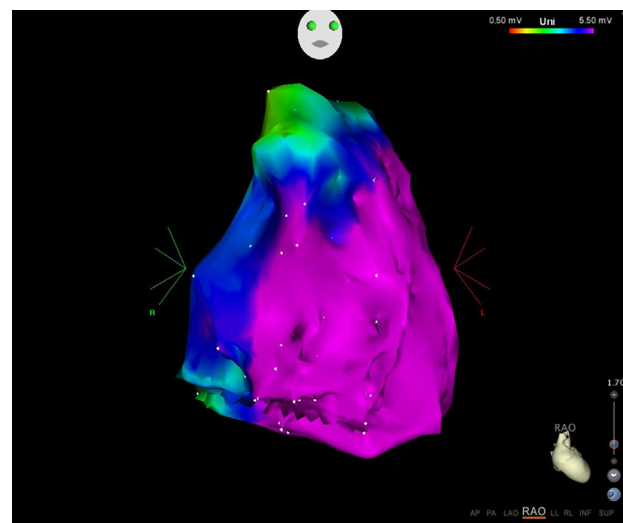


Figure 2 Endocardial unipolar voltage map of the right ventricle using a voltage range from 0 to 5.5 mV is illustrated in the right anterior oblique (RAO) orientation.

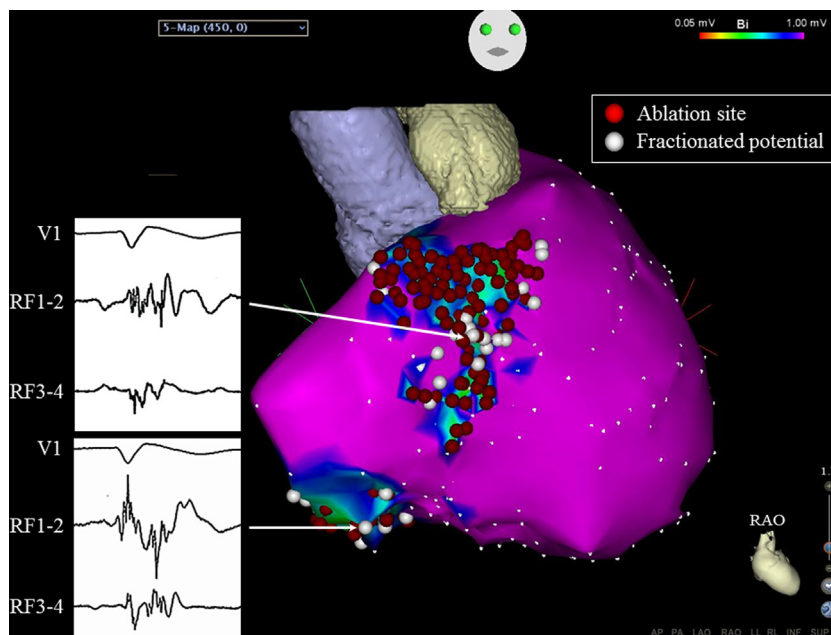


Figure 3 Epicardial bipolar voltage map of the right ventricle (RV) is shown using a voltage range from 0.5 to 1.0 mV. The epicardial RV voltage map identified a low-voltage area in the inferior RV. Fractionated and late potentials were tagged with white, clustering in the RVOT and inferior RV. RFA procedures were applied to eliminate abnormal electrogram areas with good clinical efficacy. RAO = right anterior oblique; RF = radiofrequency; RFA = radiofrequency ablation.

References

1. Brugada J, Brugada R, Brugada P. Right bundle-branch block and ST-segment elevation in leads V1 through V3: a marker for sudden death in patients without demonstrable structural heart disease. *Circulation* 1998;97:457–460.
2. Morita H, Zipes DP, Morita ST, Lopshire JC, Wu J. Epicardial ablation eliminates ventricular arrhythmias in an experimental model of Brugada syndrome. *Heart Rhythm* 2009;6:665–671.
3. Nademanee K, Veerakul G, Chandanamattha P, Chaothawee L, Ariyachaipanich A, Jirasirirojanakorn K, Likittanasombat K, Bhuripanyo K, Ngarmukos T. Prevention of ventricular fibrillation episodes in Brugada syndrome by catheter ablation over the anterior right ventricular outflow tract epicardium. *Circulation* 2011;123:1270–1279.
4. Takagi M, Aonuma K, Sekiguchi Y, Yokoyama Y, Aihara N, Hiraoka M, Japan Idiopathic Ventricular Fibrillation Study (J-IVFS) Investigators. The prognostic value of early repolarization (J wave) and ST-segment morphology after J wave in Brugada syndrome: multicenter study in Japan. *Heart Rhythm* 2013;10:533–539.
5. Catalano O, Antonaci S, Moro G, et al. Magnetic resonance investigations in Brugada syndrome reveal unexpectedly high rate of structural abnormalities. *Eur Heart J* 2009;30:2241–2248.
6. Frustaci A, Priori SG, Pileri M, Chimenti C, Napolitano C, Rivolta I, Sanna T, Bellocci F, Russo MA. Cardiac histological substrate in patients with clinical phenotype of Brugada syndrome. *Circulation* 2005;112:3680–3687.