

Contents lists available at [ScienceDirect](http://www.sciencedirect.com)

Trauma Case Reports

journal homepage: <http://www.journals.elsevier.com/trauma-case-reports/>

Case Report

Trauma sternotomy for presumed haemopericardium with incidental coccidioidal pericarditis

Seth I. Felder*

Department of Surgery, Division of Trauma and Critical Care, Cedars-Sinai Medical Center, Los Angeles, CA, United States

ARTICLE INFO

Article history:

Accepted 16 February 2015

Available online 14 April 2015

Keywords:

Trauma

Infection

Focussed assessment with sonography for trauma (FAST)

ABSTRACT

Background: Disseminated coccidiomycosis with extrapulmonary disease occurs in less than 1% of infected patients, with few cases involving the pericardium reported in the literature. A subxiphoid window in a focussed assessment with sonography for trauma is a fast and reliable study for detecting haemopericardium in the haemodynamically unstable injured patient.

Methods: Case report and literature review.

Case report: A 50-year old man presented in extremis following a stab wound to the right thoracoabdominal region with a positive pericardial ultrasound. At the time of emergent sternotomy, the pericardial effusion appeared non-traumatic and not the cause of haemodynamic instability. Lung, diaphragm, liver and transverse colon lacerations were controlled by laparotomy. He was discovered to have extensive adenopathy within the mediastinum, porta hepatis, and lesser sac, which after histopathologic examination, demonstrated granulomatous lymphadenitis consistent with disseminated coccidiomycosis.

Conclusions: This case report describes the first reported "incidental" pericardial effusion in a haemodynamically unstable patient sustaining a thoracoabdominal stab wound discovered on a positive ultrasound study. Emergent operative exploration and subsequent workup determined the pericardial fluid to be of infectious origin, rather than traumatic. With the incidence of coccidiomycosis within endemic geographic regions significantly rising, coccidioidal pericarditis may become an increasingly relevant cause of fluid detected on noninvasive pericardial examination.

© 2015 Published by Elsevier Ltd. This is an open access article under the CC BY-NC-ND license

(<http://creativecommons.org/licenses/by-nc-nd/4.0/>).

* Cedars Sinai Medical Center, Department of Surgery, 8635 West Third Street, Suite 650, Los Angeles, CA 90048, United States. Tel.: + 1 310 423 8513; fax: + 1 310 423 5454.

E-mail address: sifelder@gmail.com.

We report a case of coccidioidal pericarditis discovered on emergent sternotomy performed for presumed traumatic haemopericardium resulting from a penetrating thoracoabdominal injury. Coccidioidomycosis is primarily a fungal disease of the lungs, however, it can disseminate to virtually any organ in the body [1]. Disseminated coccidioidomycosis occurs in fewer than 1% of immunocompetent patients, with 35 cases (20 with clinical information) involving the pericardium reported in the English literature [2,3]. Coccidioidal pericarditis may manifest as a rapidly progressing effusive-tamponade process or as an indolent chronic, constrictive pericarditis, associated with an effusion [2]. To our knowledge, this is the first report describing incidental coccidioidal pericarditis diagnosed following emergency surgery based on a positive focussed assessment with sonography for trauma (FAST). Although the subxiphoid pericardial FAST window has been shown to be a reliable and quick noninvasive modality for evaluating patients with possible penetrating cardiac injuries [4–6], it is unable to identify structural cardiac injuries or distinguish the character of pericardial fluid (blood vs. effusion) [7].

Case report

Clinical course

A 50-year old homeless, African American male was brought to the emergency department (ED) in extremis after sustaining a 3 centimeter (cm) stab wound between the right 4th and 5th intercostal spaces, just medial to the nipple. He was tachycardic, hypotensive with an initial systolic blood pressure of 70 mm Hg, tachypneic, and saturating 90% on supplemental oxygen. A right-sided thoracostomy tube was placed for a haemopneumothorax and drained 400 milliliters (mL) of blood immediately. A FAST subxiphoid view of the pericardium demonstrated fluid within the pericardium. Because of a presumed haemopericardium causing haemodynamic instability, the patient was emergently taken to the operating room for a median sternotomy.

The pericardium was sharply opened longitudinally, and the patient was found to have approximately 70 mL of sero-purulent pericardial fluid without evidence of myocardial injury. Right lower pulmonary lobe, diaphragm, liver segment 4, and transverse colon lacerations were rapidly identified and controlled through the sternotomy incision and a subsequent midline laparotomy. The injury to his lung was addressed with a wedge resection, and injuries to the diaphragm and colon repaired primarily. After removing abdominal packings, the liver laceration was not repaired, as active bleeding or bile was not appreciated. On further inspection of the chest and abdominal cavity, the patient was found to have lymphadenopathy in the porta hepatis as well as mediastinum. An enlarged, freely accessible lymph node from the porta hepatis was obtained for pathologic examination. The patient was brought to the surgical intensive care unit in critical, but stable condition.

The patient was extubated on post-operative day 1 and underwent an infectious disease workup. He reported no recent travel history to endemic regions nor did he endorse any pre-injury cardiopulmonary or systemic symptoms. Histopathologic examination of the biopsied lymph node demonstrated granulomatous lymphadenitis and multiple epithelioid granulomas with fungal forms consistent with *Coccidioides* species on Grocott's methenamine silver (GMS) stain and Periodic acid–Schiff (PAS) histochemistry staining (Fig. 1). Cocci serologies for Immunoglobulin (Ig) G and IgM were both positive, and complement fixation titer was $\geq 1:512$. Human immunodeficiency virus (HIV) and Hepatitis surface Antigen were negative. Pericardial fluid culture was negative for fungus and acid-fast bacilli, and cytopathology exhibited a lymphocytic predominance.

Computerised tomography (CT) identified epicardial, paratracheal, aortopulmonary, and portacaval adenopathy, as well as a 2 cm nodular mass in the right lung apex with pleural parenchymal scarring and multiple subcentimetre hypodensities within the spleen (Fig. 2a, b, c). A bone scan was negative.

Electrocardiogram (EKG) performed 6 h postoperatively demonstrated acute pericarditis with sinus tachycardia. Except for mildly increased peak pulmonary artery systolic pressure (44 mm Hg), his transthoracic echocardiogram was normal. The pericarditis was not treated and resolved on a follow-up EKG. His post-operative course was otherwise uneventful and he was discharged on hospital day 10. He was treated with oral fluconazole and recommended to continue antibiotic therapy for 6 months. At one year follow-up, the patient is doing well, not having required any further intervention or hospitalisation.

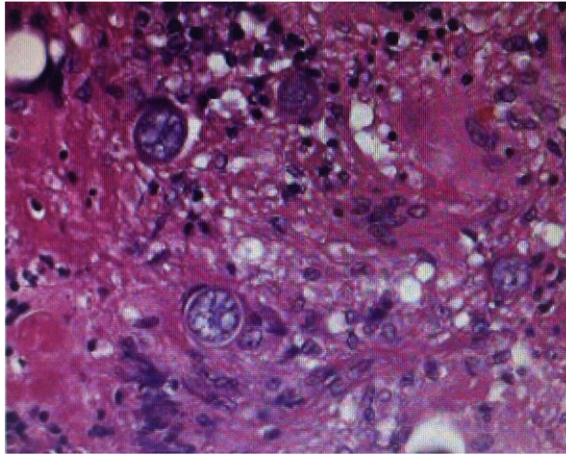


Fig. 1. Epithelioid granulomas with fungal forms consistent with *Coccidioides* species.

Discussion

The diagnosis of cardiac tamponade must be made quickly and accurately in patients with possible penetrating cardiac wounds so that surgery is not delayed. Although pulsus paradoxus or Beck's triad may be associated with cardiac tamponade, neither is consistently present. However, pericardial FAST is a rapid, non-invasive, and extremely accurate test not only valuable for the detection of haemopericardium, but as importantly, for the documentation of its absence [5,6]. The literature has reported sensitivity, specificity, and accuracy approaching 100% using pericardial ultrasound examination in patients considered to be at high risk for cardiac injury from penetrating precordial or transthoracic wounds [7]. In one of the largest series including 261 trauma patients with a precordial or transthoracic wound with a suspicion for a cardiac injury, 7 (2.7%) patients had a false-positive FAST with a benign pericardial effusion discovered at laparotomy. The authors, however, stated that each of these cases subsequently undergoing emergent operations was indicated [5]. Despite the known high accuracy for pericardial FAST examinations, the study is limited by its inability to identify cardiac injuries or characterize the nature of the pericardial fluid (ie., blood or effusion) [4,7].

Coccidioidomycosis is a systemic mycosis caused by the fungus *Coccidioides immitis*. *Coccidioides* species are endemic to the United States Southwest and adjacent areas in northern Mexico [8]. The Centers for Disease Control and Prevention (CDC) recent analysis of data from the National Notifiable Diseases Surveillance System for the years 1998 through 2011 indicated that the incidence of reported coccidioidomycosis increased substantially from 5.3 per 100,000 population in endemic areas (Arizona, California, Nevada, New Mexico, and Utah) in 1998 to 42.6 per 100,000 in 2011 [9].

Approximately 60% of patients with primary pulmonary infection are asymptomatic [2], with the remaining 40% of symptomatic patients experiencing a flu-like illness [10]. Patients with chronic pulmonary coccidioidomycosis are typically immunocompromised, 5% developing lung nodules that may progress to a progressive pneumonia and bronchiectasis [2,11].

Extrapulmonary coccidioidomycosis dissemination occurs in less than 1% of immunocompetent patients, most commonly to the skin, bones, soft tissue, meninges, and regional lymph nodes [8,12]. African and Filipino ancestry and immunocompromised individuals have been recognised as populations at increased risks of disseminated extrapulmonary disease [8].

The diagnosis of coccidioidal infection is established by culture or pathologic examination of the involved tissue, supplemented by the use of serologic tests [2,8]. A complement fixation titer > 1:16 is highly suggestive of disseminated disease, our patient reported had a titer \geq 1:512. Pericardial fluid may reveal an elevated white blood cell count with most cases showing lymphocytic predominance. Fluid culture may grow the organism, however, in some cases the fluid is sterile. Histologically, coccidioidal spherules confirm the diagnosis.

An extensive literature review of pericardial presentations of coccidioidomycosis by Crum-Cianflone et al. located 20 cases, with 13 (65%) diagnosed antemortem. Some patients had a history of prior pulmonary

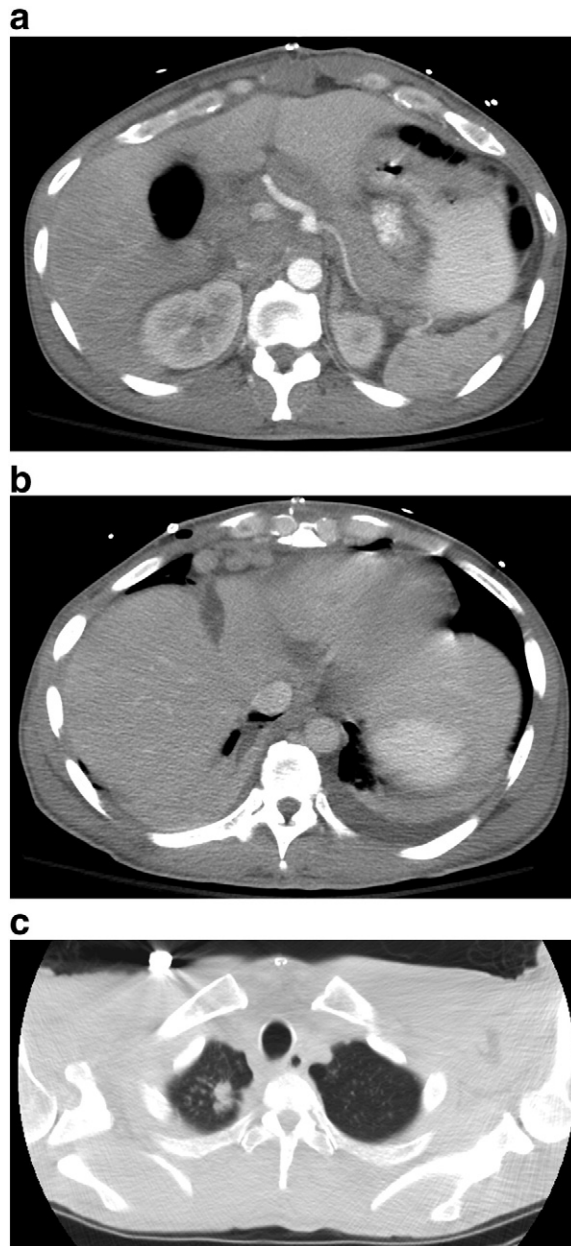


Fig. 2. a: Postoperative computerised tomography scan demonstrating portacaval adenopathy. b: Postoperative computerised tomography scan demonstrating epicardial and paratracheal adenopathy. c: Postoperative computerised tomography scan demonstrating pleural parenchymal scarring.

coccidioidomycosis, which antedated the presentation of pericarditis by up to 6 years, whilst other cases presented with concurrent pulmonary involvement or with no prior history of lung disease [13]. Our patient did not have pre-traumatic symptoms of constrictive pericarditis. Interventions for coccidioidal pericarditis have included pericardiocentesis, pericardial window, or complete pericardiectomy to free the heart from the constrictive process [1,13,14].

Incidental discovery of disseminated coccidioidomycosis has been sporadically reported, however, it has been located in the peritoneum. Coccidioidomycosis has been found following exploratory laparotomy for abdominal pain [15], presumed malignancy [16,17], appendectomies, herniorrhaphies, and hysterectomies [18–20].

Coccidioidal infection may be treated with an antifungal agent, with itraconazole and fluconazole most frequently used. The recommended duration for anti-fungal treatment varies depending on the extent of disease and patient's immune status, but typically is suggested for 3 to 6 months [21].

Conclusions

The patient described in this case report presented emergently following a penetrating thoracoabdominal injury and ultimately was discovered to have an infectious, rather than traumatic, cause for his pericardial effusion. Operative exploration revealed no cardiac injury, although mediastinal and abdominal adenopathy with histopathologic and serologic results consistent with disseminated coccidioidomycosis species were discovered. Our case describes the first reported “incidental” pericardial effusion in a haemodynamically unstable patient sustaining a thoracoabdominal stab wound determined by a positive FAST.

Conflict of interest

The author has no conflict of interest to report and have received no financial or material support related to this manuscript.

References

- [1] E.L. Schwartz, E.B. Waldmann, R.M. Payne, D. Goldfarb, S.A. Kinard, Coccidioidal pericarditis, *Chest* 70 (1976) 670–672.
- [2] N.F. Crum-Cianflone, et al., Unusual presentations of coccidioidomycosis: a case series and review of the literature, *Medicine (Baltimore)* 85 (2006) 263–277.
- [3] E.L. Arsura, R.K. Bobba, C.M. Reddy, Coccidioidal pericarditis: a case presentation and review of the literature, *Int. J. Infect. Dis. IJID Off. Publ. Int. Soc. Infect. Dis.* 9 (2005) 104–109.
- [4] C.G. Ball, et al., A caveat to the performance of pericardial ultrasound in patients with penetrating cardiac wounds, *J. Trauma* 67 (2009) 1123–1124.
- [5] G.S. Rozycki, et al., The role of ultrasound in patients with possible penetrating cardiac wounds: a prospective multicenter study, *J. Trauma* 46 (1999) 543–551 (discussion 551–552).
- [6] G.S. Rozycki, et al., The role of surgeon-performed ultrasound in patients with possible cardiac wounds, *Ann. Surg.* 223 (1996) 737–744 (discussion 744–746).
- [7] J.K. Lukan, G.A. Franklin, D.A. Spain, E.H. Carrillo, 'Incidental' pericardial effusion during surgeon-performed ultrasonography in patients with blunt torso trauma, *J. Trauma* 50 (2001) 743–745.
- [8] J.M. Parish, J.E. Blair, Coccidioidomycosis, *Mayo Clin. Proc. Mayo Clin.* 83 (2008) 343–348 (quiz 348–349).
- [9] Centers for Disease Control and Prevention (CDC), Increase in reported coccidioidomycosis—United States, 1998–2011, *MMWR Morb. Mortal. Wkly Rep.* 62 (2013) 217–221.
- [10] W.A. Kormos, C.C. Wu, J.A. Branda, A. Piris, Case records of the Massachusetts General Hospital. Case 35–2010. A 56-year-old man with cough, hypoxemia, and rash, *N. Engl. J. Med.* 363 (2010) 2046–2054.
- [11] A. de Deus Filho, Chapter 2: coccidioidomycosis, *J. Bras. Pneumol. Publicação Of. Soc. Bras. Pneumol. E Tisiologia* 35 (2009) 920–930.
- [12] H.R. Vikram, G. Dhaliwal, S. Saint, C.B. Simpson, Clinical problem-solving. A recurrent problem, *N. Engl. J. Med.* 364 (2011) 2148–2154.
- [13] A.L. Visbal, P.A. DeValeria, J.E. Blair, M.A. Zarka, L.A. Lanza, Coccidioidal pericarditis: implications of surgical treatment in the elderly, *Ann. Thorac. Surg.* 75 (2003) 1328–1330.
- [14] J.L. Faul, K. Hoang, J. Schmoker, R.H. Vagelos, G.J. Berry, Constrictive pericarditis due to coccidiomycosis, *Ann. Thorac. Surg.* 68 (1999) 1407–1409.
- [15] J.P. Micha, B.H. Goldstein, P.A. Robinson, M.A. Rettenmaier, J.V. Brown, Abdominal/pelvic coccidioidomycosis, *Gynecol. Oncol.* 96 (2005) 256–258.
- [16] B.A. Eyer, et al., Peritoneal coccidioidomycosis: a potential CT mimic of peritoneal malignancy, *Abdom. Imaging* 29 (2004) 505–506.
- [17] M.W. Ellis, D.P. Dooley, M.J. Sundborg, L.L. Joiner, E.R. Kost, Coccidioidomycosis mimicking ovarian cancer, *Obstet. Gynecol.* 104 (2004) 1177–1179.
- [18] E.C. Saw, S.J. Shields, T.P. Comer, R.W. Huntington Jr., Granulomatous peritonitis due to *Coccidioides immitis*, *Arch. Surg. Chic. Ill* 1960 108 (1974) 369–371.
- [19] T.L. Buchmiller-Craig, Initial presentation of coccidioidomycosis during inguinal herniorrhaphy, *Hernia J. Hernias Abdom. Wall Surg.* 7 (2003) 92–94.
- [20] K.T. Chen, Coccidioidal peritonitis, *Am. J. Clin. Pathol.* 80 (1983) 514–516.
- [21] D.J. DiCaudo, Coccidioidomycosis: a review and update, *J. Am. Acad. Dermatol.* 55 (2006) 929–942 (quiz 943–945).