Injury Extra (2005) 36, 255—258

ELSEVIER

www.elsevier.com/locate/inext

CASE REPORT

Avulsion fracture of the greater trochanter of the femur: recommendations for closed reduction of the apophyseal injury

J.J. Wood[a,*], R. Rajput[b], A.J. Ward[b]

[a]*Department of Surgery, Southmead Hospital, North Bristol NHS Trust, Westbury-on-Trym, Bristol BS10 5NB, UK*
[b]*Department of Orthopaedics, Frenchay Hospital, North Bristol NHS Trust, Beckspool Road, Frenchay, Bristol BS16 1JE, UK*

Accepted 17 October 2004

Introduction

This report describes a case of traumatic avulsion of the greater trochanter of the left femur in a 15-year-old male. This is a rare injury in which open reduction and internal fixation is recommended. Based on our operative findings we recommend attempting closed reduction and percutaneous internal fixation.

Case report

A 15-year-old boy presented with pain in the left hip after falling from a banana boat ride on a local lake. The mechanism of injury was uncertain but the hips were flexed and abducted whilst sat astride the banana boat.

On examination he was lying with the left leg in external rotation and the hip in slight flexion. All movements of the hip were painful. There were no other associated injuries.

Plain radiographs (Fig. 1) showed avulsion of the whole of the greater trochanter with separation from the externally rotated femur. Further fine cut CT imaging of the acetabulum and proximal femur was obtained (Fig. 2) to define the trochanteric fracture and degree of displacement prior to exploration and internal fixation. The trochanteric apophyseal fragment was lying in a neutral position anterior to the externally rotated femur.

At surgery a lateral incision was made over the greater trochanter, splitting gluteus maximus. The greater trochanter fragment appeared to be lying in a neutral lateral position held by the intact attachments of vastus lateralis inferiorly and gluteus medius and minimus superiorly. With full internal rotation of the femur the trochanteric fragment reduced spontaneously on the underlying femur. No direct manipulation of the trochanteric fragment was needed. Two AO 6.5 mm partially threaded (32 mm thread) cancellous screws and washers were inserted for internal fixation of the trochanter. The reduction was screened with the image intensifier, which appeared to be good, with no more than 2 mm residual superior displacement of the greater trochanter on the femur.

* Corresponding author. Tel.: +44 117 9505050/ +44 7740680676 (M)
E-mail address: jimwood@doctors.net.uk (J.J. Wood).

1572-3461
doi:10.1016/j.injury.2004.10.038

Figure 1 AP radiograph of the pelvis showing the avulsed left greater trochanter.

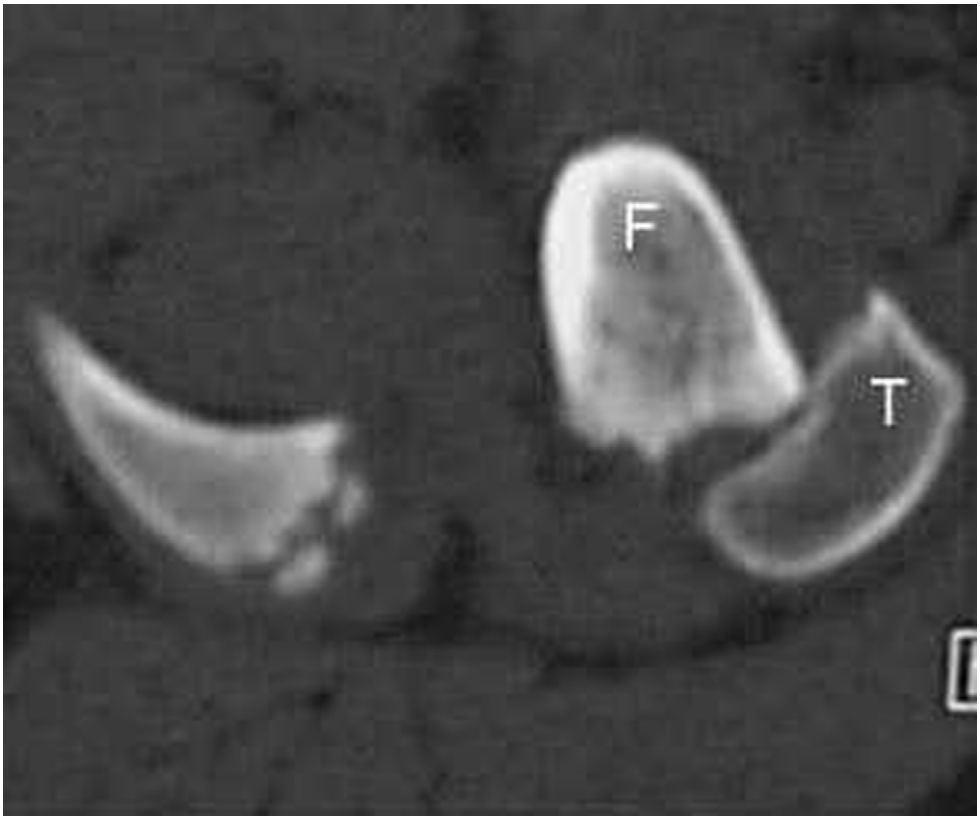

Figure 2 CT image showing avulsion of the left greater trochanter. The trochanteric apophyseal fragment (T) is lying in a neutral position anterior to the externally rotated femur (F).

Figure 3 Post-operative radiograph of the pelvis.

Following surgery further radiographs were taken to check symmetry of reduction (Fig. 3). The patient made an uneventful recovery. He was mobilised partial weight bearing with crutches for 6 weeks before fully weight bearing.

Discussion

Fractures of the greater trochanter are rare. They may be divided into those involving epiphyseal separation of adolescence and true fractures of adulthood.[7]

In adults isolated fractures of the greater trochanter have been treated both conservatively and surgically.[6,7] Avulsion fractures of the apophyses of the pelvis and proximal femur, rarely affecting the greater trochanter, have been described.[2] These tend to occur in males during the second decade. One case report has described a healing non-avulsed greater trochanteric apophyseal fracture without a history of trauma in a 15-year-old male.[1]

We are aware of only two case reports of avulsion fracture of the greater trochanter following trauma in adolescents.[4,5] The patients were aged twelve and fourteen years. In both cases internal fixation was performed with screws.

In our case the mechanism of injury was likely to have been due to forced external rotation of the leg with simultaneous contraction in the gluteus medius and minimus muscles. The apparent neutral position of the avulsed segment would have been maintained by the intact gluteal and vastus lateralis muscle attachments.

Since we observed that reduction of the trochanteric apophysis was achieved spontaneously by full internal rotation of the femur we postulate that a closed reduction could have been achieved. This would have enabled percutaneous screw fixation of the trochanteric apophysis to be performed.

Apophyseal fractures of the pelvis tend to have an excellent prognosis.[2] However, fractures of the greater trochanter can have serious consequences including avascular necrosis of the femoral head leading to severe hip deformity.[3,4] We recommend a trial of closed reduction and percutaneous fixation be considered in this apophyseal injury.

References

1. Bloome DM, Thompson JD. Apophyseal fracture of the greater trochanter. South Med J 2000;93(8):832—3.

2. Fernbach SK, Wilkinson RH. Avulsion injuries of the pelvis and proximal femur. AJR 1981;137:581—4.
3. Hosli P, Laer L. Traumatic loosening of apophyses in the pelvic area and the proximal femur. Orthopade 1995;24(5):429—35.
4. Kaweblum M, Wallace BL, Grant AD, Strongwater A. Avascular necrosis of the femoral head as sequela of fracture of the greater trochanter. Clin orthop 1993;294:193—5.
5. Mbubaegbu CE, O'Doherty D, Shenolikar A. Traumatic apophyseal avulsion of the greater trochanter: case report and review of the literature. Injury 1998;29(8):647—9.
6. Merlino AF, Nixon JE. Isolated fractures of the greater trochanter. Int Surg 1969;52(2):117—24.
7. Milch H. Avulsion fracture of the great trochanter. Arch Surg 1939;38:334—50.