

Pure Red Cell Aplasia and Hypogammaglobulinemia in a Patient with Thymoma

Chen-Sung Lin^{1,2,5}, Yuan-Bin Yu^{3,6}, Han-Shui Hsu^{2,5}, Teh-Ying Chou^{4,5}, Wen-Hu Hsu^{2,6},
Biing-Shiun Huang^{2,6,7*}

¹Division of Thoracic Surgery, Department of Surgery, Keelung Hospital, Department of Health Executive Yuan, Keelung;

²Division of Thoracic Surgery, Department of Surgery, ³Division of Hematology and Oncology, Department of Internal Medicine, and ⁴Division of Surgical Pathology, Department of Pathology and Laboratory Medicine,

Taipei Veterans General Hospital; ⁵Clinical Medicine Institute and ⁶School of Medicine, National Yang-Ming University; ⁷School of Medicine, Taipei Medical University, Taipei, Taiwan, R.O.C.

Both pure red cell aplasia (PRCA) and hypogammaglobulinemia are rarer conditions than myasthenia gravis (MG) in thymoma patients. Several articles have discussed the relation between PRCA and thymoma or hypogammaglobulinemia and thymoma, and their proper treatments. Instances of both PRCA and hypogammaglobulinemia in a thymoma patient are few and reported sporadically in the literature. We discuss a 46-year-old woman with thymoma and simultaneous PRCA and hypogammaglobulinemia who achieved complete remission from PRCA after perioperative steroid administration and extended thymectomy, and review the literature. [*J Chin Med Assoc* 2009;72(1):34–38]

Key Words: hypogammaglobulinemia, pure red cell aplasia, thymoma

Introduction

A thymoma is a neoplasm originating from the thymic epithelium and is the most common tumor of the anterior mediastinum. Approximately 40% of thymoma patients have clinically associated parathymic syndromes, with myasthenia gravis (MG) being the most common.¹ The others, including pure red cell aplasia (PRCA), hypogammaglobulinemia (Good's syndrome), autoimmune disorders and vasculitis, occur in about 5–10% of thymoma patients.² PRCA is characterized by normocytic anemia, reticulocytopenia and severe erythroid hypoplasia in the bone marrow but normal myeloid and megakaryocytic cell lineages.³ Although PRCA occurs in only 5% of thymoma patients, thymoma can be found in 50% of PRCA patients.¹ This indicates that PRCA is rarer than MG in thymoma patients, but the relationship between PRCA and thymoma is closer. Thymoma, combined with hypogammaglobulinemia, was first recognized by Dr Robert Good in 1954. This occurs in approximately 6–11% of thymoma patients and is characterized by low serum

immunoglobulin levels, few B cells, abnormal CD4+/CD8+ T-cell ratios, and CD4 T-cell lymphopenia.^{1,4} Thymoma patients with PRCA or hypogammaglobulinemia are rare, while those with both PRCA and hypogammaglobulinemia are even rarer. We discuss a 46-year-old woman with thymoma, who had simultaneous PRCA and hypogammaglobulinemia, who achieved complete PRCA remission after perioperative steroid administration and extended thymectomy.

Case Report

A pale 46-year-old woman was referred to hematology for progressive palpitations, dizziness and shortness of breath for 5 months. The symptoms were exaggerated, especially during menstruation. She had also suffered from recurrent canker sores and common colds in the past years.

Routine chest radiography disclosed a mass over the left anterior mediastinal area (Figure 1A). Chest computed tomography (CT) showed the mass to be



*Correspondence to: Dr Biing-Shiun Huang, Department of Surgery, Taipei Veterans General Hospital, 201, Section 2, Shih-Pai Road, Taipei 112, Taiwan, R.O.C.

E-mail: bshuang@vghtpe.gov.tw • Received: March 12, 2008 • Accepted: August 27, 2008

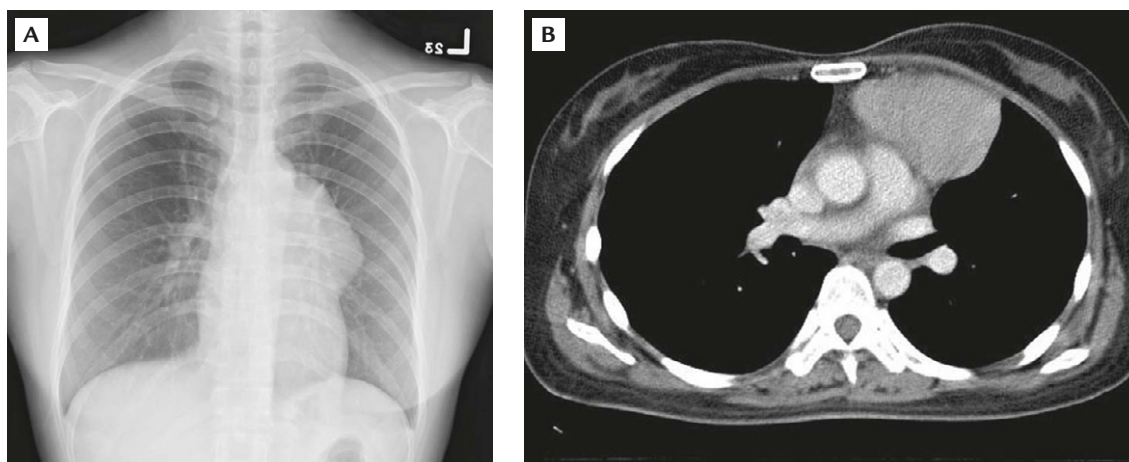


Figure 1. (A) Chest radiography shows a huge mass lesion over the left anterior mediastinal area. (B) Chest computed tomography demonstrates a soft tissue mass measuring $7.0 \times 4.5 \times 8.4$ cm with homogeneous enhancement in the left anterior mediastinum.

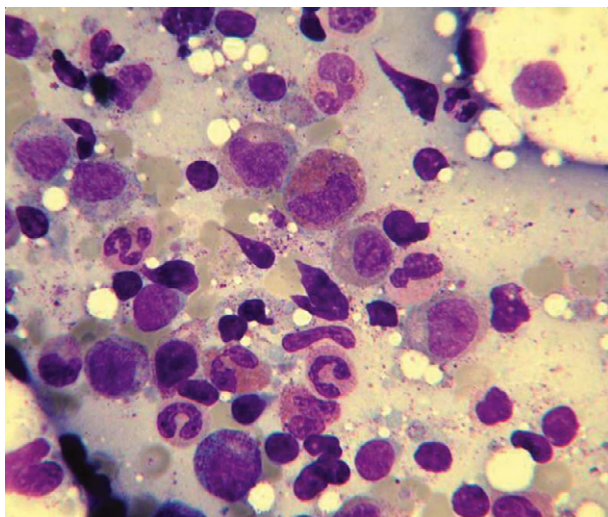


Figure 2. Bone marrow biopsy: there is severe erythroid hypoplasia associated with normal myeloid series (Wright's stain, $1,000\times$).

$7.0 \times 4.5 \times 8.4$ cm in size (Figure 1B). Ultrasound-guided percutaneous fine needle biopsy was performed, and the pathologist confirmed a diagnosis of thymoma. Even with mild elevation of AChR-Ab (1.37 nmole/L; normal range <0.5), neurologists ruled out MG due to negative clinical symptoms and signs. Blood tests revealed severe normocytic anemia with a red cell count of $2.17 \times 10^6/\mu\text{L}$, hemoglobin of 5.0 g/dL and reticulocyte count of 0.09% , but normal white blood cell and platelet counts. Normal serum bilirubin, serum haptoglobin, and urine hemosiderin levels ruled out the possibility of hemolysis. Serum levels of vitamin B12, folic acid, ferritin and total iron binding capacity were all within normal limits. Thus, bone marrow biopsy was done, showing severe erythroid hypoplasia with normal myeloid and megakaryocytic cell lineages. PRCA was diagnosed (Figure 2).

Positive antinuclear ($1:320$) and anti-DS-DNA antibodies (55 IU/mL) were detected, but anti-Smith and anti-cardiolipin IgM antibodies were not found. All indicated an aberration in immunologic conditions. In addition, low IgG (675 mg/dL; normal range, 751 – $1,560$), low IgA (41 mg/dL; normal range, 82 – 453) and low C3 (59 mg/dL; normal range, 79 – 152) were noted. These led to the suspicion of hypogammaglobulinemia. The woman was diagnosed with thymoma combined with both PRCA and hypogammaglobulinemia. Preoperatively, she was treated with intravenous dexamethasone 5 mg every 12 hours for 14 days, then with intravenous methylprednisolone $1,000$ mg during the operation, and then with oral prednisolone 5 mg twice a day for 1 month after operation. Median sternotomy was done for extended thymectomy. This showed a yellow-white mass that measured $7.5 \times 5.5 \times 3.5$ cm over the left lobe of the thymus (Figure 3A). Microscopically, the tumor invaded into but not through the fibrous capsule and was composed of spindle cells with foci rich in lymphocytes, compatible with thymoma WHO type AB, in Masaoka stage I (Figure 3B).⁵

The patient's hematologic readings are illustrated in Figure 4. Complete remission from PRCA was achieved and maintained for at least 3 years. Chest CT also demonstrated no tumor recurrence. Her perioperative immunologic changes are listed in Table 1. Her white cell count (1 year after operation) was $4,680$ ($1/\mu\text{L}$), with lymphocyte percentage of 42% . The lymphocyte subpopulations were CD3 of 73% , CD4 of 30% , CD8 of 40% , and CD19 of 8% . The patient did not totally recover from hypogammaglobulinemia. Clinically, she has had no severe infection postoperatively till now. But the canker sores have recurred and continue to bother her.

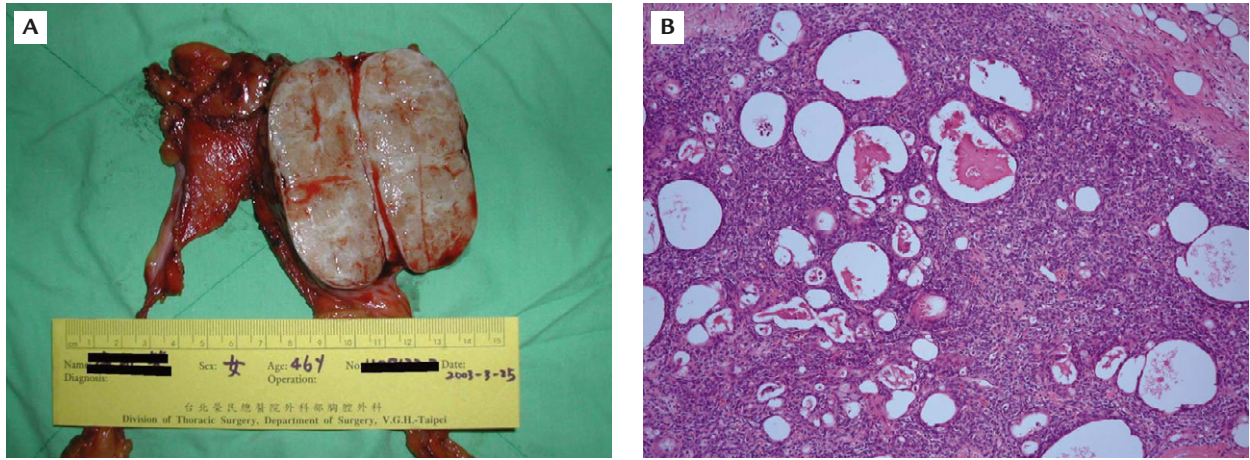
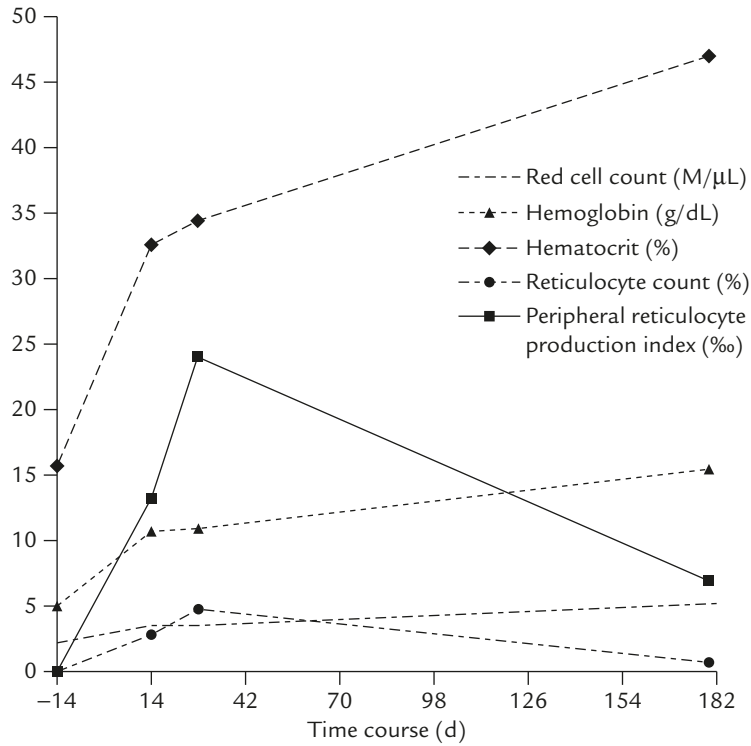


Figure 3. (A) Gross appearance: a yellowish-white mass lesion about 7.5 × 5.5 × 3.5 cm in size located over the left lobe of the thymus. (B) Microscopic picture shows a tumor in which foci have features of type A thymoma mixed with foci rich in lymphocytes (hematoxylin & eosin, 400×).



Hematological conditions	Preoperative	Postoperative				
	14 d	14 d	28 d	6 mo	1 yr	3 yr
Red cell count (M/ μ L)	2.17	3.58	3.56	5.16	4.9	5.13
Hemoglobin (g/dL)	5.0	10.7	10.9	15.5	14.6	15.6
Hematocrit (%)	15.7	32.6	34.5	47.0	45.6	45.7
Reticulocyte count (%)	0.09	2.74	4.69	0.66	-	-
PRPI (%)	0.10	13.23	23.97	6.89	-	-

PRPI = peripheral reticulocyte production index (normal range: 5–15%) = (patient's hematocrit (%) / 45) × reticulocyte count × (1 / correction shift factor of maturation time).

Figure 4. Perioperative changes in hematologic condition.

Table 1. Perioperative changes in clinical manifestation and profile

	Clinical signs/antibody titers/immunoglobulin levels							
	Oral ulcer	Common cold	ANA	DS-DNA (IU/mL)	IgG (mg/dL)	IgA (mg/dL)	CD4 (%)	CD8 (%)
Preoperative	Yes	Yes	1:320	55	675	41	–	–
Postoperative	Yes	No	1:160	Negative	608	8.99	30	40

Discussion

PRCA, either congenital or acquired, is a disease that selectively disturbs erythropoiesis.⁶ Acquired PRCA is further divided into primary and secondary. Primary PRCA has no suspicious causative disease or drug, and sometimes shows autoantibodies to erythroblasts or erythropoietins, or is a disorder of lymphocytes relating to erythropoiesis. For example, there may be an increase in T-cell suppression that inhibits erythropoiesis.⁶ Secondary PRCA, however, has some suspicious causes, such as thymoma, malignant lymphoma, chronic leukemia, systemic lupus erythematosus (SLE), and Sjögren's syndrome. Among them, thymoma is the most common.^{7,8} Thymoma might produce suppressor T-cells or serum thymic factor that inhibits erythroid differentiation, but the definite inhibitors have not yet been identified.^{9–11} The inhibitors may decay after extended thymectomy; its course can be reflected by peripheral reticulocyte production index (PRPI) increase (Figure 4). From 14 days before to 14 days after surgery, PRPI in our patient increased 132-fold, from 0.1‰ to 13.2‰. This implies an inhibitor drop in the circulation and adequate compensated erythropoiesis in the bone marrow. Further detection of inhibitors of erythropoietin or erythroid progenitor in the future is recommended.

Thymoma with hypogammaglobulinemia was first described by Dr Robert Good in 1954, and termed *Good's syndrome*. It becomes obvious in the 4th or 5th decades of life, and most patients suffer from recurrent sinopulmonary, bacterial urinary tract and skin infections. Serum shows hypogammaglobulinemia, few B-cells, an abnormal CD4+/CD8+ ratio and CD4 cell lymphopenia.⁴ In our case, IgG and IgA were low, even after extended thymectomy (Table 1). Moreover, B and CD4+ T lymphocytes were few and accounted for 8% and 30% of total leukocytes, respectively. A reversed CD4+ over CD8+ T lymphocyte ratio of 0.75 was also noted. Good's syndrome does not entirely improve after treatment.

According to Jeunet in 1965, 35% of Good's syndrome patients also had pure red cell anemia.¹²

There are only a few reports discussing the coexistence of PRCA and hypogammaglobulinemia in thymoma patients in the literature.^{13–16} The definite mechanism between thymoma, PRCA and hypogammaglobulinemia is still obscure.

The relationship between thymoma histologic type and PRCA is also not clear. Masaoka et al reported that 17 thymoma patients with PRCA were all of the spindle type, in contrast to the polygonal cell types in myasthenic thymomas.¹⁷ But Kuo and Shih doubted the findings because none of their 5 thymoma patients with PRCA were of the spindle type. This included 2 with type B1 thymoma, 2 with type B2 thymoma and 1 with type AB thymoma (new WHO classification).¹⁸ All 17 patients reported by Masaoka et al might be type A thymoma according to the histologic findings of spindle type thymoma. Our case was stage I type AB thymoma, characterized by foci having features of type A thymoma mixed with foci rich in lymphocytes. For thymoma patients with PRCA and hypogammaglobulinemia, typical histologic types have not yet been reported. In the 17 thymoma patients reported by Masaoka et al, 3 had hypogammaglobulinemia. They were all spindle cell thymomas (WHO, type A), different from our case. This discrepancy could be due to a lack of consensus in the histologic classification of thymoma and the low case number.

Treatments for thymoma patients with PRCA, hypogammaglobulinemia or both are also diverse. For thymoma patients, extended thymectomy is the best choice of treatment if the thymoma is resectable. For thymoma patients with PRCA, the complete PRCA remission rate after extended thymectomy is about 30%.^{17,19,20} But Kuo and Shih doubted the effects of surgery, because none of their patients improved after surgery.¹⁸ Adjuvant therapy using immunosuppressive agents might be necessary to achieve complete remission.^{17,18} One month of perioperative steroids plus extended thymectomy led to complete remission in our case. The surgical effects on hypogammaglobulinemia were varied.¹⁷ There are no studies on surgical resection or multimodal treatments in thymoma patients with hypogammaglobulinemia in the English literature.

Extended thymectomy plus intravenous immunoglobulin replacement might be a choice for treating thymoma and altering hypogammaglobulinemia to reduce infection.²¹

Few have discussed the relationships between PRCA, thymoma and hypogammaglobulinemia. Treatment modalities are still controversial. Based on our case and others, it is hypothesized that some kind of inhibitor in the thymoma or thymus itself might precipitate the pathogenesis of PRCA.⁹⁻¹¹ Even after extended thymectomy, previously released inhibitors still circulate in the serum and need time to decay and be eliminated. Before average or range of time to decay, adjuvant steroid therapy might be necessary. Intravenous immunoglobulin replacement therapy is still controversial, except when there are serious signs of infection. Our experience suggests that both extended thymectomy and immunosuppressive therapy may play key roles in patients with thymoma who have both PRCA and hypogammaglobulinemia, but further understanding and improvement in the management of hypogammaglobulinemia are necessary.

References

- Rosenow EC 3rd, Hurley BT. Disorders of the thymus. A review. *Arch Intern Med* 1984;144:763-70.
- Thomas CR, Wright CD, Loehrer PJ. Thymoma: state of the art. *J Clin Oncol* 1999;17:2280-9.
- Ammus SS, Yunis AA. Acquired pure red cell aplasia. *Am J Hematol* 1987;24:311-26.
- Kelleher P, Misbah SA. What is Good's syndrome? Immunological abnormalities in patients with thymoma. *J Clin Pathol* 2003; 56:12-6.
- Rosai J. Histological typing of tumours of the thymus. In: World Health Organization. *International Histological Classification of Tumors*. Berlin: Springer-Verlag, 1999:9-15.
- Krantz SB. Diagnosis and treatment of pure red cell aplasia. *Med Clin North Am* 1976;60:945-58.
- Schmid JR, Kiely JM, Harrison EG Jr, Bayrd ED, Pease GL. Thymoma associated with pure red-cell agenesis: review of literature and report of 4 cases. *Cancer* 1965;18:216-30.
- Havard CW, Scott RB. Thymic tumour and erythroblastic aplasia: report of three cases and a review of the syndrome. *Br J Haematol* 1960;6:178-90.
- Lahiri TK, Agrawal D, Agrawal K, Shukla J. Pure red cell aplasia associated with thymoma. *Indian J Chest Dis Allied Sci* 2002; 44:259-62.
- Zoumbos NC, Gascon P, Djeu JY, Trost SR, Young NS. Circulating activated suppressor T lymphocytes in aplastic anemia. *N Engl J Med* 1985;312:257-65.
- Peschle C, Marmont AM, Marone G, Genovese A, Sasso GF, Condorelli M. Pure red cell aplasia: studies on an IgG serum inhibitor neutralizing erythropoietin. *Br J Haematol* 1975;30: 411-7.
- Jeunet F. Thymoma and immunoglobulin deficiency syndrome. *Schweiz Med Wochenschr* 1965;95:1419-20.
- Sato M, Nagai H, Kurasima A, Yotsumoto H, Mohri M, Tanaka K, Fukushima K, et al. Lung abscess in a patient with Good's syndrome and pure red cell aplasia. *Nihon Kokyuki Gakkai Zasshi* 1998;36:187-91.
- Kawamura M, Sawafuji M, Hangai N, Yamamoto T, Kakizaki T, Kobayashi T, Kato R, et al. Multidisciplinary treatment for a patient with recurrent thymoma associated with myasthenia gravis (MG), pure red cell aplasia (PRCA), and hypogammaglobulinemia. *Kyobu Geka* 1993;46:1161-5.
- Fujimura S, Ohnuki T, Tanida T, Kondo T, Yamauchi A, Handa M, Okabe T, et al. Surgery of thymoma associated with pure red cell aplasia (PRCA) and hypogammaglobulinemia. *Kyobu Geka* 1982;35:800-4.
- Murray WD, Webb JN. Thymoma associated with hypogammaglobulinemia and pure red cell aplasia. *Am J Med* 1966; 41:974-80.
- Masaoka A, Hashimoto T, Shibata K, Yamakawa Y, Nakamae K, Iizuka M. Thymomas associated with pure red cell aplasia: histologic and follow-up studies. *Cancer* 1989;64:1872-8.
- Kuo T, Shih LY. Histologic types of thymoma associated with pure red cell aplasia: a study of five cases including a composite tumor of organoid thymoma associated with an unusual lipofibroblastoma. *Int J Surg Pathol* 2001;9:29-35.
- Zeok JV, Todd EP, Dillon M, DeSimone P, Utley JR. The role of thymectomy in red cell aplasia. *Ann Thorac Surg* 1979;28: 257-60.
- Hirst E, Robertson TI. The syndrome of thymoma and erythroblastopenic anemia. A review of 56 cases including 3 case reports. *Medicine (Baltimore)* 1967;46:225-64.
- Tarr PE, Sneller MC, Mechanic LJ, Economides A, Eger CM, Strober W, Cunningham-Rundles C, et al. Infections in patients with immunodeficiency with thymoma (Good's syndrome): report of 5 cases and review of the literature. *Medicine (Baltimore)* 2001;80:123-33.