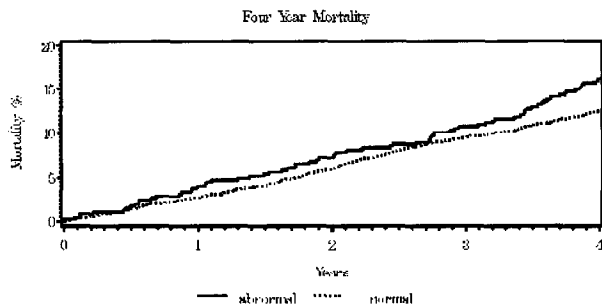


the mortality outcome significantly as has been demonstrated in prior studies  
**Conclusion:** Post-exercise ABI is an important predictor of all-cause mortality.



11:30 a.m.

### 886-5 Contrast-Enhanced Ultrasound Imaging Measurement of Carotid Artery Intimal Medial Thickness

**James E. Macioch**, Samir N. Patel, Charlotte J. Bai, Paras S. Bhatt, Pete Meyer, Chris T. Geohas, Michael Davidson, Jean-Claude Provost, Steven B. Feinstein, Rush-Presbyterian-St. Luke's Medical Center, Chicago, IL

**Background:** Carotid artery intimal-medial thickness (CIMT) is a noninvasive surrogate marker for atherosclerosis. Using traditional B-mode ultrasound, the IMT of the far wall is well defined. There is significant variability when determining the near wall IMT due to difficulty discerning the lumen-intima interface. The aim of this study was to determine whether contrast-enhanced ultrasound of the common carotid artery (CCA) would better delineate this interface, therefore allowing for improved accuracy when measuring the CIMT.

**Methods:** 117 patients had CIMT of right and left CCA. Each patient underwent imaging with contrast and without Optison<sup>TM</sup> (contrast agent). Six points along both the near and far wall were measured over a 1cm distance. 234 carotid arteries (117 patients) were examined for a total of 5616 IMT measurements.

Contrast enhancement on the near wall CIMT is significant ( $p < 0.0001$ ), with the IMT measuring 19% greater than its corresponding non-contrast image. Non-contrast ultrasound imaging underestimates the near wall IMT by 20% when compared to histologic measures. The contrast-enhanced near wall IMT was 12% thicker than the far wall IMT ( $p = 0.001$ ).

**Conclusion:** Contrast-enhanced CIMT:

- 1) Near wall is thicker with contrast ( $P < 0.0001$ )
- 2) Near wall with contrast is thicker than the far wall CIMT.

	NON-CONTRAST	CONTRAST	pValue
Near Wall IMT (cm)	0.062 +/- 0.013	0.074 +/- 0.018	<0.0001
Far Wall IMT (cm)	0.066 +/- 0.014	0.066 +/- 0.020	0.90
pValue	0.02	<0.001	

11:45 a.m.

### 886-6 Briefly Trained Physicians Can Screen for Early Atherosclerosis at the Bedside Using Hand-Carried Carotid Ultrasonography

Bruce J. Kimura, **Steven J. Fowler**, Stan A. Amundson, Duyen T. Nguyen, Anthony N. DeMaria, Scripps Mercy Hospital, San Diego, CA, University of California, San Diego, CA

**Background:** Carotid atherosclerosis is associated with a marked increased risk for coronary heart disease (CHD). In addition to detecting severe stenoses, hand-carried ultrasonography is a novel bedside technique to visualize the early atherosclerotic process and could provide immediate data that would be useful for CHD risk management, particularly in intermediate-risk patients.

**Methods:** To determine whether physicians can learn to screen for "subclinical" atherosclerosis in the extracranial carotid artery, we first trained 16 medical residents with a one-hour course on carotid ultrasound and then tested their diagnostic skill on 10 asymptomatic patients (64 +/- 6y, 7 males) whose carotids (n=20) contained only minimal (n=12) or no plaque (n=8). Carotid findings (plaque thickness, calcification, location, and peak systolic velocity) were confirmed by a standard Duplex study. Residents, blinded to Duplex results, used a hand-carried, 6-lb, 5 MHz device (SonoSite 180) and performed a 5-min, 2D ultrasound exam (without Doppler) of both carotids of each patient. Diagnostic errors were tabulated and sensitivity (SN), specificity (SP), and accuracy (ACC) were calculated for each resident and for the group.

**Results:** On Duplex exam, minimal nonobstructive disease (<50% stenosis) was seen in 12 carotids (plaque thickness: 1.5-3.5mm; peak systolic velocity: 46-119cm/s). Plaque was calcified in 6/12 lesions and isolated to the far wall in 8/12 arteries. Of the 20 arteries, average resident error was 5.9 +/- 2.1 [95% CI: 4.8-7.1]. Hand-carried ultrasound screening (n=320) resulted in an average SN=67% (range: 42-92%), SP=73% (range:

38-100%), and ACC=70% (range: 55-85%). A small, noncalcified atheroma on the far wall was the most difficult lesion to detect.

**Conclusions:** After a 1-hour training course, residents learned a simple bedside screening technique for atherosclerosis. Longer training emphasizing the small soft plaque should improve sensitivity. Teaching carotid ultrasonography using hand-carried devices to primary care physicians has the potential to promote early, in-office detection of the atherosclerotic disease process.

## ORAL CONTRIBUTIONS

### 889 C-Reactive Protein in Vascular Disease

Wednesday, April 02, 2003, 10:30 a.m.-Noon  
 McCormick Place, Room S405

10:30 a.m.

#### 889-1 Marked Coronary Endothelial Dysfunction in Patients With Low High-Density Lipoprotein and Elevated C-Reactive Protein

**Lukas E. Speiker**, Thomas Munzel, Markus Nauck, Winfried Maerz, Wolf Raffienbeul, Micheal Pieper, Gabor Sutsch, Ricardo Seabra-Gomes, Frank van den Branden, Gerald S. Werner, Michael Haude, Kurt Quitzau, Paul G. Hugenholtz, Thomas F. Luscher, Cardiovascular Center, Zurich, Switzerland

**Background:** Inflammation plays a key role in atherosclerosis. Inflammatory markers such as C-reactive protein (CRP) correlate with severity and prognosis of atherosclerotic vascular disease. In contrast, high-density lipoproteins (HDL) have protective effects, which are at least in part related to its anti-inflammatory properties. We investigated the combined effects of low HDL and elevated CRP levels on coronary endothelial function.

**Methods:** In 316 patients with angiographically documented coronary artery disease, the coronary artery vasomotor response to intracoronary infusion of acetylcholine and nitroglycerine was measured by quantitative angiography in a left coronary artery with less than 40% stenosis.

**Results:** CRP levels were inversely associated with HDL cholesterol, but not with LDL cholesterol or triglyceride levels. Those patients with HDL cholesterol below the median (38 mg/dl) and elevated CRP levels (above the median, >0.3 mg/dl) showed a pronounced coronary vasoconstriction to acetylcholine ( $P = 0.02$  for interaction) and had higher levels of ICAM-1 and E-selectin. In contrast, in patients with elevated CRP but HDL above the median the pronounced coronary vasoconstriction was not observed, and levels of cell adhesion molecules (ICAM-1, E-selectin) were lower. Vasodilation to nitroglycerin was not affected by HDL or CRP levels.

**Conclusion:** High concentrations of HDL cholesterol levels prevent marked endothelial dysfunction in epicardial coronary arteries in patients with stable coronary artery disease and with elevated inflammatory markers. These findings illustrate the potential of novel therapeutic strategies attempting to increase HDL and reduce CRP for the prevention of inflammation-induced coronary dysfunction.

10:45 a.m.

#### 889-2 C-Reactive Protein Activates the NF- $\kappa$ B Signal Transduction Pathway in Human Saphenous Vein Endothelial Cells

**Subodh Verma**, Mitesh V. Badiwala, Chao H. Wang, Richard D. Weisel, Shu-Hong Li, Bikramjit Dhillon, Paul W. Fedak, Ren-Ke Li, Donald A. Mickle, University of Toronto, Toronto, ON, Canada

**BACKGROUND:** C-Reactive Protein (CRP) is one of the most powerful predictors of myocardial infarction, stroke, and vascular death currently known. Recent studies demonstrate marked upregulation of ICAM-1, VCAM-1 and MCP-1 with concomitant down-regulation of eNOS in endothelial cells subjected to CRP. The NF- $\kappa$ B signal transduction pathway is known to play a key role in expression of these proatherogenic entities. However, the direct effect of CRP on NF- $\kappa$ B signal transduction pathway activation is unknown. We conducted a series of studies to examine the direct effects of human recombinant CRP on  $\kappa$ B degradation and subsequent NF- $\kappa$ B activation.

**METHODS:** Human Saphenous Vein Endothelial Cells (HSVECs) were harvested from vein segments obtained from patients undergoing CABG surgery and were grown to confluency. The degradation of  $\kappa$ B- $\alpha$  and  $\kappa$ B- $\beta$  were assessed by Western Blotting of the cell lysates obtained from cells incubated with Human Recombinant CRP (50  $\mu$ g/mL) for 15 min, 30 min, and 1 hour. The activation of NF- $\kappa$ B was determined by confocal microscopy assessing the nuclear localization of NF- $\kappa$ B in cells incubated with CRP (50  $\mu$ g/mL) for 30 minutes and 3 hours. Cells not incubated with CRP were used as negative controls and cells incubated with TNF- $\alpha$  (10 ng/mL) for 15 min were used as positive controls in all studies.

**RESULTS:** Incubation with CRP resulted in degradation of  $\kappa$ B- $\alpha$  that was maximal at 30 minutes ( $p < 0.05$ ). CRP had no significant effect on  $\kappa$ B- $\beta$  degradation. NF- $\kappa$ B nuclear localization in HSVECs increased significantly after 30 minutes of incubation with CRP ( $p < 0.01$ ). Nuclear localization of NF- $\kappa$ B returned to baseline levels after 3 hours of incubation with CRP.

**CONCLUSIONS:** These data demonstrate, for the first time, that CRP activates the NF- $\kappa$ B signal transduction pathway in HSVECs. Degradation of  $\kappa$ B- $\alpha$  but not  $\kappa$ B- $\beta$  seems to be the major pathway leading to NF- $\kappa$ B nuclear localization and activation induced by CRP. Future studies and interventions targeted at blocking  $\kappa$ B- $\alpha$  degradation and/or NF- $\kappa$ B activation are justified with the aim of attenuating the proatherogenic effects of CRP on vascular endothelial cells.