View metadata, citation and similar papers at core.ac.uk
brought to you by CORE
provided by Elsevier - Publisher Connector

© 2012 International Society of Nephrology

Medullary amyloidosis associated with apolipoprotein A-IV deposition

Sanjeev Sethi[1], Jason D. Theis[1], Shirley M. Shiller[1], Cynthia C. Nast[2], David Harrison[3], Helmut G. Rennke[4], Julie A. Vrana[1] and Ahmet Dogan[1]

[1]Department of Laboratory Medicine and Pathology, Mayo Clinic, Rochester, Minnesota, USA; [2]Department of Pathology, Cedars Sinai Hospital, Los Angeles, California, USA; [3]Best Doctors, Boston, Massachusetts, USA and [4]Department of Pathology, Brigham and Women's Hospital, Boston, Massachusetts, USA

Amyloidosis is caused by extracellular deposition of proteins in an insoluble manner within tissues. In hereditary forms of amyloidosis, transthyretin, fibrinogen A-α, lysozyme, gelsolin, apolipoprotein A-I, and A-II accumulate in the tissue plaques. Here we describe a 52-year-old man with no family history of renal disease who presented with increased urinary frequency, gradual loss of renal function but no significant proteinuria. Renal biopsy found large amounts of amyloid restricted to the medulla with no involvement of glomeruli or vessels. Immunohistochemical analysis for transthyretin or serum amyloid A and tests for an underlying monoclonal gammopathy were negative. Although initially suspected to be amyloid light chain amyloidosis, laser microdissection and mass spectrometry showed that the amyloid was composed of large amounts of apolipoprotein A-IV. This was based on mass spectrometry studies that showed 100, 96, and 73 spectra in three microdissected samples that matched to apolipoprotein A-IV with 100% probability. DNA analyses detected three sequence variants representing common polymorphisms of the apolipoprotein A-IV gene. Thus, in this case, apolipoprotein A-IV deposition and renal involvement appear to be restricted to the medulla. A high degree of suspicion is required for the diagnosis of apolipoprotein A-IV amyloidosis as it may be missed if a renal biopsy consists only of cortex.

Kidney International (2012) **81,** 201–206; doi:10.1038/ki.2011.316; published online 7 September 2011

KEYWORDS: amyloid; apolipoprotein A-IV; laser microdissection; mass spectrometry; medulla; proteomics

Correspondence: *Sanjeev Sethi, Department of Laboratory Medicine and Pathology, Mayo Clinic, 200 1st Street SW, Rochester, Minnesota 55905, USA. E-mail: sethi.sanjeev@mayo.edu*

Received 28 January 2011; revised 1 July 2011; accepted 19 July 2011; published online 7 September 2011

Amyloidosis is caused by extracellular deposition of proteins in an insoluble β-pleated format. Amyloid deposits are identified based on their apple-green birefringence under a polarized light microscope on Congo red staining and by the presence of rigid, non-branching fibrils that measure 7.5–10 nm in diameter on electron microscopy.[1,2] The most common forms of systemic amyloidosis are immunoglobulin light-chain amyloidosis, and reactive secondary amyloidosis due to chronic inflammatory diseases (e.g., rheumatoid arthritis and chronic infections). Hereditary forms of amyloidosis is another group of amyloid that is now being diagnosed with increasing frequency, and includes amyloid derived from transthyretins (TTRs), fibrinogen A-α chain, lysozyme, and apolipoproteins.[3–10]

Renal apolipoprotein A-I and A-II amyloidosis have recently been described.[4,5] Apolipoprotein A-I amyloidosis shows extensive involvement of the medulla with tubulointerstitial nephritis,[11] whereas apolipoprotein A-II amyloidosis tends to involve glomeruli and vessels.[6,12] Renal apolipoprotein A-IV-associated amyloidosis has not been described, although apolipoprotein A-IV was co-deposited with TTR in the heart in a case of senile systemic amyloidosis.[13,14] Apolipoprotein A-IV is a small 46 kDa glycoprotein that is primarily synthesized in the small intestine and is important in the absorption, transport, and metabolism of lipids.[14] We describe a unique case of renal amyloidosis confined to the medulla, and using laser microdissection and mass spectrometry we show that the amyloid is composed predominantly of apolipoprotein A-IV.

RESULTS

Case history

A 52-year-old man presented with a 10-year history of urinary symptoms of frequency and urgency. His primary-care physician evaluated him through the years. Urinalyses and prostate-specific antigen were reportedly always within normal limits. However, even 7 years ago, his serum creatinine was elevated at 1.7 mg/dl, and gradually had risen to 1.97 mg/dl last year at which time he was referred to a nephrologist. The patient reported an increased sensation of bladder pain preceding urination. Urinalysis

Table 1 | Summary of laboratory findings

		Reference range
White blood cell count	$6.80 \times 10^3/\mu l$	$3.28–9.29 \times 10^3/\mu l$
Red blood cell count	$4.61 \times 10^6/\mu l$	$4.21–5.6 \times 10^6/\mu l$
Hemoglobin	14.6 g/dl	12.3–16.3 g/dl
Hematocrit	41.2%	37.4–47%
Platelet count	$167 \times 10^3/\mu l$	$143–398 \times 10^3/\mu l$
Beta-2-microgobulin	2.7 mg/dl	1.0–2.1 mg/dl
Sodium	142 mmol/l	137–145 mEq/l
Potassium	4.7 mmol/l	3.6–5.4 mEq/l
Chloride	105 mmol/l	98–110 mEq/l
CO_2 content	31 mmol/l	20–29 mmol/l
Glucose	98 mg/dl	65–100 mg/dl
eGFR	33 ml/min	$>$ 89 ml/min
Creatinine	2.1 mg/dl	0.5–1.3 mg/dl
Urea nitrogen	21 mg/dl	7–23 mg/dl
Total protein	6.6 g/dl	6.2–8.3 g/dl
Albumin	4.5 g/dl	3.7–5.1 U/l
Total bilirubin	0.5 mg/dl	0.2–1.1 mg/dl
Alkaline phosphatase	60 U/l	31–103 U/l
Aspartate transferase	18 U/l	7–36 U/l

was unremarkable. The impression was of stage III chronic kidney disease of unknown etiology. The patient did not smoke and his family history was negative for renal disease. Renal ultrasound with post-void bladder scanning was unremarkable. Twenty-four hour urine collection showed no proteinuria. Serum and urine protein electrophoresis and immunofixation studies were negative for monoclonal proteins. Free light chain (kappa to lambda) ratio was 1.05. In addition, parathyroid hormone was normal. Laboratory values are given in Table 1. At this time, a renal biopsy was performed.

Renal biopsy findings

Light microscopy. Three cores were received and contained both renal cortex and medulla. There were up to 27 glomeruli present in the sample submitted for light microscopy; three glomeruli were globally sclerosed. Glomeruli with segmental sclerosis were not present. The glomeruli showed no significant abnormalities; in particular, there was no hypercellularity, leukocytic infiltrates, or crescents, and deposits of amorphous, homogeneous, acellular, eosinophilic material were not present in the glomeruli (Figure 1a). In contrast, the medulla was expanded by accumulation of acellular, eosinophilic, amorphous material (Figure 1b). Congo red stain revealed orange-red deposits limited to the medulla that showed the characteristic apple-green birefringence of amyloid under polarized light (Figure 1c and d). There was no inflammation in the cortex or in the medulla. Approximately 10% of the cortical tissue showed tubular atrophy and interstitial fibrosis. Arteries and arterioles showed mild sclerosis of the media without any significant Congo red-positive staining. Immunohistochemistry for reactive secondary amyloidosis and transthyretin was negative.

Immunofluorescence microscopy contained 22 glomeruli, of which 8 were globally sclerosed. The glomeruli were

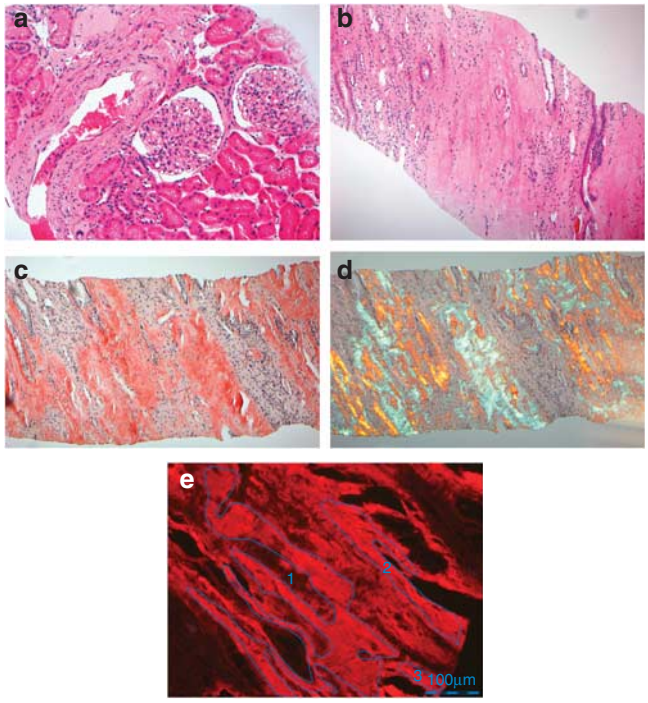

Figure 1 | Light microscopy. (**a**, **b**) Hematoxylin and eosin ($\times$ 40)-stained sections showing (**a**) normal glomerular morphology and (**b**) marked interstitial expansion with the amyloid. (**c**) Congo red showing reddish orange amyloid material in the interstitium that shows (**d**) apple-green birefringence under polarized light ($\times$ 40). (**e**) Congo red stain showing marked area for microdissection.

negative for immune deposits, including kappa and lambda light chains. The medulla was also negative for immune deposits, including kappa and lambda light chains. There was no staining of fibrinogen in the glomeruli or medulla. Electron microscopy showed amyloid fibrils in the medulla, whereas the glomeruli were negative for amyloid fibrils.

The diagnosis was that of renal amyloidosis, undetermined type limited to the renal medulla.

Clinical follow-up. The patient was referred to a hematologist and a cardiologist. The cardiology evaluation included a normal electrocardiogram and echocardiogram, with no wall thickening, no speckling pattern, and a normal left ventricular ejection fraction of 65%. The patient reported no cardiac-related symptoms and his cardiovascular physical exam was within normal limits. He was advised about the need for regular cardiology follow-up in the setting of amyloidosis. A bone marrow aspirate and biopsy at this time showed a normocellular marrow with no evidence of lymphoproliferative or plasma cell disorder. There was also no evidence of amyloid in the bone marrow. Six months following renal biopsy, the patient continued to report dysuria, but he denied weight loss, diarrhea, constipation, abdominal pain, macroglossia, difficulty in swallowing, dizziness, orthostasis, syncope, or paresthesias. The patient was started on dexamethasone and received the first cycle of lenalidomide. Autologous stem cell transplantation was

discussed as the best option for treatment and the patient was accepted into the transplant program.

Laser microdissection and mass spectrometry. At this time, the biopsy specimen was sent to the Renal Biopsy Laboratory Mayo Clinic for work-up and typing of the amyloid. Laser microdissection (LMD) and mass spectrometry analysis of the amyloid was performed as previously described.[15,16] Briefly, Congo red-positive regions of the medulla were microdissected by using laser capture techniques (Figure 1e). Peptides extracted from the microdissected tissue were subjected to liquid chromatography and tandem mass spectrometry (MS/MS). The most abundant peptides detected represented apolipoprotein A-IV protein. MS/MS showed 100, 96, and 73 spectra in three patient samples that matched to apolipoprotein A-IV. Small amounts of apolipoprotein E, serum amyloid protein, apolipoprotein A-I, Igγ1, Igγ2, Igγ3, Igα, kappa and lambda light chains were also detected. LC-MS/MS failed to detect peptides representing transthyretin, fibrinogen A-α, serum amyloid A component, or apolipoprotein A-II. The results are shown in Figure 2.

Genetic evaluation. Sequencing of the *apolipoprotein A-IV* gene was performed. The following three-sequence variants of the *apolipoprotein A-IV* gene were detected: c.548G>A, p.T29T (Thr29Thr) (Figure 3a); c.1678G>A, p.S147N (Ser147Asn) (Figure 3b); and c.2378G>T, p.Q380H (Gln380His) (Figure 3c). Sequencing for *apolipoprotein A-I* gene was performed. Two sequence variants were detected in apolipoprotein A-I as follows: c.60T>C, p. H20H (His20His), and c.209T>C, p. L70P (Leu70Pro).

Final renal biopsy diagnosis. Apolipoprotein A-IV amyloidosis involving the renal medulla.

Further follow-up

Eighteen months following the kidney biopsy, the patient is well, except for his chronic urinary symptoms, including urgency and pain preceding urination. He is following a low-sodium, low-protein diet. He continues to work full time and keeps physically active.

DISCUSSION

We describe a case of renal amyloidosis that was limited to the medulla. The initial suspicion was that of an amyloid light-chain amyloidosis. However, subsequent work-up did not show an underlying gammopathy, and electrophoresis studies and bone marrow biopsy were negative for an underlying lymphoproliferative plasma cell disorder. Staining for serum amyloid A and TTR were also negative on the kidney biopsy. Subsequent protein analysis by LMD and MS/MS revealed the amyloid to be composed primarily of apolipoprotein A-IV.

Hereditary amyloidoses are a group of disorders in which the amyloid fibrils are derived from genetic variants of TTR, fibrinogen A-α chain, gelsolin, lysozyme, apolipoprotein A-I, and apoliporotein A-II. Most cases of hereditary amyloidosis are autosomal dominant with a typically late adulthood onset, and many cases do not have a family history of amyloidosis. Hereditary amyloidosis typically has a slower rate of progression compared with amyloid light-chain amyloidosis. The diagnosis of hereditary amyloidosis has implications for prognosis, genetic counseling, and treatment. A recent study found that almost 10% of the amyloid light-chain amyloidosis diagnosed by clinical or laboratory finding with an absence of family history, in fact, had evidence of an underlying hereditary amyloidosis.[17] The most commonly missed diagnosis was that of fibrinogen A-α chain and TTR amyloidosis.

Our laboratory has considerable experience with work-up and diagnosis of amyloidosis using the technique of LMD and MS/MS, and we have shown that LMD and MS/MS is a sensitive and specific tool for the diagnosis and typing of amyloid.[15,16] We performed LMD on the medullary tissue to determine the composition of amyloid. LMD and MS/MS showed that the amyloid deposits were made of large amounts of apolipoprotein A-IV, which came as a surprise to us. MS/MS showed 100, 96, and 73 spectra in three microdissected samples that matched to apolipoprotein A-IV. This is a very high number of mass spectra and is indicative of great abundance and high amino acid sequence coverage (68% in this case). A high mass spectra value also indicates a higher confidence in protein identification. It is not uncommon to find very small amounts of apolipoprotein E, apolipoprotein A-I and A-IV, and immunoglobulins on mass spectrometry studies on different types of amyloid. However, the extensive deposition of apolipoprotein A-IV is unique in this case, and we have not observed it in any of the other types of amyloidosis.

Our molecular genetics laboratory has extensive experience with transthyretin amyloidosis diagnosis by gene sequencing, and has recently developed sequencing assays for the fibrinogen-alpha, lysozyme, gelsolinA, apoplipoprotein A-I, and apolipoprotein A-II familial amyloidosis variants. An assay has also been developed for apolipoprotein A-IV, as this protein has been detected in other cases of suspected amyloidosis. Although the literature lacks evidence supporting apolipoprotein A-IV as a genetic disorder, the possibility for this entity still exists as more cases are investigated and detected initially through LC MS/MS. *In silico* analysis using Alamut v2 (Interactive Biosoftware, San Diego, CA) indicates that the two-sequence variants in apolipoprotein-AI and three-sequence variants detected in apolipoprotein A-IV in our case are common polymorphisms in the respective genes. Moreover, the c.2378G>T, p.Q380H alteration has been detected previously in our molecular genetics laboratory in a case of cardiac amyloid with apolipoprotein A-IV detected by LC MS/MS (data not shown). According to the dbSNP reference (rs5110) for the Q380H alteration, this polymorphism occurs with an allele frequency of 5–20% depending on the population tested. The dbSNP references for the other two alterations seen, c.548G>A, p.T29T, and c.1678G>A, p.S147N, are rs5104 and rs5092, respectively. An allele frequency of 10–40% exists for the T29T sequence variant, and 5–30% for S147N, also

a

Display Options: Unweighted Spectrum Count Req Mods: No Filter Search:

Probability Legend: over 95% | 80% to 94% | 50% to 79% | 20% to 49% | 0% to 19%

#	Visible?	Starred?	Bio View: Identified Proteins (283)	Accession Number	Molecular Weight	Protein Grouping Ambiguity	Blank	Patient Sample 1	Patient Sample 2	Patient Sample 3
1	☑	☆	Apolipoprotein A-IV OS=Homo s...	APOA4_H...	45 kDa			100	96	73
2	☑	☆	Apolipoprotein E OS=Homo sapi...	APOE_HU...	36 kDa			61	47	65
3	☑	☆	Serum amyloid P-component OS...	SAMP_HU...	25 kDa			16	16	20
4	☑	☆	Ig gamma-1 chain C region OS=...	IGHG1_HU...	36 kDa	★		11	9	9
5	☑	☆	Ig kappa chain C region OS=Ho...	IGKC_HUM...	12 kDa			9	8	9
6	☑	☆	Apolipoprotein A-I OS=Homo sa...	APOA1_H...	31 kDa			4	7	4
7	☑	☆	Ig gamma-3 chain C region OS=...	IGHG3_HU...	41 kDa	★		9	7	7
8	☑	☆	Ig gamma-2 chain C region OS=...	IGHG2_HU...	36 kDa	★		7	6	7
9	☑	☆	Ig lambda chain C regions OS=H...	LAC_HUMAN	11 kDa			2	2	2
10	☑	☆	Ig alpha-1 chain C region OS=H...	IGHA1_HU...	38 kDa			1	1	
11	☑	☆	Serum albumin OS=Homo sapien...	ALBU_HU...	69 kDa			77	59	81
12	☑	☆	Vitronectin OS=Homo sapiens G...	VTNC_HU...	54 kDa			57	68	54
13	☑	☆	Collagen alpha-2(I) chain OS=H...	CO1A2_H...	129 kDa			16	17	11
14	☑	☆	Alpha-1-antitrypsin OS=Homo s...	A1AT_HU...	47 kDa			13	16	10
15	☑	☆	Collagen alpha-1(I) chain OS=H...	CO1A1_H...	139 kDa			14	11	11
16	☑	☆	Clusterin OS=Homo sapiens GN...	CLUS_HU...	52 kDa			4	15	12
17	☑	☆	Serotransferrin OS=Homo sapie...	TRFE_HU...	77 kDa			11	6	6
18	☑	☆	Fibrillin-1 OS=Homo sapiens GN...	FBN1_HU...	312 kDa			5	6	5
19	☑	☆	Actin, cytoplasmic 1 OS=Homo s...	ACTB_HU...	42 kDa	★		4	7	4
20	☑	☆	Protein AMBP OS=Homo sapiens...	AMBP_HU...	39 kDa			5	5	6

b

APOA4_HUMAN (100%), 45,399.4 Da
Apolipoprotein A-IV OS=Homo sapiens GN=APOA4 PE=1 SV=3 (sp) (P06727)
26 unique peptides, 33 unique spectra, 96 total spectra, 268/396 amino acids (68% coverage)

M F L K A V V L T L	A L V A V A G A R A	E V S A D Q V A T V	M W D Y F S Q L S N	N A K E A V E H L Q
K S E L T Q Q L N A	L F Q D K L G E V N	T Y A G D L Q K K L	V P F A T E L H E R	L A K D S E K L K E
E I G K E L E E L R	A R L L P H A N E V	S Q K I G D N L R E	L Q Q R L E P Y A D	Q L R T Q V N T Q A
E Q L R R Q L T P Y	A Q R M E R V L R E	N A D S L Q A S L R	P H A D E L K A K I	D Q N V E E L K G R
L T P Y A D E F K V	K I D Q T V E E L R	R S L A P Y A Q D T	Q E K L N H Q L E G	L T F Q M K K N A E
E L K A R I S A S A	E E L R Q R L A P L	A E D V R G N L R G	N T E G L Q K S L A	E L G G H L D Q Q V
E E F R R R V E P Y	G E N F N K A L V Q	Q M E Q L R Q K L G	P H A G D V E G H L	S F L E K D L R D K
V N S F F S T F K E	K E S Q D K T L S L	P E L E Q Q Q E Q Q	Q E Q Q Q E Q V Q M	L A P L E S

c

Sequence Coverage	Prob	Protein	Bio Sample	#Spec	Weight
	100%	Apolipoprotein A-IV ...	Patient Sample 1	100	45 kDa
	100%	Apolipoprotein A-IV ...	Patient Sample 2	96	45 kDa
	100%	Apolipoprotein A-IV ...	Patient Sample 3	73	45 kDa

Figure 2 | Mass spectrometry data. (**a**) Scaffold readout of top 20 proteins by Spectra. Liquid chromatography and tandem mass spectrometry (LC-MS/MS) proteomic data are shown from three samples prepared from three separate laser microdissections (LMDs) of Congo red-positive medullary tissue. The proteomic data show large amount of apolipoprotein A-IV with 100% probability. The probability number (100% is highlighted by green, >90% by yellow) indicates essentially the percent homology between peptides detected in the specimens and the published amino acid sequences of their corresponding proteins. (**b**, **c**) Sequence coverage shows that peptides in microdissected sample covers 68% of apolipoprotein A-IV peptide sequence and shows 100% probability of the protein representing apolipoprotein A-IV.

depending on the population tested. No allele frequency data nor dbSNP references are available for the alterations detected in apolipoprotein A-I; however, our laboratory experience has demonstrated the H20H alteration in 95% of cases sequenced thus far, and the L70P in greater than 1%. Allele frequencies greater than 1% suggest that the sequence variant occurs with regular frequency in the genome and population, hence implying that the change is well tolerated and does not elicit pathogenesis. Furthermore, the H20H (apolipoprotein A-I) and T29T (apolipoprotein A-IV) alterations are silent changes (conferring no change in amino acid) and inherently assumed to be nonpathogenic. The potential for a splice-site change for all of these variants was performed, with particular relevance to the H20H and T29T

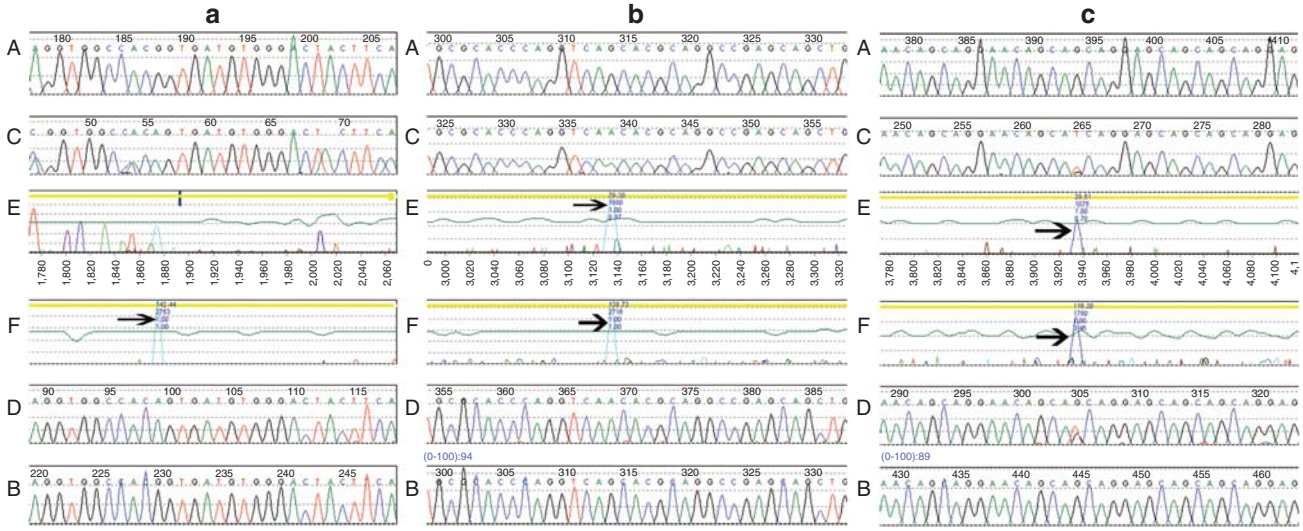

Figure 3 | Sequencing of apolipoprotein A-IV. (**a**) Left panel: electropherogram of c.548G > A, p.T29T alteration. Segments A and B are the reference sequence, C and D are the patient's sequence, and E and F are the subtraction plot between the reference sequence and the patient. The black arrow indicates the detected alteration. (**b**) Middle panel: electropherogram of c.1678G > A, p.147S > N alteration. Segments A and B are the reference sequence, C and D the patient's sequence, and E and F are the subtraction plot between the reference sequence and the patient. The black arrows indicate the detected alteration. (**c**) Right panel: electropherogram of c.2378G > T, p.Q380H alteration. Segments A and B are the reference sequence, C and D the patient's sequence, and E and F are the subtraction plot between the reference sequence and the patient. The black arrows indicate the detected alteration.

(silent) variants in apolipoprotein A-I and apolipoprotein A-IV, respectively. Results of this analysis further supported that these changes are benign polymorphisms as no change in mRNA splicing was noted. Bergstrom *et al.*[13,14] also did not find any mutations in the nucleotides of the *apolipoprotein A-IV* gene cloned from a patient with cardiac amyloid composed of apolipoprotein A-IV and TTR. Thus far, this is the extent of our understanding of the genetic alterations in amyloidosis associated with apolipoprotein A-IV. With time, some changes detected, which were originally thought to be benign polymorphisms, may be determined to be pathogenic as has been seen with other genetic diseases. More cases are needed to sort out this dilemma.

This is the first report to show amyloidosis associated with apolipoprotein A-IV in the kidney. The renal involvement was limited to the medulla and the cortex showed no amyloid deposition. This is in sharp contrast to the typical renal amyloid in which the glomeruli, vascular compartment and, less often, tubulointerstitium are involved. The limitation of the amyloid to the medulla correlates with the clinical findings of slow decline of renal function, unremarkable urinalysis, and no significant proteinuria. The apolipoprotein A-IV appears similar in this regard to apolipoprotein A-I, which also involves the medulla, with similar clinical findings of moderate polyuria and nocturia, suggesting a mild form of nephrogenic diabetes insipidus.[11] Patients with apolipoprotein A-1 often show liver disease with deposition of amyloid in the liver, resulting in abnormal liver function tests; cardiac amyloidosis is also noted in a few patients. In our patient, liver and cardiac function was normal, and neither liver nor cardiac biopsies have been performed to determine whether there is subclinical involvement of these organs by amyloid. It is possible that apolipoprotein A-IV-associated amyloid does not involve the heart and liver. There is no specific therapy available for apolipoprotein A-IV-associated amyloid. However, given the long history of renal dysfunction in our patient, apolipoprotein A-IV amyloid appears to be only very slowly progressive. Renal transplantation is a likely option when end-stage renal disease develops.

Studies on apolipoprotein A-I have shown that cleavage of the full-length protein and generation of an N-terminal fragment are important steps in amyloidogensis.[18,19] Another study shows that C-terminal amphipathic molecules of apolipoprotein A-I initially bind to the lipid surface, resulting in a major conformational change in the N-terminal portion of the molecule, leading to hydrophobic helix lipid interactions rather than to intramolecular N-terminal hydrophobic helix–helix interactions that would otherwise occur.[20] A similar mechanism is proposed for apolipoprotein A-IV, where the N terminus residues of apolipoprotein A-IV are unfolded and reoriented toward lipid surfaces, resulting in aggregation of these proteins.[13,14] As both apolipoprotein A-I and apolipoprotein A-IV amyloidosis appear to involve the renal medulla genetic analysis, immunohistochemistry, and LMD and MS/MS will be required to differentiate between these two types of amyloidosis.

To summarize, we report a case of renal apolipoprotein A-IV-associated amyloid that is limited to the renal medulla and presents with slowly progressive renal dysfunction. A high degree of suspicion is required for the diagnosis of apolipoprotein A-IV amyloidosis and the diagnosis may be missed if the renal biopsy consists of only renal cortex. As the

diagnosis of this disorder increases in prevalence, perhaps the genetic constructs of this disease, if present, will be better understood. Finally, LC MS/MS is key to setting this process in motion, as it confirms the presence of amyloidogenic protein and classifies the type of amyloid.

MATERIALS AND METHODS

Specimen preparation, laser microdissection, and MS-based proteomic analysis

The methods have previously been published.[15,21,22] Briefly, 10-μm-thick sections of formalin-fixed paraffin-embedded tissues were stained with Congo red. Medulla with positive Congo red areas viewed under fluorescent light source appeared bright red. The Congo red deposits were identified under fluorescent light and microdissected with LMD. Following LMD, there is a vacant space on the slide. The microdissected material was collected into 0.5-ml microcentrifuge tube caps containing 35 μl Tris/EDTA/0.002% Zwittergent buffer. Microdissected fragments were digested into tryptic peptides overnight and analyzed by liquid chromatography electrospray tandem MS. MS raw data files were queried using three different algorithms (Sequest, Mascot, and X!Tandem); the results were combined and assigned peptide and protein probability scores in Scaffold (Proteome Software, Portland, OR). For each case, a list of proteins based on peptides identified by MS was generated. Peptide identifications were accepted if they could be established at greater than 90.0% probability as specified by the Peptide Prophet algorithm.[23–25] Protein identifications below the 90% confidence level and those with single peptide identification were not considered in our analysis. The 'Spectra' value indicates the total number of mass spectrum collected on the mass spectrometer and matched to the protein using the proteomics software. A higher number of mass spectra is indicative of greater abundance and will typically yield greater amino acid sequence coverage. A higher mass spectra value also indicates a higher confidence in the protein identification. Our clinical amyloid testing requires a minimum number of four spectra in all samples before the protein identification will be deemed clinically valid.

Genetic evaluation

Evaluation of mutations for familial amyloidosis (as with other hereditary conditions) requires a blood sample for assessment of germline mutations. This was acquired and submitted to our Molecular Genetics Laboratory. The DNA was extracted using the MagNaPure LC (Roche Diagnostics, Indianapolis, IN), followed by PCR amplification using primers for apolipoprotein A-I and apolipoprotein A-IV with universal sequencing tags attached. Next, gel electrophoresis was performed ensuring adequate PCR product, then the PCR product was cleaned using Agencourt AMPure XP (Beckman Coulter Genomics, Danvers, MA) and placed on ABI3730 for sequencing by capillary electrophoresis. Results were analyzed using the Mutation Surveyor v3.24 software (Softgenetics, State College, PA).

DISCLOSURE

All the authors declared no competing interests.

ACKNOWLEDGMENTS

This research was supported in part by the Fulk Family Foundation award (Mayo Clinic) to SS.

REFERENCES

1. Dember LM. Amyloidosis-associated kidney disease. *J Am Soc Nephrol* 2006; **17**: 3458–3471.
2. Merlini G, Bellotti V. Molecular mechanisms of amyloidosis. *N Engl J Med* 2003; **349**: 583–596.
3. Picken MM. New insights into systemic amyloidosis: the importance of diagnosis of specific type. *Curr Opin Nephrol Hypertens* 2007; **16**: 196–203.
4. Vigushin DM, Gough J, Allan D *et al.* Familial nephropathic systemic amyloidosis caused by apolipoprotein AI variant Arg26. *QJM* 1994; **87**: 149–154.
5. Yazaki M, Liepnieks JJ, Barats MS *et al.* Hereditary systemic amyloidosis associated with a new apolipoprotein AII stop codon mutation Stop78Arg. *Kidney Int* 2003; **64**: 11–16.
6. Yazaki M, Liepnieks JJ, Yamashita T *et al.* Renal amyloidosis caused by a novel stop-codon mutation in the apolipoprotein A-II gene. *Kidney Int* 2001; **60**: 1658–1665.
7. Benson M, Liepnieks J, Uemichi T *et al.* Hereditary renal amyloidosis associated with a mutant fibrinogen [alpha]-chain. *Blood* 1993; **3**: 252–255.
8. Benson MD. Ostertag revisited: the inherited systemic amyloidoses without neuropathy. *Amyloid* 2005; **12**: 75–87.
9. Joy T, Wang J, Hahn A *et al.* Apoa1 related amyloidosis: a case report and literature review. *Clin Biochem* 2003; **36**: 641–645.
10. Gillmore JD, Booth DR, Madhoo S *et al.* Hereditary renal amyloidosis associated with variant lysozyme in a large English family. *Nephrol Dial Transplant* 1999; **14**: 2639–2644.
11. Gregorini G, Izzi C, Obici L *et al.* Renal apolipoprotein A-I amyloidosis: a rare and usually ignored cause of hereditary tubulointerstitial nephritis. *J Am Soc Nephrol* 2005; **16**: 3680–3686.
12. De Gracia R, Fernandez EJ, Rinon C *et al.* Hereditary renal amyloidosis associated with a novel mutation in the apolipoprotein AII gene. *QJM* 2006; **99**: 274.
13. Bergström J, Murphy C, Eulitz M *et al.* Codeposition of apolipoprotein A-IV and transthyretin in senile systemic (ATTR) amyloidosis. *Biochem Biophy Res Commun* 2001; **285**: 903–908.
14. Bergstrom J, Murphy CL, Weiss DT *et al.* Two different types of amyloid deposits—apolipoprotein A-IV and transthyretin—in a patient with systemic amyloidosis. *Lab Invest* 2004; **84**: 981–988.
15. Vrana JA, Gamez JD, Madden BJ *et al.* Classification of amyloidosis by laser microdissection and mass spectrometry based proteomic analysis in clinical biopsy specimens. *Blood* 2009; **114**: 4957–4959.
16. Sethi S, Theis JD, Leung N *et al.* Mass spectrometry based proteomic diagnosis of renal immunoglobulin heavy chain amyloidosis. *Clin J Am Soc Nephrol* 2010; **5**: 2180–2187.
17. Lachmann HJ, Booth DR, Booth SE *et al.* Misdiagnosis of hereditary amyloidosis as AL (primary) amyloidosis. *N Engl J Med* 2002; **346**: 1786–1791.
18. Obici L, Franceschini G, Calabresi L *et al.* Structure, function and amyloidogenic propensity of apolipoprotein A-I. *Amyloid* 2006; **13**: 191–205.
19. Andreola A, Bellotti V, Giorgetti S *et al.* Conformational switching and fibrillogenesis in the amyloidogenic fragment of apolipoprotein A-I. *J Biol Chem* 2003; **278**: 2444–2451.
20. Saito H, Dhanasekaran P, Nguyen D *et al.* Domain structure and lipid interaction in human apolipoproteins A-I and E, a general model. *J Biol Chem* 2003; **278**: 23227–23232.
21. Sethi S, Gamez JD, Vrana JA *et al.* Glomeruli of dense deposit disease contain components of the alternative and terminal complement pathway. *Kidney Int* 2009; **75**: 952–960.
22. Rodriguez FJ, Gamez JD, Vrana JA *et al.* Immunoglobulin derived depositions in the nervous system: novel mass spectrometry application for protein characterization in formalin-fixed tissues. *Lab Invest* 2008; **88**: 1024–1037.
23. Choi NH, Nakano Y, Tobe T *et al.* Incorporation of SP-40,40 into the soluble membrane attack complex (SMAC, SC5b-9) of complement. *Int Immunol* 1990; **2**: 413–417.
24. Nesvizhskii AI, Keller A, Kolker E *et al.* A statistical model for identifying proteins by tandem mass spectrometry. *Anal Chem* 2003; **75**: 4646–4658.
25. Keller A, Nesvizhskii AI, Kolker E *et al.* Empirical statistical model to estimate the accuracy of peptide identifications made by MS/MS and database search. *Anal Chem* 2002; **74**: 5383–5392.