




Available online at  
 ScienceDirect  
[www.sciencedirect.com](http://www.sciencedirect.com)

Elsevier Masson France  
  
[www.em-consulte.com](http://www.em-consulte.com)



## REVIEW

# Genetics and embryological mechanisms of congenital heart diseases

## Génétique et mécanismes embryologiques des cardiopathies congénitales

Fanny Bajolle<sup>a</sup>, Stéphane Zaffran<sup>b</sup>, Damien Bonnet<sup>a,\*</sup>

<sup>a</sup> *Malformations cardiaques congénitales complexes (M3C), Reference Centre, Department of Paediatric Cardiology, hôpital Necker–Enfants-Malades, AP–HP, université Paris-V, 149, rue de Sèvres, 75015 Paris, France*

<sup>b</sup> *CNRS UMR 6216, institut de biologie du développement de Marseille-Luminy, campus de Luminy, 13009 Marseille, France*

Received 30 April 2008; received in revised form 10 June 2008; accepted 19 June 2008  
Available online 4 December 2008

### KEYWORDS

Congenital heart diseases;  
Genetics;  
Cardiogenesis

### MOTS CLÉS

Cardiopathies congénitales ;

**Summary** Developmental genetics of congenital heart diseases has evolved from analysis of embryo sections towards molecular genetics of cardiac morphogenesis with a dynamic view of cardiac development. Lineage analysis, transgenic animal models and retrospective clonal analysis of the developing heart led to identification of different cardiac lineages and their respective roles. Genetics of congenital heart diseases has also changed from formal genetic analysis of familial recurrences or population based analysis to screening for mutations in candidate genes identified in animal models. Based on these new concepts, genetic counselling in congenital heart diseases is based on the mechanism of a given heart defect rather than on its anatomy. Using this approach, genetic heterogeneity or intrafamilial variability of a molecular anomaly can at least be partially explained. Close cooperation between molecular embryologists, pathologists involved in heart development and paediatric cardiologists is crucial for further increase of knowledge in the field of cardiac morphogenesis and genetics of cardiac defects.

© 2008 Elsevier Masson SAS. All rights reserved.

**Résumé** La connaissance de l'embryologie des cardiopathies congénitales a évolué depuis l'anatomie segmentaire sur coupes d'embryons. Aujourd'hui, nous disposons de réelles données d'embryologie moléculaire permettant d'avoir une vision dynamique du cœur en développement. L'utilisation de lignées de souris transgéniques, l'analyse clonale du cœur murin et les nouvelles études de lignage cellulaires ont permis l'identification de deux lignages

\* Corresponding author. Fax: +33 1 44 49 43 40.  
E-mail address: [damien.bonnet@nck.aphp.fr](mailto:damien.bonnet@nck.aphp.fr) (D. Bonnet).

## Génétique ; Cardiogenèse

cardiaques contribuant à la formation du cœur ainsi qu'à la définition de leurs rôles respectifs. La génétique des cardiopathies congénitales a elle aussi évolué depuis la génétique formelle et l'analyse des récurrences familiales. Désormais, nous recherchons des mutations dans des gènes candidats issus des modèles animaux. Le conseil génétique dans les formes isolées de cardiopathies congénitales ou dans les formes familiales est aujourd'hui fondé sur l'appréciation du ou des mécanismes à l'origine de la cardiopathie observée, et donc d'un ou de plusieurs gènes. L'hétérogénéité génétique ou la variabilité d'expression intrafamiliale d'une anomalie moléculaire peut ainsi être expliquée, au moins en partie. Une coopération entre spécialistes de la morphogenèse cardiaque, anatomistes des cardiopathies congénitales et cardiologues pédiatres est devenue indispensable au perfectionnement des connaissances et à l'identification de nouveaux gènes pour les malformations cardiaques chez l'homme.

© 2008 Elsevier Masson SAS. Tous droits réservés.

These last two decades have seen a wealth of new information concerning heart development. Previously, our knowledge of cardiac development was essentially based on the analysis of series of embryo sections and three-dimensional reconstructions so as to clarify the anatomy of certain regions that were difficult to interpret on simple sections. The use of these techniques does not allow either to follow the outcome of a group of cells or to accurately distinguish the development mechanisms of a given cardiac chamber, the atrioventricular junction or even the efferent pathway. The use of molecular techniques has revolutionised all these approaches. A retrospective clonal analysis of the cardiac precursors in the mouse enabled to follow the outcome of a cell and all its descendants (sister cells) in the developing heart [1]. This method, supported by cellular lineage studies [2], has helped to demonstrate that the cardiac development concept based on the "segmentation" of the embryonic heart is far from suitable. In other words, the notion of a primitive cardiac tube cut into segments with a predefined outcome is erroneous. Today, it is asserted that different portions of a developing heart are added sequentially to the primitive linear cardiac tube. The latter derives from the primitive embryonic heart and exclusively supplies the cellular contingent for the future left ventricle [3]. This paper aims to show how the concepts of cardiogenesis have evolved and how this evolution has led to analyse certain congenital heart diseases differently in terms of embryological mechanisms.

## New concepts

### The origins of the heart

Data taken from the retrospective clonal mouse analysis shows that there are two cell lineages from the areas known as "cardiac", at the gastrulation stage. The first lineage forms the embryonic heart, formerly considered the only structure at the origin of the primitive cardiac tube. The second lineage derives from an additional "cardiac" area called the "second cardiac field". We now know that the embryonic heart exclusively provides the precursors for the left ventricle and the cells from both lineages contribute to the formation of the atria and the right ventricle. The efferent pathway derives exclusively from the second cardiac field [4].

### Structure of the primitive cardiac tube

The cardiac tube, connected to the embryo by the dorsal cardiac mesoderm, has a symmetrical structure and it is the addition of cells to its caudal end (venous pole) and cranial end (arterial pole or efferent pathway) which leads to its elongation. This cellular addition participates to this elongation and to the curved movement of the tube called "looping". This asymmetrical curve enables to create the structure of four chambers and the arterial and venous poles. The cardiac chambers (atria and ventricles) then mature through a ballooning process, symmetrically for the atria but sequentially for the ventricles. It is this sequential phenomenon for the ventricles that produces the primitive interventricular foramen (the initial septum) [5].

### Formation of the efferent pathway

Development of the efferent pathway is a complex phenomenon that involves the cells of the neural crest, the endocardium and the underlying myocardium. Several simultaneous and intricate events occur, including the epithelio-mesenchymal transformation of the endocardium to form the endocardial cushions, the colonisation of the extracellular matrix by the neural crest cells providing the aortopulmonary septation, and finally the rotation of the myocardium from the base of the efferent pathway to bring the vessels in line with their respective ventricle (wedging) [6].

## How do these new concepts translate into practice?

To understand how this cognitive research on the cardiac morphogenesis is integrated into paediatric cardiac practice at all stages of life, it is necessary to briefly touch upon the history of cardiac genetics and embryology (Table 1).

### Genetic background and environment

In the 1980s, the recurrence of congenital heart diseases within the same family and the different anatomical phenotypes in the affected individuals led to Nora's hypothesis of multifactorial inheritance of congenital heart diseases.

**Table 1** Conceptual evolution of the genetics of congenital heart diseases.

Concepts	Examples
Multifactorial inheritance Major role of the environment Unique mechanism of anatomically different heart disease: one genetic abnormality—several heart diseases	All heart diseases Teratogenic: rubella, thalidomide Deletion of chromosome 22q1.1 and conotruncal heart diseases
Monogenic nature of many heart diseases	Interatrial communication, atrioventricular canals, tetralogy of Fallot
Failure of strategies of partial phenocopy: genetically different syndrome and non-syndrome associated heart diseases	Interatrial communication and Holt-Oram syndrome ( <i>TBX5</i> ), tetralogy of Fallot and deletion of chromosome 22q1.1, atrioventricular canals and critical cardiac region of trisomy 21
Notion of phenotype continuum or gravity spectrum	Bicuspid aortic valve, aortic stenosis and coarctation, Shone syndrome, hypoplasia of left heart
Variability of intrafamilial expression for a same molecular abnormality	Familial heart diseases of deletion of chromosome 22q1.1
Genetic heterogeneity of congenital heart diseases: one malformation—several genes	Interatrial communication and mutations in <i>NKX2.5</i> , <i>GATA4</i> , <i>MYH7</i>
Heterogeneity of mechanisms for a same heart disease	Common arterial trunk: septation disease of the efferent pathway or of myocardium rotation from the base of the efferent pathway
Redefinition of the phenotype in relation to the mechanism	Double outlet right ventricles

The recurrence was explained by a risk related to “genetic background” and the environment shared within the same family [7].

### One molecular abnormality—one mechanism—one group of heterogeneous heart diseases

Experiences including the ablation of the neural crest cells in chick embryos, the use of quail-chick chimeric models and then the use of “genetic” ablation models of neural crest cells gave rise to the hypothesis that a

disturbed embryonic mechanism in cardiac development could produce anatomically different cardiac phenotypes that were embryological related [8]. The example of heart disease observed in the deletion of chromosome 22q1.1 confirms this concept in humans. Indeed, the children with this cytogenetic abnormality have a heart disease that still involves the efferent pathway or the aortic arches [9]. This concept is expressed in the following way: one molecular abnormality—one mechanism—one group of heart diseases that is potentially heterogeneous anatomically but homogeneous in terms of embryological mechanism.

### Haemodynamic mechanisms of congenital heart diseases

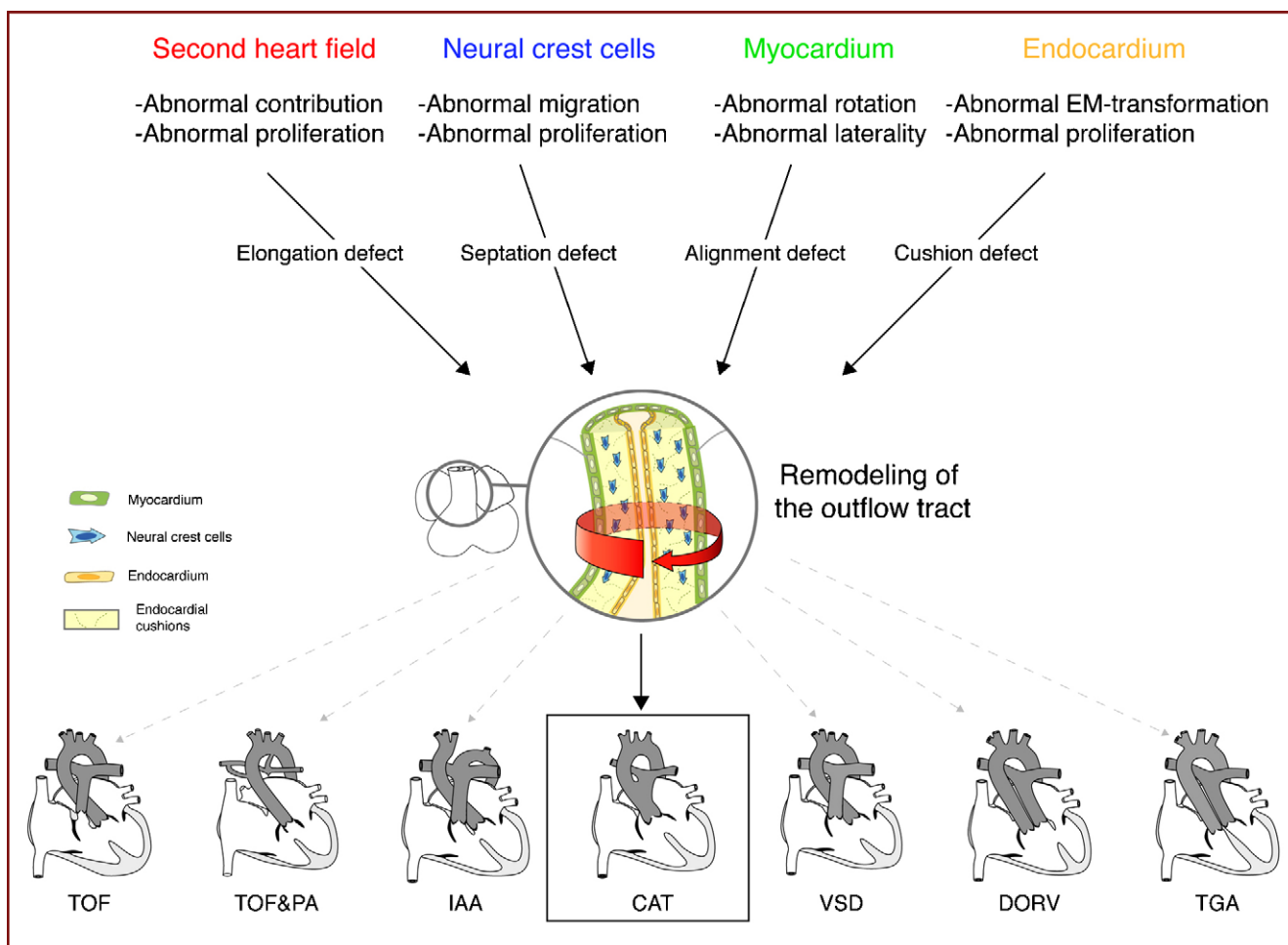
The notion of a phenotype continuum is subtly different from the previous item. The example is that of obstructive heart diseases of the left side heart. Since Abraham Rudolph, it is commonly admitted that the development of heart chambers and resulting vessels is related to the pattern of the combined foetal blood flow that passes through them. Thus, a reduction in flow in the left heart may lead to coarctation, at one end of the spectrum, and to hypoplasia of the left heart, at the other end [10]. The idea that these heart diseases belonged to a same embryological group has been perfectly demonstrated through several arguments, namely recurrences of different severity within the same family, prenatal progression of obstructive left heart diseases, and finally identification of the same mutation in *NOTCH1* in patients of the same family with a different cardiac phenotype [11]. Recently, a study conducted in zebrafish confirmed the relationship between the quality of the intracardiac blood flow and the future morphology of the heart [12].

### Mechanistic classification of congenital heart diseases

The segmental view of congenital heart diseases, while remaining essential during echocardiography analysis, simplifies the embryological and molecular approach. The use of a mechanistic classification proposed by Clark [13] has clarified things and many attitudes are today based on this: indication for screening of 22q1.1 the deletion in conotruncal heart diseases, coherent analysis of recurrences of congenital heart diseases within families, identification of new genes of congenital heart diseases, etc.

### One heart disease—several genes

A great heterogeneity observed in each congenital heart disease group has made the situation more complex, but it has also enabled the analysis of phenotype and genotype relationships for these malformations. Again, the concept is still reflected in daily practice: differential phenotype of atrioventricular canals in relation to the karyotype or their anatomy thereby offering a quick indication of syndrome [14], complexity of the anatomy of pulmonary revascularisation in pulmonary atresia with interventricular communication in relation to their association with deletion



**Figure 1.** One heart disease—several mechanisms—several genes. A malformation may originate from different embryology mechanisms. A common arterial trunk may result from a participation defect of progenitors from the second cardiac field and/or a migration defect of the neural crest cells and/or a rotation defect of the myocardium and/or a formation abnormality of the endocardial cushions. All these mechanisms are controlled by multiple genes (*Pax3*, *Pitx2*, *Tbx1*, *Fgf8*, *Bmp*...). The result is a concept known as “one heart disease—several mechanisms—several genes”. In addition, impairment of these different mechanisms may generate a broad spectrum of heart diseases affecting the conotruncal region (TOF, IAA, DORV...). CAT: common arterial trunk; DORV: double outlet right ventricle; EM: epithelio-mesenchymal; IAA: interrupted aortic arch; TGA: transposition of the great arteries; TOF: tetralogy of Fallot; TOF&PA: tetralogy of Fallot with pulmonary atresia; VSD: sub-arterial ventricular septal defect.

of chromosome 22q1.1 or mutations in *Jagged1* [15,16], etc. We may therefore state one heart disease—several genes.

### One heart disease—several mechanisms—several genes

Continuing with these new developments, the identification of a second cardiac field and the use of transgenic mice have helped to demonstrate that the transposition of the great vessels is a heart disease located in the conotruncal region, but not belonging to this group in the strict sense. Indeed, murine models and the identification in humans of laterality gene mutations in this heart disease are proof that there may be a segmental defect in the left–right laterality [6,17–19]. This would explain why this heart disease is not associated with 22q1.1 deletion, which is common in other types of conotruncal heart diseases. If we develop this concept further, we can see that other heart diseases involving the efferent pathway such as the double outlet right ventricles

or even the common arterial trunk are observed in these animal models with laterality abnormalities. We may therefore conclude that these malformations may originate from different embryological mechanisms, namely a septation defect of the conotruncal region related to a neural crest abnormality, or a rotation and alignment defect of the efferent pathway on the ventricles corresponding to a segmental defect of laterality [6]. These observations lead to the concept of one heart disease—several mechanisms—several genes (Fig. 1). They explain the genetic heterogeneity of certain malformative heart diseases, not by chance but by the heterogeneity of mechanisms.

The “clinical translation” of this cognitive progress is significant. It can be summarised in several points. The *description of the cardiac phenotype* must be anatomically accurate. It must use the segmental classification, while indicating every anatomical detail that would offer guidance on the mechanism of the heart disease. It is only at this price that a suitable genetic advice may be given.

Certain *cardiac malformations* are development sequences or algorithms with a highly complex anatomical outcome (cardiac isomerisms), but they are actually simple since all elements of the heart disease derive from a same morphogenetic defect. The role of the clinician is to recognise these sequences so as to describe each step. Certain heart diseases fall within a *gravity spectrum* such as coarctation of the aorta and hypoplastic left heart syndrome. Knowing how to look for staggered abnormalities of the left track in this group and understanding the progressive nature of these heart diseases that are dependent at least in part upon foetal cardiac flow is essential for screening prenatal and postnatal worsening conditions. Certain heart diseases may be considered as "lures" on the embryological front since they correspond to the anatomical expression of another abnormality. We can cite here the example of the coarctation associated with the persistent left upper vena cava which disturbs the mitral flow during the foetal life. The coarctation here is only the translation of a congenital abnormality to the systemic venous return and not an actual disease of the aorta.

## Conclusion

We deliberately chose not to list the many genes known in congenital heart diseases. This type of information was recently published [20,21]. Far from being esoteric, knowledge of normal cardiac development and the mechanisms of congenital heart diseases are essential to daily practice, as much for the daily examination of heart diseases as for genetic counselling before birth or in the case of familial forms.

## References

- [1] Meilhac SM, Esner M, Kelly RG, Nicolas JF, Buckingham ME. The clonal origin of myocardial cells in different regions of the embryonic mouse heart. *Dev Cell* 2004;6:685–98.
- [2] Cai CL, Liang X, Shi Y, Chu PH, et al. *Isl1* identifies a cardiac progenitor population that proliferates prior to differentiation and contributes a majority of cells to the heart. *Dev Cell* 2003;5:877–89.
- [3] Zaffran S, Kelly RG, Meilhac SM, Buckingham ME, Brown NA. Right ventricular myocardium derives from the anterior heart field. *Circ Res* 2004;95:261–8.
- [4] Buckingham M, Meilhac S, Zaffran S. Building the mammalian heart from two sources of myocardial cells. *Nat Rev Genet* 2005;6:826–35.
- [5] Christoffels VM, Habets PE, Franco D, et al. Chamber formation and morphogenesis in the developing mammalian heart. *Dev Biol* 2000;223:266–78.
- [6] Bajolle F, Zaffran S, Kelly RG, et al. Rotation of the myocardial wall of the outflow tract is implicated in the normal positioning of the great arteries. *Circ Res* 2006;98:421–8.
- [7] Nora JJ. Multifactorial inheritance hypothesis for the etiology of congenital heart diseases. The genetic-environmental interaction. *Circulation* 1968;38:604–17.
- [8] Kirby ML, Turnage KL, Hays BM. Characterization of conotruncal malformations following ablation of "cardiac" neural crest. *Anat Rec* 1985;213:87–93.
- [9] Boudjemline Y, Fermont L, Le Bidois J, Lyonnet S, Sidi D, Bonnet D. Prevalence of 22q11 deletion in fetuses with conotruncal cardiac defects: a 6-year prospective study. *J Pediatr* 2001;138:520–4.
- [10] Heymann MA, Rudolph AM. Effects of congenital heart disease on fetal and neonatal circulations. *Prog Cardiovasc Dis* 1972;15:115–43.
- [11] Garg V, Muth AN, Ransom JF, et al. Mutations in *NOTCH1* cause aortic valve disease. *Nature* 2005;437:270–4.
- [12] Auman HJ, Coleman H, Riley HE, Olale F, Tsai HJ, Yelon D. Functional modulation of cardiac form through regionally confined cell shape changes. *PLoS Biol* 2007;5:604–15.
- [13] Clark EB. Pathogenetic mechanisms of congenital cardiovascular malformations revisited. *Semin Perinatol* 1996;20:465–72.
- [14] Marino B, Vairo U, Corno A, et al. Atrioventricular canal in Down syndrome. Prevalence of associated cardiac malformations compared with patients without Down syndrome. *Am J Dis Child* 1990;144:1120–2.
- [15] Boudjemline Y, Fermont L, Le Bidois J, Villain E, Sidi D, Bonnet D. Can we predict 22q11 status of fetuses with tetralogy of Fallot? *Prenat Diagn* 2002;22:231–4.
- [16] Kamath BM, Spinner NB, Emerick KM, et al. Vascular anomalies in Alagille syndrome: a significant cause of morbidity and mortality. *Circulation* 2004;109:1354–8.
- [17] Goldmuntz E, Bamford R, Karkera JD, dela Cruz J, Roessler E, Muenke M. *CFC1* mutations in patients with transposition of the great arteries and double-outlet right ventricle. *Am J Hum Genet* 2002;70:776–80.
- [18] Muncke N, Jung C, Rudiger H, et al. Missense mutations and gene interruption in *PROSIT240*, a novel TRAP240-like gene, in patients with congenital heart defect (transposition of the great arteries). *Circulation* 2003;108:2843–50.
- [19] Megarbane A, Salem N, Stephan E, et al. X-linked transposition of the great arteries and incomplete penetrance among males with a nonsense mutation in *ZIC3*. *Eur J Hum Genet* 2000;8:704–8.
- [20] Bajolle F, Bonnet D. Left heart defects and genetics. *Arch Mal Coeur* 2006;99:494–6.
- [21] Bajolle F, Zaffran S, Bonnet D. Molecular aspects of congenital heart diseases. *Arch Mal Coeur* 2007;100:484–9.