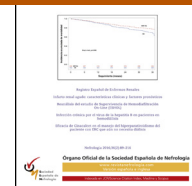




nefrología

Revista de la Sociedad Española de Nefrología

www.revistanefrologia.com



Original article

Acute kidney injury due to excessive and prolonged intramuscular injection of veterinary supplements containing vitamins A, D and E: A series of 16 cases

Elizabeth De Francesco Daher^{a,*}, Lorena Vasconcelos Mesquita Martiniano^a,
Laio Ladislau Lopes Lima^a, Newton Carlos Viana Leite Filho^a,
Louize Emanuele de Oliveira Souza^a, Paulo Henrique Palácio Duarte Fernandes^a,
Sonia Leite da Silva^b, Geraldo Bezerra da Silva Junior^b

^a Department of Internal Medicine, School of Medicine, Medical Sciences Graduate Program, Federal University of Ceará, Fortaleza, Ceará, Brazil

^b School of Medicine, Public Health Graduate Program, University of Fortaleza, Fortaleza, Ceará, Brazil

ARTICLE INFO

Article history:

Received 23 December 2015

Accepted 9 May 2016

Available online xxx

Keywords:

Acute kidney injury
Vitamin supplements
Hypercalcaemia

ABSTRACT

Background: Despite well-documented risks, injectable supplements containing high doses of vitamins are commonly used.

Objectives: To describe acute kidney injury (AKI) as a complication of vitamin intoxication.

Methods: Our series consisted of 16 patients with kidney complications resulting from the use of veterinary intramuscular injection supplements of vitamin A, D and E. The patients were admitted to two referral hospitals in Fortaleza (Brazil) between January 2010 and January 2015.

Results: Patients' mean age was 28.3 ± 8.9 years (19–53 years), and 11 (68.7%) were male. Main signs and symptoms upon admission were nausea (68.7%), vomiting (62.5%), weight loss (43.7%), epigastric pain (31.2%) and headache (31.2%). At hospital admission the mean laboratory values were: hemoglobin 10 ± 2.0 g/dL (6.1–14.2), leukocytes $10,542 \pm 4871/\text{mm}^3$ (4100–15,100), creatinine 3.9 ± 5.2 mg/dL (0.7–22) and urea 91 ± 88 mg/dL (22–306), respectively. Serum calcium was 12 ± 2.2 mg/dL (8.8–15.5), 24-h urine calcium was 575 ± 329 mg (10.7–1058), serum PTH was 55 ± 141 pg/mL (2–406), and serum vitamin D concentration was 135 ± 75 ng/mL (22–265). Using KDIGO criteria, AKI was diagnosed in 13 patients (81.2%), classified as stage 1 ($n=3$), stage 2 ($n=3$) or stage 3 ($n=7$). No deaths occurred in the study period.

Conclusions: Excessive use of veterinary vitamin supplements containing high doses of vitamin A, D and E was associated with AKI. Hypercalcaemia, which was a common finding, appears to be a contributing factor to the development of this type of AKI.

© 2016 Sociedad Española de Nefrología. Published by Elsevier España, S.L.U. This is an open access article under the CC BY-NC-ND license (<http://creativecommons.org/licenses/by-nc-nd/4.0/>).

* Corresponding author.

E-mail address: ef.daher@uol.com.br (E. De Francesco Daher).

<http://dx.doi.org/10.1016/j.nefro.2016.05.017>

0211-6995/© 2016 Sociedad Española de Nefrología. Published by Elsevier España, S.L.U. This is an open access article under the CC BY-NC-ND license (<http://creativecommons.org/licenses/by-nc-nd/4.0/>).

Daño renal agudo debido a inyección intramuscular excesiva y prolongada de suplementos veterinarios con vitaminas A, D y E: serie de 16 casos

R E S U M E N

Palabras clave:

Daño renal agudo
Suplementos vitamínicos
Hipercalcemia

Antecedentes: Suplementos inyectables que contienen altas dosis de vitaminas son utilizados con frecuencia, a pesar de los riesgos bien documentados.

Objetivo: Describir la ocurrencia de daño renal agudo (IRA) como complicación de intoxicación por suplementos vitamínicos.

Métodos: Esta es una serie de 16 pacientes con complicaciones renales resultantes de la utilización de inyección intramuscular de suplementos veterinarios con vitaminas A, D y E. Los pacientes fueron ingresados en 2 hospitales de referencia en Fortaleza (Brasil), entre enero de 2010 y enero de 2015.

Resultados: La edad media de los pacientes fue de $28,3 \pm 8,9$ años (19–53 años) y 11 (68,7%) eran varones. Signos y síntomas principales al ingreso fueron náuseas (68,7%), vómitos (62,5%), pérdida de peso (43,7%), dolor epigástrico (31,2%) y cefalea (31,2%). Al ingreso en el hospital los valores medios de laboratorio fueron: hemoglobina $10 \pm 2,0$ g/dL (6,1–14,2), leucocitos $10.542 \pm 4.871/\text{mm}^3$ (4.100–15.100), creatinina $3,9 \pm 5,2$ mg/dL (0,7–22) y urea 91 ± 88 mg/dL (22–306), respectivamente. El nivel de calcio sérico fue de $12 \pm 2,2$ mg/dL (8,8–15,5), el de calcio en orina de 24 h fue de 575 ± 329 mg (10,7–1.058), el de PTH sérico fue de 55 ± 141 pg/mL (2–406) y el nivel de vitamina D sérica fue de 135 ± 75 ng/mL (22–265). Utilizando criterios KDIGO, se diagnosticó IRA en 13 pacientes (81,2%); fueron clasificadas como clase 1 ($n=3$), clase 2 ($n=3$) y clase 3 ($n=7$). No hubo muertes en el período de estudio.

Conclusiones: El uso excesivo de suplementos vitamínicos veterinarios que contienen altas dosis de vitamina A, D y E se asoció con IRA. La hipercalcemia, un hallazgo común, parece ser un factor que contribuye al desarrollo de este tipo de IRA.

© 2016 Sociedad Española de Nefrología. Publicado por Elsevier España, S.L.U. Este es un artículo Open Access bajo la licencia CC BY-NC-ND (<http://creativecommons.org/licenses/by-nc-nd/4.0/>).

Introduction

Body sculpting is an increasingly common practice in modern society.¹ Some enthusiasts resort to substance abuse to boost results, despite the serious health risks involved. A number of commercially available substances, from anabolic steroids (hormones promoting muscle anabolism) to oily compounds (increasing muscle volume by way of retention, without contributing to anabolism), are known to cause severe damage to the organism.²

One such substance is the compound “ADE”, a veterinary product containing liposoluble vitamin A, D and E, indicated for the treatment of vitamin deficiency and infection in cattle and horses. According to the manufacturers, animals should not be injected with more than 5 mL per 120-day period of fattening. However, much higher doses are used by human body sculptors.² The injection of ADE produces a local granulomatous reaction and encapsulation. If encapsulation fails, or if the substance enters the blood stream, embolism may occur, in some cases followed by death.² In Brazil, human ADE use was first described in the late 1980s, but may have started earlier.³

The purpose of the present study was to evaluate the occurrence of acute kidney injury (AKI) or chronic kidney disease (CKD) in a series of patients admitted to two Brazilian referral hospitals due to complications from excessive and prolonged intramuscular injection of ADE vitamins.

Patients and methods

Study design

This is a descriptive study based on a case series. We have evaluated a series of 16 patients with kidney complications resulting from the use of veterinary intramuscular vitamin supplements containing high doses of vitamin A, D and E. The patients were admitted to two referral hospitals in Fortaleza (Northeastern Brazil) between January 2010 and January 2015. Patients with a history of renal failure, hypertension, diabetes mellitus, nephrolithiasis, nephrotoxic drug use, or any comorbidity potentially detrimental to renal function, were excluded from the analysis.

Vitamin supplements used

All studied patients have used vitamin supplements containing vitamins A, D and E. In each 100 mL the following composition was observed: vitamin A 20,000,000 IU, vitamin D 35,000,000 IU and vitamin E 6000 IU, which represents a very high dose, higher than the recommended daily intake for humans.

Study parameters

Information was collected on demographics, length of hospital stay, clinical manifestations, laboratory findings, need

for dialysis, treatment and mortality. Clinical information included all clinical signs and symptoms registered upon admission and during hospitalization. The laboratory tests included complete blood count, serum urea, creatinine, sodium, potassium, calcium, aspartate aminotransferase, alanine aminotransferase, parathyroid hormone (PTH), vitamin D and urinalysis. Twenty-four-hour urinary calcium levels were also registered.

Definitions

AKI and CKD were diagnosed and classified according to KDIGO criteria.⁴ Due to lack of information on serum creatinine levels prior to admission, all patients were assumed to have a baseline glomerular filtration rate of 100 mL/min/m². The patients were classified as the highest KDIGO stage observed during hospitalization. Oliguria was defined as a urine output <0.5 mL/kg/h. Dialysis was indicated for patients who remained oliguric after effective hydration for at least 24 h, for refractory hypervolemia, severe metabolic acidosis or uremia. High blood pressure was defined as systolic blood pressure \geq 140 mmHg and/or diastolic blood pressure \geq 90 mmHg.

Ethical aspects

The study protocol was reviewed and approved by the Research Ethics Committees of the General Hospital of Fortaleza and the Walter Cantídio University Hospital.

Results

Patients' mean age was 28.3 \pm 8.9 years (19–53 years), and 11 (68.7%) were male. Mean length of hospital stay was 15 \pm 13 days (1–52 days). Upon admission, all patients reported a history of intramuscular injection of vitamin supplements containing vitamins A, D and E for esthetic purposes. Six patients reported concurrent use of anabolic steroids. All were body building practitioners and attended gyms regularly. The median time between the last injection and hospitalization was 10 months (range: 1–48 months). The median time between the first use and hospitalization was 28 months (range: 4–60 months). **Table 1** summarizes patients' clinical and laboratory characteristics.

Main signs and symptoms upon admission were nausea (68.7%), vomiting (62.5%), weight loss (43.7%), epigastric pain (31.2%) and headache (31.2%), fever (25%), paresthesia in the upper and lower limbs (25%), polyuria (18.7%), syncope (18.7%) and anorexia (18.7%). Patients also reported low back pain, edema, nocturia and pallor (12.5% each), and gynecomastia and lymphadenopathy (6.2% each).

At hospital admission the mean laboratory values were: hemoglobin 10 \pm 2.0 g/dL (range 6.1–14.2), leukocytes 10,542 \pm 4871/mm³ (4100–15100), creatinine 3.9 \pm 5.2 mg/dL (0.7–22) and urea 91 \pm 88 mg/dL (22–306), respectively. Serum calcium level was 12 \pm 2.2 mg/dL (8.8–15.5), 24-h urine calcium level was 575 \pm 329 mg (10.7–1058), median PTH level was 55 \pm 141 pg/mL (2–406), and serum vitamin D concentration was 135 \pm 75 ng/mL (22–265). During hospital stay

Table 1 – Clinical and laboratory characteristics of 16 patients with acute kidney injury due to vitamin supplements abuse.

	n	%
Age (years)	28.3 \pm 8.9	–
Gender		
Male	11 (68.7%)	68.7
Female	5 (31.3%)	31.3
Length of hospital stay (days)	15 \pm 13	–
Median time between first use and admission (months)	28	–
Signs and symptoms at admission		
Nausea	11	68.7
Vomiting	10	62.5
Weight loss	7	43.7
Epigastric pain	5	31.2
Headache	5	31.2
Fever	4	25
Paresthesia (limbs)	4	25
Polyuria	3	18.7
Syncope	3	18.7
Anorexia	3	18.7
Low back pain	2	12.5
Edema	2	12.5
Nocturia	2	12.5
Pallor	2	12.5
Gynecomastia	1	6.2
Lymphadenopathy	1	6.2
AKI	13	81.2
Laboratory tests		
Hb _{adm} (g/dL)	10 \pm 2.0	–
Leukocytes _{adm} (1 \times /mm ³)	10,542 \pm 4871	–
Cr _{adm} (mg/dL)	3.9–5.2 mg	–
Cr _{max} (mg/dL)	4.3 \pm 5.2	–
Cr _{dis} (mg/dL)	1.6 \pm 1.8	–
Ur _{adm} (mg/dL)	91 \pm 88	–
Ur _{max} (mg/dL)	102 \pm 86	–
Ur _{dis} (mg/dL)	45 \pm 28	–
Ca _{adm} (mg/dL)	12–2.2	–
Ca _{max} (mg/dL)	13 \pm 2.2	–
24 h-Ca (mg/dL)	575 \pm 329	–
PTH (pg/mL)	55 \pm 141	–
Vitamin D (ng/mL)	135 \pm 75	–

Mean \pm SD and %.

Hb, hemoglobina (g/dL); Ur, urea (mg/dL); Cr, creatinine (mg/dL); Ca, calcium (mg/dL); 24 h-Ca, 24 h calciuria (mg/dL); adm, at admission; max, maximum at hospital stay; dis, at hospital discharge.

maximum creatinine ranged from 0.8 to 8.6 mg/dL (mean 4.3 \pm 5.2 mg/dL) and serum calcium from 10.2 to 16.8 mg/dL (mean 13 \pm 2.2 mg/dL). Laboratory findings for each patient are summarized in **Table 2**.

Three patients had imaging findings compatible with nephrocalcinosis and seven had nephrolithiasis. Using KDIGO criteria, AKI was diagnosed in 13 cases (81.2%) and classified as stage 1 (23%), stage 2 (23%) or stage 3 (54%). No deaths occurred in the study period.

Treatment consisted primarily of controlling calcium levels and complications such as acute pancreatitis due to

Table 2 – Laboratory tests during hospital stay of 16 patients with kidney injury due to vitamin supplements abuse.

#	Age	Gender	Ht adm	Hb adm	WBC adm	Platelets adm	Ur adm	Ur max	Ur dis	Cr adm	Cr max	Cr dis	AST/ALT adm	AST/ALT max	AST/ALT dis	Na adm	K adm	Ca adm	Ca max	Ca dis	Vit D	24 h calciuria	PTH
1	22	F	27.5	9.2	7584	397,709	30	45	33	1.6	1.6	1.1	21/14	–	–	140	3.5	11.9	12.4	11.1	>150	–	–
2	29	M	30	10.1	8214	463,100	62	73	66	1.6	2.4	1.7	19/35	25/52	20/52	139	4.4	11.7	14.6	10	>150	499.8	3.4
3	34	F	26.5	8.9	12,530	288,800	46	80	78	2.5	2.5	1.4	24/14	47/26	–	146	3.5	15.5	16.8	10.1	–	422.8	7
4	23	M	34.7	11.6	4100	200,000	61	61	48	2.5	2.5	1.4	117/73	117/73	–	139	4	–	12.8	9.1	–	–	–
5	29	F	33.3	11.5	10,800	313,000	32	32	30	1.4	1.5	1.2	58/75	58/75	–	136	2.9	11.8	12.8	11.7	182.4	484.16	8.41
6	28	M	29.6	9.16	6060	286,000	32	–	29	1.1	–	0.9	–	–	–	139	3.8	9.5	–	8.8	154.4	–	–
7	19	M	34.8	11.8	23,900	594,000	54	35	30	3.5	3.5	0.8	–	–	–	137	4.2	13.3	13.3	7.9	–	1058	–
8	45	F	34.4	11.5	10,540	250,000	32	57	15	1.5	1.5	0.8	–	15/22	15/22	139	3.8	11	11.3	9.8	>160	428.4	–
9	26	M	–	–	5500	–	55	77	15	2.7	3.7	0.6	–	–	–	135	3	10.6	16.8	8	116.7	1039.5	–
10	53	M	27.7	9.44	15,100	320,000	68	68	42	3.2	3.2	1.3	40/32	50/25	35/22	139	4.8	14	14	9.6	160	536.3	5.15
11	24	M	30.6	10.9	8350	60,000	200	200	56	8.6	8.6	1.8	30/22	–	–	141	3.4	13.8	14.2	–	53.9	330.2	6.32
12	21	M	43.9	14.2	13,000	247,000	22	28	16	0.7	1	0.7	33/44	33/44	22/30	140	4.6	9.2	10.2	10	–	–	–
13	25	F	25.3	8.02	7480	457,000	–	–	–	0.79	0.8	0.8	–	–	–	–	–	10.01	10.73	10.73	129.1	–	2
14	25	M	19.8	6.1	12,540	31,200	247	247	56	5.8	5.8	1.3	31/29	39/48	–	148	4.9	15	15	12	–	–	–
15	24	M	20.4	6.8	12,440	114,600	306	306	124	22	22	8.5	–	–	–	120	4.6	8.8	9	8.6	22.5	10.73	406
16	27	M	33	10.8	–	–	122	122	37	4.1	4.1	1.3	43/45	43/111	36/111	136	5.3	14.9	14.9	9.3	265.25	1012	4.1

Ht, hematocrit (%); Hb, hemoglobina (g/dL); WBC, white blood count (1×/mm³); platelets, 1×/mm³; Ur, urea (mg/dL); Cr, creatinine (mg/dL); AST, aspartate aminotransferase (IU/L); ALT, alanine aminotransferase (IU/L); Na, sodium (mEq/L); K, potassium (mEq/L); Ca, calcium (mg/dL); Vit D, vitamin D (ng/mL); PTH, parathyroid hormone (pg/dL); adm, at admission; max, maximum at hospital stay; dis, at hospital discharge.

hypercalcemia (18.7%) and local infections (18.7%) resulting from intramuscular injections of vitamin supplements without sterilization. Hypercalcemia was treated with vigorous hydration, steroids and loop diuretics. Due to severe AKI, two patients required dialysis. One (#11) received 5 hemodialysis sessions during hospitalization. The other (#15) developed chronic kidney disease and was started on regular hemodialysis three times a week. Six previously non-hypertensive patients presented hypertensive peaks upon admission. Hypertension persisted in four cases who were discharged with prescriptions for anti-hypertensive drugs.

Discussion

A considerable number of patients with severe kidney complications (including chronic kidney failure) from excessive use of vitamin supplements are described in this study. Kidney injury due to vitamin abuse is seldom reported in literature and it seems to be a frequent complication, at least among patients taking very high doses of vitamins (veterinary doses).⁵ The possible mechanisms involved in the pathophysiology of kidney injury associated with hypercalcemia and injectable vitamins A, D and E supplements is schematized in Fig. 1.

As in other granulomatous conditions, such as tuberculosis, sarcoidosis and fungal infections, vitamin D is converted extra-renal into its active form by granuloma cells (especially macrophages). This increases the intestinal absorption of vitamin D-dependent calcium and raises serum calcium levels.⁶ Hypercalcemia and high level of $1,25(\text{OH})_2\text{D}_3$ concentrations have a negative impact on the parathyroid glands, reducing

PTH production and serum levels.⁷ This pattern was observed in most of our patients and in most patients reported in the literature.^{5,8-10}

On the other hand, some believe hypervitaminosis is the result of the absorption of injected vitamin D. Further studies are necessary to clarify the mechanisms involved, but the fact that a similar reaction occurs when other substances (such as paraffin) are injecting into the muscle, along with the observed late onset of hypercalcemia (months later), point to granuloma formation and extra-renal conversion as the most likely explanation.³ If the absorption of injected vitamin D were the culprit, the onset of hypercalcemia would be acute.¹¹⁻¹³

The effects of hypervitaminosis A and E in humans are less studied than hypervitaminosis D. It is known that after consumption of high doses of vitamin A the concentrations of retinoids and metabolites are elevated in plasma. Toxicity following high consumption of vitamin A can be acute (intake >660,000 IU) or chronic, when intake lasts for months or years (a dose >100,000 IU for more than 6 months is considered toxic),^{14,15} and our patients consumed a dose very higher than the levels considered toxic. The main effects of hypervitaminosis A are related to bone metabolism. There is association between high vitamin A intake and osteoporosis and pathological fractures.¹⁴ Other signs and symptoms of vitamin A toxicity include dry skin, nausea, headache, fatigue, irritability, anorexia, liver disease, hair loss and alopecia, hyperostosis, high cholesterol and increased cerebrospinal fluid pressure.¹⁵ Hypervitaminosis E is rare, but it is possible to be more frequent once consumption of this vitamin is increasing due to its potentially antioxidant and antiatherogenic effects. Toxic effects of hypervitaminosis E includes prolongation of prothrombin time and hemorrhage

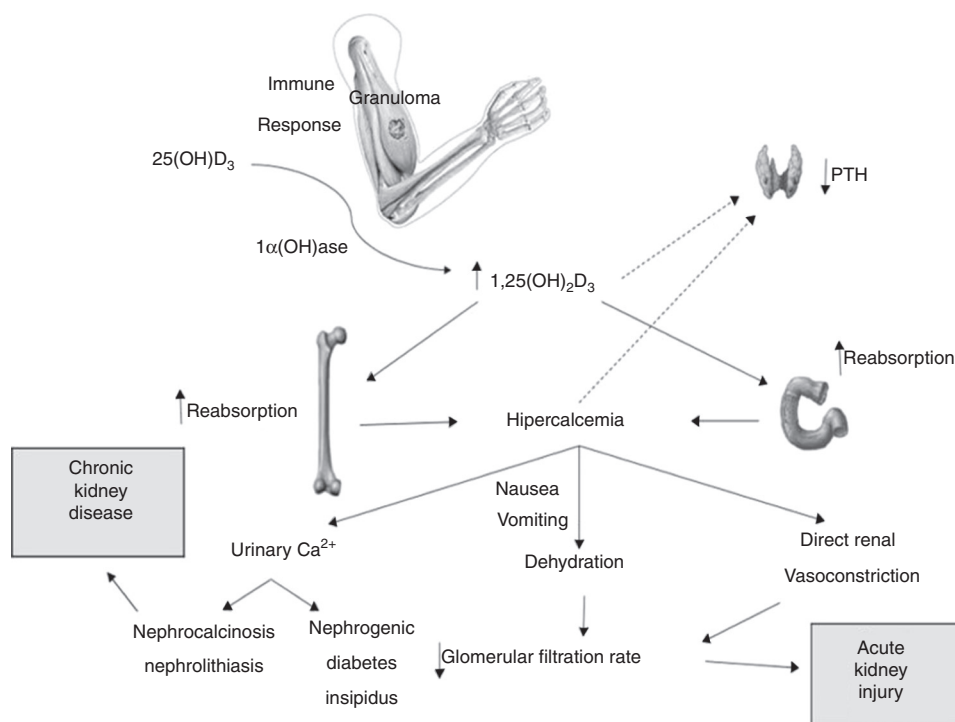


Fig. 1 – Possible mechanisms involved in the pathophysiology of kidney injury associated with hypercalcemia and injectable vitamins A, D and E supplements.

(due to antagonist effects of vitamin E against vitamin K), hypertension, angina and stroke.¹⁶ Our patients had nausea, vomiting and headache, which could be attributable to hypervitaminosis A and E, but these symptoms could also be consequence of AKI-associated uremia.

In the present case series, kidney injury ranged from relatively mild and reversible acute injury to severe disease progressing to end-stage chronic kidney failure (as observed in patient #15). Persistent hypercalcemia with serum calcium levels >11 mg/dL may in up to 20% of cases develop into nephrogenic diabetes insipidus, which usually reverts with the resolution of the hypercalcemic condition. Though not yet fully understood, the mechanism of nephrogenic diabetes insipidus possibly involves the inhibition of reabsorption of sodium chloride in the thick ascending limb of the loop of Henle (in detriment to countercurrent exchange) and of vasopressin-mediated water permeability in the terminal collecting duct.¹⁷

Hypercalcemia has been shown to downregulate aquaporin 2 protein expression in rat kidney medulla, interfering with the ability to concentrate urine.¹⁸ Calcium deposition in the medulla (a cause of tubulointerstitial injury) appears to play an important role in this process.¹⁹ The activation of calcium-sensing receptor can affect the urinary-concentrating mechanism by acting in both the loop of Henle and the collecting tubules.²⁰

Hypercalciuria secondary to hypercalcemia also leads to the deposition of calcium in the renal parenchyma, eventually causing nephrocalcinosis and irreversible damage and predisposing toward the development of chronic nephropathy. When the concentration of calcium phosphate exceeds solubility, Randall's plaques are formed in the basement membranes of the thin limbs of the loop of Henle in the inner medullary interstitium.²¹⁻²³ These calcium phosphate plaques can extend into the surrounding interstitial tissue, producing medullar nephrocalcinosis, or penetrate the urothelium where they are believed to provide a nidus for intratubular stone formation, leading to nephrolithiasis, obstructive uropathy and kidney injury.²⁴

Thus, nephropathy induced by vitamin supplement abuse can indeed lead to chronic kidney disease. This sheds light on the findings and outcome of patient #15 in our series. Unlike the other patients, #15 had low calcium and vitamin D levels and high PTH levels. Combined with anemia and the need for persistent dialysis, these findings are an indication of terminal chronic kidney injury. In the absence of other offending factors, it may be inferred that the condition of this 25-year old patient was specifically the result of vitamin supplement abuse.

Most of our patients experienced acute kidney injury, but did not develop chronic kidney disease (nephrocalcinosis or hydronephrosis). The observed kidney injury may have involved other mechanisms. Thus, serum calcium levels in excess of 12-15 mg/dL can acutely induce a reversible decrease in glomerular filtration by direct renal vasoconstriction of the arterioles and decreased extracellular fluid volume due to anorexia, vomiting and inability to concentrate urine (nephrogenic diabetes insipidus).²⁵ Vomiting was a common symptom in our patients, most likely due to hypercalcemia. In such cases, kidney function is often fully restored by early

treatment. On the other hand, non-renal function recovery or partial recovery in patients with chronic hypercalcemia with tubular degeneration, fibrosis and nephrocalcinosis are observed.²⁶

High blood pressure observed in these patients is due mainly to hypercalcemia or kidney injury. Hypercalcemia affects the vascular smooth muscle directly increasing vascular resistance, and indirectly increasing catecholamines levels. However, the impact is much stronger on renal vascular resistance than on peripheral vascular resistance.²⁷ There are also reports associating vitamin A intoxication with hypercalcemia.^{28,29} Its mechanism is still poor understood and may include up-regulation of osteoclasts by retinol metabolites.²⁹

In conclusion, excessive use of veterinary vitamin supplements that containing high doses of vitamin A, D and E is associated with AKI and prolonged use with CKD. Hypercalcemia, a common finding, appears to be a contributing factor for this outcome. The importance of this report is to alert the medical community to the ongoing and dangerous practice of vitamin and supplement abuse by young individuals.

Study limitations

As this is a descriptive study, there are some limitations. We have described a small number of patients, but this is representative of a rare complication (AKI-associated to vitamin supplements abuse), which is still not well described in literature. Some laboratory tests, such as creatine kinase (CK), to rule out rhabdomyolysis, and serum vitamin D were not available for all patients due to technical and economic problems. It was not possible to perform a powerful statistical analysis, so it was not possible to draw statistically significant associations between possible causal factors for AKI.

Conflict of interest

The authors have no conflicts of interest to disclose.

REFERENCES

1. Soler PT, Fernandes HM, Damasceno VO, Novaes JS. Vigorexia e níveis de dependência de exercício em frequentadores de academias e fisiculturistas. *Rev Bras Med Esporte*. 2013;19:343-8.
2. Figueiredo VC, Silva PRP, Trindade RS, Rose EH. Doping cosmético: a problemática das aplicações intramusculares de óleos. *Rev Bras Med Esporte*. 2011;17:56-61.
3. Belda W Jr, Carmignotto DA, Aguirre Ruiz JF. Parafinoma: a proposito de um caso. *An Bras Dermatol*. 1989;64:129-32.
4. Levey AS, Levin A, Kellum KA. Definition and classification of kidney diseases. *Am J Kidney Dis*. 2013;61:686-8.
5. Daher EF, Silva Junior GB, Queiroz AL, Ramos LM, Santos SQ, Barreto DM, et al. Acute kidney injury due to anabolic steroid and vitamin supplement abuse: report of two cases and a literature review. *Int Urol Nephrol*. 2009;41:717-23.
6. Zehnder D, Bland R, Williams MC, McNinch RW, Howie AJ, Stewart PM, et al. Extrarenal expression of

- 25-hydroxyvitamin(3)-1-hydroxylase. *J Clin Endocrinol Metab.* 2001;86:888–94.
7. Sharma OP. Hypercalcemia in granulomatous disorders: a clinical review. *Curr Opin Pulm Med.* 2000;6:442–7.
 8. Titan SM, Callas SH, Uip DE, Kalil-Filho R, Galvão PC. Acute renal failure and hypercalcemia in an athletic young man. *Clin Nephrol.* 2009;71:445–7.
 9. Loke SC, Leow MK. Calcinosis cutis with siliconomas complicated by hypercalcemia. *Endocr Pract.* 2005;11:341–5.
 10. Libório AB, Nasseralla JC, Gondim AS, Daher EF. The case: renal failure in a bodybuilder athlete. Diagnosis: nephrocalcinosis secondary to exogenous vitamin D intoxication. *Kidney Int.* 2014;85:1247–8.
 11. Moraitis AG, Hewison M, Collins M, Anaya C, Holick MF. Hypercalcemia associated with mineral oil-induced sclerosing paraffinomas. *Endocr Pract.* 2013;19:50–6.
 12. El Muayed M, Costas AA, Pick AJ. 1,25-Dihydroxyvitamin D-mediated hypercalcemia in oleogranulomatous mastitis (paraffinoma), ameliorated by glucocorticoid administration. *Endocr Pract.* 2010;16:102–6.
 13. Gyldenløve M, Rørvig S, Skov L, Hansen D. Severe hypercalcaemia, nephrocalcinosis, and multiple paraffinomas caused by paraffin oil injections in a young bodybuilder. *Lancet.* 2014;383:2098.
 14. Penniston KL, Tanumihardjo AS. The acute and chronic toxic effects of vitamin A. *Am J Clin Nutr.* 2006;83:191–201.
 15. Hammoud D, El Haddad B, Abdallah J. Hypercalcemia secondary to hypervitaminosis A in a patient with chronic renal failure. *West Indian Med J.* 2014;63:105–8.
 16. Moharana S, Moharana DN. Hypervitaminosis E. *Indian J Physiol Pharmacol.* 1999;43:407–9.
 17. Sands JM, Bichet DG. Nephrogenic diabetes insipidus. *Ann Intern Med.* 2006;144:186–94.
 18. Sands JM, Flores FX, Kato A, Baum MA, Brown EM, Ward DT, et al. Vasopressin-elicited water and urea permeabilities are altered in IMCD in hypercalcemic rats. *Am J Physiol.* 1998;274:978–85.
 19. Rosen S, Greenfeld Z, Bernheim J, Rathaus M, Podjarny E, Brezis M. Hypercalcemic nephropathy: chronic disease with predominant medullary inner stripe injury. *Kidney Int.* 1990;37:1067–75.
 20. Hebert SC. Extracellular calcium-sensing receptor: implications for calcium and magnesium handling in the kidney. *Kidney Int.* 1996;50:2129–39.
 21. Evan AP, Lingeman JE, Coe FL, Parks JH, Bledsoe SB, Shao Y, et al. Randall's plaque of patients with nephrolithiasis begins in basement membranes of thin loops of Henle. *J Clin Invest.* 2003;111:607–16.
 22. Evan A, Lingeman J, Coe FL, Worcester E. Randall's plaque: pathogenesis and role in calcium oxalate nephrolithiasis. *Kidney Int.* 2006;69:1313–8.
 23. Asplin JR, Mandel NS, Coe FL. Evidence of calcium phosphate supersaturation in the loop of Henle. *Am J Physiol.* 1996;270:604–13.
 24. Sayer JA, Carr G, Simmons NL. Nephrocalcinosis: molecular insights into calcium precipitation within the kidney. *Clin Sci (Lond).* 2004;106:549–61.
 25. Moyses-Neto M, Guimaraes FM, Ayoub FH, Vieira-Neto OM, Costa JA, Dantas M. Acute renal failure and hypercalcemia. *Ren Fail.* 2006;28:153–9.
 26. Williams PF, Thomson D, Anderton JL. Reversible renal failure due to isolated renal sarcoidosis. *Nephron.* 1984;37:246–9.
 27. Eiam-Ong S, Eiam-Ong S, Punsin P, Sitprija V, Chaiyabutr N. Acute hypercalcemia-induced hypertension: the roles of calcium channel and alpha-1 adrenergic receptor. *J Med Assoc Thai.* 2004;87:410–8.
 28. Rocha PN, Santos CS, Avila MO, Neves CL, Bahiense-Oliveira M. Hypercalcemia and acute kidney injury caused by abuse of a parenteral veterinary compound containing vitamins A, D, and E. *J Bras Nefrol.* 2011;33:467–71.
 29. Fishbane S, Frei GL, Finger M, Dressler R, Silbiger S. Hypervitaminosis A in two hemodialysis patients. *Am J Kidney Dis.* 1995;25:346–9.