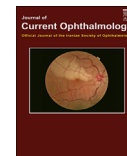

Available online at www.sciencedirect.com**ScienceDirect**

Journal of Current Ophthalmology 27 (2015) 37–40

<http://www.journals.elsevier.com/journal-of-current-ophthalmology>

Survey of 274 patients with conjunctival neoplastic lesions in Farabi Eye Hospital, Tehran 2006–2012

Fahimeh Asadi-Amoli^a, Alireza Ghanadan^{b,c,*}

^aDepartment of Pathology, Farabi Eye Hospital, Tehran University of Medical Sciences, Tehran, Iran

^bDepartment of Pathology, Razi Skin Hospital, Tehran University of Medical Sciences, Tehran, Iran

^cDepartment of Pathology, Cancer Institute, Imam Khomeini Hospital Complex, Tehran University of Medical Sciences, Tehran, Iran

Available online 31 October 2015

Abstract

Purpose: To evaluate conjunctival epithelial neoplastic lesions in a 7-year period.

Materials and methods: The data of all primary cases of conjunctival neoplasia diagnosed in the Pathology Department of Farabi Eye Hospital were analyzed.

Results: The patient group consisted of 179 (65.3%) males and 95 (34.6%) females, with an age range of 14–90 years and a mean age of 57.9 years. The most common primary conjunctival epithelial neoplastic lesion was invasive squamous cell carcinoma (SCC) (40.8%), followed by dysplasia (17%), papilloma (16.4%), in situ SCC (16%), actinic keratosis (7.3%), basal cell carcinoma (0.7%), xeroderma pigmentosum (0.7%), and mucoepidermoid carcinoma (0.3%). Of 274 lesions, 47 (17.1%) were benign, 159 (58%) were malignant, and 68 (24.8%) were precancerous. Compared to the results of a previous study of this center (1990–2004), the incidence of precancerous lesions has slightly increased whereas the incidence of SCC has decreased (22.1% vs. 24.8% and 59% vs. 40.8%, respectively).

Conclusion: SCC is the most common conjunctival epithelial neoplasm in this study, and its prevalence in males is nearly two times higher than in females. The high percentage of squamous cell carcinoma can likely be attributed to elevated sun exposure and ultraviolet light in Iran.

© 2015 Iranian Society of Ophthalmology. Production and hosting by Elsevier B.V. This is an open access article under the CC BY-NC-ND license (<http://creativecommons.org/licenses/by-nc-nd/4.0/>).

Keywords: Conjunctival epithelial neoplasm; Squamous cell carcinoma; Papilloma

Introduction

Squamous cell carcinoma of the conjunctiva (SCCC) is a rare cancer of the ocular surface with an incidence rate that varies geographically from 0.02 per 100,000 in high latitude areas to 3.5 per 100,000 at low latitudes.^{1,2} Ocular surface squamous neoplasias (OSSN), a recent term ranging from "precancerous" lesions to invasive carcinoma, comprises a wide spectrum of dysplastic alterations of the squamous epithelium of the eye surface, including conjunctival

intraepithelial neoplasia (CIN), carcinoma in situ (CIS), and SCCC.^{1,3} Among the general population in the United States, using data from the Surveillance, Epidemiology, and End Results (SEER) Program of the National Cancer Institute, the risk of SCCC was higher in males and in whites and was correlated exposure to ultraviolet radiation.¹ The etiology of the conjunctival cancers appears to be multifactorial; several etiologic factors have been identified including smoking, sun-exposure, latitude, history of pterygium, and both human immunodeficiency virus (HIV) and Human papilloma virus (HPV) infection. However, the reports on HPV and conjunctival neoplasms are controversial.⁴ OSSN grows in a flat superficial leukoplakia, velvety or papilliform, gelatinous nodular, or diffuse in an invasive fashion. These tumors may present as localized and slowly growing lesions and have

*Corresponding author. Department of Pathology, Razi Skin Hospital, Tehran University of Medical Sciences, Tehran, Iran. Tel.: +98 2155159988; fax: +98 2155155050.

E-mail address: dermpath101@gmail.com (A. Ghanadan).

Peer review under responsibility of the Iranian Society of Ophthalmology.

sometimes been associated with pinguecula and pterygia.^{5–7} In elderly patients, the tumor may be initially diagnosed as a chronic unilateral conjunctivitis or scleritis, and as chalazion if arising from the bulbar conjunctiva.⁶

In the present study, we enrolled all conjunctival epithelial tumors in Farabi Eye Hospital (Tehran, Iran) over a 7-year period and evaluated the etiologic factors and clinical and pathologic features of the most malignant tumor, SCCC.

Patients and methods

In this retrospective seven-year cross-sectional study (2006–2012), 274 patients with conjunctival epithelial tumors were enrolled through the pathology files of Farabi Eye Hospital in Tehran, Iran. The tumors were classified as benign, precancerous, and malignant. Conjunctival intraepithelial neoplasia (CIN) encompasses dysplasia and actinic keratosis that were considered precancerous lesions of the conjunctiva. Demographic data with tumor location and presentation were also obtained from all patient's medical records. A survey was prepared inquiring if patients were exposed to the sun more or less than 180 days per year over the last 10 years. An age and gender matched control group (50 patients) with lesion-free, normal conjunctival biopsies (mean age: 64.3, age p-value: 0.4, sex p-value: 0.63) were selected from the archive of the Pathology Department of Farabi Eye Hospital.

Statistical analysis

The results are expressed as mean ± SD. Statistical analysis was performed using SPSS version 16.0.1 (SPSS Inc., Chicago, IL, U.S.A.). The statistical differences between proportions were determined by χ^2 analysis. Numerical data were evaluated using analysis of variance, followed by Tukey's post hoc test. P value < 0.05 was considered significant.

Results

Demographic data

Among all conjunctival specimens which were addressed to the pathology department of Farabi Eye Hospital between 2006 to 2012, 274 patients (171 male and 103 female with a mean age of 57.9 years ranged from 14 to 90 years) were enrolled in this cross-sectional study. The mean age of the patients with malignant tumors was 62.1 years (range, 16–90 years), and the majority of patients were in their eighties (48 cases, 30.2%). About half of the conjunctival epithelial tumors (48.2%) were manifested in ages over 60 years. Among 274 tumors, 159 (58%) were malignant, 68 (24.8%) were precancerous, and 47 (17.1%) were benign. There was no association between gender and the type of the lesions (p > 0.05). Age stratification and frequency of benign, precancerous, and malignant epithelial tumors of the conjunctiva are denoted in Fig. 1. Compared to a previous study⁸ from this center conducted during 1990–2004, the incidence of precancerous conjunctival lesions slightly increased (22.1%–24.8%) whereas the incidence of SCC decreased (59%–40.8%). Characteristics of the tumors in comparison to the control group and previous studies are summarized in Tables 1 and 2.

Clinical data

The most frequent clinical findings and symptoms among malignant tumors were gelatinous mass (41.5%), followed by leukoplakia (24.5%), nodular mass (21.4%), pigmented lesions (8.2%), chronic conjunctivitis (3.1%), and blurred vision (1.3%). Among 274 patients, 126 (45.9%) of the lesions were on the bulbar conjunctiva, 122 (44.5%) on the limbal conjunctiva, 22 (8%) on the palpebral conjunctiva, and 4 (1.4%) on the fornix. Limbal and bulbar conjunctivas were the most frequent sites for benign and malignant tumors, respectively. No statistically significant difference was found among different anatomic sites in benign and malignant tumors (Table 3).

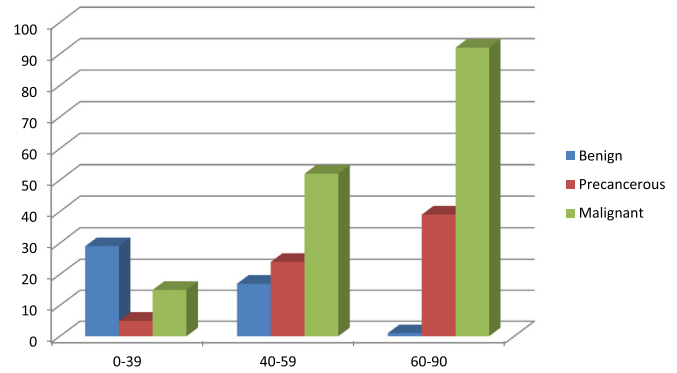


Fig. 1. Age stratification and frequency of 247 conjunctival epithelial neoplasms.

Etiology and associated conditions

To define the etiologic effect of UV light on conjunctival epithelial tumors, we compared 50 age- and gender-matched control patients in the matter of the sun-exposure days per year with a cut-off point of 180 days/year. Our data revealed a significant association between the duration of sun exposure and the lesions with more than 180 days/year exposed to sun were more likely to be malignant than lesions with less than 180 days/year (p < 0.001). Malignant tumors had a significant association with sun exposure of more than 180 days/year in comparison to benign tumors (p < 0.001). Precancerous lesions had been also exposed to sun light more than 180 days/year (Table 1). Intraepithelial neoplasia including dysplasia and actinic keratosis were accompanied with malignant tumors, in which 107 (67.3%) cases of malignant tumors were associated with them. History of actinic changes and pterygium was present in 101 (63.5%) of malignant tumors.

Discussion

In our study, malignant epithelial tumors of the conjunctiva were more common than benign tumors, which may be due to the fact that Farabi Eye Hospital is a referral center for eye diseases, and more complicated cases are referred to this center. At the same time, this is a large series of benign, precancerous, and malignant epithelial tumors of the conjunctiva in Iran. In our previous report, it was suggested to consider patient age as a predictive factor of malignancy while evaluating conjunctival neoplasms.⁸ Compared to previous study in this center, the incidence of precancerous lesions, such as dysplasia and actinic keratosis, increased whereas the incidence of SCCC decreased. This fact may be a result of

Table 1
Characteristic of 274 conjunctival epithelial tumors in comparison to control group in Farabi Eye Hospital, Tehran, Iran.

Characteristic	N (%)	Benign	IEN ^a	Malignant	Control group
Sex					
Male	171 (62.4)	28	45	98	29
Female	103 (37.6)	19	23	61	21
Sun-exposure (days/year)					
< 180	133 (48.5)	32	41	60	20
> 180	141 (51.5)	15	27	99	30

^aIEN, intraepithelial neoplasia.

Table 2
Pathology classification in 274 conjunctival epithelial tumors in Farabi Eye Hospital, Tehran, Iran.

Histopathologic classification	M/F	This study (%) 2006–2012	Previous study (%) ^a 1990–2004
Benign	28/19	47 (17.1)	35 (18.4)
Papilloma	26/19	45 (16.4)	35 (18.4)
XP	2/0	2 (0.7)	–
IEN	45/23	68 (24.8)	42 (22.1)
Dysplasia	33/15	48 (17.5)	25 (13.2)
Actinic keratosis	12/8	20 (7.3)	17 (8.9)
Malignant	98/61	159 (58)	113 (59.5)
Invasive SCC	69/43	112 (40.8)	112 (59)
In situ SCC	27/17	44 (16)	–
BCC	1/1	2 (0.7)	–
MEC	1/0	1 (0.3)	1 (0.5)
Total	171/103	274 (100)	190 (100)

BCC, basal cell carcinoma; IEN, intraepithelial neoplasia; MEC, mucoepidermoid carcinoma, SCC, squamous cell carcinoma; XP, Xeroderma pigmentosum.

^aRef.⁸.

Table 3
Anatomic sites in benign, precancerous, and malignant epithelial tumors of the conjunctiva.

Anatomic site	Benign tumors N (%)	IEN N (%)	Malignant tumors N (%)	Total N (%)
BC	18 (38.3)	32 (47)	76 (47.8)	126 (45.9)
LC	23 (49)	29 (42.6)	70 (44)	122 (44.5)
PC	5 (10.6)	7 (10.2)	10 (6.3)	22 (8)
F	1 (2.1)	0 (0)	3 (1.9)	4 (1.4)
Total	47 (17.1)	68 (24.8)	159 (58)	274 (100)

BC, bulbar conjunctiva; F, fornix; IEN, intraepithelial neoplasia; LC, limbal conjunctiva; PC, palpebral conjunctiva.

earlier detection and better management of patients in this center.

Ocular surface squamous neoplasia is more common in countries with high exposure to sunlight. In line of this fact, the interpalpebral zone, the part of the conjunctiva heavily exposed to the ultraviolet light is the most prevalent site of the malignancy.^{6,9,10,11} Malignant epithelial tumors are more common in men than in women because men spend more time outdoors and are exposed to sunlight more. However, in a study in Zimbabwe, 70% of the patients with OSSN were female due to their involvement in agriculture and harvesting in farms, which led to high sun exposure.¹²

Regarding exposure time, malignant tumors in our presentation had a significant association with the sun exposure being more than 180 days/year in comparison to benign tumors (p -value < 0.001). Precancerous lesions are also correlated with sun exposure of more than 180 days/year, devoid of significant association. Actinic changes/pterygium and conjunctival intraepithelial neoplasia (CIN), which were present in 63.5% and 67.3% of squamous carcinoma, respectively, may be

attributed to the intensity and duration of sunlight exposure in our country. This strong association confirms the role of direct sun-exposure in etiology of actinic changes and epithelial neoplasia of the conjunctiva. Other studies have also confirmed that OSSN is associated with pinguecula, pterygium, and CIN.^{5–7,13–15} Usually, these lesions arise within interpalpebral fissure, mostly at the limbus, although they may be found in any part of the conjunctiva and cornea.³

Recently, human papilloma virus (HPV), mainly type 16, has been detected in tissue specimens of OSSN. Our previous study on 50 cases of SCCC showed that HPV is strongly associated with SCCC in comparison to all normal conjunctival biopsy specimens.¹⁶ Ateenyi-Agaba et al.'s study supports the hypothesis that cutaneous, but not mucosal subtypes of HPV, may be involved in the etiology of this rare malignancy and its precursor lesions.^{17–19} There are marked variations in the reported HPV prevalence rates in conjunctival carcinoma, ranging from 0% to 100%.^{20–30} Whereas some studies have reported highest incidence of HPV,^{21,24} others have shown no evidence of HPV infection in OSSN lesions.^{20,25–34} These discrepancies show the more important role of UV exposure in OSSN development than HPV infection.^{35,36}

In conclusion, the high percentage of squamous cell carcinoma can likely be attributed to geographical latitude and greater sun exposure. The characterization of precancerous lesions in this study emphasizes their potential to transform into malignant lesions and the need for sufficient early management and follow-up. The incidence of precancerous lesions and SCC compared to a previous study increased and decreased, respectively, suggesting earlier detection and better management of OSSN in this eye center.

Acknowledgment

This study was supported by a grant from the Deputy for Research of Tehran University of Medical Sciences, Tehran, Iran (Grant 20915).

References

- Alves LF, Fernandes BF, Burnier, JV, et al. Incidence of epithelial lesions of the conjunctiva in a review of 12,102 specimens in Canada (Quebec). *Arq Bras Ophthalmol* 2011 Jan–Feb;74:21–23.
- Emmanuel B, Ruder E, Lin, SW, et al. Incidence of squamous-cell carcinoma of the conjunctiva and other eye cancers in the NIH-AARP Diet and Health Study. *Ecancermedicalscience* 2012;6:254.
- Pe'er J. Ocular surface squamous neoplasia. *Ophthalmol Clin North Am* 2005 Mar;18:1–13. vii. review.
- Peralta R, Valdivia A, Estañol, P, et al. Low frequency of human papillomavirus infection in conjunctival squamous cell carcinoma of Mexican patients. *Infect Agent Cancer* 2011;18:24.
- Ni C, Searl SS, Kriegstein HJ, Wu BF. Epibulbar carcinoma. *Int Ophthalmol Clin* 1982;22:1–33.
- Tunc M, Char DH, Crawford, B, et al. Intraepithelial and invasive squamous cell carcinoma of the conjunctiva: analysis of 60 cases. *Br J Ophthalmol* 1999;83:98–103.
- Lee GA, Hirst LW. Ocular surface squamous neoplasia. *Surv Ophthalmol* 1995;39:429–450.

8. Amoli FA, Heidari AB. Survey of 447 patients with conjunctival neoplastic lesions in Farabi Eye Hospital, Tehran, Iran. *Ophthalmic Epidemiol* 2006;13:275–279.
9. McDonnell JM, McDonnell PJ, Mounts, P, et al. Demonstration of papillomavirus capsid Pe'er 8 antigen in human conjunctival neoplasia. *Arch Ophthalmol* 1986;104:1801–1805.
10. Guech-Ongey M, Engels EA, Goedert, JJ, et al. Elevated risk for squamous cell carcinoma of the conjunctiva among adults with AIDS in the United States. *Int J Cancer* 2008;122:2590–2593.
11. Lee GA, Hirst LW. Incidence of ocular surface dysplasia in metropolitan Brisbane. A ten year survey. *Arch Ophthalmol* 1992;110:525–527.
12. Pola EC, Masanganise R, Rusakaniko S. The trend of ocular surface squamous neoplasia among ocular surface tumour biopsies submitted for histology from Sekuru Kaguvi Eye Unit, Harare between 1996 and 2000. *Cent Afr J Med* 2003;49:1–4.
13. Degrassi M, Piantanida A, Nucci P. Unexpected histological findings in pterygium. *Optom Vis Sci* 1993;70:1058–1060.
14. Clear AS, Chirambo MC, Hutt MS. Solar keratosis, pterygium, and squamous cell carcinoma of the conjunctiva in Malawi. *Br J Ophthalmol* 1979;63:102–109.
15. Seregard S, Kock E. Squamous spindle cell carcinoma of the conjunctiva: fatal outcome of pterygium-like lesion. *Acta Ophthalmol Scand* 1995;73:464–466.
16. Asadi-Amoli F, Heidari AB, Jahanzad, I, et al. Detection of human papillomavirus in squamous cell carcinoma of conjunctiva by nested PCR: a case control study in Iran. *Acta Med Iran* 2011;49:707–714.
17. Ateenyi-Agaba C, Franceschi S, Wabwire-Mangen, F, et al. Human papillomavirus infection and squamous cell carcinoma of the conjunctiva. *Br J Cancer* 2010;102:262–267.
18. Ateenyi-Agaba C, Weiderpass E, Smet, A, et al. Epidermodysplasia verruciformis human papillomavirus types and carcinoma of the conjunctiva: a pilot study. *Br J Cancer* 2004;90:1772–1779.
19. de Koning MN, Waddell K, Magyezi, J, et al. Genital and cutaneous human papillomavirus (HPV) types in relation to conjunctival squamous-cell neoplasia: a case – control study in Uganda. *Infect Agent Cancer* 2008;3:12.
20. McDonnell JM, Mayr AJ, Martin WJ. DNA of human papillomavirus type 16 in dysplastic and malignant lesions of the conjunctiva and cornea. *N Engl J Med* 1989;320:1442–1446.
21. Lauer SA, Malter JS, Meier JR. Human papillomavirus type 18 in conjunctival intraepithelial neoplasia. *Am J Ophthalmol* 1990;110:23–27.
22. McDonnell JM, Wagner D, Ng, ST, et al. Human papillomavirus type 16 DNA in ocular and cervical swabs of women with genital tract condylomata. *Am J Ophthalmol* 1991;112:61–66.
23. Odrich MG, Jakobiec FA, Lancaster, WD, et al. A spectrum of bilateral squamous conjunctival tumors associated with human papillomavirus type 16. *Ophthalmology* 1991;98:628–635.
24. Tuppurainen K, Raninen A, Kosunen, O, et al. Squamous cell carcinoma of the conjunctiva. Failure to demonstrate HPV DNA by in situ hybridization and polymerase chain reaction. *Acta Ophthalmol (Copenh)* 1992;70:248–254.
25. McDonnell JM, McDonnell PJ, Sun YY. Human papillomavirus DNA in tissues and ocular surface swabs of patients with conjunctival epithelial neoplasia. *Invest Ophthalmol Vis Sci* 1992;33:184–189.
26. Saegusa M, Takano Y, Hashimura, M, et al. HPV type 16 in conjunctival and junctional papilloma, dysplasia, and squamous cell carcinoma. *J Clin Pathol* 1995;48:1106–1110.
27. Lewallen S, Shroyer KR, Keyser, RB, et al. Aggressive conjunctival squamous cell carcinoma in three young Africans. *Arch Ophthalmol* 1996;114:215–218.
28. Nakamura Y, Mashima Y, Kameyama, K, et al. Detection of human papillomavirus infection in squamous tumors of conjunctiva and lacrimal sac by immunohistochemistry, in situ hybridisation, and polymerase chain reaction. *Br J Ophthalmol* 1997;81:308–313.
29. Tabrizi SN, McCurrach FE, Drewe, RH, et al. Human papillomavirus in corneal and conjunctival carcinoma. *Aust N Z J Ophthalmol* 1997;25:211–215.
30. Karcioğlu ZA, Issa TM. Human papilloma virus in neoplastic and non-neoplastic conditions of the external eye. *Br J Ophthalmol* 1997;81:595–598.
31. McDonnell PJ, McDonnell JM, Kessis, T, et al. Detection of human papillomavirus type 6/11 DNA in conjunctival papillomas by in situ hybridization with radioactive probes. *Hum Pathol* 1987;18:1115–1119.
32. Dushku N, Hatcher SL, Albert DM, Reid TW. p53 expression and relation to human papillomavirus infection in pingueculae, pterygia, and limbal tumors. *Arch Ophthalmol* 1999;117:1593–1599.
33. Toth J, Karcioğlu ZA, Moshfeghi, AA, et al. The relationship between human papillomavirus and p53 gene in conjunctival squamous cell carcinoma. *Cornea* 2000;19:159–162.
34. Waddell K, Magyezi J, Boursarghin, L, et al. Antibodies against human papillomavirus type 16 (HPV-16) and conjunctival squamous cell neoplasia in Uganda. *Br J Cancer* 2003;88:2002–2003.
35. Eng HL, Lin TM, Chen, SY, et al. Failure to detect human papillomavirus DNA in malignant epithelial neoplasia of conjunctiva by polymerase chain reaction. *Am J Clin Pathol* 2002;117:429–436.
36. Verma V, Shen D, Sieving, PC, et al. The role of infectious agents in the etiology of ocular adnexal neoplasia. *Surv Ophthalmol* 2008;53:312–331.