



Anatomical and magnetic resonance imaging study of the medial collateral ligament of the ankle joint



Sally Mahmood Mohamed Hussin Omar ^a, Fardos Ahmed El-Kalaa ^a,
El Sebai Farag Ali ^b, Ali Ali Abd El-Karim ^c, Nancy Mohamed El Sekily ^{d,*}

^a Department of Anatomy and Embryology, Faculty of Medicine, University of Alexandria, Egypt

^b Department of Orthopaedic Surgery and Traumatology, Faculty of Medicine, University of Alexandria, Egypt

^c Department of Radiodiagnosis, Faculty of Medicine, University of Alexandria, Egypt

^d Department of Anatomy and Embryology, Faculty of Medicine, Alexandria University, Egypt

Received 25 November 2014; accepted 30 April 2015

Available online 10 July 2015

KEYWORDS

Medial collateral ligament;
MRI;
Ankle joint;
Disrupted ligament

Abstract *Introduction:* The medial collateral ligament of the ankle joint also known as the deltoid ligament, is a multifascicular group of ligaments. It can be divided into a superficial and deep group of fibers originating from the medial malleolus to insert in the talus, calcaneus, and navicular bones. Wide variations have been noted in the anatomical description of the medial ligamentous complex of the ankle. The various components of the deltoid ligament are well visualized on both axial and coronal images on routine ankle MR imaging sequences including T1 weighted image and T2 weighted image.

Aim: This study was done to study the anatomy of the normal and variated attachment of the medial collateral ligament of the ankle joint, and also to study the MR imaging of the normal, variated and disrupted attachment of the medial collateral ligament.

Materials and methods: Twenty preserved cadaveric adult ankle specimens were collected from the dissecting room, Anatomy Department, Faculty of Medicine, Alexandria University. MR imaging of ten ankles was performed before and after disruption of every band of the ligament of medial side of the ankle.

Results: The medial collateral ligament of the ankle was found to consist of six bands or components, three of them are always present whereas the presence of the other three may vary. The exact attachments and measurements of these bands were described.

Axial imaging provided optimum views of the deep layers of the medial collateral ligament and the tibionavicular ligament. Coronal imaging allowed complete visualization of the tibio-calcaneal, and

* Corresponding author at: Anatomy Department, Faculty of Medicine, Alexandria University, Egypt.

E-mail address: nancyelsekily@yahoo.com (N.M. El Sekily).

Peer review under responsibility of Alexandria University Faculty of Medicine.

<http://dx.doi.org/10.1016/j.ajme.2015.04.003>

2090-5068 © 2015 The Authors. Alexandria University Faculty of Medicine. Production and hosting by Elsevier B.V.

This is an open access article under the CC BY-NC-ND license (<http://creativecommons.org/licenses/by-nc-nd/4.0/>).

deep posterior tibiotalar ligaments. High resolution MR imaging allows excellent visualization of the collateral ligaments of the ankle.

Conclusion: The study of the anatomy of the ankle joint, its collateral ligaments and their functions aid for the proper diagnosis and treatment of the conditions affecting the ankle.

© 2015 The Authors. Alexandria University Faculty of Medicine. Production and hosting by Elsevier B.V. This is an open access article under the CC BY-NC-ND license (<http://creativecommons.org/licenses/by-nc-nd/4.0/>).

1. Introduction

The ligaments of the ankle hold the ankle bones and joint in position and they protect the ankle joint from abnormal movements – especially twisting of the foot.¹

The medial collateral ligament of the ankle joint also known as the deltoid ligament, is a multifascicular group of ligaments.² The deltoid ligament is a strong restraint that limits talar abduction and pronation.³

It can be divided into a superficial and deep group of fibers originating from the medial malleolus to insert in the talus, calcaneus, and navicular bones.⁴

Wide variations have been noted in the anatomical description of the medial ligamentous complex of the ankle. The medial ligamentous complex is multibanded and it can be considered as having superficial and deep components^{4,5}; the tibiocalcaneal ligament constitutes the superficial layer of the deltoid ligament that spans the medial malleolus to the medial aspect of the calcaneus. The other three divisions, the anterior tibiotalar, intermediate tibiotalar ligament, and posterior tibiotalar ligament, they attach the medial malleolus to the talus. Although the tibiocalcaneal ligament is extremely thin and supports only negligible forces before failing, the tibiotalar ligaments are strong. Six bands or component have been described for the medial collateral ligaments. Four components were superficial (tibiospring, tibionavicular, superficial posterior tibiotalar, and tibiocalcaneal ligaments) of which only the tibiospring and tibionavicular ligaments were constant. Two bands were deep (deep posterior tibiotalar and deep anterior tibiotalar ligaments), of which the deep posterior tibiotalar ligament was constant.⁵

Because the tibioligamentous portion of the superficial deltoid has a broad insertion on the spring ligament, this ligament complex may interplay with the deltoid ligament in the stabilization of the medial ankle joint, and thus functionally cannot be separated from it. The tendon sheath of the posterior tibial muscle covers the posterior and middle part of the deltoid ligament.^{5,6}

Medial instability is suspected on the basis of patient's feeling that his/her ankle is "giving – way" especially medially, when walking on ground or on downstairs, pain at the antero-medial aspect of the ankle, and sometimes pain on the lateral aspect of the ankle, especially during dorsiflexion of the foot.⁷ Injuries to the medial side of the ankle and foot in the athlete can involve several different structures, abnormalities, and grades of injury. The tibialis posterior tendon (TPT), the spring and deltoid ligament complexes combine to provide dynamic and passive stabilization on the medial side of the ankle and hindfoot.⁸

Diagnosis of the medial ankle instability depends on patient's history of having sustained eversion trauma (i.e., outward rotation of the foot during simultaneous inward rotation of the tibia).⁷

Magnetic resonance (MR) imaging plays an important role in the diagnosis and treatment of many musculoskeletal diseases of the ankle and foot. It demonstrates the abnormalities of the bones and soft tissues before they become evident at other imaging modalities. Being noninvasive and has multi-planer capabilities making it valuable for the detection and assessment of a variety of soft tissue disorders especially the ligament (e.g., Sprain), MR imaging is increasingly being recognized as a modality of choice for the assessment of pathologic conditions of the ankle and foot.^{9,10}

Routine ankle MR imaging sequences including T1 weighted image and T2 weighted image are performed in the axial and coronal planes. The foot is imaged in the axial plane (parallel to the long axis of the metatarsal bones) and coronal plane (perpendicular to the long axis of the metatarsals).¹⁰

In general the ligaments are readily identified as thin, linear and low signal intensity structures joining adjacent bones. The various components of the deltoid ligament are well visualized on both axial and coronal images. The deep tibiotalar component of the deltoid ligament normally demonstrates regular striations and thus has a heterogeneous appearance.¹¹

The injured ligament is frequently thickened and heterogeneous. Injuries to the tibiotalar component of the deltoid ligament manifest as loss of the regular striations that are normally seen in the ligament.^{11,12}

The Aim was to study the anatomy of the normal and varied attachment of the medial collateral ligament of the ankle joint, and also to study the MR imaging of the normal, varied and disrupted attachment of the medial collateral ligament.

2. Materials and methods

Twenty preserved cadaveric adult ankle specimens were collected from the dissecting room, Anatomy Department, Faculty of Medicine, Alexandria University.

Twenty human preserved ankle specimens were subjected to dissection and ten ankle specimens were subjected to MRI imaging to demonstrate anatomical and disrupted attachment of the medial collateral ligament of the ankle.

2.1. Anatomical study

This was carried out on twenty ankles from ten adult cadavers.

Each ankle was placed on the dissecting table in supine position. Three cutaneous incisions were prepared as follows: an upper semicircular incision just 0.5 cm above the ankle anteriorly, a posterior incision 1.5 cm away from the posterior aspect of the Achilles tendon and a lower longitudinal incision joining the upper and posterior incisions. The flap consisting of the skin and subcutaneous tissue was reflected upward and medially. A thin layer of adipose tissue was removed to expose the underlying tendons, ligaments and bones. The underlying

structures and the medial aspect of the ankle were identified. Care was taken to preserve the anatomical relation of each structure. The rest of the long tendons crossing the ankle were preserved. The medial aspect of the capsule of the ankle joint was seen partly at a deeper plane. The cutaneous branches of the common peroneal and tibial nerves were identified but were cut at the different stages of dissection.

- (a) Exposure of the medial collateral ligament of the ankle joint occurs by removal of the tendon of flexor digitorum longus and the tendon of tibialis posterior muscle.
- (b) All anatomical variations found were recorded.
- (c) The length and width of each ligament were measured in millimeters in neutral, dorsiflexion and plantarflexion positions using Vernier Swiss caliber.

2.2. MRI study

This was carried on ten ankles from five adult cadavers. The specimens were cut through the distal portion of the tibia and fibula to allow the preservation of the tibiofibular syndesmosis. The examination is performed using 0.5 T units

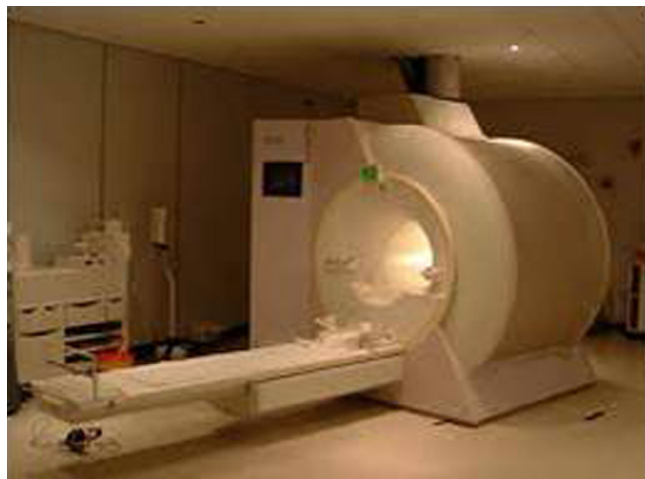

Figure 1 A photograph of open MRI machine.

Siemens Magnetom (Erlangen, Germany) open MRI machine (Fig. 1).

The specimens are supine with the foot in the position of dorsiflexion so that the dorsal aspect of foot is perpendicular to the examination couch. The specimens are positioned so that the longitudinal alignment light lies in the midline and the horizontal alignment light passes through the level of the malleoli. Standard spin-echo (SE) pulse sequences are usually adequate for anatomical identification of the ligaments. MR imaging sequences including T1 weighted image and T2 weighted image were performed in the axial (parallel to the long axis of the metatarsal bones) and coronal planes (perpendicular to the long axis of the metatarsals) (Fig. 2) before and after cutting every band of the ligament.

The imaging parameters for the 0.5 T Siemens Magnetom machine were as follows: 4 mm section thickness, 0.4 mm intersection gap, 256 × 192 acquisition matrix and 12–16 cm field of view.

- T1-weighted spin echo
TR 600 ms
TE 20 ms
- T2-weighted spin echo
TR 4000
TE 120

MRI was analyzed by an expert musculoskeletal radiologist.

3. Results

3.1. Anatomical results

3.1.1. Gross morphology and attachment

The medial collateral ligament (MCL) is a multibanded ligament, originating from the medial malleolus to insert in the navicular bone, spring ligament (plantar calcaneonavicular ligament) and calcaneal bone (Fig. 3).

Three constant bands are present arranged anteroposteriorly: tibionavicular ligament (Fig. 4), tibiospring ligament (Figs. 5 and 6), and deep posterior tibiotalar ligament (Fig. 7).

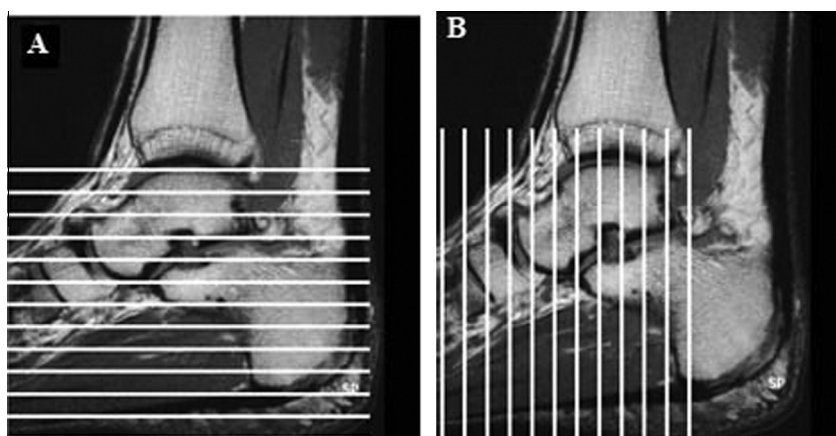


Figure 2 Right ankle joint shows both axial plane view (A) (horizontal lines) (parallel to the long axis of the metatarsal bones) and coronal plane view (B) (longitudinal lines) (perpendicular to the long axis of the metatarsals).

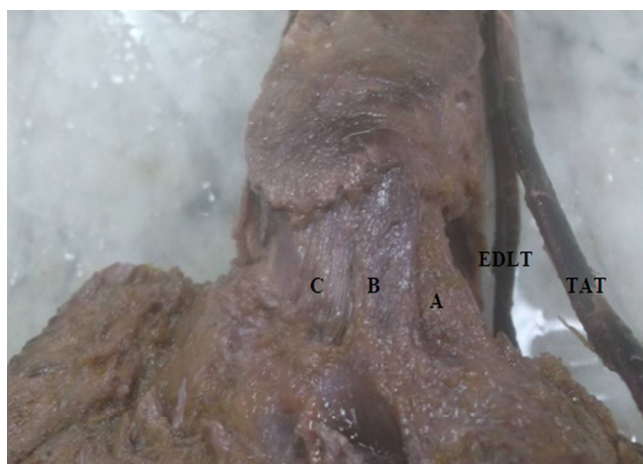

Figure 3 A photograph of the medial aspect of the left ankle joint shows three bands of the deltoid ligament arranged antero-posteriorly: (A) Tibionavicular ligament. (B) Tibiospring ligament. (C) Tibiocalcaneal ligament. EDLT: Extensor digitorum longus muscle. TAT: Tibialis anterior tendon.

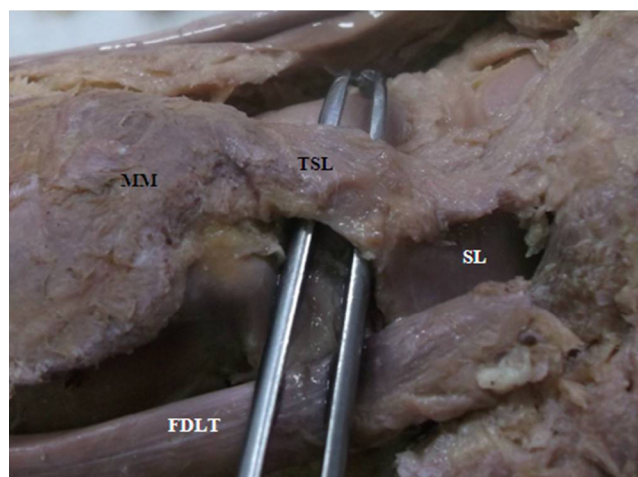


Figure 5 A photograph of anteromedial aspect of the left ankle joint shows the tibiospring part of the deltoid ligament (TSL) extending almost perpendicularly from the medial malleolus (MM) to the superior border of the plantar calcaneonavicular ligament (Spring ligament) (SL). FDLT: Flexor digitorum longus tendon.

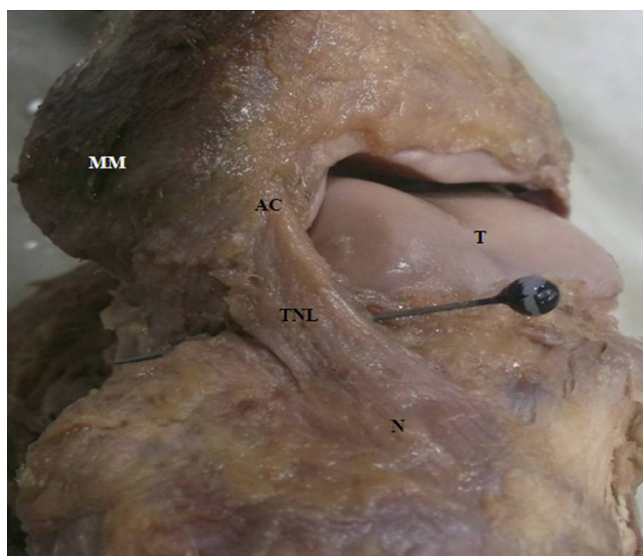

Figure 4 A photograph of anteromedial aspect of the left ankle joint shows the tibionavicular part of the deltoid ligament (TNL) originating from the anterior border of the anterior colliculus (AC) and inserts into the dorsomedial aspect of the navicular bone (N). MM: Medial malleolus. T: Talus.

The tibionavicular part of the deltoid ligament originating from the anterior border of the anterior colliculus and inserts into the dorsomedial aspect of the navicular bone (Fig. 4).

The tibiospring part of the deltoid ligament extending almost perpendicularly from the medial malleolus to the superior border of the plantar calcaneonavicular ligament (Figs. 5 and 6).

The deep posterior tibiotalar part of the deltoid ligament originating from the intercollicular groove to insert

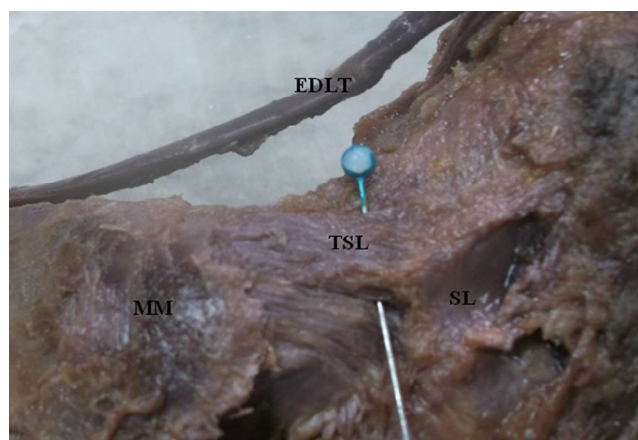


Figure 6 A photograph of anteromedial aspect of the left ankle joint shows the tibiospring part of the deltoid ligament (TSL) extending almost perpendicularly from the medial malleolus (MM) to the superior border of the plantar calcaneonavicular ligament (Spring ligament) (SL). EDLT: Extensor digitorum longus tendon.

into the medial surface of the talus under the articular facet (Fig. 7).

The tibiocalcaneal ligament was found in 50% (10 ankles). This ligament originating from the medial surface of the anterior colliculus and inserts into the medial border of the sustentaculum tali (Fig. 8).

3.1.2. Length and width dimensions of the MCL

Length and width dimensions of the MCL are summarized in the following table (Table 1) (Fig. 9).

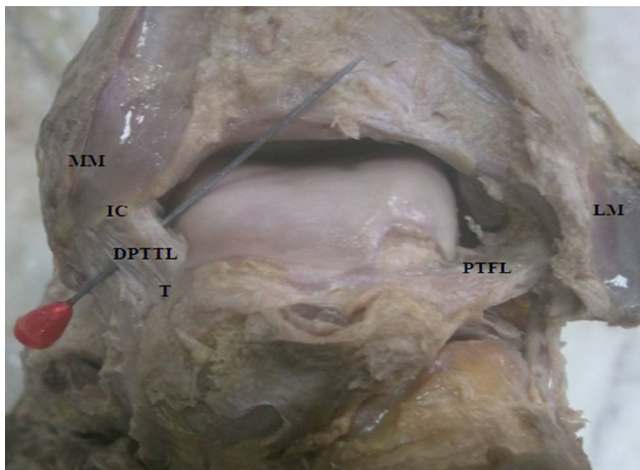


Figure 7 A photograph of posterior view of the right ankle joint shows the deep posterior tibiotalar part of the deltoid ligament (DPTTL) originating from the intercollicular groove (IC) to insert into the medial surface of the talus (T). LM: Lateral malleolus. MM: Medial malleolus. PTFL: Posterior talofibular ligament.

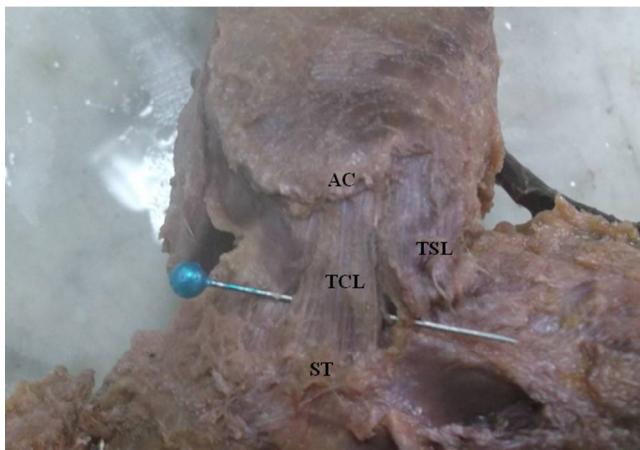


Figure 8 A photograph of anteromedial aspect of the left ankle joint shows the tibio calcaneal part of the deltoid ligament (TCL) originating from the medial surface of the anterior colliculus (AC) and inserts into the medial border of the sustentaculum tali (ST). TSL: Tibiospring ligament.

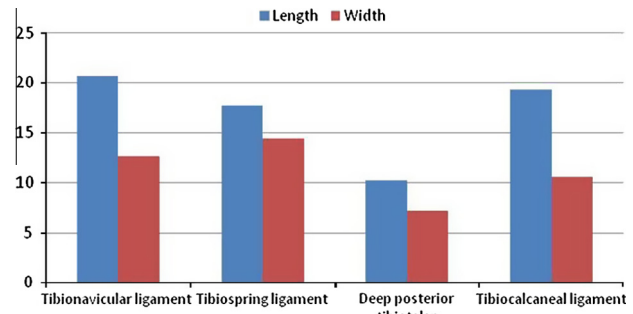


Figure 9 Histogram of length and width dimensions of the different parts of medial collateral ligament.

3.1.3. Apparent change of the MCL

There was no apparent change in length or width of the ligament when the ankle was placed into dorsiflexion or plantarflexion.

3.1.4. Attachment points of the MCL from anterior to posterior: (Table 2)

1. Tibionavicular ligament:

The average dimensions of the tibial and navicular attachment areas were 8.7 ± 1.5 mm and 6.7 ± 1.14 mm in order.

2. Tibiospring ligament:

The average dimensions of the tibia and spring ligament attachment areas were 7 ± 1.7 mm and 12.4 ± 1.5 mm in order.

3. Deep posterior tibiotalar ligament:

The average dimensions of the tibial and talar attachment areas were 6.5 ± 1.06 mm and 8 ± 1.4 mm in order.

4. Tibio calcaneal ligament:

The average dimensions of the tibial and calcaneal attachment areas were 9 ± 2.21 mm and 7.6 ± 1.3 mm in order.

3.2. MR imaging results of the normal medial collateral ligament

The MR imaging data were obtained by imaging of ten post mortem ankles from five adult cadavers.

3.2.1. Axial plane

The deep posterior tibiotalar ligament appears as thick, inhomogeneous band with broad attachment to the medial surface of the talus (Figs. 10 and 11). The tibionavicular ligament was well visualized as a thin homogeneous band of low signal intensity that inserted on the navicular bone (Figs. 12 and 13).

Table 1 Length and width dimensions of the MCL.

Bands of the MCL	Length (mm)		Width (mm)	
	Mean ± S.D.	Range	Mean ± S.D.	Range
Tibionavicular ligament	20.7 ± 2.716	15–24	12.7 ± 1.863	10–15
Tibiospring ligament	17.8 ± 2.280	15–21	14.5 ± 1.137	13–16
Deep posterior tibiotalar	10.3 ± 2.083	7–13	7.2 ± 0.829	6–8.4
Tibio calcaneal ligament	19.3 ± 2.103	16–22	10.6 ± 0.824	9.3–12

Table 2 Attachment points of the MCL from anterior to posterior.

Bands	Attachment area(mm)				
	Tibia	Navicular	Spring ligament	Talus	Calcaneus
Tibionavicular ligament	8.7 ± 1.5	6.7 ± 1.14	–	–	–
Tibiospring ligament	7 ± 1.7	–	12.4 ± 1.5	–	–
Deep posterior tibiotalar ligament	6.5 ± 1.06	–	–	8 ± 1.4	–
Tibiocalcaneal ligament	9 ± 2.21	–	–	–	7.6 ± 1.3

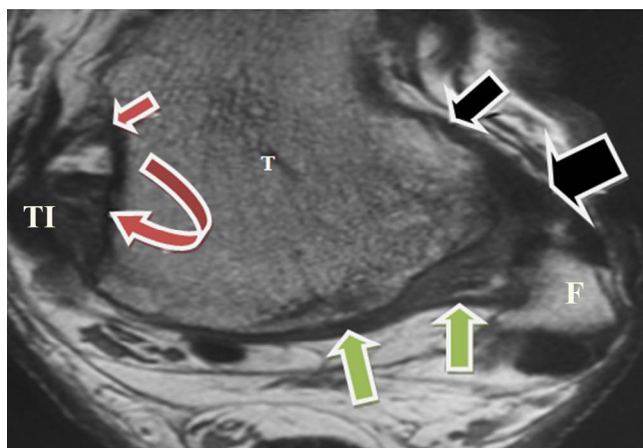


Figure 10 MR image (axial section) through the right ankle of a cadaver shows the deep posterior tibiotalar ligament (DPTTL) (red arrows) appears as a thick, inhomogeneous band with broad attachment to the medial surface of the talus (T). Black arrows: anterior talofibular ligament. Green arrows: The posterior talofibular ligament. F: Fibula. TI: Tibia.

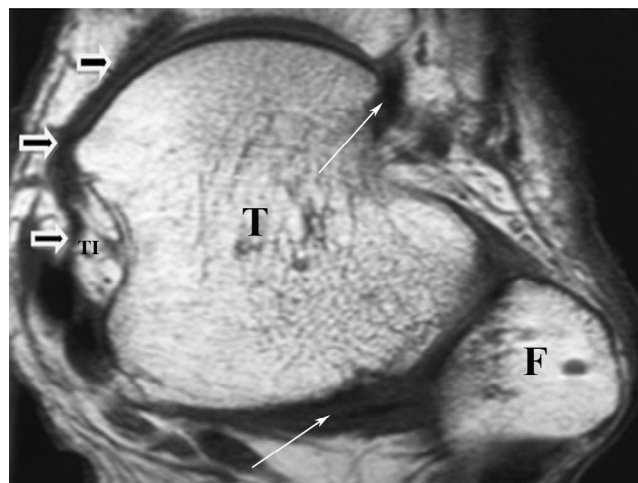


Figure 12 MR image (axial section) through the right ankle of a cadaver shows the tibionavicular ligament (TNL) visualized as a thin homogeneous band of low signal intensity that inserted on the navicular bone (black arrows). White arrow: posterior talofibular ligament. T: Talus. F: Fibula. TI: Tibia.

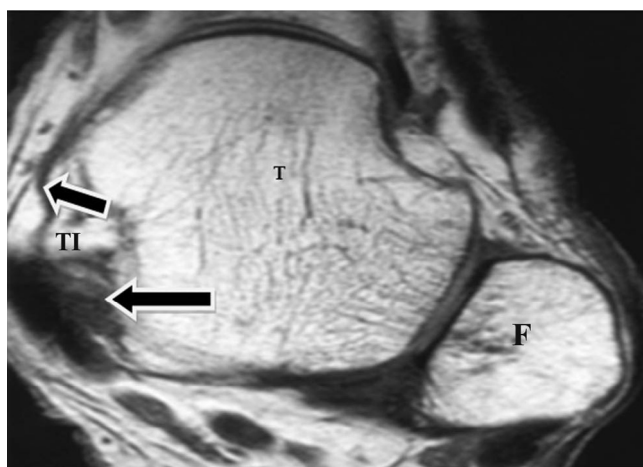


Figure 11 MR image (axial section) through the right ankle of a cadaver shows the deep posterior tibiotalar ligament (DPTTL) (Black arrows) appears as a thick, inhomogeneous band with broad attachment to the medial surface of the talus (T) and the posterior talofibular ligament (PTFL) (Blue arrow). F: Fibula TI: Tibia.

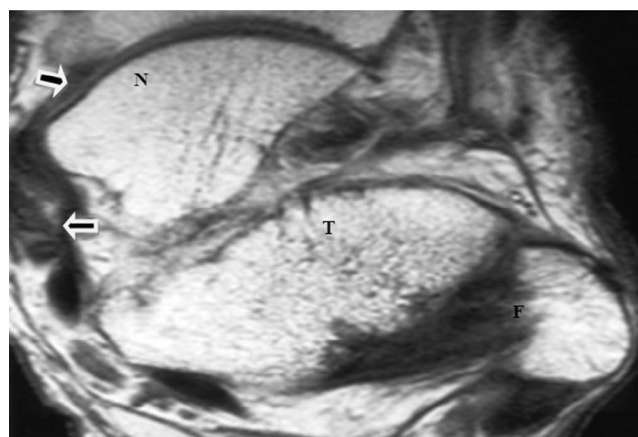


Figure 13 MR image (axial section) through the right ankle of a cadaver shows the tibionavicular ligament (TNL) (arrows) visualized as a thin homogeneous band of low signal intensity that inserted on the navicular bone (N). T: Talus. F: Fibula. TI: Tibia.

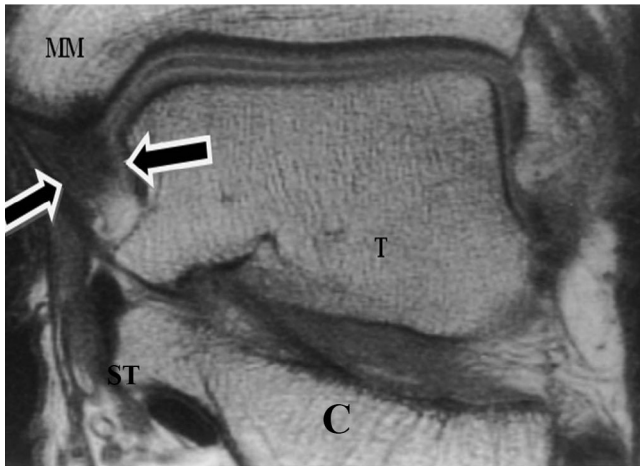


Figure 14 MR image (coronal section) through the right ankle of a cadaver shows the deep posterior tibiotalar ligament (DPTTL) (arrows) as a short, thick band that extends from the tip of the medial malleolus (MM) to the medial talar surface (T). C: Calcaneus. ST: Sustentaculum tali.

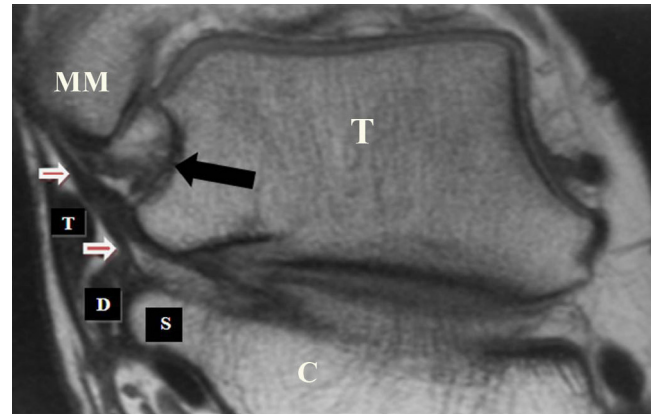


Figure 16 MR image (coronal section) through the right ankle of a cadaver shows the deep posterior tibiotalar ligament (DPTTL) (black arrow). The tibiocalcaneal ligament (TCL) (white arrows) is shown as a small, homogeneous band of low signal intensity lateral to the deep posterior tibiotalar ligament. D = flexor digitorum longus tendon, S = sustentaculum tali of the calcaneus, TP = tibialis posterior tendon. MM: Medial malleolus. T: Talus. C: Calcaneus.

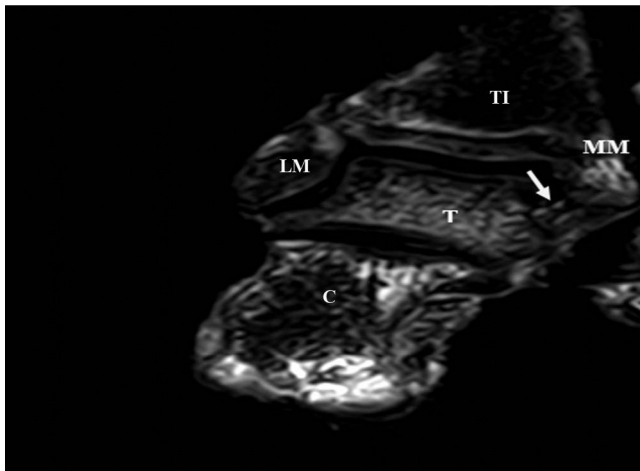


Figure 15 MR image (coronal section) through the left ankle of a cadaver shows the deep posterior tibiotalar ligament (DPTTL) (arrows) as a short, thick band that extends from the tip of the medial malleolus (MM) to the medial talar surface (T). C: Calcaneus. TI: Tibia. LM: Lateral malleolus.

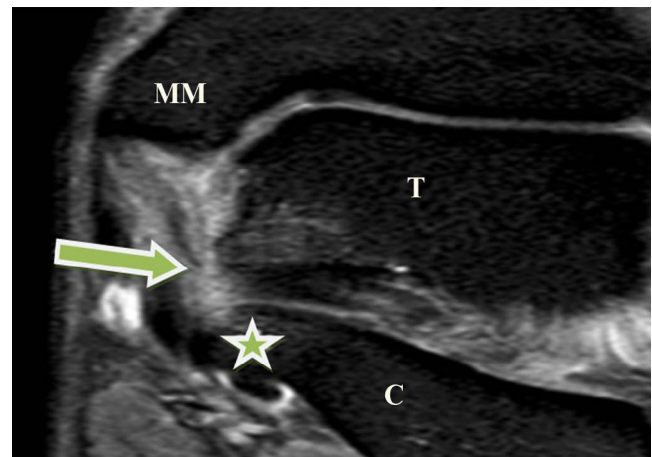

Figure 17 MR image through the right ankle of a cadaver shows disrupted tibiocalcaneal ligament (waviness, thickening and irregular contour) (arrow). Sustentaculum tali (asterisk). C: Calcaneus. T: Talus. MM: Medial malleolus.

3.2.2. Coronal plane

On coronal images, the deep posterior tibiotalar ligament was identified as short, obliquely oriented fibers extending from the tip of the medial malleolus to the medial talar surface (Figs. 14 and 15). The tibiocalcaneal ligament appeared as a small homogeneous band of low signal intensity that attached to the sustentaculum tali of the calcaneus. The fibers of this ligament were easily differentiated from those of the posterior

tibiotalar ligament and the tibialis posterior and flexor digitorum longus tendons (Fig. 16).

3.2.3. MR imaging results of the disrupted medial collateral ligament

The same ligaments were reimaged after disruption of every band. The disruption appeared in the form of waviness, thickening and irregular contour (Figs. 17–19).

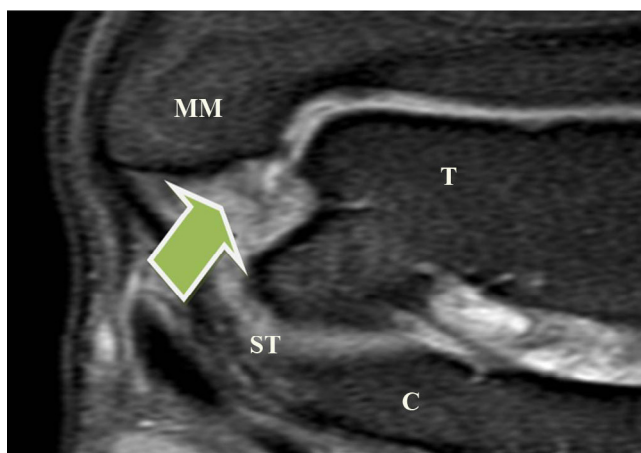


Figure 18 MR image through the right ankle of a cadaver shows discontinuous deep posterior tibiotalar ligament (arrow). T: Talus. C: Calcaneus. MM: Medial malleolus. ST: Sustentaculum tali.

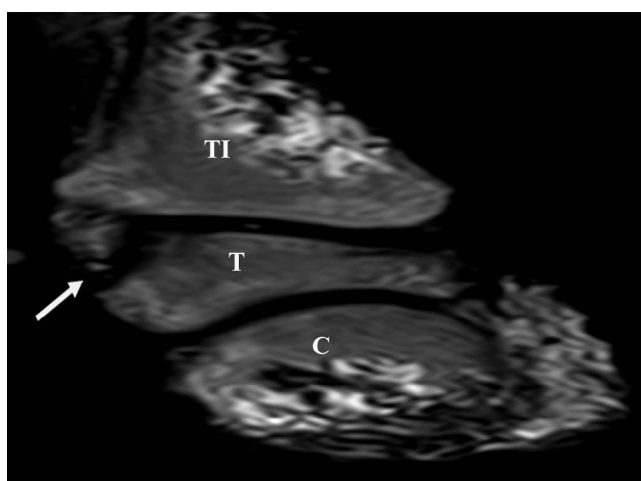


Figure 19 MR image through the right ankle of a cadaver shows discontinuous deep posterior tibiotalar ligament (arrow). C: Calcaneus. TI: Tibia. T: Talus.

4. Discussion

Certain problems exist in different reconstruction of the medial part of the ankle joint. Some authors have stressed the importance of anatomical knowledge of the ligaments in obtaining good results.^{13,14} The diagnosis and the therapy of ligamentous ruptures resulted from various forcing accidents are only possible with the detailed anatomical knowledge of the ligaments.¹³

A precise knowledge of the origin, location, direction and extent of the medial ligaments of the ankle is important to interpret the severity of ligamentous injury. Ankle injuries may be associated with avulsion fractures at either the origin or the insertion of any of ankle ligament.¹⁵⁻¹⁷

The medial collateral ligament was seen in the present study consisting of three constant bands in all specimens: tibiospring, tibionavicular and deep posterior tibiotalar ligaments. This agrees with the study of Saraffian² and Milner and Soames Table 3.⁶

Table 3 Comparison of the nomenclature used for the medial collateral components as suggested by Saraffian² and Milner and Soames.⁶

Milner and Soames ⁶	Saraffian ²
<i>Superficial layer</i>	
– Tibiospring (Major component)	– Tibioligamentous fascicle
– Tibionavicular (Major component)	– Tibionavicular fascicle and anterior superficial tibiotalar fascicle
– Superficial tibiotalar (additional band)	– Superficial posterior tibiotalar ligament
– Tibiocalcaneal (additional band)	– Tibiocalcaneal ligament
<i>Deep layer</i>	
– Deep posterior tibiotalar (Major component)	– Deep posterior tibiotalar ligament
– Anterior deep tibiotalar (additional band)	– Deep anterior tibiotalar ligament

Saraffian² divided the tibionavicular ligament into the tibionavicular fascicle and the anterior superficial tibiotalar fascicle. The latter attaches to the talus.

Milner and Soames⁶ found that the tibiocalcaneal ligament was overlapped by the tibiospring ligament in all specimens. Saraffian² reported that the tibiocalcaneal ligament was in continuity with the tibiospring ligament and was overlapped by it only occasionally.

In the present study, the tibiocalcaneal ligament was found in 50% of the specimens and the deep posterior tibiotalar ligament was found as a single band in all specimens. This disagrees with the study of Saraffian² who reported that the deep posterior tibiotalar ligament may be fasciculated or divided into two bands. Fasciculation was also observed by other investigators^{4,5} but without evidence of division into multiple bands.

As regard the deep anterior tibiotalar ligament, it was not found in the present study, but several investigators^{5,6} reported the presence of two deep tibiotalar ligaments: anterior and posterior.

In the present study, on axial plane the deep posterior tibiotalar ligament appears as thick, inhomogeneous band with broad attachment to the medial surface of the talus. On coronal images, the deep posterior tibiotalar ligament was identified as short, obliquely oriented fibers extending from the tip of the medial malleolus to the medial talar surface. The tibiocalcaneal ligament appeared as a small homogeneous band of low signal intensity that attached to the sustentaculum tali of the calcaneus.

Kannus and Renstrom¹¹ mentioned that in general the ligaments are readily identified as thin, linear and low signal intensity structures joining adjacent bones. The various components of the deltoid ligament are well visualized on both axial and coronal images. The deep tibiotalar component of the deltoid ligament normally demonstrates regular striations and thus has a heterogeneous appearance.

In the present study, the tibionavicular ligament was well visualized as a thin homogeneous band of low signal intensity that inserted on the navicular bone. The disruption of ligaments appeared in the form of waviness, thickening and irregular contour.

Kannus and Renstrom¹¹ stated that the injured ligament is frequently thickened and heterogeneous. Injuries to the tibiotalar component of the deltoid ligament manifest as loss of the regular striations that are normally seen in the ligament.

Conflict of interest

The authors declare that they have no conflict of interest.

References

1. Van Dijk CN. *On diagnostic strategies in patients with severe ankle sprain*, vol. 5. Amsterdam, Holland: University of Amsterdam; 1994, p. 145–50.
2. Sarrafian SK. *Anatomy of the foot and ankle. Descriptive, topographic, functional*, vol. 2. Philadelphia: Lippincott; 1993, p. 20–40.
3. Close JR. Some applications of the functional anatomy of the ankle joint. *J Bone Joint Surg* 1956;**38**:761–81.
4. Boss AP, Hintermann B. Anatomical study of the medial ankle ligament complex. *Foot Ankle Int* 2002;**23**:547–55.
5. Pankovich AM, Shivaram MS. Anatomical basis of variability in injuries of the medial malleolus and the deltoid ligament. *Anatomical studies. Acta Orthop Scand* 1979;**50**:217–23.
6. Milner CE, Soames RW. Anatomy of the collateral ligaments of the human ankle joint. *Foot Ankle Int* 1998;**19**:757–60.
7. Hintermann B, Valdervabano V, Boss AP, Trouillier HH, Dick W. Medial ankle instability a prospective study of 54 cases. *Am J Sports Med* 2003;**32**:44–55.
8. Ribbans William John, Garde Ajit. Tibialis posterior tendon and deltoid and spring ligament injuries in the elite athlete. *Foot Ankle Clin N Am* 2013;**18**:255–91.
9. Resnick D. Ankle and foot. In: Resnick D, Kang HS, editors. *Internal derangement of joints emphasis on MR imaging*. Philadelphia: Pa Saunder; 1997. p. 823–38.
10. Chandnani VP, Harper MT, Ficke IB, et al. Chronic ankle instability evaluation with MR arthrography. *MR Imag Stress Radiogr* 1994;**192**:189–94.
11. Kannus P, Renstrom P. Treatment of acute tears of the lateral ligaments of the ankle. Operation, cast, or early controlled mobilization. *J Bone Joint Surg Am* 1991;**73**:305–12.
12. Marder RA. Currents methods for the evaluation of the ankle ligament injuries. *Instr Course Lect* 1995;**44**:349–57.
13. Cimen A. Anatomi uludag universitesi. *Rasimevi* 1991;78–9.
14. Shibata Y, Nishi G, Masegi A. Stress test and anatomical study of the lateral collateral ligaments of the ankle. *Nippon – Seikeigeka – Gakkai – Zasshi* 1986;**60**(6):611–22.
15. Brostrom L, Sprained Ankles I. Anatomic lesions in recent sprains. *Acta Chir Scand* 1964;**128**:483–95.
16. Garrick JG. The frequency of injury, mechanism of injury and epidemiology of ankle sprains. *Am J Sports Med* 1977;**5**(6):241–2.
17. Kumai T, Takakura Y, Rufai A, Milz S, Benjamin M. The functional anatomy of the human anterior talofibular ligament in relation to ankle sprains. *J Anat* 2002;**200**:457–65.