

Contents lists available at [ScienceDirect](http://ScienceDirect.com)

## International Journal for Parasitology

journal homepage: [www.elsevier.com/locate/ijpara](http://www.elsevier.com/locate/ijpara)

## Invited Review

## Female genital schistosomiasis (FGS): from case reports to a call for concerted action against this neglected gynaecological disease

Vanessa Christinet<sup>a</sup>, Janis K. Lazdins-Helds<sup>b</sup>, J. Russell Stothard<sup>c</sup>, Jutta Reinhard-Rupp<sup>d,\*</sup><sup>a</sup> Centre International de Recherches, d'Enseignements et de Soins en Milieu Tropical (CIRES), Akonolinga, Cameroon<sup>b</sup> Geneva, Switzerland<sup>c</sup> Department of Parasitology, Liverpool School of Tropical Medicine, Liverpool L3 5QA, UK<sup>d</sup> Merck, Coinsins, Switzerland

## ARTICLE INFO

## Article history:

Received 30 December 2015

Received in revised form 22 February 2016

Accepted 23 February 2016

Available online 8 April 2016

## Keywords:

Urogenital schistosomiasis

Gynaecology

FGS

HIV/AIDS

Praziquantel

Female genital schistosomiasis

## ABSTRACT

In recent years, control of neglected tropical diseases has been increasingly gaining momentum and interventions against schistosomiasis are being progressively scaled-up through expansion of donated praziquantel and preventive chemotherapy campaigns. However, the public health importance of female genital schistosomiasis is not fully recognised nor its control is adequately addressed. Taking a clinical and anatomopathological perspective, we evaluated the available literature to highlight the importance of female genital schistosomiasis and its connections with two sexually transmitted infections of global importance, Human Immunodeficiency Virus (HIV) and Human Papilloma Virus. Outside the long list of clinical descriptive reports beginning in 1899, there is presently a shocking gap in epidemiological assessment and a significant underestimation of the burden of FGS remains. The scarcity of integrated approaches to address female genital schistosomiasis calls for more concerted action in its detection, treatment and prevention alongside other concomitant women's health issues, otherwise female genital schistosomiasis will remain a neglected gynaecological disease.

© 2016 The Authors. Published by Elsevier Ltd on behalf of Australian Society for Parasitology. This is an open access article under the CC BY license (<http://creativecommons.org/licenses/by/4.0/>).

## 1. Introduction

Schistosomiasis is a water-borne parasitic disease caused by infection with trematode worms of the genus *Schistosoma*. The disease was originally described in Egypt by Theodor Bilharz in 1851 and today can be found throughout Africa, South America and Asia (Colley et al., 2014). Infection may affect humans of all ages and genders, and globally it has the highest burden of disease among the 17 recognised neglected tropical diseases (World Health Organization (WHO), 2016b). Owing to a variety of factors underlying an individual's exposure and infection, there can be substantial differences in prevalence and intensity of infection across communities, as well as an associated spectrum in the severity of disease. These manifestations are determined by a number of causal factors such as the species of schistosome, the duration of infection, host-specific factors that influence immuno-pathological lesions to the worm eggs and access to praziquantel treatment (Hirayama, 2006). Furthermore, as

individuals rarely harbour schistosomiasis alone, prior infection with *Schistosoma* can increase the severity of other bacterial, protozoal or helminth infections acquired later (Abruzzi and Fried, 2011).

Schistosomiasis can be broadly classified as either acute or chronic presentations (Colley et al., 2014). Upon initial percutaneous infection by cercariae, acute symptoms may include dermatitis, then later non-specific symptoms of fever, headache and cough. Acute symptoms normally resolve in a few weeks but in exceptional cases, death by hyper-infection may occur. As adult schistosomes mature within the body and commence egg deposition, chronic manifestations ensue, typically related to immunopathological lesions and the formation of granulomata in various organs around eggs (Colley et al., 2014). The involvement of the intestinal tract with hepato-splenic disease and the urinary tract with its associated organs is well-known (Centers for Disease Control and Prevention (CDC), 2012 <http://www.cdc.gov/parasites/schistosomiasis/disease.html>; WHO, 2016, <http://www.who.int/mediacentre/factsheets/fs115/en/>). Since eggs can be found throughout the body in variable amounts, other clinical and pathological diseases can be found in the heart, lungs, brain and spinal cord as well as in the genital organs of both genders (Barsoum et al., 2013).

\* Corresponding author at: Translational Innovation Platform Global Health, Ares Trading SA, route de la Verrerie 6, 1267 Coinsins, Switzerland. Tel.: +41 21 900 3170.

E-mail address: [jutta.reinhard-rupp@merckgroup.com](mailto:jutta.reinhard-rupp@merckgroup.com) (J. Reinhard-Rupp).

The pathological alterations due to the presence of schistosome eggs in the genitalia of women have been defined as a particular entity called female genital schistosomiasis (FGS). In 1997, the Gender Task Force of the Tropical Disease Research Programme (TDR) of the WHO included FGS in a list of scientific areas that deserve higher research priority (Poggensee et al., 1999). Since then, however, the extent of morbidity ascribed to FGS, which can be found in both the lower and upper genital tract, has continued to be insufficiently addressed. Moreover, FGS has failed to be reported at national levels which has hampered an international appraisal. As an unfortunate outcome, prevention and control of FGS is largely disconnected from global efforts to improve the reproductive and sexual health of women. To address this, we attempted to draw together the available literature to give a continental perspective and highlight how FGS should be integrated into a broader vision of improving women's health.

## 2. Methodology

PubMed was used as the search tool. The key words used to gather information on FGS in general were 'female', 'genital' and 'schistosomiasis'. Only publications treating the clinical and anatomopathological aspects of FGS were selected and mapped or displayed in the table. Articles published between 1899 and September 2015 were included. Articles in English, French, German and Spanish were considered. Articles in Portuguese, Japanese or Chinese were included only as cited in Table 1 or Fig. 1. A specific review was performed on FGS attributed to *Schistosoma haematobium* and its association with HIV infection. The following keywords were used: 'HIV' OR 'acquired immunodeficiency syndrome' AND 'schistosomiasis' OR 'bilharzia' or 'haematobium'. Owing to their wider implications, publications that addressed schistosomiasis during pregnancy and HPV/cervical cancer, when encountered during the initial literature review, were also inspected but the topic was formalised in the initial search algorithm.

## 3. An overview of the FGS literature

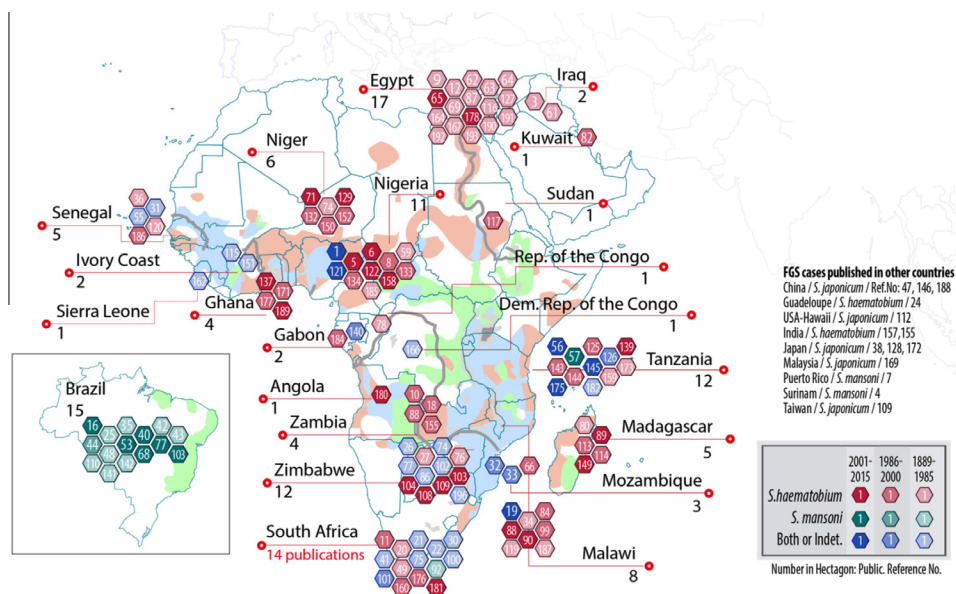
A total of 193 publications featuring reports on the clinical and pathological presentation of FGS were identified while preparing this review. A considerable proportion describe African cases published during the colonial era (Fig. 1). Some 44 publications were from Europe, USA and Oceania, describing FGS in migrants or travellers coming from schistosomiasis-endemic countries (Table 1). The large majority of the reviewed publications were case reports or case series; the oldest published FGS case was reported in the Lancet in 1899 (Madden, 1899). The analysis of case reports and case series shows that every female genital organ (vulva, vagina, uterine cervix, uterine body, Fallopian tubes and ovaries) can be affected by schistosomiasis. We note that uterine body involvement is greatly under-reported in such reports, being clearly revealed upon comparison with findings from post-mortem studies. These latter studies demonstrate that the most frequently affected gynaecological organs are the uterine cervix and the uterine body, followed by the adnexa and the vulvo-vagina (Charlewood et al., 1949; Gelfand and Ross, 1953; Youssef et al., 1970; Gelfand et al., 1971; Edington et al., 1975). Of the three schistosomes of most medical significance, the majority of FGS is caused by *S. haematobium* but in Brazil, for example, FGS has been shown to be caused by *Schistosoma mansoni* (Chaves and Palitot, 1964; Coelho et al., 1979; Poggensee et al., 2001; Downs et al., 2011; Goncalves Amorim et al., 2014). In Asia, cases of FGS have also been described as resultant from *Schistosoma japonicum*. Less important schistosome species such as *Schistosoma intercalatum* have also been shown to cause FGS (Koller, 1975; Berry, 1976; Yang, 1984; Picaud et al., 1990; Qunhua et al., 2000; WHO, 2016, [http://www.who.int/schistosomiasis/genital\\_schistosomiasis/en/](http://www.who.int/schistosomiasis/genital_schistosomiasis/en/)).

Most of the FGS cases reported before 1990 probably underrepresented the real burden of FGS for, in our opinion, they were based on reports from African urban centres or in northern countries where more advanced screening tools were available. Several more recent studies attempted to address this systemic bias by

**Table 1**  
Forty-six publications out of the 193 reviewed papers are from Europe, USA and Oceania describing Female Genital Schistosomiasis in migrants or travellers coming from schistosomiasis endemic countries. The table provides an overview of countries of diagnosis, countries of infection, patient number and age, clinical condition and *Schistosoma* spp.

Country of diagnosis	Schistosomiasis infestation origin	Age (years)	Schistosomiasis-associated clinical condition	<i>Schistosoma</i> spp.	Publication reference number
UK	Malawi Lake, Zimbabwe (t), Zambia, Nigeria, Zimbabwe (m)	34, 43, 51, 26, 39, 37, 27, 31, 28, 29, 28, 29	Vulvar granuloma (3 cases), adnexal mass, infertility, tubal carcinoma, ectopic pregnancy, teratoma, HPV/HIV infection, cervicitis, cervical carcinoma in situ	<i>S. haematobium</i>	14, 17, 37, 107, 147, 148, 156, 168, 183
USA	Senegal, East Africa, Liberia, Guinea, South Africa (m)	27, 20, 28, 41, 22, 20, 63, 32, 37	Cervical dysplasia with HPV, cervical dysplasia with HPV/HIV, sandy patches, ectopic pregnancy, salpingitis, infertility, perianal fistula, cervical cancer without HPV	<i>S. haematobium</i> , <i>S. mansoni</i> (1 case)	2, 13, 45, 54, 93, 131, 154
France	DRC (m), Mauritania (m), Senegal (ms), Tunisia (m), Mali (m), Mali (t), Senegal (m)	28, 34, 22, 29, 32, 35, 29, 21, 33, 27	Infertility, cervical dysplasia, tubal obstruction, hydrosalpinx, adnexal mass, secondary amenorrhoea, endometritis, ectopic pregnancy	<i>S. haematobium</i> , <i>S. mansoni</i> (DRC, 1 case from Senegal)	51, 58, 60, 108, 123, 124, 165
Germany	Angola, Sierra Leone, Togo (m)	24, 30, 21	Ectopic pregnancy, leiomyoma, infertility, adnexal tumour	<i>S. haematobium</i>	86, 118, 161
Netherlands	Malawi Lake, Mali (t)	37, 33	Leiomyoma, infertility	<i>S. mansoni</i> , <i>S. haematobium</i>	29, 79
Spain	Nigeria (m) Mali (t)	26	Infertility, vulvitis	<i>S. haematobium</i>	15, 50
Switzerland	Egypt, Malawi Lake (t)	54, 26	Vulvar granuloma, asymptomatic ovarian and tubal schistosomiasis, vulvar lesion and cervical lesions	<i>S. haematobium</i>	28, 76, 105
Portugal			Ovarian schistosomiasis, external genital mass		104, 179
Australia					91
Belgium	Mali, Senegal (t)	20	Vulvar mass	<i>S. haematobium</i>	39
Czech Rep.	Brazil		Hydrosalpinx, tubal schistosomiasis	<i>S. mansoni</i>	136
Israel	Ethiopia (m)	19	Recto-vaginal fistula		102
Ireland	Nigeria (m)	31	Ectopic pregnancy, tubal schistosomiasis		67
Italy	South Tunisia (t)		Vaginal mass	<i>S. haematobium</i>	23
New Zealand	Malawi Lake	30, 28	Adnexal mass, vulvar lesion	<i>S. haematobium</i>	52, 111

m, migrants; t, travellers; HPV, human papilloma virus; HIV, human immunodeficiency virus.



**Fig. 1.** Map indicating all publications reviewed with a considerable proportion of papers describing African cases published during the colonial era, followed by Brazil. Each hexagon represents one publication with its respective reference number. The years of publication are classified into three groups of colour shades: light colours show publications before 1986; medium colours show those between 1986 and 2000 and dark colours those from 2001 to 2015. In particular, the two last groups highlight a time period before and after the World Health Assembly (WHA) resolution 54.19 in 2001, which promotes regular chemotherapy for school-age children and women to reduce morbidity. Map modified from Gryseels et al. (2006).

measuring the prevalence of cervical schistosomiasis in several rural communities known to be endemic for schistosomiasis. These studies assessed the cervical form of FGS (diagnosed by biopsy except in the Talaat study (Talaat et al., 2004) in the frame of schistosomiasis screening studies targeting the general population in regions known to be endemic for schistosomiasis in Madagascar, Tanzania, Malawi, Niger and Egypt. In these studies, cervicovaginal schistosomiasis prevalence ranged from 33% (95% confidence interval (CI): 19–51) in Madagascar to 75% (95% CI 65–87) in Niger, with Tanzania and Egypt in between (Renaud et al., 1989; Leutscher et al., 1998; Poggensee et al., 2000; Talaat et al., 2004; Kjetland et al., 2005).

Another systematic bias apparent in the literature is that most FGS cases were reported in women less than 30 years of age, however, this probably reflects the age of the studied population and not the true age distribution of FGS. Symptoms attributable to FGS have been reported in young children (Hegertun et al., 2013) particularly the vulvo-vaginal forms (Berry, 1966; Al-Adnani and Saleh, 1982; Gouzou et al., 1984), as well as in post-menopausal women (Berry, 1966; McKee et al., 1983; Arora et al., 1986; Billy-Brissac et al., 1994; Nouhou et al., 1998; North et al., 2003).

With the above considerations, the examined literature reporting FGS cases from Africa and Brazil were mapped to show their geographical distribution with the underlying prevalence of *S. haematobium* and *S. mansoni* (Fig. 1). The years of publication are classified into three groups: before 1986; between 1986 and 2000 and from 2001 to 2015. In particular, the two last groups highlight a similar time period (15 years) before and after the WHO World Health Assembly (WHA) resolution number 54.19 endorsed in 2001 which promotes regular chemotherapy for school-age children and women to reduce morbidity due to schistosomiasis and soil transmitted helminths (STH). Publications reporting FGS cases in other parts of the world are also listed (Fig. 1). It should also be noted that FGS can be associated with active egg-patent excretion but can also be present without eggs detected in urine or stools. For example, several studies showed a prevalence of cervico-vaginal schistosomiasis of 55–75% in women with *S. haematobium* eggs detected in urine (Kjetland

et al., 1996; Leutscher et al., 1997; Poggensee et al., 1998), whereas in other studies, up to one-fourth of cervical lesions were present without eggs being detected in urine (Nouhou et al., 1998; Poggensee et al., 1998; Kjetland et al., 2005, 2008; Shennan and Gelfand, 1971). The imprecise relationship between FGS and egg-patent urogenital schistosomiasis confounds attempts to estimate the number of women with, or at risk of FGS with current estimates for those with urogenital schistosomiasis. By examining the literature relative to the clinical presentation and the reported consequences of FGS, as well as the potential relationship with other sexually transmitted diseases, we seek to reposition schistosomiasis in the broader context of gynaecological diseases.

#### 4. Schistosomiasis and female genital pathologies

The clinical symptoms of FGS are in general non-specific and can be similar to those resulting from other causes. Clinical diagnosis requires trained health care professionals and/or histopathological visualisation of the eggs in the lesions. FGS cases have been reported in African women, African migrants or European or American travellers, and in some instances they had a similar clinical presentation. In the following section we highlight the pathological conditions affecting the female genital tract, however the recurrent challenge is to assess whether schistosomiasis is directly implicated in the pathological process or if it is just an incidental finding in the biopsies or in the anatomopathological tissue samples. In most of the case reports the causal relationship is well based, however in some of the cases reported in anatomopathological series the causal relationship is sometimes less obvious and the conclusions cannot be clearly supported.

##### 4.1. Schistosomiasis and ectopic pregnancy (EP)

Ectopic pregnancy (EP) is a pregnancy that occurs outside the uterine cavity. Tubal pregnancy is the implantation of the embryo in the Fallopian tube and is the most frequent type of EP. It is potentially a deadly condition as it can occasion severe



intra-abdominal bleeding due to tubal rupture and requires emergency surgical intervention (Bugalho et al., 1991b). EPs attributed to schistosomiasis have been repeatedly reported in many geographical areas between 1943 and 2013 and by several authors, i.e.: in Mozambique in a series of 103 cases of EPs, 4 out of 103 were attributed to a genital foci of schistosomiasis (Bugalho et al., 1991a,b). In Ivory Coast 12 out of 331 cases of EPs were associated with tubal schistosomiasis. In Loubière's anatomopathological series (Loubière et al., 1977), 15 Fallopian tubes out of 32 cases of tubal schistosomiasis were removed due to tubal pregnancy. *Schistosoma* granuloma was always present but sometimes not prominent enough to be considered as the causal factor except in one case of a bilateral tubal schistosomiasis due to *S. mansoni* which was responsible for bilateral EPs (Loubière et al., 1977). Two cases of tubal pregnancies in a series of 17 utero-adnexal schistosomiasis cases were described by Diouf et al. (1973).

Although two studies from the 1970s comparing cases and controls failed to demonstrate any association between schistosomiasis and EPs (Bland and Gelfand, 1970a; Frost, 1975), tubal pregnancy was considered as the consequence of tubal alteration due to schistosomiasis granulomata and/or salpingitis in the anatomopathological analysis of a salpingectomy specimen in the following cases: Gilbert (1943), El-Bedri, (1958), Hassim, (1966), Rosen and Kim, (1974), Vass and Lucey, (1982), Yang, (1984), Okonofua et al. (1990), Ekoukou et al. (1995), Nouhou et al. (1998), Schneider and Steyn (2000), Woto-Gaye et al. (2000), Eogan et al. (2002), Hoffmann and Bauerfeind (2003), Garba et al. (2004), Mohammed et al. (2004), Bahrami et al. (2006), Laxman et al. (2008), Owusu-Bempah et al. (2013), Sahu et al. (2013), Aminu et al. (2014). Most of the previous cases were reported in African residents or migrants, one in a traveller, one in a Chinese resident, one in an Indian and one in an Iraqi woman. Two cases were attributed to *S. mansoni* and one to *S. japonicum*. The possible physiopathological mechanism as to how schistosomiasis can increase the risk of EP could be due to tubal submucosa alteration. Mucosal alteration have also been described (Mohammed et al., 2004), which rarely results in an obstruction but could induce a loss of tubal elasticity. This would affect the peristalsis of the tube and the ovum carriage. Fertilisation may occur and the conceptus implants in the tubal mucosa instead of uterine cavity (Bland and Gelfand, 1970a; Ville et al., 1991; Hoffmann and Bauerfeind, 2003). Several descriptions of surgical procedures report peritoneal, peri-ovarian and/or peri-tubal adhesions, reflecting a chronic inflammatory process associated with chronic schistosomiasis infection (Mensah et al., 1972; Schneider and Steyn, 2000; Bahrami et al., 2006).

#### 4.2. Schistosomiasis and sub-fertility and infertility

It is estimated that female causes of infertility account for between 25% and 37% of infertility worldwide, with the largest proportions in sub-Saharan Africa and south-eastern Asia, which are the regions with the highest worldwide prevalence of schistosomiasis and FGS (Nguyen and Kols, 1997). Two case-control studies have shown a significant association between *S. haematobium* and infertility. One study was conducted in 483 Zimbabwean women whose husbands' infertility had been excluded. The presence of *Schistosoma* eggs in the cervical smear was significantly associated with infertility (Odd ratio (OR): 3.6 (95%CI: 1.05–12;  $P=0.041$ ) (Kjetland et al., 2010a,b). The second study which was done in Malawi showed a significantly higher proportion of infection with *S. haematobium* in a group of primary and secondary infertile women than in fertile controls (41.3% versus 21.4%;  $P < 0.02$ ) (Bullough, 1976).

In a study in Pemba Island, Zanibar, tubal schistosomiasis was found in 40% of the cases of primary or secondary infertility

(Scheller, 1971). In Niger a prevalence of 38.5% of urinary schistosomiasis was found in 109 women with infertility. Women with schistosomiasis presented more lesions of the female genital tract (cervicitis, adnexal mass) than those who were not infected (Nayama et al., 2007). In the analysis of 111 patients with female genital schistosomiasis in Tanzania, Swai et al. (2006) reported 7% infertility.

Infertility was often the only reason leading to the histopathological diagnosis of schistosomiasis involvement of the upper genital tract. In many cases there were no other symptoms (Adeniji, 2001). Occasionally the schistosomiasis finding was reported as incidental (DeMille et al., 1995; Goverde et al., 1996), however, in most cases infertility was attributed to *Schistosoma* lesions found in the Fallopian tubes. As for EPs attributed to schistosomiasis, the surgical procedures often described important peritoneal, peri-ovarian and peri-tubal adhesions (Gilbert, 1943; Seneze et al., 1963; Mouktar, 1966; Diouf et al., 1973; Bailey et al., 2011; Cornier et al., 1981; El-Mahgoub, 1982; El-maraghy et al., 1982; Harouny and Pedersen, 1988; Letterie and Sakas, 1991; Morice et al., 1993, 1996; Ogunniyi et al., 1994; Balasch et al., 1995; Schroers et al., 1995; Nouhou et al., 1998; Swai et al., 2006; Schanz et al., 2010). Two cases of infertility associated with endometrium pathology have been reported (Le Guyader et al., 1965; Krolkowski et al., 1995). Tuberculosis has been reported concomitantly to peritoneo-tubal schistosomiasis in an infertile woman (Ekoukou et al., 1995). Tuberculosis granuloma in the genitals is the main differential diagnosis of schistosoma granuloma in the genital tract.

In two studies of female infertility where male causes were excluded, El-Mahgoub (1972) evoked several mechanisms of female infertility induced by schistosomiasis: tubal obstruction, defective luteal phase, anovulation or antispermatozoal antibodies. He also reported the presence of antispermatozoal antibodies in 63% of the 41 women with cervicovaginal schistosomiasis compared with 10% in a control group of women with urinary or gastrointestinal schistosomiasis without FGS. (El-Mahgoub, 1972, 1982).

#### 4.3. Schistosomiasis and adnexal mass

Ovarian or tubal adnexal masses associated with *S. haematobium*, *S. mansoni* or *S. japonicum* infections have been reported independently from infertility or EP cases. Lower abdominal pain was sometimes the only clinical symptom (Gilbert, 1943; Ali et al., 1956; Seif-Eldin, 1958; Carpenter et al., 1964; Diouf et al., 1973; Gloor et al., 1979; Bac et al., 1987; Crump et al., 2000; Lee et al., 2000; Shekhar et al., 2000; Lambertucci et al., 2009; Batista et al., 2010; Bailey et al., 2011; Sedlis, 1961). Schistosomiasis fibrous tumours involving the adnexa has been described in very young girls (Symmers, cited in Camain et al. (1951)). Various types of adnexal tumours associated with schistosomiasis have been described such as arrhenoblastoma (Lemos et al., 1960; Foda et al., 1961), cystadenoma (El-Maraghy et al., 1982), teratoma (Paradinas, 1972; Sunder-Raj, 1976; Gigase and Vanderputte, 1980; Kahn et al., 1978), ovarian carcinoma (Goncalves Amorim et al., 2014) ovarian Brenner cell tumour (Iskander and Kamel, 1968), ovarian thecoma (Onuigbo and Twomey, 1978) and one carcinoma of the Fallopian tube (Beadles et al., 2007). An important proportion of schistosomiasis adnexal involvement due to *S. haematobium* or *S. mansoni* has been demonstrated in several histopathological series (Arean, 1956; Badawy, 1962; Ricosse et al., 1980; Al-Adnani and Saleh, 1982; Gouzouf et al., 1984; Gwavava et al., 1984; Mohammed et al., 2007).

#### 4.4. Schistosomiasis and vulvo-vaginal pathology

The first FGS report was published in 1899. It was a case of a warty prominent mass in the vagina of an Egyptian woman

(Madden, 1899). Many other cases of vulvo-vaginal lesions associated with schistosomiasis have been described since then. Schistosomiasis on the vulva or in the vagina, histopathologically typically consists of a granuloma or a polypous/papillomatous tumour (Scheller, 1971; Al-Adnani and Saleh, 1982; Helling-Giese et al., 1996; Mohammed et al., 2007). Clinically it appears as a swelling, wart, sore, plaque, bleeding pseudotumoural mass (Ricosse et al., 1980; Wright et al., 1982). Vulvar schistosomiasis lesions can be easily confounded with condylooma acuminata (genital warts due to Human Papilloma Virus (HPV)) (Boulle and Noreloviu, 1964; McKee et al., 1983; Samuel and Taylor, 2015) or syphilis. Helling-Giese and colleagues have demonstrated that polypoid/papillomatous tumours, in the vagina and vulva, can be considered to be pathognomonic for FGS only in the absence of HPV infection or syphilis (Helling-Giese et al., 1996). Prominent lesions of the vulva were described in a series in Zambia in which the mean age was 18 years (S.D. = 5) (Attili et al., 1983). Descriptions of similar prominent lesions can also be found in earlier publications (Kingsley, 1969; Gras et al., 1980). In post-mortem studies (Gelfand et al., 1971; Edington et al., 1975), as in histopathological series (van Raalte et al., 1981; Al-Adnani and Saleh, 1982; Swai et al., 2006) vulvo-vaginal schistosomiasis infections are predominantly found in young girls or teenagers. Cases of vulvo-vaginal schistosomiasis have been also associated with *S. mansoni* (Areal, 1956). Several cases of schistosomiasis lesions of the vulva have been described in Europe and the USA in migrants (Mawad et al., 1992) or travellers (Bianchi and De Carneri, 1970; Leslie et al., 1993; Corachan et al., 1997; Blum et al., 1998; Laven et al., 1998; Carey et al., 2001; Catteau et al., 2011; Samuel and Taylor, 2015). Landry et al. (1996) described in a female traveller a case of a vulvar schistosomiasis lesion 1 year after a retrospective diagnosis of Katayama syndrome (fever due to primary schistosomiasis infection in non-immune persons). Vesico-vaginal fistulas (Servais, 1965; Ricosse et al., 1980; Kunin et al., 1996) and perianal fistulas (DeMille et al., 1995), associated with schistosomiasis, have been reported. In contrast, Bland did not find any association between schistosomiasis and vesico-vaginal fistula but patients with vesico-vaginal fistulas and schistosomiasis were less likely to heal after surgical procedures than those who did not have schistosomiasis (Bland and Gelfand, 1970b).

#### 4.5. Schistosomiasis and uterine body-associated pathology

As previously noted clinical cases of schistosomiasis with uterine body involvement are underreported compared with the frequently described uterine body involvement in post-mortem studies. This contradiction was already noted by Attia in his review (Attia, 1962). In some recent publications, *S. mansoni* and *S. haematobium* infections have been associated with leiomyoma of the uterus, a pathology which is known to frequently affect sub-Saharan African women (Boers et al., 2003; Mayr et al., 2005; Cavalcanti et al., 2011; Hillers and Wiersema, 1961). A case of endometritis due to the presence of the parasite in the intramural uterine vein in a 42 year old Chinese woman (Ching-ch'ien, 1951) and a Japanese case with endometrial schistosomiasis were reported (Sugiyama et al., 1963). Cases of schistosomiasis associated with pregnancy have been associated with stillbirths (Narabayashi, 1914 cited in Carpenter et al., 1964; Youssef and Abdine, 1958; Sutherland et al., 1965; Berry, 1966; Bittencourt et al., 1980). One case control study examined the impact of schistosomiasis on birth weight. While not showing any differences in the delivery term, it did show that schistosomiasis in pregnant women was significantly associated with low birth weight in preterm deliveries (Siegrist and Siegrist-Obimpeh, 1992).

#### 4.6. Schistosomiasis and cervical alterations

In anatomopathological case series and post-mortem studies, the uterine cervix is the female genital organ most frequently affected by schistosomiasis. Cervical schistosomiasis has been the most studied aspect of FGS with many studies conducted during the last 20 years by Feldmeier, Kjetland and associates. FGS clinical presentation can be similar to other gynaecological pathologies (sexually transmitted infection, endometriosis, etc). Several clinical signs and symptoms have been significantly associated with cervical schistosomiasis such as low abdominal pain, irregular menstruation, cervical contact bleeding, abnormal vaginal discharge, dyspareunia, vaginal or cervical polyps, contact bleeding, vulval itching and chronic cervicitis (Leutscher et al., 1998; Anosike et al., 2003; Talaat et al., 2004; Swai et al., 2006). Rubbery papules, sandy patches and neovascularization are cervical lesions that have been statistically strongly associated with *S. haematobium*, (Kjetland et al., 2005; Randrianasolo et al., 2015) and with *S. mansoni* (Poggensee et al., 2001); grainy and yellow sandy patches and rubbery papules being considered pathognomonic of cervical schistosomiasis (Kjetland et al., 2012, 2014; Norseth et al., 2014). In Europe and in the USA several cases of schistosomiasis have been diagnosed through cervical smears of women with dysplasia (Adeniran et al., 2003; Chenault and Hoang, 2006; Dzeing-Ella et al., 2009; Chen et al., 2012). Endocervical forms of schistosomiasis such as polyps have been described as well (Eladl et al., 2012; Delmondes et al., 2014). Three cases of schistosomiasis have been reported in HIV patients with cervical dysplasia or carcinoma with HPV (Chenault and Hoang, 2006; Rachaneni et al., 2007; Toller et al., 2015). In an observational study conducted in the Limpopo province in South Africa, van Bogaert (2011) found an HIV prevalence of 14% in 234 women with biopsy-confirmed FGS, which is the expected HIV prevalence in this region; schistosomiasis cervical involvement was observed in the large majority of HIV-positive women and more frequently than in the whole study group of (HIV+ and HIV-) women with FGS (94% versus 54%). Intraepithelial neoplasia was observed more frequently in HIV-positive women than in the whole studied group (50% versus 17.5%). HIV-infected women were significantly older than women with FGS who were not infected with HIV (42 versus 35 years;  $P = 0.003$ ) (van Bogaert, 2011).

#### 5. *Schistosoma haematobium* and HIV

In 1995, the first article suggesting FGS as a risk factor for HIV was published, establishing a plausibility and prevalence correlation between HIV and urinary schistosomiasis (Feldmeier et al., 1995a,b). Since then, several studies documented that schistosomiasis of the uterine cervix is associated with disrupted epithelia, neovascularisation, contact bleeding or spontaneous bleeding (Wright et al., 1982; Poggensee et al., 2000; Kjetland et al., 2005, 2006a,b, 2009; Swai et al., 2006; Jourdan et al., 2011b, 2013), and a higher density of HIV target cells; factors that predispose to HIV infection (Jourdan et al., 2011a; Kleppa et al., 2014). While the association between *S. haematobium* and HIV has been documented in several observational studies, the association between *S. mansoni* and HIV is less clear. Two case control studies performed in comparable groups and adjusted for the main confounding factors showed two- to four-fold increased odds of HIV in women with FGS due to *S. haematobium* (Kjetland et al., 2006b) or urogenital schistosomiasis (Downs et al., 2011). In an ecological study including 43 sub-Saharan African countries Ndeffo Mbah et al. (2013b) demonstrated that each infection with *S. haematobium* per 100 individuals was associated with a 2.9% relative increase in HIV infection (95% CI: 0.2–5.8%;  $P = 0.038$ ).

Three mathematical modelling studies have shown a correlation between HIV and schistosomiasis epidemics and an impact of schistosomiasis treatment on the HIV epidemic (Gibson et al., 2010; Mushayabasa and Bhunu, 2011; Ndeffo Mbah et al., 2013a). Furthermore, one of these studies showed the cost effectiveness of a schistosomiasis intervention on HIV infection prevention (Ndeffo Mbah et al., 2014). The main limitation of the above cited observational studies is that they cannot prove causality and some relevant confounding factors may have been missed.

The interpretation of the results could be wrong if HIV infection would occur before FGS and if it would induce more severe FGS lesions (as it is the case for cervical dysplasia). Schistosomiasis age prevalence curves and its genital manifestation before the onset of sexual activity tend to make more it probable that schistosomiasis infection and its related genital lesions occur before HIV infection (Poggensee et al., 2000; Kjetland et al., 2005; Hegertun et al., 2013). Moreover FGS clinical presentation does not differ in HIV-infected women versus HIV non-infected women (Kleppa et al., 2015). Egg excretion in urine might be increased in HIV-positive women which would overestimate the association but several studies have shown that egg excretion tends to be similar or even lower in HIV-infected individuals with urinary schistosomiasis (N'Zoukoudi-N'Doundou et al., 1995; Mwanakasale et al., 2003; Kallestrup et al., 2005; Kleppa et al., 2015).

## 6. Cervical schistosomiasis, HPV and cervical carcinoma

It is well established that cervical carcinoma is mainly due to HPV infection. While the association between schistosomiasis and cervical carcinoma remains unclear, several cases of cervical carcinoma associated with schistosomiasis have been reported many years ago (Chaves, 1966; Pimentafilho, 1964). In two histopathological series, cervical carcinoma was found in 9–10% of the studied cervical schistosomiasis cases (Badawy, 1962; Gwavava et al., 1984). Payet and Camain (cited in Gwavava et al. (1984)) found four cases of cervical cancer associated with schistosomiasis in a series of 38 cervical carcinoma cases. Youssef reported 15 cases of invasive cervical carcinoma in which *Schistosoma* eggs were visualised microscopically out of 121 cases of cervical schistosomiasis (Youssef et al., 1970). On the other hand, other studies found no association between cervical carcinoma and schistosomiasis (Williams, 1967; Coelho et al., 1979; Wright et al., 1982; Szela et al., 1993). However, in one study when no association between cervical cancer and cervical schistosomiasis was found, it was observed that women affected with both schistosomiasis and cervical cancer were significantly younger than those affected by cervical cancer only (Moubayed et al., 1994, 1995). This could reflect the fact that young girls are more at risk of having FGS but it could also be compatible with the hypothesis that schistosomiasis could increase the carcinogenic effect of HPV infection on the uterine cervix by predisposing to HPV infection or favouring its persistence as several authors have hypothesised. Indeed Petry and colleagues (2003) found a higher proportion of high risk HPV in the genitals of women from a schistosomiasis endemic area compared with controls (Poggensee et al., 1999; Poggensee and Feldmeier, 2001; Petry et al., 2003). More recently a longitudinal study showed that the development of high-grade squamous intraepithelial neoplasia was significantly associated with FGS of a minimum of 5 years duration, while no association was found between FGS and persistent high-risk HPV (Kjetland, 2010).

## 7. Discussion

The majority of the publications examined in this review were case reports or case series. The few general population based

studies were mostly performed in *S. haematobium* endemic areas. Despite the relatively similar methodology, these studies revealed significantly different results, which most likely reflected the prevalence and intensity of schistosomiasis in the studied areas. However, other reasons cannot be excluded and deserve further research. Equally relevant is the lack of population studies in areas endemic to *S. mansoni* (and eventually *S. japonicum*), given the abundance of case reports of FGS associated with this species, particularly in Brazil (Fig. 1). Traditionally, the interface between parasitology and gynaecology has been weak and largely focused on diseases caused by protists e.g. *Trichomonas vaginalis*. It has been only recently appreciated that helminths, and particularly schistosomiasis, cause significant damage to the female genitalia, as highlighted in a relevant WHO document (WHO, 2016a).

Today, we appreciate many of the possible consequences of FGS such as EP, infertility, spontaneous abortion, low premature infant birth weight, possibly cervical cancers, cervical lesions and especially its probable role in increasing susceptibility to other infections such as HIV/AIDS, however we lack reliable up-to-date epidemiological information on prevalence, incidence and geographical distribution of FGS. We can only make conservative estimates of the overall prevalence of the disease and of the 250 million people infected with schistosomiasis, approximately two-thirds of whom (ca. 170 million) are infected by the urogenital form caused by *S. haematobium* (the form with the highest correlation with cases of FGS). Among those 170 million, half of them are women (ca. 85 million) and at least one-third of those women may suffer from FGS. Of them, probably 20 million are girls or young women, most of them lacking suitable medical attention (Hotez and Whitham, 2014). We consider that this lack of validated epidemiological information is the major impediment towards bringing FGS to the forefront of strategic discussions not only in the context of schistosomiasis disease control interventions, but perhaps even more importantly, in the context of addressing women's health in the broadest sense including mental health, sexually transmissible diseases, cancer and reproductive/maternal health. This is especially important when considered in the context of achieving the 2030 Sustainable Development Goals (SDGs) and particularly SDG 3: "Ensure healthy lives and promote well-being for all at all ages". FGS falls within the targets set for SDG3 on at least two accounts: "By 2030, ensure universal access to sexual and reproductive health-care services, including for family planning, information and education, and the integration of reproductive health into national strategies and programmes" and "By 2030, end the epidemics of AIDS, tuberculosis, malaria and neglected tropical diseases and combat hepatitis, water-borne diseases and other communicable diseases". (SDG 3 [www.un.org/sustainabledevelopment/sustainable-development-goals](http://www.un.org/sustainabledevelopment/sustainable-development-goals)).

When examining the case reports, the vast majority of those were in the context of medical care reports from women living in schistosomiasis endemic countries or from individual cases of tourists who acquired FGS in sub-Saharan countries and were diagnosed in the well-equipped health care facilities of western countries. In those reports it was often difficult to be affirmative regarding the causal relationship between schistosomiasis and the described pathology. The high number of FGS descriptions to date has had little impact on performing large scale population based studies to estimate more precisely the FGS burden and to address its public health implications, particularly in relation to gynaecological health or to highly prevalent infections such as HIV or HPV. Therefore, well designed prospective studies addressing the full spectrum of potential target organs, particularly the upper genital tract (Richter et al., 1995), should be conducted in various schistosomiasis endemic areas (including *S. mansoni* and *S. japonicum*).



The main challenge when planning or conducting the above suggested studies resides in the difficulty associated with the diagnosis of FGS. While for FGS affecting the uterine cervix and vagina the recently published WHO pocket atlas (<http://pocketatlas.org>) and the supporting material sets clear criteria to identify the lesions (Norseth et al., 2014), much work is needed to address the diagnosis of lesions in other organs (Richter et al., 1995). Furthermore, even with the available tools there is a great need for trained personnel and appropriate equipment which are not available in many endemic areas.

In terms of disease management, the current gold standard to treat schistosomiasis is a single dose of 40 mg/kg of praziquantel according to the WHO recommendation (WHO, 2016, <http://www.who.int/schistosomiasis/strategy/en/>). Treatment with praziquantel kills the adult worms and provides some regression of inflammatory lesions. However, the recommended regimen is probably not sufficient to prevent and eliminate the eggs associated with FGS (Richter et al., 1996; Poggensee and Feldmeier, 2001; Kjetland et al., 2006a, 2008; Downs et al., 2013). As a preventive measure, regular praziquantel treatment starting in early childhood (including pre-school age children) could be the most effective intervention to prevent the occurrence and development of future complications associated with genital schistosomiasis. However, for a patient who presents herself with severe symptoms of FGS there are no validated therapeutic options. Therefore, there is a great need to search for treatment alternatives, focussing on reducing the pathological process induced by the *Schistosoma* eggs, alternative praziquantel doses or regimens aiming to achieve total elimination of adult worms and therefore interrupting egg production that sustains the pathology.

## 8. Conclusion

The clinical manifestations of FGS, since first reported in the Lancet in 1899 (Madden, 1899), have been continuously described through time in most schistosomiasis endemic areas affected by different *Schistosoma* spp. While the original descriptions mostly highlighted the macroscopic external lesions of the female genital tract, today we know that it can affect all of the genital tract with serious health implications. On the other hand, given the nature of the reports, it is difficult to establish how large or extensive the current burden of disease is; thus only crude extrapolations are possible. FGS appears to be a prevailing condition even with the progress achieved in the implementation of schistosomiasis control strategies. Strategies fundamentally focus on (morbidity) prevention while proper clinical and laboratory diagnosis of FGS remains a significant issue and bottleneck. Women suffering from FGS approach health care providers with complaints about bleeding, infertility or suspicion of having sexually transmitted infections, however little attention is provided because the recognition and treatment of schistosomiasis genital tract lesions requires well trained physicians and specialised infrastructure which are not readily available in most schistosomiasis endemic settings. The scarcity of integrated approaches to address FGS calls for more concerted action in its detection, treatment and prevention, otherwise it will remain a neglected gynaecological disease.

## Acknowledgements

The work was partly funded by Merck KGaA, Germany. JRS is Director of COUNTDOWN which is in receipt of funding from the Department for International Development, UK. The authors would like to thank Marcell Nimfuehr, (Vienna, Austria) for the design of Fig. 1 and Table 1.

## References

- Abruzzi, A., Fried, B., 2011. Coinfection of *Schistosoma* (Trematoda) with bacteria, protozoa and helminths. *Adv. Parasitol.* 77, 1–85.
- Adeniji, K.A., 2001. Morphological features and organ distribution of schistosomal infection. *Afr. J. Med. Med. Sci.* 30, 53–56 (1).
- Adeniran, A., Dimashkieh, H., Nikiforov, Y., 2003. Schistosomiasis of the cervix. *Arch. Pathol. Lab. Med.* 127, 1637–1638 (2).
- Al-Adnani, M.S., Saleh, K.M., 1982. Extraurinary schistosomiasis in Southern Iraq. *Histopathology* 6, 747–752 (3).
- Ali, R., Hillers, A., Stolze, E., 1956. *Schistosoma mansoni* infections of the female genital organs. *Doc. Med. Geogr. Trop.* 8, 335–336 (4).
- Aminu, M.B., Abdullahi, K., Dattijo, L.M., 2014. Tubal ectopic gestation associated with genital schistosomiasis: a case report. *Afr. J. Reprod. Health* 18, 144–146 (5).
- Anosike, J.C., Okere, A.N., Nwoke, B.E., Chukwu, J.U., Nwosu, D.C., Njoku-Tony, R.F., Oguwuike, T.U., Ezike, M.N., Godwin, Okogun, R.A., Obasi, C.U., Ogbusu, F.I., Onyirioha, C.U., Ajero, C.M., Dike, M.U., 2003. Endemicity of vesical schistosomiasis in the Ebonyi Benue river valley, south eastern Nigeria. *Int. J. Hyg. Environ. Health* 206, 205–210 (6).
- Arean, V.M., 1956. Manson's schistosomiasis of the female genital tract. *Am. J. Obstet. Gynecol.* 72, 1038–1053 (7).
- Arora, H.L., Chadda, S., Chadda, V.S., 1986. Schistosomiasis of female genital tract. *Indian J. Pathol. Microbiol.* 29, 71–73 (8).
- Attia, O.M., 1962. A critical study of bilharziasis of the uterus. *J. Obstet. Gynaecol. Br. Emp.* 69, 334–336 (9).
- Attili, V.R., Hira, S.K., Dube, M.K., 1983. Schistosomal genital granulomas: a report of 10 cases. *Br. J. Vener. Dis.* 59, 269–272 (10).
- Bac, D.J., Teichler, M.J., Jonker, L.C., van der Merwe, C.F., 1987. Schistosomiasis in ectopic or unusual sites. A report of 5 cases. *S. Afr. Med. J.* 72, 717–718 (11).
- Badawy, A.H., 1962. Schistosomiasis of the cervix. *Br. Med. J.* 1, 369–372 (12).
- Bahrami, S., Alatassi, H., Slone, S.P., O'Connor, D.M., 2006. Tubal gestation and schistosomiasis: a case report. *J. Reprod. Med.* 51, 595–598 (13).
- Bailey, S.L., Price, J., Llewelyn, M., 2011. Fluke infertility: the late cost of a quick swim. *J. Travel Med.* 18, 61–62 (14).
- Balasz, J., Martinez-Roman, S., Creus, M., Campo, E., Fortuny, A., Vanrell, J.A., 1995. Schistosomiasis: an unusual cause of tubal infertility. *Hum. Reprod.* 10, 1725–1727 (15).
- Barsoum, R.S., Esmat, G., El-Baz, T., 2013. Human schistosomiasis: clinical perspective: review. *J. Adv. Res.* 4, 433–444.
- Batista, T.P., de Andrade, J.J., Filho, L.A., 2010. *Schistosoma mansoni*: an unusual cause of ovarian pseudotumor. *Arch. Gynecol. Obstet.* 281, 141–143 (16).
- Beadles, W., Wilks, D., Monaghan, H., 2007. Fallopian tube carcinoma associated with schistosomiasis. *J. Infect.* 55, e121–e123 (17).
- Bellingham, F.R., 1972. Genital bilharzia: a report of 3 cases. *Aust. N. Z. J. Obstet. Gynaecol.* 12, 267–268 (18).
- Berezowska, S., Tomoka, T., Kamiza, S., Milner Jr., D.A., Langer, R., 2012. Surgical pathology in sub-Saharan Africa—volunteering in Malawi. *Virchows Arch.* 460, 363–370 (19).
- Berry, A., 1966. A cytopathological and histopathological study of bilharziasis of the female genital tract. *J. Pathol. Bacteriol.* 91, 325–338 (20).
- Berry, A., 1971. Evidence of gynecologic bilharziasis in cytologic material. A morphologic study for cytologists in particular. *Acta Cytol.* 15, 482–498 (21).
- Berry, A., 1976. Multispecies schistosomal infections of the female genital tract detected in cytology smears. *Acta Cytol.* 20, 361–365 (22).
- Bianchi, L., De Carneri, I., 1970. Imported schistosomiasis. *Trans. R. Soc. Trop. Med. Hyg.* 64, 650–651 (23).
- Billy-Brissac, R., Foucan, L., Gallais, A., Wan-Ajouhu, G., Roudier, M., 1994. Genital *Schistosoma mansoni* bilharziasis in women: apropos of 2 cases in Guadeloupe. *Med. Trop. (Mars)* 54, 345–348 (24).
- Bittencourt, A.L., Cardoso de Almeida, M.A., lunes, M.A., Casulari da Motta, L.D., 1980. Placental involvement in schistosomiasis mansoni. Report of four cases. *Am. J. Trop. Med. Hyg.* 29, 571–575 (25).
- Bland, K.G., Gelfand, M., 1970a. The effects of schistosomiasis on the fallopian tubes in the African female. *J. Obstet. Gynaecol. Br. Commonw.* 77, 1024–1027 (26).
- Bland, K.G., Gelfand, M., 1970b. The influence of urinary bilharziasis on vesico-vaginal fistula in relation to causation and healing. *Trans. R. Soc. Trop. Med. Hyg.* 64, 588–592 (27).
- Blum, J., Beck, B., Strnad, I., Hatz, C., 1998. Vulvar lesion in urogenital schistosomiasis (*S. haematobium*). *Z. Geburtshilfe Neonatol.* 202, 255–257 (28).
- Boers, K.E., Sastrowijoto, P.H., Elzakker van, E.P., Hermans, M.P., 2003. Schistosomiasis of the uterus in a patient with dysmenorrhoea and menorrhagia. *Eur. J. Obstet. Gynecol. Reprod. Biol.* 108, 106–108 (29).
- Boulle, P., Norelovu, M., 1964. Bilharzia of the female genital tract. *S. Afr. Obscec. Gynaecol.* 2, 48–50 (30).
- Breda, Y., Bayon, P., Rodier, J., Maistre, B., 1983. Tubal localization of genital bilharziasis. Apropos of a clinical case discovered during surgery. *Dakar Med.* 28, 173–178 (31).
- Bugalho, A., Strolego, F., Benussi, G., Pregazzi, R., Osman, N., 1991a. Schistosomiasis: possible cause of ectopic pregnancy. Four clinical cases. *Minerva Ginecol.* 43, 577–579 (32).
- Bugalho, A., Strolego, F., Pregazzi, R., Osman, N., Ching, C., 1991b. Extrauterine pregnancy in Mozambique. *Int. J. Gynaecol. Obstet.* 34, 239–242 (33).
- Bullough, C.H., 1976. Infertility and bilharziasis of the female genital tract. *Br. J. Obstet. Gynaecol.* 83, 819–822 (34).

- Burgos, J.F., Pontesneto, L., 1963. Finding of *Schistosoma mansoni* ova in female genitalia. An. Bras. Ginecol. 55, 309–316 (35).
- Camain, R., Navarranne, P., Ayite, E., 1951. Two cases of adnexitis from *Schistosoma haematobium* seen at Dakar. Bull. Soc. Pathol. Exot. Filiales 44, 202–208 (36).
- Carey, F.M., Quah, S.P., Hedderwick, S., Finnegan, D., Dinsmore, W.W., Maw, R.D., 2001. Genital schistosomiasis. Int. J. STD AIDS 12, 609–611 (37).
- Carpenter, C.B., Mozley, P.D., Lewis, N.G., 1964. Schistosomiasis japonica involvement of the female genital tract. JAMA 188, 647–650 (38).
- Catteau, X., Fakhri, A., Albert, V., Doukoure, B., Noel, J.C., 2011. Genital schistosomiasis in European women. ISRN Obstet. Gynecol. 2011, 242140 (39).
- Cavalcanti, M.G., Goncalves, M.M., Barreto, M.M., Silva, A.H., Madi, K., Peralta, J.M., Igreja, R.P., 2011. Genital schistosomiasis mansoni concomitant to genital tumor in areas of low endemicity: challenging diagnosis. Braz. J. Infect. Dis. 15, 174–177 (40).
- Charlewood, G.P., Shippel, S., Renton, H., 1949. Schistosomiasis in gynaecology. J. Obstet. Gynaecol. Br. Emp. 56, 367–385 (41).
- Chaves, E., Palitot, P., 1964. Pelvic Schistosomiasis. Am. J. Obstet. Gynecol. 89, 1000–1002 (42).
- Chaves, E., 1966. Malignant mesodermal mixed tumors of the uterus. Report of 3 cases one of which associated with squamous cell carcinoma of the cervix and schistosomiasis of the uterine wall. Am. J. Obstet. Gynecol. 96, 1017–1021 (43).
- Chaves, 1988. Manson's schistosomiasis of the female genital tract a clinical and pathologic study of 14 cases. J. Bras. Ginecol. 98, 115–119 (44).
- Chen, W., Flynn, E.A., Shreefer, M.J., Blagg, N.A., 2012. Schistosomiasis: an unusual finding of the cervix. Obstet. Gynecol. 119, 472–475 (45).
- Chenault, C., Hoang, M.P., 2006. An unusual cervical finding. Female genital schistosomiasis with associated cervical severe squamous dysplasia (cervical intraepithelial neoplasia grade III). Arch. Pathol. Lab. Med. 130, e37–e38 (46).
- Ching-ch'ien, K., 1951. Pathology of Schistosomiasis, first ed. Commercial Press, Shanghai (47).
- Coelho, L.H., Carvalho, G., Carvalho, J.M., 1979. Carcinoma in situ and invasive squamous cell carcinoma associated with schistosomiasis of the uterine cervix a report of three cases. Acta Cytol. 23, 45–48 (48).
- Coetzee, L.F., Jaffe, A.A., 1971. Mullerian duct dysgenesis and bilharziasis: report of a case. S. Afr. Med. J. 45, 447–451 (49).
- Colley, D.G., Bustinduy, A.L., Secor, W.E., King, C.H., 2014. Human schistosomiasis. Lancet 2014 (383), 2253–2264.
- Corachan, M., Almeda, J., Vinuesa, T., Valls, M.E., Mejias, T., Jou, P., Biarnes, C., Pous, E., Vilana, R., Gascon, J., 1997. Schistosomiasis imported by Spanish travelers: clinico-epidemiologic study of 80 cases. Med. Clin. (Barc) 108, 721–725 (50).
- Cornier, E., Jouhanet, H., Feintuch, H., Delafontaine, D., Dao, C., Bouccara, L., 1981. Intra-uterine pregnancy after microsurgical salpingostomy for bilharziasis of the tubal ampulla. Nouv. Presse Med. 10, 2514–2515 (51).
- Crump, J.A., Murdoch, D.R., Chambers, S.T., Aickin, D.R., Hunter, L.A., 2000. Female genital schistosomiasis. J. Travel Med. 7, 30–32 (52).
- Delmondes, L.M., Cruz, M.A., Guimaraes, M.K., Santana, L.G., Goncalves, V.P., Brito, H. L., 2014. Endocervical schistosomiasis: case report. Rev. Bras Ginecol. Obstet. 36, 276–280 (53).
- DeMille, P.A., Bourquin, P., Sun, C.C., Kauffman, L., 1995. Cytologic diagnosis of *Schistosoma haematobium* in routine cervicovaginal smear from an infertile woman. Diagn. Cytopathol. 13, 181–182 (54).
- Diouf, B., Spay, G., Toure, P., 1973. Genital bilharziasis in women. Bull. Soc. Med. Afr. Noire Lang. Fr. 18, 517–519 (55).
- Downs, J.A., Kabangila, R., Verweij, J.J., Jaka, H., Peck, R.N., Kalluvya, S.E., Changalucha, J.M., Johnson, W.D., van Lieshout, L., Fitzgerald, D.W., 2013. Detectable urogenital schistosome DNA and cervical abnormalities 6 months after single-dose praziquantel in women with *Schistosoma haematobium* infection. Trop. Med. Int. Health 18, 1090–1096.
- Downs, J.A., Mguta, C., Kaatano, G.M., Mitchell, K.B., Bang, H., Simplicio, H., Kalluvya, S.E., Changalucha, J.M., Johnson Jr., W.D., Fitzgerald, D.W., 2011. Urogenital schistosomiasis in women of reproductive age in Tanzania's Lake Victoria region. Am. J. Trop. Med. Hyg. 84, 364–369 (56).
- Downs, J.A., van Dam, G.J., Changalucha, J.M., Corstjens, P.L., Peck, R.N., de Dood, C.J., Bang, H., Andreasen, A., Kalluvya, S.E., van Lieshout, L., Johnson Jr., W.D., Fitzgerald, D.W., 2012. Association of Schistosomiasis and HIV infection in Tanzania. Am. J. Trop. Med. Hyg. 87, 868–873 (57).
- Dzeing-Ella, A., Mechai, F., Consigny, P.H., Zerai, L., Viard, J.P., Lecuit, M., Lortholary, O., 2009. Cervical schistosomiasis as a risk factor of cervical uterine dysplasia in a traveler. Am. J. Trop. Med. Hyg. 81, 549–550 (58).
- Edington, G.M., Nwabuebo, I., Junaid, T.A., 1975. The pathology of schistosomiasis in Ibadan, Nigeria with special reference to the appendix, brain, pancreas and genital organs. Trans. R. Soc. Trop. Med. Hyg. 69, 153–156 (59).
- Ekoukou, D., Luzolo-Lukanu, A., Mulard, C., Bazin, C., Ng Wing Tin, L., 1995. Peritoneal and tubal *Schistosoma haematobium* bilharziasis. Two case reports. J. Gynecol. Obstet. Biol. Reprod. (Paris) 24, 819–824 (60).
- El-Bedri, L., 1958. Ectopic pregnancy caused by *Schistosoma haematobium* infection of the fallopian tube; a case report. Am. J. Obstet. Gynecol. 76, 515–517 (61).
- El-Mahgoub, S., 1972. Antispermatozoal antibodies in infertile women with cervicovaginal schistosomiasis. Am. J. Obstet. Gynecol. 112, 781–784 (62).
- El-Mahgoub, S., 1982. Pelvic schistosomiasis and infertility. Int. J. Gynaecol. Obstet. 20, 201–206 (63).
- El-maraghy, M.A., Elyan, A., El-Leithy, A.G., El-Tehewey, F.A., Senna, I.A., El-Tawil, A., Naguib, F., 1982. Bilharziasis of the female genital tract; new concepts. J. Egypt. Soc. Parasitol. 12, 179–186 (64).
- Eladl, A.E., Shebl, A.M., Elkashef, W.F., Zalata, K.R., 2012. Bilharzial endocervical polyp. Indian J. Pathol. Microbiol. 55, 377–378 (65).
- Elling, D., Kupferschmidt, H.G., 1988. Genital schistosomiasis—diagnosis and therapy. Zentralbl. Gynakol. 110, 671–676 (66).
- Eogan, M., O'Malley, A., Flavin, R., Gillan, J., McKenna, P., Coulter-Smith, S., 2002. Ectopic pregnancy associated with tubal schistosomiasis. Ir. Med. J. 95, 250 (67).
- Faria, C.A., Conceicao, J.C., Valadares, T.F., Rodrigues, B., Carneiro, L., 2010. *Schistosoma mansoni*: a rare cause of tubal infection. Braz. J. Infect. Dis. 14, 288–290 (68).
- Feldmeier, H., Krantz, I., Poggensee, G., 1995a. Female genital schistosomiasis: a neglected risk factor for the transmission of HIV? Trans. R. Soc. Trop. Med. Hyg. 89, 237.
- Feldmeier, H., Poggensee, G., Krantz, I., Helling-Giese, G., 1995. Female genital schistosomiasis. New challenges from a gender perspective. Trop. Geogr. Med. 47, S2–S15.
- Foda, M.S., Youssef, A.F., Shafeek, M.A., 1961. Arrhenoblastoma associated with bilharziasis. J. Obstet. Gynaecol. Br. Emp. 68, 986–990 (69).
- Frost, O., 1975. Bilharzia of the Fallopian tube. S. Afr. Med. J. 49, 1201–1203 (70).
- Garba, M., Almoustapha, T., Garba, A., Nouhou, H., 2004. Extra uterine pregnancy associated with a tubal schistosomiasis due to *Schistosoma haematobium*. A case report from Niger. Bull. Soc. Pathol. Exot. 97, 41–42 (71).
- Gelfand, M., Ross II, W.F., 1953. The distribution of schistosome ova in the genitourinary tract in subjects of bilharziasis. Trans. R. Soc. Trop. Med. Hyg. 47, 218–220 (72).
- Gelfand, M., Ross, M.D., Blair, D.M., Weber, M.C., 1971. Distribution and extent of schistosomiasis in female pelvic organs, with special reference to the genital tract, as determined at autopsy. Am. J. Trop. Med. Hyg. 20, 846–849 (73).
- Gibson, L.R., Li, B., Remold, S.K., 2010. Treating cofactors can reverse the expansion of a primary disease epidemic. BMC Infect. Dis. 10, 248.
- Gigase, P.L., Vanderputte, S.R., 1980. Presence of *Schistosoma haematobium* eggs in an ovarian teratoma. Ann. Soc. Belg. Med. Trop. 60, 107–109 (74).
- Gilbert, B., 1943. Schistosomiasis (Bilharziasis) of the female genital tract and neighbouring tissues. J. Obstet. Gynaecol. Br. Emp. 50 (75).
- Gloor, E., Merz, W.R., Tolck, P., 1979. Female genital bilharziasis. 1 case. Schweiz. Med. Wochenschr. 109, 55–59 (76).
- Goncalves Amorim, A., Alves Barbosa Pagio, F., Neves Ferreira, R., Chambo Filho, A., 2014. Genital schistosomiasis: a report on two cases of ovarian carcinomas containing viable eggs of *Schistosoma mansoni*. Case Rep. Obstet. Gynecol. 2014, 508718 (77).
- Gouzou, A., Baldassini, B., Opa, J.F., 1984. Anatomicopathological aspects of genital bilharziasis in women. Med. Trop. (Mars) 44, 331–337 (78).
- Goverde, A.J., Schats, R., van Berlo, P.J., Claessen, F.A., 1996. An unexpected guest in follicular fluid. Hum. Reprod. 11, 531–532 (79).
- Gras, C., Andre, J.L., Pecarrere, J.L., Normand, P., Barabe, P., 1980. Schistosomiasis of vulvae (case report and comments) (author's transl). Med. Trop. (Mars) 40, 335–338 (80).
- Gryseels, B., Polman, K., Clerinx, J., Kestens, L., 2006. Human schistosomiasis. Lancet 368, 1106–1118.
- Gwavava, N.J., Harrison, D.J., Gwata, T.F., Zengeza, C., 1984. Incidence of schistosomiasis in surgical biopsies: a review of 284 cases. Cent. Afr. J. Med. 30, 241–245 (81).
- Harouny, A., Pedersen, H., 1988. Pelveo-peritoneal schistosomiasis as a cause of primary infertility. Int. J. Gynaecol. Obstet. 27, 467–469 (82).
- Hassim, A.M., 1966. Tubal gestation associated with schistosomiasis. J. Obstet. Gynaecol. Br. Commonw. 73, 855–856 (83).
- Hegertun, I.E., Sulheim Gundersen, K.M., Klepp, E., Zulu, S.G., Gundersen, S.G., Taylor, M., Kvalsvig, J.D., Kjetland, E.F., 2013. *S. haematobium* as a common cause of genital morbidity in girls: a cross-sectional study of children in South Africa. PLoS Negl. Trop. Dis. 7, e2104.
- Helling-Giese, G., Sjaastad, A., Poggensee, G., Kjetland, E.F., Richter, J., Chitsulo, L., Kumwenda, N., Racz, P., Roald, B., Gundersen, S.G., Krantz, I., Feldmeier, H., 1996. Female genital schistosomiasis (FGS): relationship between gynecological and histopathological findings. Acta Trop. 62, 257–267 (84).
- Hillers, A.A., Wiersema, J.P., 1961. Metrorrhagia caused by *Schistosoma mansoni*. Trop. Geogr. Med. 13, 115–118 (85).
- Hirayama, K., 2006. Schistosomiasis and Immunity. Scientific Working Group, Report on Schistosomiasis, TDR/SWG/07, 2006. Working paper 14. <http://www.who.int/tdr/publications/tdr-research-publications/swg-report-schistosomiasis/en/>.
- Hoffmann, H., Bauerfeind, I., 2003. High tissue egg burden mechanically impairing the tubal motility in genital schistosomiasis of the female. Acta Obstet. Gynecol. Scand. 82, 970–971 (86).
- Hotez, P., Whitham, M., 2014. Helminth infections: a new global women's health agenda. Obstet. Gynecol. 123, 155–160.
- Iskander, S.G., Kamel, R., 1968. Bilharziasis in a malignant Brenner-cell tumour of the ovary. J. Egypt. Med. Assoc. 51, 922–928 (87).
- Jourdan, P.M., Holmen, S.D., Gundersen, S.G., Roald, B., Kjetland, E.F., 2011a. HIV target cells in *Schistosoma haematobium*-infected female genital mucosa. Am. J. Trop. Med. Hyg. 85, 1060–1064 (88).
- Jourdan, P.M., Randrianasolo, B.S., Feldmeier, H., Chitsulo, L., Ravoniarimbinina, P., Roald, B., Kjetland, E.F., 2013. Pathologic mucosal blood vessels in active female genital schistosomiasis: new aspects of a neglected tropical disease. Int. J. Gynecol. Pathol. 32, 137–140 (89).
- Jourdan, P.M., Roald, B., Poggensee, G., Gundersen, S.G., Kjetland, E.F., 2011b. Increased vascularity in cervicovaginal mucosa with *Schistosoma haematobium* infection. PLoS Negl. Trop. Dis. 5, e1170 (90).



- Joyce, P.R., Blackwell, J.B., Charters, A.D., 1972. Schistosomiasis in gynaecology—two cases in immigrants in Western Australia. *Aust. N. Z. J. Obstet. Gynaecol.* 12, 137–141 (91).
- Kahn, H.J., Stroud, B.J., Berry, A.V., 1978. *Schistosoma mansoni* worm in ovarian cystic teratoma. A case report. *S. Afr. Med. J.* 54, 673–674 (92).
- Kameh, D., Smith, A., Brock, M.S., Ndubisi, B., Masood, S., 2004. Female genital schistosomiasis: case report and review of the literature. *South. Med. J.* 97, 525–527 (93).
- Kallestrup, P., Zinyama, R., Gomo, E., Butterworth, A.E., van Dam, G.J., Erikstrup, C., Ullum, H., 2005. Schistosomiasis and HIV-1 infection in rural Zimbabwe: implications of coinfection for excretion of eggs. *J. Infect. Dis.* 191, 1311–1320.
- Kingsley, H.J., 1969. 3 cases of cutaneous schistosomiasis of the vulva in 3 African women. *Cent. Afr. J. Med.* 15, 285–286 (94).
- Kjetland, E.F., Hove, R.J., Gomo, E., Midzi, N., Gwanzura, L., Mason, P., Friis, H., Verweij, J.J., Gundersen, S.G., Ndhlovu, P.D., Mduluzi, T., Van Lieshout, L., 2009. Schistosomiasis PCR in vaginal lavage as an indicator of genital *Schistosoma haematobium* infection in rural Zimbabwean women. *Am. J. Trop. Med. Hyg.* 81, 1050–1055 (95).
- Kjetland, E.F., Kurewa, E.N., Mduluzi, T., Midzi, N., Gomo, E., Friis, H., Gundersen, S.G., Ndhlovu, P.D., 2010a. The first community-based report on the effect of genital *Schistosoma haematobium* infection on female fertility. *Fertil. Steril.* 94, 1551–1553 (96).
- Kjetland, E.F., Kurewa, E.N., Ndhlovu, P.D., Midzi, N., Gwanzura, L., Mason, P.R., Gomo, E., Sandvik, L., Mduluzi, T., Friis, H., Gundersen, S.G., 2008. Female genital schistosomiasis—a differential diagnosis to sexually transmitted disease: genital itch and vaginal discharge as indicators of genital *Schistosoma haematobium* morbidity in a cross-sectional study in endemic rural Zimbabwe. *Trop. Med. Int. Health* 13, 1509–1517.
- Kjetland, E.F., Leutscher, P.D., Ndhlovu, P.D., 2012. A review of female genital schistosomiasis. *Trends Parasitol.* 28, 58–65.
- Kjetland, E.F., Mduluzi, T., Ndhlovu, P.D., Gomo, E., Gwanzura, L., Midzi, N., Mason, P.R., Friis, H., Gundersen, S.G., 2006a. Genital schistosomiasis in women: a clinical 12-month in vivo study following treatment with praziquantel. *Trans. R. Soc. Trop. Med. Hyg.* 100, 740–752.
- Kjetland, E.F., Ndhlovu, P.D., Gomo, E., Mduluzi, T., Midzi, N., Gwanzura, L., Mason, P.R., Sandvik, L., Friis, H., Gundersen, S.G., 2006b. Association between genital schistosomiasis and HIV in rural Zimbabwean women. *AIDS* 20, 593–600.
- Kjetland, E.F., Ndhlovu, P.D., Mduluzi, T., Deschoolmeester, V., Midzi, N., Gomo, E., Gwanzura, L., Mason, P.R., Vermorken, J.B., Friis, H., Gundersen, S.G., Baay, M.F., 2010b. The effects of genital *Schistosoma haematobium* on human papillomavirus and the development of cervical neoplasia after five years in a Zimbabwean population. *Eur. J. Gynaecol. Oncol.* 31, 169–173 (97).
- Kjetland, E.F., Ndhlovu, P.D., Mduluzi, T., Gomo, E., Gwanzura, L., Mason, P.R., Kurewa, E.N., Midzi, N., Friis, H., Gundersen, S.G., 2005. Simple clinical manifestations of genital *Schistosoma haematobium* infection in rural Zimbabwean women. *Am. J. Trop. Med. Hyg.* 72, 311–319 (98).
- Kjetland, E.F., Norseth, H.M., Taylor, M., Lillebo, K., Kleppa, E., Holmen, S.D., Andebirhan, A., Yohannes, T.H., Gundersen, S.G., Vennervald, B.J., Bagratee, J., Onsrud, M., Leutscher, P.D., 2014. Classification of the lesions observed in female genital schistosomiasis. *Int. J. Gynaecol. Obstet.* 127, 227–228.
- Kjetland, E.F., Poggensee, G., Helling-Giese, G., Richter, J., Sjaastad, A., Chitsulo, L., Kumwenda, N., Gundersen, S.G., Krantz, I., Feldmeier, H., 1996. Female genital schistosomiasis due to *Schistosoma haematobium*. Clinical and parasitological findings in women in rural Malawi. *Acta Trop.* 62, 239–255 (99).
- Kleppa, E., Klinge, K.F., Galapaththi-Arachchige, H.N., Holmen, S.D., Lillebo, K., Onsrud, M., Gundersen, S.G., Taylor, M., Ndhlovu, P., Kjetland, E.F., 2015. *Schistosoma haematobium* infection and CD4+ T-cell levels: a cross-sectional study of young South African women. *PLoS One* 10, e0119326.
- Kleppa, E., Ramsuran, V., Zulu, S., Karlsen, G.H., Bere, A., Passmore, J.A., Ndhlovu, P., Lillebo, K., Holmen, S.D., Onsrud, M., Gundersen, S.G., Taylor, M., Kjetland, E.F., Ndung'u, T., 2014. Effect of female genital schistosomiasis and anti-schistosomal treatment on monocytes, CD4+ T-cells and CCR5 expression in the female genital tract. *PLoS One* 9, e98593.
- Koller, A.B., 1975. Granulomatous lesions of the cervix uteri in Black patients. *S. Afr. Med. J.* 49, 1228–1232 (100).
- Krolikowski, A., Janowski, K., Larsen, J.V., 1995. Asherman syndrome caused by schistosomiasis. *Obstet. Gynecol.* 85, 898–899 (101).
- Kunin, J., Bejar, J., Eldar, S., 1996. Schistosomiasis as a cause of rectovaginal fistula: a brief case report. *Isr. J. Med. Sci.* 32, 1109–1111 (102).
- Lambertucci, J.R., Villamil, Q.T., Savi, D., Dias, I.C., 2009. Genital schistosomiasis mansoni: tubal tumor and parietal peritoneum involvement diagnosed during laparoscopy. *Rev. Soc. Bras. Med. Trop.* 42, 583–586 (103).
- Lana, F.V., 1961. Ovarian schistosomiasis. Report of a case. *J. Med. (Oporto)* 46, 567–571 (104).
- Landry, P., Favrat, B., Raeber, P.A., 1996. Genital schistosomiasis after a missed diagnosis of Katayama syndrome. *J. Travel Med.* 3, 237–238 (105).
- Laven, J.S., Vleugels, M.P., Dofferhoff, A.S., Bloembergen, P., 1998. Schistosomiasis haematobium as a cause of vulvar hypertrophy. *Eur. J. Obstet. Gynecol. Reprod. Biol.* 79, 213–216 (106).
- Laxman, V.V., Adamson, B., Mahmood, T., 2008. Recurrent ectopic pregnancy due to *Schistosoma haematobium*. *J. Obstet. Gynaecol.* 28, 461–462 (107).
- Le Guyader, A., Kekeh, K., Richier, E.M., Ferrand, B., Chevrel, M.L., 1965. Genital bilharziasis in women. A case of endometritis due to *Schistosoma haematobium*. *Arch. Anat. Pathol. (Paris)* 13, 256–258 (108).
- Lee, K.F., Hsueh, S., Tang, M.H., 2000. Schistosomiasis of the ovary with endometriosis and corpus hemorrhagicum: a case report. *Chang Gung Med. J.* 23, 438–441 (109).
- Lemos, C., Lobo, M.J., Leme, M.A., Serapiao, C.J., 1960. Arrhenoblastoma associated with Manson's schistosomiasis of the ovary. *Hospital (Rio J)* 57, 851–862 (110).
- Leslie, T.A., Goldsmith, P.C., Dowd, P.M., 1993. Vulval schistosomiasis. *J. R. Soc. Med.* 86, 51 (111).
- Letterie, G.S., Sakas, E.L., 1991. Histology of proximal tubal obstruction in cases of unsuccessful tubal canalization. *Fertil. Steril.* 56, 831–835 (112).
- Leutscher, P., Raharisolo, C., Pecarrere, J.L., Ravaolimalala, V.E., Serieye, J., Rasendramino, M., Vennervald, B., Feldmeier, H., Esterre, P., 1997. *Schistosoma haematobium* induced lesions in the female genital tract in a village in Madagascar. *Acta Trop.* 66, 27–33 (113).
- Leutscher, P., Ravaolimalala, V.E., Raharisolo, C., Ramarokoto, C.E., Rasendramino, M., Raobelison, A., Vennervald, B., Esterre, P., Feldmeier, H., 1998. Clinical findings in female genital schistosomiasis in Madagascar. *Trop. Med. Int. Health* 3, 327–332 (114).
- Loubière, R., Ette, M., Nozais, J.P., 1977. La bilharziose en Côte d'Ivoire vue du laboratoire d'anatomie pathologique. *Med. Afr. Noire* 24, 453–461 (115).
- Madden, F.C., 1899. A case of bilharzia of the vagina. *Lancet* 153, 1716 (116).
- Mawad, N.M., Hassanein, O.M., Mahmoud, O.M., Taylor, M.G., 1992. Schistosomal vulval granuloma in a 12 year old Sudanese girl. *Trans. R. Soc. Trop. Med. Hyg.* 86, 644 (117).
- Mayr, D., Straub, J., Müller-Hocker, J., 2005. Schistosomiasis in a leiomyoma of the uterus. *Pathologe* 26, 300–303 (118).
- McKee, P.H., Wright, E., Hutt, M.S., 1983. Vulval schistosomiasis. *Clin. Exp. Dermatol.* 8, 189–194 (119).
- Mensah, A., Wade, A., Tossou, H., Akpo, C., 1972. Genital localization of bilharziasis (4 cases). *Bull. Soc. Med. Afr. Noire Lang. Fr.* 17, 562–566 (120).
- Mohammed, A.Z., Edino, S.T., Samaila, A.A., 2007. Surgical pathology of schistosomiasis. *J. Natl. Med. Assoc.* 99, 570–574 (121).
- Mohammed, A.Z., Uzoho, C.C., Galadanci, H.S., Ashimi, A., 2004. Ruptured tubal gestation: an unusual presentation of *Schistosoma haematobium* infection of the fallopian tube. *Trop. Doct.* 34, 48–49 (122).
- Morice, P., Chapron, C., Vacher Lavenue, M.C., Terrasse, G., Dubuisson, J.B., 1996. Genital bilharziasis and female infertility. Review of the literature and three case reports. *Contracept. Fertil. Sex.* 24, 56–61 (123).
- Morice, P., Gadonneix, P., Van den Akker, M., Antoine, M., Villet, R., 1993. Tubal bilharziasis. *J. Gynecol. Obstet. Biol. Reprod. (Paris)* 22, 848–850 (124).
- Moubayed, P., Lepere, J.F., Mwakyoma, H., Neuvians, D., 1994. Carcinoma of the uterine cervix and schistosomiasis. *Int. J. Gynaecol. Obstet.* 45, 133–139 (125).
- Moubayed, P., Ziehe, A., Peters, J., Mwakyoma, H., Schmidt, D., 1995. Carcinoma of the uterine cervix associated with schistosomiasis and induced by human papillomaviruses. *Int. J. Gynaecol. Obstet.* 49, 175–179 (126).
- Mouktar, M., 1966. Functional disorders due to bilharzial infection of the female genital tract. *J. Obstet. Gynaecol. Br. Commonw.* 73, 307–310 (127).
- Mushayabasa, S., Bhunu, C.P., 2011. Modeling schistosomiasis and HIV/AIDS codynamics. *Comput. Math. Methods Med.* 2011, 846174.
- Mwanakasale, V., Vouatsou, P., Sukwa, T.Y., Ziba, M., Ernest, A., Tanner, M., 2003. Interactions between *Schistosoma haematobium* and human immunodeficiency virus type 1: the effects of coinfection on treatment outcomes in rural Zambia. *Am. J. Trop. Med. Hyg.* 69, 420–428.
- Narabayashi, 1914. *Verh. Jap. Path. Ges.* 4, 123 (128).
- Nayama, M., Garba, A., Boulama-Jackou, M.L., Toure, A., Idi, N., Garba, M., Nouhou, H., Decanter, C., 2007. Uro-genital schistosomiasis with *S. haematobium* and infertility in Niger. Prospective study of 109 cases. *Mali Med.* 22, 15–21 (129).
- Ndeffo Mbah, M.L., Gilbert, J.A., Galvani, A.P., 2014. Evaluating the potential impact of mass praziquantel administration for HIV prevention in *Schistosoma haematobium* high-risk communities. *Epidemics* 7, 22–27.
- Ndeffo Mbah, M.L., Kjetland, E.F., Atkins, K.E., Poolman, E.M., Orenstein, E.W., Meyers, L.A., Townsend, J.P., Galvani, A.P., 2013a. Cost-effectiveness of a community-based intervention for reducing the transmission of *Schistosoma haematobium* and HIV in Africa. *Proc. Natl. Acad. Sci. U.S.A.* 110, 7952–7957.
- Ndeffo Mbah, M.L., Poolman, E.M., Drain, P.K., Coffee, M.P., van der Werf, M.J., Galvani, A.P., 2013b. HIV and *Schistosoma haematobium* prevalences correlate in sub-Saharan Africa. *Trop. Med. Int. Health* 18, 1174–1179.
- Nguyen, T., Kols, A., 1997. Infertility in Developing Countries. Program for Appropriate Technology in Health, 15.
- Norseth, H.M., Ndhlovu, P.D., Kleppa, E., Randrianasolo, B.S., Jourdan, P.M., Roald, B., Holmen, S.D., Gundersen, S.G., Bagratee, J., Onsrud, M., Kjetland, E.F., 2014. The colposcopic atlas of schistosomiasis in the lower female genital tract based on studies in Malawi, Zimbabwe, Madagascar and South Africa. *PLoS Negl. Trop. Dis.* 8, e3229.
- North, M., Dubinchik, I., Hamid, A., Elderiny, S., Sayegh, R., 2003. Association between cervical schistosomiasis and cervical cancer. A report of 2 cases. *J. Reprod. Med.* 48, 995–998 (131).
- Nouhou, H., Seve, B., Idi, N., Moussa, F., 1998. Schistosomiasis of the female genital tract: anatomoclinical and histopathological aspects. Apropos of 26 cases. *Bull. Soc. Pathol. Exot.* 91, 221–223 (132).
- N'Zoukoudi-N'Doundou, M.Y., Dirat, I., Akouala, J.J., Penchenier, L., Makuwa, M., Rey, J.L., 1995. Bilharziasis and human immunodeficiency virus infection in Congo. *Med. Trop. (Mars)* 55, 249–251.
- Ogunniyi, S.O., Nganwuchu, A.M., Adenle, M.A., Dare, F.O., 1994. Pregnancy following infertility due to pelvic schistosomiasis—a case report. *West Afr. J. Med.* 13, 132–133 (133).

- Okonofua, F.E., Ojo, O.S., Odunsi, O.A., Odesanmi, W.O., 1990. Ectopic pregnancy associated with tubal schistosomiasis in a Nigerian woman. *Int. J. Gynaecol. Obstet.* 32, 281–284 (134).
- Onuigbo, W.I., Twomey, D., 1978. Schistosomiasis of ovarian thecoma—a case report. *Med. J. Zambia* 12, 27–28 (135).
- Orlandini, L.F., Munhoz, A.S., Nogaroto, M., Galao, E.A., Bagarelli, L.B., Oliani, A.H., 2009. Tubal schistosomiasis in Brazilian women: a case report. *Prague Med. Rep.* 110, 250–254 (136).
- Owusu-Bempah, A., Odoi, A.T., Dassah, E.T., 2013. Genital schistosomiasis leading to ectopic pregnancy and subfertility: a case for parasitic evaluation of gynaecologic patients in schistosomiasis endemic areas. *Case Rep. Obstet. Gynecol.* 2013, 634264 (137).
- Paradinas, F.J., 1972. Schistosomiasis in a cystic teratoma of the ovary. *J. Pathol.* 106, 123–126 (138).
- Petry, K.U., Scholz, U., Hollwitz, B., Von Wasielewski, R., Meijer, C.J., 2003. Human papillomavirus, coinfection with *Schistosoma hematobium*, and cervical neoplasia in rural Tanzania. *Int. J. Gynecol. Cancer* 13, 505–509 (139).
- Picaud, A., Walter, P., Bennani, S., Minko Mi Etoua, D., Nlome Nze, A.R., 1990. Fallopian tube bilharziasis caused by *Schistosoma intercalatum* disclosed by hemoperitoneum. *Arch. Anat. Cytol. Pathol.* 38, 208–211 (140).
- Pimentafilho, R., 1964. Schistosomiasis of the uterine cervix associated with carcinoma. (Presentation of a case). *An. Bras. Ginecol.* 58, 13–18 (141).
- Pitta, H.D.R., 1959. Tuboovarian localization of schistosomiasis mansonii. *Rev. Bras. Cir.* 37, 5–22 (142).
- Poggensee, G., Feldmeier, H., Krantz, I., 1999. Schistosomiasis of the female genital tract: public health aspects. *Parasitol. Today* 15, 378–381.
- Poggensee, G., Feldmeier, H., 2001. Female genital schistosomiasis: facts and hypotheses. *Acta Trop.* 79, 193–210.
- Poggensee, G., Kiwelu, I., Saria, M., Richter, J., Krantz, I., Feldmeier, H., 1998. Schistosomiasis of the lower reproductive tract without egg excretion in urine. *Am. J. Trop. Med. Hyg.* 59, 782–783 (143).
- Poggensee, G., Kiwelu, I., Weger, V., Goppner, D., Diedrich, T., Krantz, I., Feldmeier, H., 2000. Female genital schistosomiasis of the lower genital tract: prevalence and disease-associated morbidity in northern Tanzania. *J. Infect. Dis.* 181, 1210–1213 (144).
- Poggensee, G., Krantz, I., Kiwelu, I., Diedrich, T., Feldmeier, H., 2001. Presence of *Schistosoma mansoni* eggs in the cervix uteri of women in Mwanza district, Tanzania. *Trans. R. Soc. Trop. Med. Hyg.* 95, 299–300 (145).
- Qunhua, L., Jiawen, Z., Bozhao, L., Zhilan, P., Huijie, Z., Shaoying, W., Delun, M., Hsu, L.N., 2000. Investigation of association between female genital tract diseases and *Schistosoma japonica* infection. *Acta Trop.* 77, 179–183 (146).
- Rachaneni, S., Yaqoob, T., Spencer, C., 2007. Cervical schistosomiasis in an HIV-positive patient with evidence of HPV infection. *J. Obstet. Gynaecol.* 27, 632–633 (147).
- Rand, R.J., Lowe, J.W., 1998. Schistosomiasis of the uterine cervix. *Br. J. Obstet. Gynaecol.* 105, 1329–1331 (148).
- Randrianasolo, B.S., Jourdan, P.M., Ravoniarimbina, P., Ramarokoto, C.E., Rakotomanana, F., Ravaomalalala, V.E., Gundersen, S.G., Feldmeier, H., Vennervald, B.J., van Lieshout, L., Roald, B., Leutscher, P., Kjetland, E.F., 2015. Gynecological manifestations, histopathological findings, and *Schistosoma*-specific polymerase chain reaction results among women with *Schistosoma haematobium* infection: a cross-sectional study in Madagascar. *J. Infect. Dis.* 212, 275–284 (149).
- Renaud, G., Devidas, A., Develoux, M., Lamothe, F., Bianchi, G., 1989. Prevalence of vaginal schistosomiasis caused by *Schistosoma haematobium* in an endemic village in Niger. *Trans. R. Soc. Trop. Med. Hyg.* 83, 797 (150).
- Renaud, R., Brettes, P., Carrie, J., Castanier, C., Renaud, L., Chesnet, Y., Doucet, J., Loubiere, R., 1971. Bilharziasis of the internal female genital organs. *Rev. Fr. Gynecol. Obstet.* 66, 1–18 (151).
- Richter, J., Poggensee, G., Helling-Giese, G., Kjetland, E., Chitsulo, L., Koumenda, N., Gundersen, S.G., Krantz, I., Feldmeier, H., 1995. Transabdominal ultrasound for the diagnosis of *Schistosoma haematobium* infection of the upper female genital tract: a preliminary report. *Trans. R. Soc. Trop. Med. Hyg.* 89, 500–501 (152).
- Richter, J., Poggensee, G., Kjetland, E.F., Helling-Giese, G., Chitsulo, L., Kumwenda, N., Gundersen, S.G., Deelder, A.M., Reimert, C.M., Haas, H., Krantz, I., Feldmeier, H., 1996. Reversibility of lower reproductive tract abnormalities in women with *Schistosoma haematobium* infection after treatment with praziquantel—an interim report. *Acta Trop.* 62, 289–301.
- Ricossa, J.H., Emeric, R., Courbil, L.J., 1980. Anatomopathological aspects of schistosomiasis. A study of 286 pathological specimens (author's transl). *Med. Trop. (Mars)* 40, 77–94 (153).
- Rosen, Y., Kim, B., 1974. Tubal gestation associated with *Schistosoma mansoni* salpingitis. *Obstet. Gynecol.* 43, 413–417 (154).
- Sahu, L., Tempe, A., Singh, S., Khurana, N., 2013. Ruptured ectopic pregnancy associated with tubal schistosomiasis. *J. Postgrad. Med.* 59, 315–317 (155).
- Samuel, M.I., Taylor, C., 2015. A case of female urogenital schistosomiasis presenting as viral warts. *Int. J. STD AIDS* 26, 599–601 (156).
- Savardekar, L.S., Balaiah, D., Mali, B.N., 2010. Association of *Schistosoma haematobium* and human papillomavirus in cervical cancer: a case report. *Acta Cytol.* 54, 205–208 (157).
- Schanz, A., Richter, J., Beyer, I., Baldus, S.E., Hess, A.P., Krussel, J.S., 2010. Genital schistosomiasis as a cause of female sterility and acute abdomen. *Fertil. Steril.* 93 (2015), e2077–e2079 (158).
- Scheller, R., 1971. Genital bilharziasis. *Zentralbl. Gynakol.* 93, 530–540 (159).
- Schneider, D., Steyn, D.W., 2000. Genital schistosomiasis presenting as suspected ectopic pregnancy in the Western Cape. *S. Afr. Med. J.* 90, 609 (160).
- Schroers, B., Peschen-van Issum, M., Reinert, R.R., Fuzesi, L., Winkler Biesterfeld, M., 1995. Sterility as a sequela of tubal schistosomiasis. *Geburtshilfe Frauenheilkd.* 55, 140–142 (161).
- Schwartz, D.A., 1984. Carcinoma of the uterine cervix and schistosomiasis in West Africa. *Gynecol. Oncol.* 19, 365–370 (162).
- Sedlis, A., 1961. Manson's schistosomiasis of the Fallopian tube. A case report. *Am. J. Obstet. Gynecol.* 81, 254–255 (163).
- Seif-Eldin, D., 1958. Bilharziasis of the fallopian tubes and ovaries. *J. Obstet. Gynaecol. Br. Emp.* 65, 457–459 (164).
- Seneze, J., De Brux, J., Henrion, R., Baumann, H., 1963. Tubal bilharziasis. *Bull. Fed. Soc. Gynecol. Obstet. Lang. Fr.* 15, 327–337 (165).
- Servais, P., 1965. 6 cases of cervical and vaginal bilharziosis observed in Elisabethville. *Ann. Soc. Belges Med. Trop. Parasitol. Mycol.* 45, 169–172 (166).
- Shafeek, M.A., 1958. Bilharziasis of the ovary in Egypt. *Egypt Soc. Gynaecol. Obstet. Monogr. Ser.* 1, 49 (167).
- Sharma, S., Boyle, D., Wansbrough-Jones, M.H., Chiodini, P.L., Smith, J.R., 2001. Cervical schistosomiasis. *Int. J. Gynecol. Cancer* 11, 491–492 (168).
- Shekhar, K.C., Soh, E.B., Jayalakshmi, P., 2000. Upper genital schistosomiasis mimicking an ovarian tumour. *Med. J. Malaysia* 55, 371–375 (169).
- Shennan, D.W., Gelfand, M., 1971. Bilharzia ova in cervical smears a possible additional route for the passage of ova into water. *Trans. R. Soc. Trop. Med. Hyg.* 65, 95–99 (170).
- Siegrist, D., Siegrist-Obimpeh, P., 1992. *Schistosoma haematobium* infection in pregnancy. *Acta Trop.* 50, 317–321 (171).
- Sugiyama, S., Murata, H., Saito, M., 1963. Case of endometrial schistosomiasis. *Nihon Sanka Fujinka Gakkai Zasshi* 15, 983–984 (172).
- Sunder-Raj, S., 1976. Cystic teratoma of ovary associated with schistosomiasis. *East Afr. Med. J.* 53, 111–114 (173).
- Sutherland, J., Berry, A., Hynd, M., Proctor, N., 1965. Placental bilharziasis, report of a case. *S. Afr. J. Obstet. Gynaecol.* 4, 76–80 (174).
- Swai, B., Poggensee, G., Mtweve, S., Krantz, I., 2006. Female genital schistosomiasis as an evidence of a neglected cause for reproductive ill-health: a retrospective histopathological study from Tanzania. *BMC Infect. Dis.* 6, 134 (175).
- Swart, P.J., van der Merwe, J.V., 1987. Wet-smear diagnosis of genital schistosomiasis. *S. Afr. Med. J.* 72, 631–632 (176).
- Szela, E., Bachicha, J., Miller, D., Till, M., Wilson, J.B., 1993. Schistosomiasis and cervical cancer in Ghana. *Int. J. Gynecol. Obstet.* 42, 127–130 (177).
- Talaat, M., Watts, S., Mekheimer, S., Farook Ali, H., Hamed, H., 2004. The social context of reproductive health in an Egyptian hamlet: a pilot study to identify female genital schistosomiasis. *Soc. Sci. Med.* 58, 515–524 (178).
- Tavares Fortuna, J.F., 1974. External genital bilharziasis in the female. *An. Inst. Hig. Med. Trop. (Lisb)* 2, 513–520 (179).
- Toller, A., Scopin, A.C., Apfel, V., Prigenzi, K.C., Tso, F.K., Focchi, G.R., Speck, N., Ribalta, J., 2015. An interesting finding in the uterine cervix: *Schistosoma haematobium* calcified eggs. *Autops. Case Rep.* 5, 41–44 (180).
- van Bogaert, L.J., 2011. Biopsy-diagnosed female genital schistosomiasis in rural Limpopo, South Africa. *Int. J. Gynecol. Obstet.* 115, 75–76 (181).
- van Raalte, J.A., Venkataramaiah, N.R., Shaba, J.K., 1981. Bilharziasis of the female genital tract in Tanzania. *East Afr. Med. J.* 58, 543–547 (182).
- Vass, A.C., Lucey, J.J., 1982. Bilharzial granuloma of the fallopian tube. Case report. *Br. J. Obstet. Gynaecol.* 89, 867–869 (183).
- Ville, Y., Leruez, M., Picaud, A., Walter, P., Fernandez, H., 1991. Tubal schistosomiasis as a cause of ectopic pregnancy in endemic areas? A report of three cases. *Eur. J. Obstet. Gynecol. Reprod. Biol.* 42, 77–79 (184).
- Williams, A.O., 1967. Pathology of schistosomiasis of the uterine cervix due to *S. haematobium*. *Am. J. Obstet. Gynecol.* 98, 784–791 (185).
- Woto-Gaye, G., Moreau, J.C., Mendes, V., Boye, C.S., Rupari, L., Diadhio, F., Ndiaye, P. D., 2000. Grossesses extra-utérines et bilharzioses tubaire au Senegal: a propos de 3 cas. *Méd. Afr. Noire* 47 (186).
- Wright, E.D., Chipangwi, J., Hutt, M.S., 1982. Schistosomiasis of the female genital tract. A histopathological study of 176 cases from Malawi. *Trans. R. Soc. Trop. Med. Hyg.* 76, 822–829 (187).
- Yang, H.L., 1984. Female genital schistosomiasis and tubal pregnancy. *Ji Sheng Chong Xue Yu Ji Sheng Chong Bing Za Zhi* 2, 160 (188).
- Yirenya-Tawiah, D., Amoah, C., Apea-Kubi, K.A., Dade, M., Ackumei, M., Annang, T., Mensah, D.Y., Bosompem, K.M., 2011. A survey of female genital schistosomiasis of the lower reproductive tract in the volta basin of Ghana. *Ghana Med. J.* 45, 16–21 (189).
- Youssef, A.F., Abdine, F.H., 1958. Bilharziasis of the pregnant uterus. *J. Obstet. Gynaecol. Br. Emp.* 65, 991–993 (190).
- Youssef, A.F., Fayad, M.M., Shafeek, M.A., 1961. Bilharzioses of the female genital tract. *Geburtshilfe Frauenheilkd.* 21, 1061–1068 (191).
- Youssef, A.F., Fayad, M.M., Shafeek, M.A., 1970. Bilharziasis of the cervix uteri. *J. Obstet. Gynaecol. Br. Commonw.* 77, 847–851 (192).
- Youssef, A.F., 1957. Detection of bilharziasis of the uterine cervix by routine colposcopy. *Geburtshilfe Frauenheilkd.* 17, 445–449 (193).