



International Journal of Surgery Case Reports

journal homepage: www.casereports.com

Diagnosis and treatment of talar dislocation fractures illustrated by 3 case reports and review of literature



J.J.M. Haverkort*, L.P.H. Leenen, K.J.P. van Wessem

Department of Trauma Surgery, University Medical Center Utrecht, Utrecht, The Netherlands

ARTICLE INFO

Article history:

Received 30 June 2015

Received in revised form

18 September 2015

Accepted 19 September 2015

Available online 28 September 2015

Keywords:

Dislocated talar fracture

Arthritis

Avascular necrosis

ABSTRACT

INTRODUCTION: Talar fractures are a rare type of fractures (less than 1%). They are difficult to treat and outcome is often complicated by arthritis and avascular necrosis.

In this article three cases are presented with different types of dislocated talar neck fractures. Anatomy of the talus, treatment, outcome and follow up of these fractures are discussed. Further, review of literature and guidelines for treatment and follow up for dislocated talar neck fractures are discussed.

DISCUSSION: The risk of developing arthritis or avascular necrosis of the talus after dislocated talar neck fractures depends on the initial trauma with vascular compromise due to dislocation of the talus. The modified Hawkins classification gives an insight in the risk of developing avascular necrosis. During follow up the Hawkins sign can be an indication of a vital talus. To diagnose avascular necrosis MRI is the only suitable diagnostic tool.

CONCLUSION: Reduction of a dislocated talar fracture is a medical emergency in an effort to reduce the vascular compromise of the talus. Definitive fixation can be delayed but should be performed by an experienced surgeon to achieve an optimal reconstruction of the talar surface. Long-term follow up is important to evaluate signs of arthritis and avascular necrosis.

© 2015 The Authors. Published by Elsevier Ltd. on behalf of Surgical Associates Ltd. This is an open access article under the CC BY-NC-ND license (<http://creativecommons.org/licenses/by-nc-nd/4.0/>).

1. Introduction

Less than 1% of fractures occur in the talar neck [1]. Due to the complex vascularisation and the large weight bearing surface of the talus the correct treatment of fractures is very important. Talar neck fractures are known to have a high morbidity, being subject to avascular necrosis (AVN), arthritis and non-union of the talar fragments. Given the uncommon nature of talar fractures most studies included few patients, and there is room for discussion as to the correct treatment and risks following the talar neck fracture. Further, different classifications have been used, making a comparison between studies unreliable. In this article we discuss the treatment and outcome of three patients with dislocated talar neck fractures. Further, literature is reviewed and guidelines for treatment and follow up on this rare type of fractures are discussed.

2. Case reports

2.1. First case

The first patient discussed is a 19-year old motorcyclist, without medical history, who fell off his bike during acceleration. He sustained a medial subtalar luxation with a talar neck fracture type Hawkins II (Fig. 1). The skin was intact and there was no neurovascular compromise. Treatment consisted of closed reduction under general anaesthesia followed by cast immobilisation for six weeks. Radiological follow-up at six and twelve weeks showed subchondral lucency of the talar dome. This is called a Hawkins sign and occurs secondary to subchondral atrophy 6–8 weeks after a talar neck fracture. It indicates that there is sufficient vascularity in the talus and it is less likely to develop an avascular necrosis. Fracture healing was uneventful and the patient reported no complaints of pain or limitation in activities during the 19 months follow up.

2.2. Second case

A 51-year old male, without relevant medical history, who fell off a ladder, landing on his left ankle. He had a severe medial dislocation of the ankle with a lateroventral open luxation of the talus. Sensibility and vascularisation of the foot were normal. Radiography showed a tibiotalar and subtalar dislocation, classified as a Hawkins III fracture (Fig. 2). Attempts at closed reposition failed.

* Corresponding author at: University Medical Center Utrecht, Department of Trauma Surgery, Suite B00.118, Heidelberglaan 100, 3584 CX, Utrecht, The Netherlands.

E-mail address: jjm.haverkort@outlook.com (J.J.M. Haverkort).

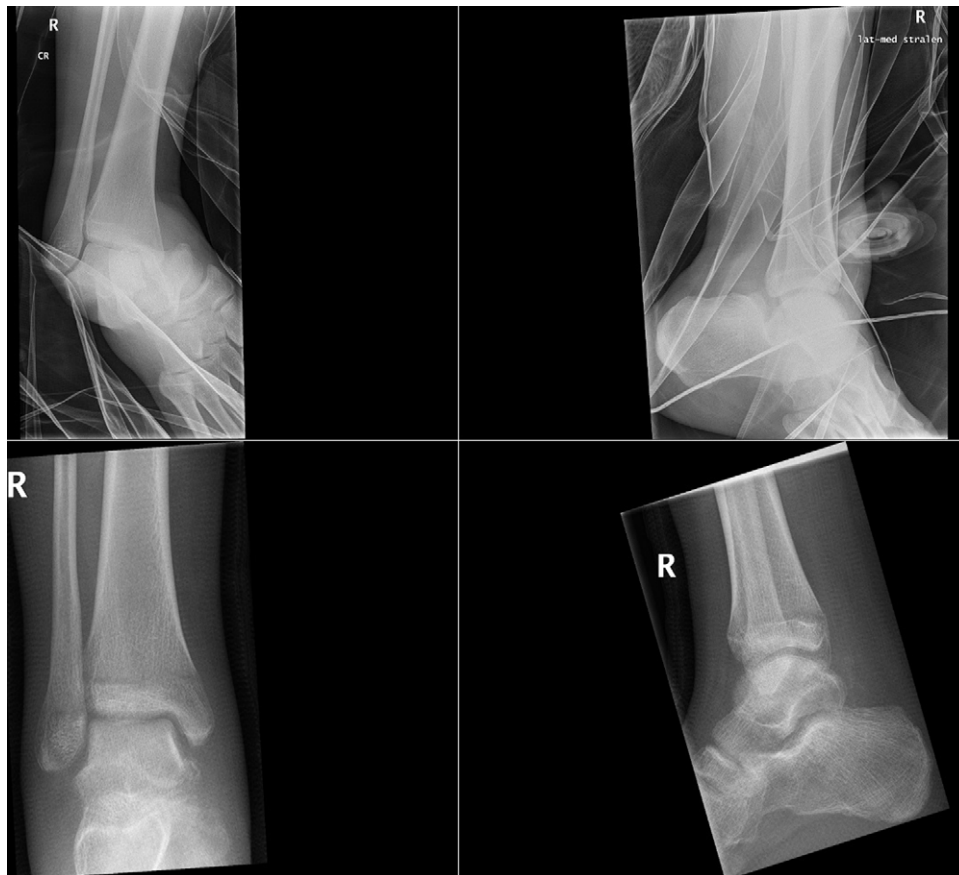

Fig. 1. Top left and right: X-ray of a right ankle in splint. A dislocated fracture of the talus can be seen. Bottom left and right: situation 3 weeks after closed reduction.

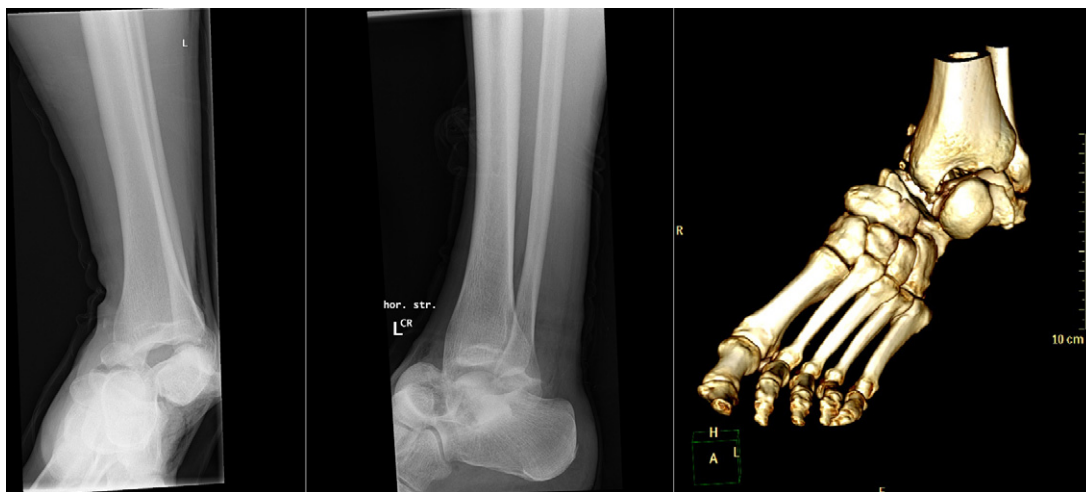


Fig. 2. X-ray of a left ankle with 3D CT reconstructions: complete dislocation of the tibiocalcaneal joint and subtotal dislocation of the tibiotalar joint combined with comminuted talar fracture.

Patient was taken to theatre where open reduction was successful and fixation of the comminuted fracture was performed with two k-wires and two screws. An external fixator was placed to assure stability. Antibiotics were prescribed because of the open nature of the fracture. No complications occurred and ten weeks after surgery there were no signs of avascular necrosis on radiologic imaging. Two years after the initial treatment the patient

suffered from local pain. CT radiography showed mild subtalar and talonavicular arthritis, moderate collapse of the talar dome and a bony impingement exactly at the location of the complaints. Considering the location of the pain and the radiographic findings an arthroscopic nettoyage of the involved region and a k-wire removal was performed with good results. Three years after the incident the patient has resumed sporting activities and only reports minor pain,

Table 1
Hawkins classification of talar neck fracture, modified by Canale and Kelly [6].

Type	Dislocation	Vascular damage	Rate of avascular necrosis
Hawkins I	None	Anterolateral	0–13%
Hawkins II	Subtalar	Neck, sinus tarsi, tarsal canal	20–50%
Hawkins III	Tibiotalar, Subtalar	All 3 arteries	20–100%
Hawkins IV	Tibiotalar, subtalar, talonavicular	All 3 arteries	100%

after intensive sporting activities, which is manageable without pain killers.

2.3. Third case

A 51-year old smoker male without relevant medical history. He was involved in a high-energy motor vehicle accident and suffered from several injuries amongst which a severely dislocated talar fracture type Hawkins IV (Fig. 3), without neurovascular compromise. Treatment consisted of open reduction followed by an external fixator to maintain adequate reposition and to monitor the soft tissues. Sixteen days post injury internal fixation was performed. X-rays six and twelve weeks post injury did not indicate avascular necrosis of the talus. After ten months a subtalar arthrodesis with a cannulated screw and iliac crest bone graft was performed because of pain caused by arthritis due to incongruent articulating surface. Rehabilitation was complicated by a wound infection. Patient did regain limited motion of the ankle joint but pain persisted. CT scans showed a non-union of the talar fracture, the vascularity of the talus could not be determined by the CT scan. After screw removal a MRI was performed. This showed an avascular talus (Fig. 4). The combination of avascular necrosis, low-grade infection and pain warranted a talectomy followed by a tibiocalcaneal fusion. Six weeks after surgery patient resumed weightbearing activities. One year after tibiocalcaneal fusion patient is in good physical condition and fairly pain free with transcutaneous electro neuro stimulation.

3. Background

The first publication describing a talar fracture was authored by Franciscus of Hilden in 1608: “the Rev. Master Voolfbrand of Duisburg, a man strong and fleshy, in jumping from a bank three feet high so twisted and broke his right foot that the whole of the os tali was not only displaced but the ligaments by which it is bound to the other bones, being broken, it burst through the skin and hung out.” The first large series of patients were described in 1919 by Anderson, a consulting surgeon of the British royal air force [2]. He reported 18 cases from 1914 to 1918, all of them being pilots with their feet resting on the rudder pedal in dorsiflexion while they crashed their airplanes. During those days talectomy was the only known treatment. Until the 1970’s over 50% of dislocated talar fractures resulted in avascular necrosis. Nowadays, the outcome has strongly improved with the present available diagnostic and operative options available [3,4].

3.1. Anatomy and vascularisation

The high risk of avascular necrosis and arthritis of the talar bone can be explained by the limited vascularisation and the vast articulating surface of the bone. The combination of the rarity of the condition and the fragile vascularisation provide a complex problem. The extra osseous vascularisation consists of three arteries: (1) the posterior tibial artery, which provides blood flow to the deltoid artery and the tarsal tunnel; (2) the anterior tibial artery providing the lateral tarsal artery and; (3) the perforating peroneal arteries providing the tarsal sinus artery. These three arteries form multi-

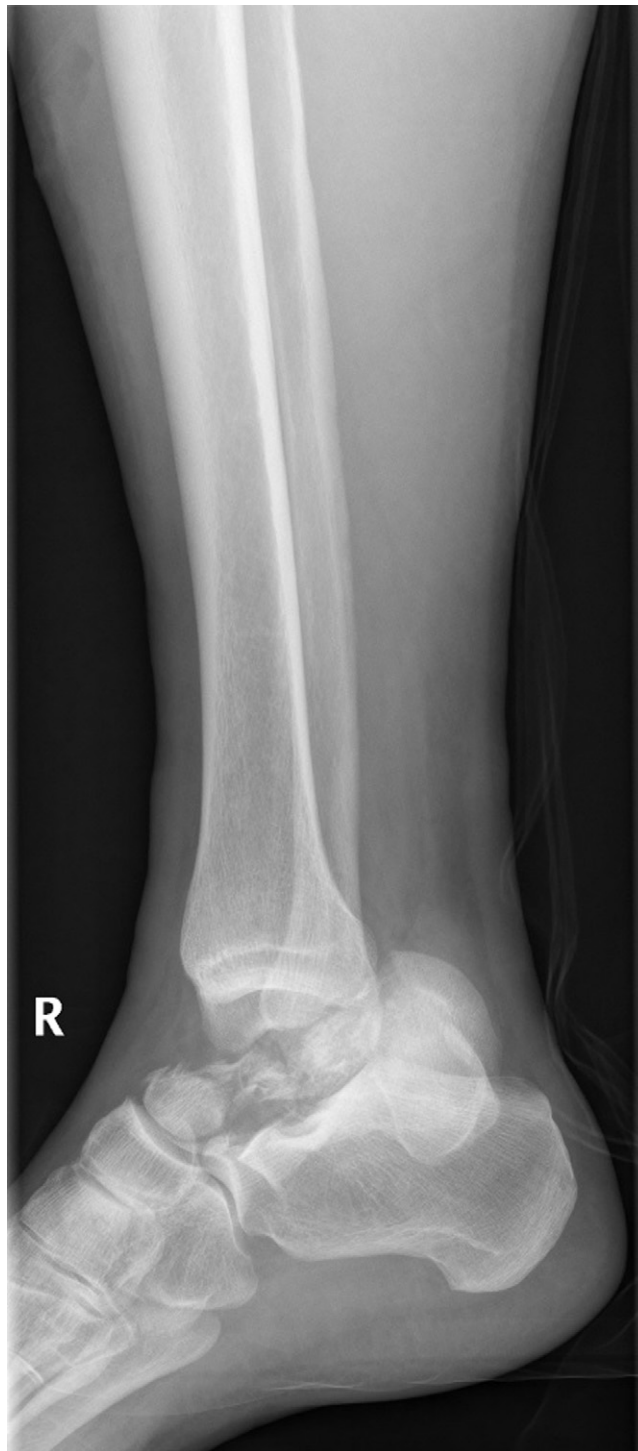

Fig. 3. X-ray of a right ankle: Hawkins IV talar neck fracture with complete dislocation of the corpus.

Table 2
Literature overview.

Study	Study type	Classification	Total talar neck fractures (total fractures reported)	Male gender	Average age (years)	Hawkins I	Hawkins II	Hawkins III	Hawkins IV	Arthritis	AVN	Follow up (years)
Hawkins [5]	Retrospective	Hawkins	57	38 (67%)	30	6 (11%)	24 (42%)	27 (47%)	NR	NR	30 (53%)	3.8
Kenwright and Taylor [20]	Retrospective	Coltart	21	49 (84%)	35	b	b	b	b	NR	8 (38%)	4
Lorentzen et al. [14]	Retrospective	Hawkins	123	107 (87%)	39	54 (44%)	53 (43%)	16 (13%)	NR	96 (78%)	26 (21%)	1.8
Canale and Kelly [6]	Retrospective	Hawkins	71	NR	30	15 (21%)	30 (42%)	23 (32%)	3 (4%)	NR	33 (47%)	13.4
Penny and Davis [10]	Retrospective	Hawkins	27	NR	30	5 (19%)	11 (41%)	11 (41%)	b	NR	13 (48%)	6.2
Schulze et al. [9]	Retrospective	Hawkins	46	NR	NR	10 (22%)	18 (39%)	17 (37%)	1 (2%)	NR	8 (17%)	6
Lindvall et al. [16]	Retrospective	Hawkins	18	10 (56%)	37	0 (0%)	11 (61%)	6 (33%)	1 (6%)	16 (89%)	7 (39%)	6.2
Sanders et al. [7]	Retrospective	Hawkins	70	57 (81%)	34	0 (0%)	29 (41%)	25 (36%)	16 (23%)	42 (40%)	8 (11%)	5.2
Vallier et al. [15]	Retrospective	Hawkins	102	60 (59%)	33	4 (4%)	68 (67%)	25 (25%)	5 (5%)	13 ^a (33%)	12 (31%) ^a	2.5
Vallier et al. [12]	Retrospective	Hawkins	81	40 (62%)	37	2 (2%)	44 (54%)	32 (40%)	3 (4%)	35 (54%)	16 (25%)	2.5

Data shown represent median ± SD.

AVN: avascular necrosis, NR: not reported.

^a Of 39 patients with radiological follow up.

^b Not used.

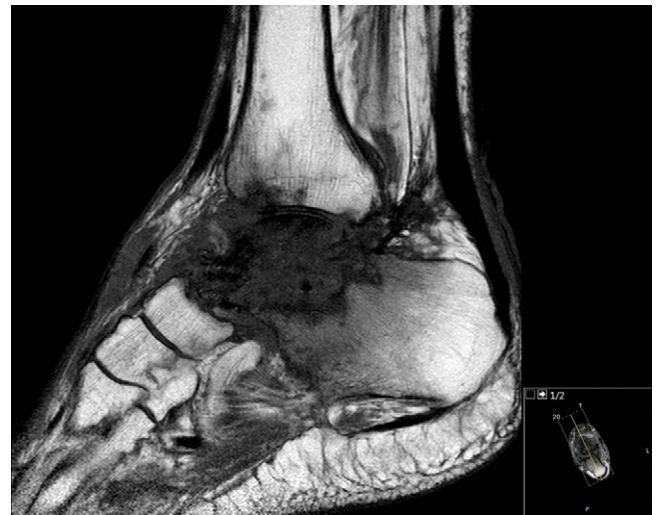

Fig. 4. MRI of the right ankle: the talus appears as a hypo-intense signal suggesting an avascular talus.

ple anastomoses that perfuse the talar neck from the tarsal sinus. In case of a talar trauma with dislocation this blood supply from the talar neck to the talar corpus is interrupted. In such cases the talar corpus is only perfused by the deltoid artery (branching from the posterior tibial artery), enhancing the risk of avascular necrosis [3].

3.2. Classification of talar fractures

The modified Hawkins classification considers, beside the grade of fracture dislocation, the severity of vascular damage possibly causing avascular necrosis of the talus [5,6]. The classification extends from a Hawkins I fracture, where there is no dislocation to Hawkins IV with severe dislocation in reference to all articulations (Table 1).

3.3. Complications

Persisting pain is a frequent recurring complaint after a talar fracture [7]. Considering the seven different articulations the talus forms, it is nearly impossible to reconstruct the articulating surfaces according to the anatomical position after a complex fracture. Patients two and three developed arthritis within two years of reconstruction, requiring arthroscopic nettoyage and arthrodesis respectively. Arthritis often occurs, especially in Hawkins III or IV fractures. 24%, 32%, 38% and 48% of patients with Hawkins III or IV fractures develop arthritis after respectively 1, 2, 3 and 10 years [7]. Arthritis is most often treated by subtalar arthrodesis followed by tibiotalar arthrodesis and triple arthrodesis.

3.4. Follow up

During follow up the treating physician should always keep the possibility of avascular necrosis in mind. Signs of revascularisation can be seen on ankle radiographs six to twelve weeks after trauma. The Hawkins sign describes subchondral lucency of the talar dome that occurs secondary to subchondral atrophy due to inactivity six to eight weeks after a talar neck fracture. It indicates that there is sufficient vascularity in the talus and it is unlikely to develop an avascular necrosis later [8,9]. In case of combined non-union of the fracture and persisting pain diagnostics should be performed to confirm avascular necrosis. Necrosis of the talar bone alone is not an indication for surgery, only in case of persisting pain and

Table 3
Rates of avascular necrosis related to Hawkins classification.

Study	Total AVN cases	Hawkins I	Hawkins II	Hawkins III	Hawkins IV
Hawkins [5]	30	0 (0%)	10 (42%)	20 (91%) ^a	^b
Kenwright and Taylor [20]	8	^b	^b	^b	^b
Lorentzen et al. [14]	26	2 (4%)	13 (24%)	11 (69%)	^b
Canale and Kelly [6]	33	2 (13%)	15 (50%)	15 (84%) ^c	1 (50%) ^d
Penny and Davis [10]	13	0 (0%)	2 (20%)	11 (100%)	^b
Schulze et al. [9]	8	0 (0%)	2 (11%)	5 (29%)	1 (100%)
Lindvall et al. [16]	7	0 (0%)	4 (40%)	2 (40%)	1 (100%)
Sanders et al. [7]	8	NR	NR	NR	NR
Vallier et al. [15]	12	NR	NR	NR	NR
Vallier et al. [12]	16	0 (0%)	4 (11%) ^e	11 (41%)	1 (33%)
Total	161	4	40	76	4

AVN: avascular necrosis.

NR: not reported.

^a Excludes 5 patients who had primary talectomy.

^b Not used.

^c Excludes two ankles in which Blair fusion was performed and two patients who had either talectomy as a primary procedure or prior to the time when the talar body could be evaluated for avascular necrosis.

^d Excludes one patient with primary talectomy.

^e Separated over groups IIA and IIB depending on rate of dislocation. All 4 (25%) cases were in the IIB group.

disability due to talar dome collapse operative options should be considered. In case of avascular necrosis of the talus talectomy with tibio calcaneal fusion is favoured over talar prosthesis or more rigorous interventions such as partial amputation as was customary in the 1980s [10].

4. Review of literature

This literature review is based on a PubMed search for keywords 'talus' and 'fracture'. We excluded articles written in languages other than English, German and Dutch, cadaveric studies, case reports and studies focussing on primary arthrodesis. Twenty-one studies remained of which we evaluated all abstracts, ten articles where available in full text. Nine studies used the Hawkins classification, the tenth study applied the Coltart classification. Results are shown in Table 2. In 2013, Halvorson et al. [11] reviewed a total of twenty-one articles. Since not all articles in their review were available in full text, only the available studies were included and listed in Table 2.

All studies were retrospective in their design. A total of 600 fractures of the talar neck were reported in these ten studies. The overview of demographic data is listed in Table 2. Three out of nine studies using the Hawkins classification did not apply the Hawkins IV category. Arthritis rate was reported in five studies. Avascular necrosis (AVN) rates reported an overall incidence of 27% (161/600). Seven studies specified the incidence of AVN per group in the Hawkins classification as shown in Table 3. Incidence of AVN in Hawkins I fractures was 2.4%, 28.3% in Hawkins II fractures, 64.9% in Hawkins III fractures and 70.8% in Hawkins IV. Hawkins IV fractures were only separately available in 4 studies, in the other studies they were part of the Hawkins III group. The correlation between Hawkins score and AVN rate was confirmed by Halvorson et al. in his review of 19 studies including AVN rates [11]. Vallier et al. has shown that the rate of AVN was not influenced by delayed definitive internal fixation [12]. This study however was underpowered to draw conclusions from the influence of delay in fracture reduction on AVN development [12].

Development of arthritis was reported in five studies, with an incidence of 54% involving the tibiotalar, subtalar, talonavicular or a combination of these joints. The included studies did not relate injury severity to the rate of arthritis development, therefore it was impossible to correlate posttraumatic arthritis to injury severity.

5. Discussion

This article aimed to provide a literature overview of talar fractures illustrated by three cases of dislocated talar fractures with their respective outcome. Talar neck fractures are rare and have a high risk of avascular necrosis depending on the severity of fracture dislocation. Outcome benefits from early fracture reduction limiting the degree of compromise resulting in avascular necrosis. Definitive fracture fixation however, can be delayed and should be performed by an experienced surgeon to assure optimal anatomical reconstruction of the articulating surfaces [3,4,15,16]. Literature does not show a clear consensus about a beneficial effect of immediate reduction combined with definitive fixation to reduce the risk of avascular necrosis. Most studies do not show a significant relation as to the timing of operative fixation of the fracture [3,4,15,16]. The risk of developing avascular necrosis depends on the initial trauma with associated vascular damage. It is rarely possible to perform a closed reduction in dislocated talar neck fractures due to interposition of soft tissue, mostly the flexor hallucis longus muscle. If closed reposition succeeds with a near anatomical position of the articulating surfaces the fracture can be treated conservatively as was done in patient one.

Halvorson et al. [11] concluded in his review that there was a correlation between the severity of talar neck fractures according to the Hawkins classification and avascular necrosis. The review showed a low incidence of avascular necrosis after a Hawkins IV fracture, which can be contributed to the fact that only 4.5% of fractures were classified as Hawkins IV and that until 1977 Hawkins IV classification did not exist. In several other studies a 100% incidence of avascular necrosis in the Hawkins IV categories is shown due to vascular compromise of the talus [8,13,14]. This is in accordance with the clinical course of patients two and three.

The most sensitive diagnostic tool for avascular necrosis is MRI. Ten weeks after the initial trauma diagnosis of (partial) avascular necrosis can be made [17]. MRI within three weeks after trauma is very unreliable [18,19]. Downside of MRI is the requirement of osteosynthesis removal.

One limitation of this literature review is that we included full-text articles from Pubmed only. Although this might limit the number of usable studies, we feel that it enhances the reliability of the numbers presented.

6. Conclusion

Talar neck fractures are rare and are characterised by high risk of avascular necrosis depending on the severity of the fracture and its dislocation. Reduction of dislocated talar neck fractures is a surgical emergency to minimize the vascular compromise. Definitive fixation of the fracture can be delayed and should be performed by an experienced surgeon to obtain optimal reconstruction of the articulating surfaces. The risk of developing avascular necrosis depends on the initial trauma. Arthritis and avascular necrosis occur frequently after severely dislocated fractures such as Hawkins III and IV, causing high morbidity. Careful follow-up is of great importance to provide adequate care.

Conflict of interest

All authors listed have contributed sufficiently to the project to be included as authors. No conflict of interest, financial or other, exists. Authors have approved publication.

Funding

No sources of funding to report.

Ethical approval

Ethical approval is not applicable.

Consent

Consent for cooperation in scientific research is given by the patient upon admission to our hospital. Every patient is informed about this prior to admittance. A written second consent for publication has not been obtained. The data is anonymised and cannot be led back to a specific patient.

Author contribution

J.J.M. Haverkort: First author, data gathering and writing of the paper.

L.P.H. Leenen: Second author, supervising, rewriting, correcting and guidance.

K.J.P. van Wessem: Senior author, supervising, rewriting, correcting and guidance.

Research registry

The article is a case series.

Guarantor

J.J.M. Haverkort.
L.P.H. Leenen.
K.J.P. van Wessem.

References

- [1] R.S. Adelaar, Fractures of the talus, Instr. Course Lect. 39 (1990) 147–156.
- [2] H.G. Anderson, The Medical and Surgical Aspects of Aviation, Oxford University Press, London, 1919.
- [3] P.T. Fortin, J.E. Balazsy, Talus fractures: evaluation and treatment, J. Am. Acad. Orthop. Surg. 9 (March–April (2)) (2001) 114–127.
- [4] S. Rammelt, H. Zwipp, Talar neck and body fractures, Injury 40 (February (2)) (2009) 120–135.
- [5] L.G. Hawkins, Fractures of the neck of the talus, J. Bone Joint Surg. Am. 52 (July (5)) (1970) 991–1002.
- [6] S.T. Canale, F.B. Kelly Jr., Fractures of the neck of the talus: long-term evaluation of seventy-one cases, J. Bone Joint Surg. Am. 60 (March (2)) (1978) 143–156.
- [7] D.W. Sanders, M. Busam, E. Hattwick, J.R. Edwards, M.P. McAndrew, K.D. Johnson, Functional outcomes following displaced talar neck fractures, J. Orthop. Trauma 18 (May–June (5)) (2004) 265–270.
- [8] T.A. Cueni, M. Allgower, Bone scintigraphic and radiologic examinations of talus fracture healing, Helv. Chir. Acta 41 (September (4)) (1974) 459–468.
- [9] W. Schulze, J. Richter, O. Russe, P. Ingelfinger, G. Muhr, Prognostic factors for avascular necrosis following talar fractures, Z. Orthop. Ihre Grenzgeb. 140 (July–August (4)) (2002) 428–434.
- [10] J.N. Penny, L.A. Davis, Fractures and fracture-dislocations of the neck of the talus, J. Trauma 20 (December (12)) (1980) 1029–1037.
- [11] J.J. Halvorson, S.B. Winter, R.D. Teasdall, A.T. Scott, Talar neck fractures: a systematic review of the literature, J. Foot Ankle Surg. 52 (January–February (1)) (2013) 56–61.
- [12] H.A. Vallier, S.G. Reichard, A.J. Boyd, T.A. Moore, A new look at the Hawkins classification for talar neck fractures: which features of injury and treatment are predictive of osteonecrosis? J. Bone Joint Surg. Am. 96 (February (3)) (2014) 192–197.
- [13] C.K. Low, C.K. Chong, H.P. Wong, Y.P. Low, Operative treatment of displaced talar neck fractures, Ann. Acad. Med. Singapore 27 (November (6)) (1998) 763–766.
- [14] J.E. Lorentzen, S.B. Christensen, O. Krogsoe, O. Sneppen, Fractures of the neck of the talus, Acta Orthop. Scand. 48 (May (1)) (1977) 115–120.
- [15] H.A. Vallier, S.E. Nork, D.P. Barei, S.K. Benirschke, B.J. Sangeorzan, Talar neck fractures: results and outcomes, J. Bone Joint Surg. Am. 86-A (August (8)) (2004) 1616–1624.
- [16] E. Lindvall, G. Haidukewych, T. DiPasquale, D. Herscovici Jr., R. Sanders, Open reduction and stable fixation of isolated, displaced talar neck and body fractures, J. Bone Joint Surg. Am. 86-A (October (10)) (2004) 2229–2234.
- [17] O. Jarde, G. Boulou, E. Havet, A. Gabrion, P. Vives, Complete transverse fractures of the talus: value of magnetic resonance imaging for detection of avascular necrosis, Acta Orthop. Belg. 67 (February (1)) (2001) 60–67.
- [18] D.B. Thordarson, M.J. Triffon, M.R. Terk, Magnetic resonance imaging to detect avascular necrosis after open reduction and internal fixation of talar neck fractures, Foot Ankle Int. 17 (December (12)) (1996) 742–747.
- [19] M.L. Prasarn, A.N. Miller, J.P. Dyke, D.L. Helfet, D.G. Lorch, Arterial anatomy of the talus: a cadaver and gadolinium-enhanced MRI study, Foot Ankle Int. 31 (November (11)) (2010) 987–993.
- [20] J. Kenwright, R.G. Taylor, Major injuries of the talus, J. Bone Joint Surg. 52B (1970) 36–48.

Open Access

This article is published Open Access at sciendo.com. It is distributed under the [IJSCR Supplemental terms and conditions](#), which permits unrestricted non commercial use, distribution, and reproduction in any medium, provided the original authors and source are credited.