

## Case Report

# Antegrade and Retrograde Decremental Conduction Properties of an Accessory Pathway Associated with the Coronary Sinus Musculature

Kohki Nakamura MD, Shigeto Naito MD, Kenichi Kaseno MD, and Shigeru Oshima MD

Division of Cardiology, Gunma Prefectural Cardiovascular Center, 3-12 Kameizumi-machi, Maebashi City, Gunma 371-0004, Japan

Address for Correspondence: Kohki Nakamura, Division of Cardiology, Gunma Prefectural Cardiovascular Center, 3-12 Kameizumi-machi, Maebashi City, Gunma 371-0004, Japan. E-mail: [kohkinakamura@yahoo.co.jp](mailto:kohkinakamura@yahoo.co.jp)

### Abstract

A 32-year-old man underwent catheter ablation of an orthodromic atrioventricular reentrant tachycardia. The sinus rhythm electrocardiogram exhibited a normal PQ interval and no delta waves, but atrial pacing produced a prolonged PQ interval and wide QRS morphology with right bundle-branch block due to antegrade accessory pathway (AP) conduction. During the tachycardia, atrial double potentials consisting of the coronary sinus musculature (CSM) and left atrial (LA) potentials were observed. Ventricular extrastimulation exhibited retrograde decremental conduction with an identical atrial activation sequence as during the tachycardia. A radiofrequency application within the posterolateral CS during ventricular pacing eliminated the CSM-LA conduction and concomitantly the ventriculoatrial conduction via the AP was abolished. In this case, the CSM was associated with the bidirectional decremental conduction properties of the AP, and the antegrade slow conduction resulted in the absence of a shortening of the PQ interval and delta waves during sinus rhythm despite the continuous presence of antegrade AP conduction.

**Key words:** accessory pathway; decremental conduction property; coronary sinus musculature; atrial double potential; atrioventricular reentrant tachycardia; catheter ablation

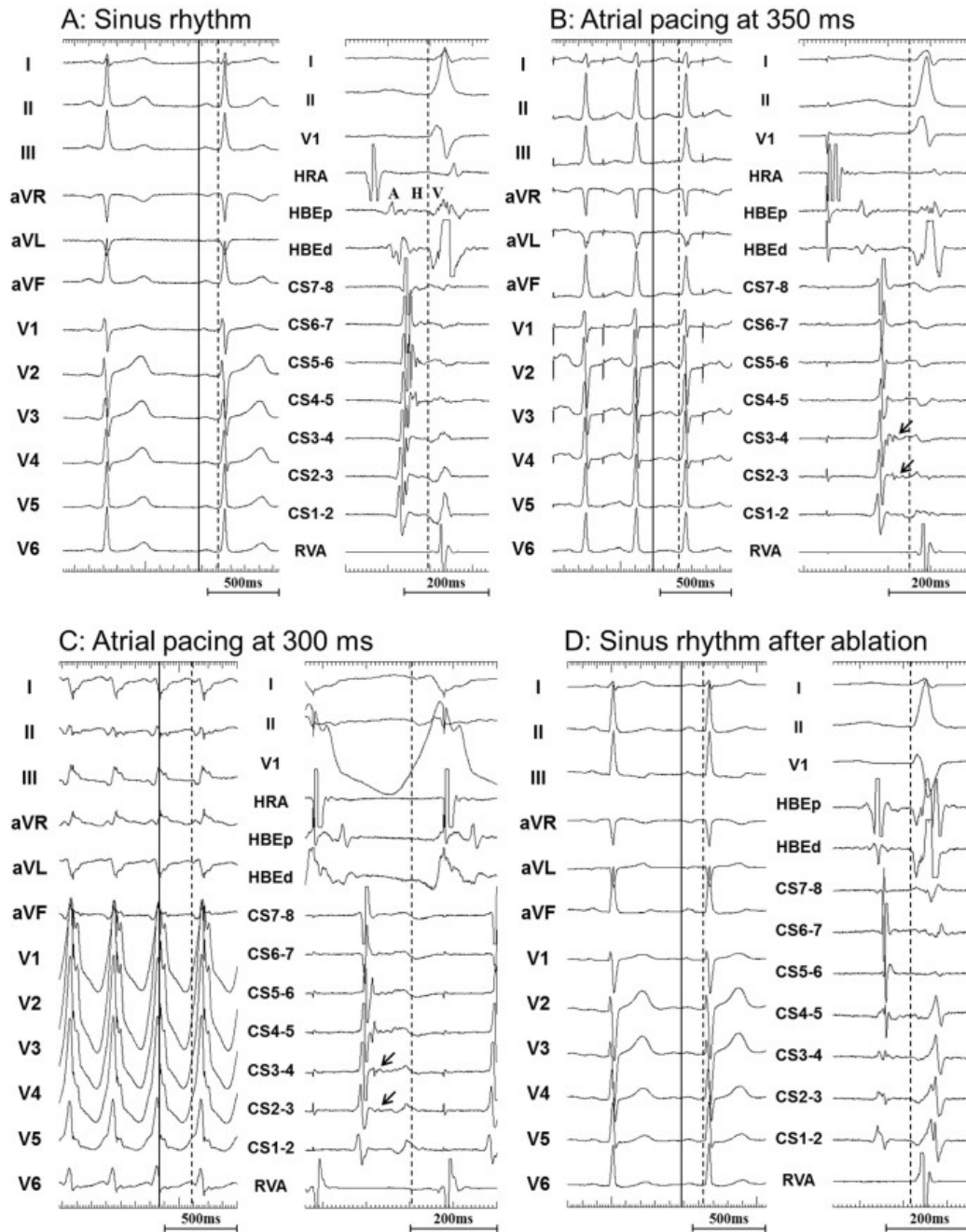
### Case Report

A 32-year-old man without structural heart disease was referred for radiofrequency (RF) catheter ablation of a narrow QRS tachycardia with recurrent palpitations. The 12-lead electrocardiogram (ECG) during sinus rhythm exhibited a normal PQ interval of 140 milliseconds (ms), normal QRS width of 82 ms and no overt delta waves (**Figure 1A**).

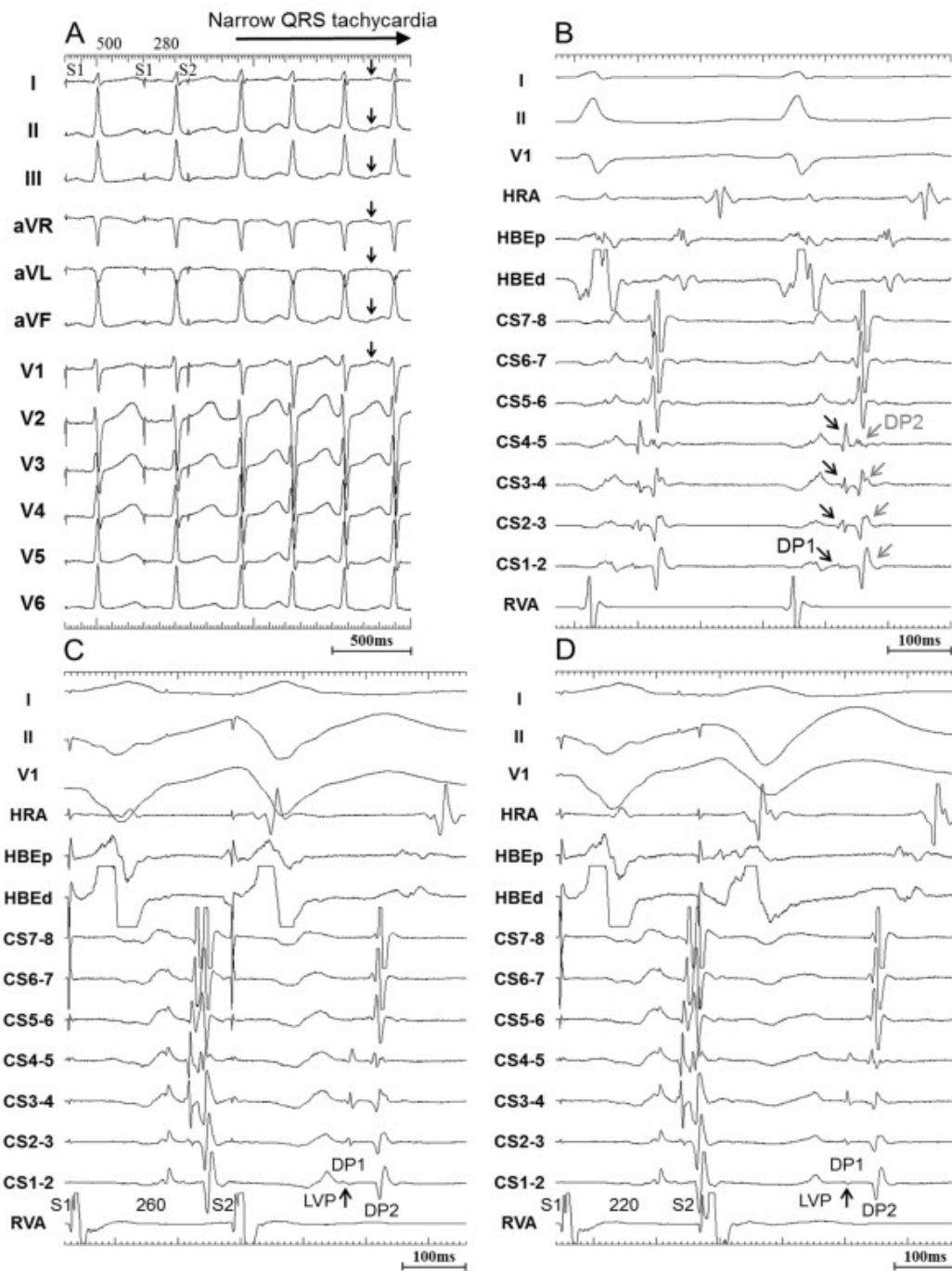
The baseline electrophysiological study demonstrated that the A-H interval was within the normal range of 70 ms, the H-V interval was short at 25 ms, and continuous low-amplitude electrograms between the atrial and ventricular potentials were recorded by a multielectrode catheter placed in the coronary sinus (CS) (**Figure 1A**). Incremental atrial pacing at cycle lengths of 600 to 350 ms resulted in a progressive prolongation of the PQ interval from 158 to 196 ms and a slight increment in the amplitude of the R wave in the precordial leads, but there

This is an open access article under the [CC BY-NC-ND license](https://creativecommons.org/licenses/by-nc-nd/4.0/).

was no significant difference in the QRS width (**Figure 1B**). Atrial pacing at 300 ms, however, resulted in a further prolonged PQ interval of 228 ms and wide QRS morphology with right bundle-branch block (RBBB) (**Figure 1C**). The earliest ventricular activation was then identified along the CS but was not in the His-bundle region. These findings suggested the presence of antegrade slow and decremental conduction over a left-sided accessory pathway (AP).



**Figure 1:** Twelve-lead and intracardiac electrograms during sinus rhythm (A) and atrial pacing at cycle lengths of 350 ms (B) and 300 ms (C) before ablation. Atrial pacing at 350 ms revealed a longer PQ interval of 196 ms and taller R waves in the precordial leads than during sinus rhythm, but a narrow QRS morphology (QRS width 86 ms), whereas atrial pacing at 300 ms revealed a wide QRS morphology with RBBB (QRS width 134 ms) and a further prolonged PQ interval of 228 ms. Fractionated potentials (arrows) were recorded between the atrial and ventricular potentials along the CS. During sinus rhythm after eliminating the AP conduction (D), the R waves in the precordial leads were slightly smaller than before (A), and the fractionated potentials recorded along the CS disappeared. The solid and dashed vertical lines represent the onset of the P and QRS waves, respectively. A, atrial electrogram; CS 7-8 to 1-2, proximal to distal coronary sinus recordings; H, His-bundle electrogram; HBd, distal His-bundle region; HBp, proximal HB; HRA, high right atrium; RVA, right ventricular apex.



**Figure 2:** A: Twelve-lead electrograms during the clinical tachycardia induced by single atrial extrastimulation with an S1-S2 interval of 280 ms at a basic cycle length (S1-S1) of 500 ms. The arrows indicate the retrograde P waves during the tachycardia. B: Surface and intracardiac electrograms during the tachycardia. Atrial double potentials (DPs) were recorded along the CS and the earliest DP1 and DP2 sites were identified at the lateral (CS1-2) and posterolateral mitral annulus (CS4-5), respectively. The black and gray arrows indicate DP1 and DP2, respectively. C, D: Single ventricular extrastimulation (S2) at a basic cycle length (S1-S1) of 500 ms demonstrating decremental retrograde conduction. When the S1-S2 interval was shortened from 260 (C) to 220 ms (D), the S2-DP1 interval prolonged from 176 to 219 ms. The arrows represent DP1. DP1, the first component of the atrial double potentials; DP2, the second component of the atrial double potentials; LVP, left ventricular potential. The other abbreviations are as in Figure 1.

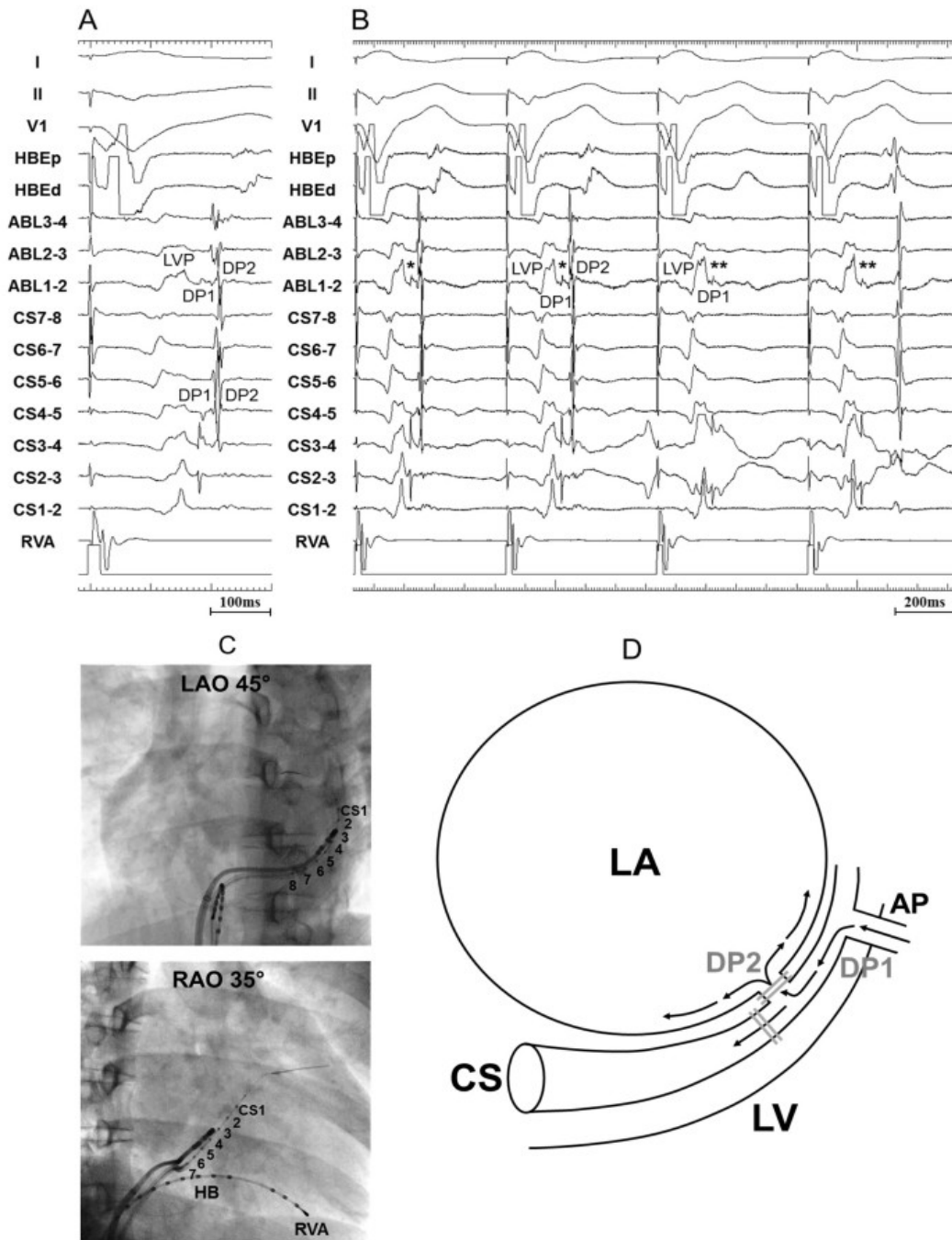
The clinical tachycardia with a cycle length of 325 ms was induced by programmed atrial stimulation and a retrograde P wave was observed approximately at the middle of the R-R interval (**Figure 2A**). During the tachycardia, the earliest ventricular activation was identified at the His-bundle region and atrial double potentials (DPs) were recorded along the CS (**Figure 2B**). The earliest site of the first component of the DPs (DP1) was identified on the

lateral mitral annulus (MA) and the activation sequence was distal-to-proximal. On the other hand, the second component (DP2) exhibited an eccentric activation sequence with the earliest activation site at the posterolateral MA. Programmed ventricular extrastimulation revealed a decremental ventriculoatrial (VA) conduction property with an identical atrial activation sequence as during the tachycardia, which was mainly due to a delay in the conduction between the left ventricular (LV) potentials and DP1 (Figure 2C and 2D). The VA conduction could not be blocked by an intravenous administration of 20mg of adenosine. According to these results, the clinical tachycardia was diagnosed as an orthodromic atrioventricular reentrant tachycardia (AVRT) via the left-sided AP with both antegrade and retrograde decremental conduction properties. Using transeptal and retrograde transaortic approaches, a total of 25 endocardial RF applications targeting the earliest DP1 or DP2 were performed both above and beneath the mitral valve along the lateral through posterolateral MA, but failed to eliminate both the AP conduction and AVRT. Each application of RF energy using a 4-mm-tip ablation catheter (Celsius, Biosense Webster, Diamond Bar, USA) was delivered for a maximum duration of 90 seconds (<30 seconds at most locations) with a power of up to 50W. Mapping was then performed in the CS using the earliest atrial activation during constant ventricular pacing. Within just 6 seconds after commencing the initial RF application within the CS along the posterolateral MA where continuous DP1 and DP2 potentials were recorded, the DP1-DP2 conduction blocked and concomitantly the VA conduction via the AP was abolished (Figure 3A, 3B, and 3C). This finding demonstrated that DP1 was a CS musculature (CSM) potential and DP2 was a left atrial (LA) potential. During sinus rhythm before DP1-DP2 blocked, the LA potentials were immediately followed by the CSM potentials, which were slowly conducted by the LV potentials (Figure 4A). After DP1-DP2 blocked, an isoelectric line was observed between the LA and LV potentials, and the CSM potentials distal to the successful ablation site followed the LV potentials (Figure 4B). In addition, conduction of the CSM also blocked simultaneously between the proximal and distal sides of the successful ablation site. Thus, the activation sequence of the CSM distal to the ablation site changed from proximal-to-distal to distal-to-proximal, but that proximal to the ablation site did not change. An additional RF application within the posterolateral CS, delivered to minimize the risk of any reconnection of the AP, eliminated the LV-CSM conduction. A 12-lead ECG during sinus rhythm exhibited slightly smaller R waves and deeper S waves in the precordial leads after elimination of the AP conduction than before (Figure 1A, 1D), suggesting that the antegrade conduction was not latent but was constantly fusing over both the atrioventricular node and AP before ablation. Thereafter, the clinical tachycardia could never be induced with atrial or ventricular rapid pacing or extra-stimuli.

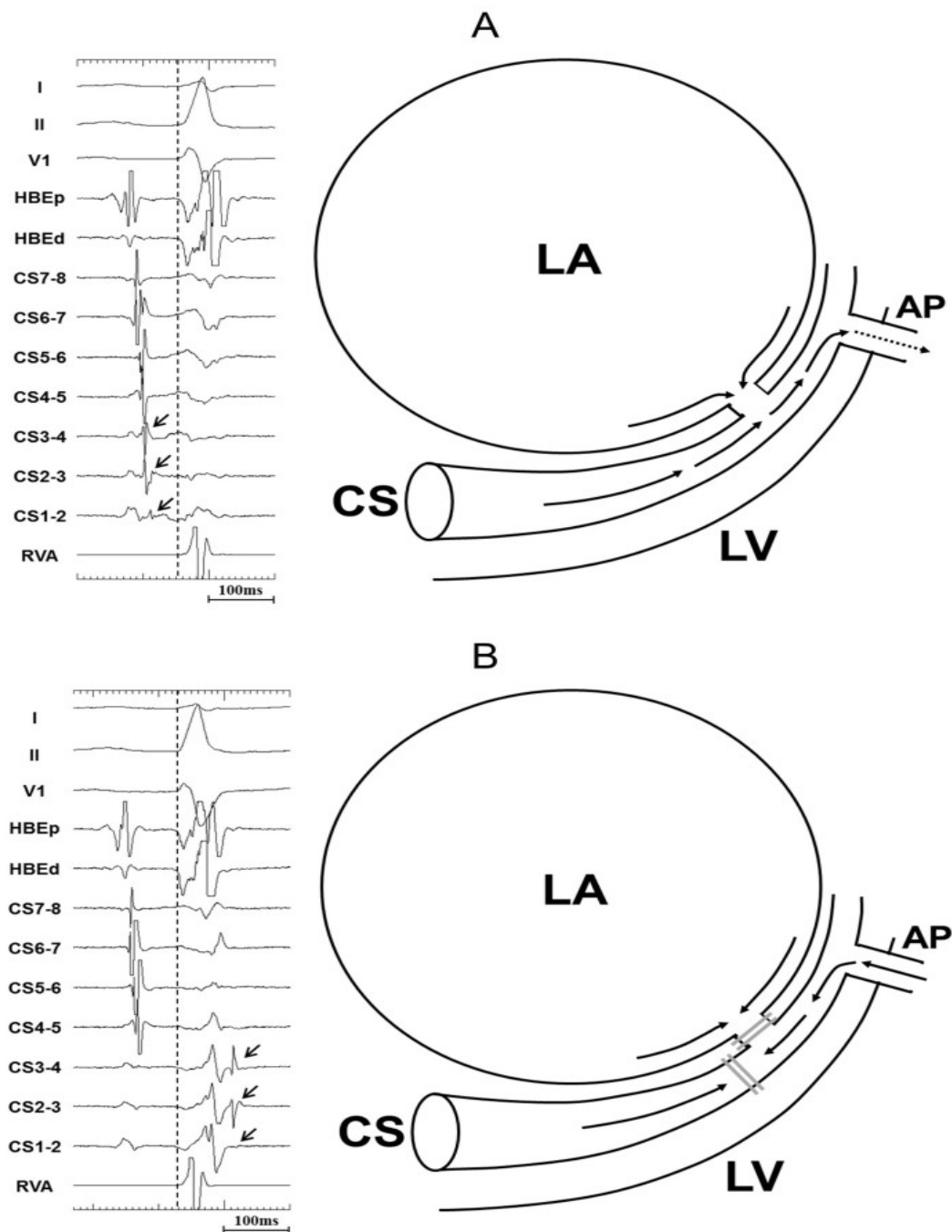
## Discussion

Left-sided atrioventricular APs capable of decremental conduction, especially both antegrade and retrograde decremental conduction, have been rarely described. [1-5] To the best of our knowledge, there have been no published reports that have documented that the CSM is associated with the decremental conduction properties of the APs.

Both a short PQ interval and delta waves, which are ECG features of a Wolff-Parkinson-White (WPW) pattern, were absent in the present case although antegrade conduction via the AP was constantly seen. A possible explanation of the mechanism for this finding is that slow conduction between the CSM and LV led to delayed preexcitation of the LV myocardium at the ventricular insertion site of the AP. Furthermore, incremental atrial pacing resulted in a progressive PQ prolongation because not only the atrioventricular node but also the CSM-LV connection had decremental conduction properties. During sinus rhythm or atrial pacing before ablation, continuous low-amplitude and fragmented electrograms between the CSM and LV potentials were recorded along the CS, suggesting the presence of a CSM-LV conduction delay. The reason why the AP in this case had slow and decremental conduction properties remains unclear.



**Figure 3:** A: Surface and intracardiac electrograms during ventricular pacing at the site that successfully eliminated the AP conduction. The tip of the ablation catheter (ABL1-2) was located near CS4-5 along the posterolateral MA within the CS, and revealed continuous DP1-DP2 potentials. B: Surface and intracardiac electrograms during ventricular pacing immediately before and after eliminating the retrograde AP conduction. In the 1st and 2nd cycles before DP1-DP2 blocked, the VA conduction via the AP was present (\*). In the 3rd and 4th cycles after DP1-DP2 blocked, the VA conduction disappeared, but the LV-DP1 conduction still persisted (\*\*). C: Fluoroscopic images showing the position of the ablation catheter and octapolar electrode catheter (eight 1 mm width electrodes with 5 mm interelectrode spacing) during mapping within the CS in the left anterior oblique (LAO) 45 degree and right anterior oblique (RAO) 35 degree views. CS1 was located on the lateral MA and CS8 on the posterior MA. D: Schematic representation of the retrograde AP conduction pattern conceivable in this case. The AP connected the LV with the LA via the CSM; therefore, DP1-DP2 block, indicating conduction block between the CSM and LA, resulted in the elimination of the VA conduction. The postulated course of the retrograde AP conduction is shown (inset). The gray double lines indicate conduction block by ablation. ABL 1-2, 2-3, and 3-4; distal, middle, and proximal ablation catheter recordings, respectively; AP, accessory pathway; LA, left atrium. The other abbreviations are as in Figures 1 and 2.



**Figure 4:** Surface and intracardiac electrograms and schematic representations of the AP conduction patterns during sinus rhythm before (A) and after (B) eliminating the AP conduction. In the electrograms, the black arrows and dashed vertical lines represent the CSM potentials and QRS onset, respectively. The postulated courses of the AP conduction are shown (inset). The dotted arrow in the schema of Panel A suggests slow conduction from the CSM to the LV. See the text for a detailed explanation. The abbreviations are as in Figures 1, 2 and 3.

A noteworthy finding seen in the present case is that the RF application within the CS blocked the DP1-DP2 conduction, and concomitantly blocked the VA conduction via the AP. This result provides direct evidence that DP1 was a CSM potential and DP2 an LA potential - in this case the AP was conducting through the CSM (**Figure 3A**). Conversely, if DP1 was an LA potential and DP2 a CSM potential, DP1-DP2 conduction block would indicate LA-CSM conduction block and not result in the elimination of the LV-LA conduction via the AP. Therefore, this assumption contradicts the findings in this case.

This CSM-associated AP had some more notable characteristics unlike the previously reported

left-sided APs with Mahaim-like conduction properties. First, most of the APs in the previous reports exhibited only antegrade conduction and an antidromic AVRT was induced. [2-5] In contrast, the AP in this case exhibited not only antegrade but also retrograde conduction and an orthodromic AVRT was induced. Second, an intravenous adenosine administration did not induce conduction block of the AP in this case, while Mahaim-like APs are known to be usually sensitive to adenosine. Third, the CSM lies on the epicardium by nature, thus all endocardial RF applications failed to eliminate this CSM-associated AP conduction. Instead, an RF application within the CS immediately eliminated the AP conduction. In contrast, endocardial ablation successfully eliminated the AP conduction in the previous reports.

We cannot rule out the possibility that this patient had an epicardial oblique atrioventricular AP with a relatively long course and DP1 during the AVRT and ventricular pacing was an AP potential. It is probably difficult to distinguish accurately between a CSM-associated AP and an epicardial oblique atrioventricular AP. Nevertheless, according to the above-mentioned characteristics unlike those of ordinary atrioventricular APs, the AP in the present case was considered to be associated with the CSM.

### Conclusions

We describe a rare case of an orthodromic AVRT via a CSM-associated AP with both antegrade and retrograde decremental conduction properties. We also report that antegrade slow conduction between the CSM and LV resulted in the absence of a shortening of the PQ interval and formation of overt delta waves during sinus rhythm despite the continuous presence of antegrade AP conduction.

### References

1. Murdock CJ, Leitch JW, Teo WS, Sharma AD, Yee R, Klein GJ. Characteristics of accessory pathways exhibiting decremental conduction. *Am J Cardiol* 1991;67:506-510.
2. Nault I, Sacher F, Knecht S, et al. Wide complex tachycardia in a healthy young man. *Europace* 2008;10:1340-1342.
3. Osman F, Stafford PJ, Ng GA. Looks like VT But Isn't - successful ablation of a left free wall accessory pathway with Mahaim-like properties. *Indian Pacing Electrophysiol J* 2009;9:112-118.
4. Goldberger JJ, Pederson DN, Damle RS, Kim YH, Kadish AH. Antidromic tachycardia utilizing decremental, latent accessory atrioventricular fibers: differentiation from adenosine-sensitive ventricular tachycardia. *J Am Coll Cardiol* 1994;24:732-738.
5. Johnson CT, Brooks C, Jaramillo J, Mickelsen S, Kusumoto FM. A left free-wall, decrementally conducting, atrioventricular (Mahaim) fiber: diagnosis at electrophysiological study and radiofrequency catheter ablation guided by direct recording of a Mahaim potential. *Pacing Clin Electrophysiol* 1997;20:2486-2488.