



PERGAMON

Vision Research 38 (1998) 1629–1641

**Vision
Research**

The congenital and see-saw nystagmus in the prototypical achiasma of canines: comparison to the human achiasmatic prototype

 L.F. Dell'Osso ^{a,*}, R.W. Williams ^b, J.B. Jacobs ^a, D.M. Erchul ^a
^a *Ocular Motor Neurophysiology Laboratory, Veterans Affairs Medical Center, and the Departments of Neurology and Biomedical Engineering, Case Western Reserve University and University Hospitals of Cleveland, 10701 East Boulevard, Cleveland, OH, USA*
^b *Department of Anatomy and Neurobiology, University of Tennessee, Memphis, TN, USA*

Received 18 March 1997; received in revised form 24 June 1997; accepted 30 September 1997

Abstract

We applied new methods for canine eye-movement recording to the study of achiasmatic mutant Belgian Sheepdogs, documenting their nystagmus waveforms and comparing them to humans with either congenital nystagmus (CN) alone or in conjunction with achiasma. A sling apparatus with head restraints and infrared reflection with either earth- or head-mounted sensors were used. Data were digitized for later evaluation. The horizontal nystagmus (1–6 Hz) was similar to that of human CN. Uniocular and disconjugate nystagmus and saccades were recorded. See-saw nystagmus (SSN), *not* normally seen with human CN, was present in all mutants (0.5–6 Hz) and in the one human achiasmatic studied thus far. This pedigree is an animal model of CN and the SSN caused by achiasma or *uniocular decussation*. Given the finding of SSN in all mutant dogs and in a human, achiasma may be sufficient for the development of congenital SSN and, in human infants, SSN should alert the clinician to the possibility of either achiasma or uniocular decussation. Finally, the interplay of conjugacy and disconjugacy suggests independent ocular motor control of each eye with variable yoking in the dog. Published by Elsevier Science Ltd. All rights reserved.

Keywords: Congenital nystagmus; See-saw nystagmus; Achiasma

1. Introduction

The Belgian sheepdog is a moderate-sized dog (20–30 kg) with a solid black coat and normally pigmented eyes. The Belgian sheepdogs whose eye movements are the subject of this study come from a single extended family that includes several generations of mutants whose optic chiasms were either absent or malformed [22]. Inheritance of the mutation does not follow any simple Mendelian pattern but almost certainly involves the segregation of one or more recessive alleles. The achiasmatic mutation displays a pattern of misrouting of optic axons opposite to that seen in albinos, in which an excess of fibers cross at the chiasm. In normal dogs, 80% of the retinal fibers decussate. Clinical examination of the mutant dogs reveals a striking nystagmus, head turns, and abnormal behavior that are absent in unaf-

ected relatives. Some aspects of this behavioral complex are similar to those seen in humans with CN.

In an earlier publication [10] we presented the results of the first study of the eye movements of a mammal with achiasma, the total absence of an optic chiasm [15,22]. The achiasmatic dogs studied had congenital nystagmus (CN), *uniocular* saccades, and at least one of them had see-saw nystagmus (SSN), identified both by videotape and direct observation in 1991 and 1992. CN is one of several types of nystagmus of infancy diagnosed by specific waveform, and SSN is a vertical-torsional nystagmus where the movements of the two eyes mimic the motion of the ends of a child's see-saw (i.e. disconjugate vertical and conjugate torsional motion). Uniocular saccades were saccades by either eye while the other made none; there were also saccades of different amplitudes or directions.

In our previous study [10], the eye movements of unstabilized dogs were recorded with a mobile monitoring system and data were digitized with only 8-bit

* Corresponding author. Tel.: +1 216 4213224; fax: +1 216 2313461; e-mail: lfld@po.cwru.edu.

resolution. This methodology was subject to movement artifact (due to movement of either the dog, the hand-held infrared (IR) spectacles, or both) and excessive digitization noise, requiring the use of digital filtering to facilitate analysis of the eye-movement records. It also raised questions regarding the occurrence of uniocular saccades, found in the records. However, attempts to produce uniocular shifts in the eye-movement traces by movement of the IR spectacles failed; all artifacts appeared in *both* traces simultaneously regardless of the plane of induced motion. In addition, accurate calibration was precluded. Nevertheless, CN waveforms could be identified in the horizontal plane and the conjugacy of the eye movements, or lack of it, could be assessed. As controls, the eye movements of normal members of this family of Belgian sheepdogs and of one Irish setter were also recorded.

In order to obtain more accurate recordings, it was necessary to design and build an apparatus that would allow us to immobilize the dogs' heads, mount the recording apparatus in a stable manner (either on the frame or the dogs' heads), present targets at known gaze angles, and digitize the data at a higher resolution. The resulting apparatus is described in Section 2. These more accurate and noise-free recordings allowed the characteristics of the ocular oscillations present in both the horizontal and vertical planes to be more fully determined. Although the obligate torsional component of the SSN was not directly measured, it was visible in both the videos and by direct observation of the dogs' nystagmus.

As the results of this study demonstrate, this family of Belgian sheepdogs is an animal model for human CN as well as for the SSN that accompanies achiasma in both species.

2. Methods

All applicable N.I.H. guidelines and regulations regarding the care and handling of the dogs are followed at the kennel and were adhered to in this study.

2.1. Recording

We designed and constructed an apparatus to comfortably hold and restrain the heads of untrained dogs. It combined the use of a dog sling (Alice King Chatham Medical Arts), massive optical columns (Ealing Electro Optics), photographic quick-locking arms (Bogen), and various additional items, constructed in-house; the assembled components were then affixed to a heavy metal table. The purpose of the sling was to allow the dogs' bodies to hang comfortably with the paws off the table top, thereby preventing any use of the legs to thrust the body. The dogs' heads were

stabilized using modified umpire's masks that were moved into position either around or beneath the dog's head and held rigidly by the locking arms. Once the head was stabilized, the eye movement measuring apparatus was either brought in front of the dog and fixed to the frame by another locking arm (earth-fixed) or placed on the dog's head using eyeglass frames with velcro on the arms to adhere to a velcro head harness (head-fixed). This latter arrangement provided the lowest signal-to-noise ratio due to head movement, and mimics the arrangement we routinely use for recordings from humans.

Horizontal and vertical eye movement recordings were made using a mobile system employing the IR reflection method; the IR system bandwidth was 0–100 Hz and drift was less than 10 mV/h (0.03°/h). Eye movements were calibrated using simultaneous light and sound sources at ± 15 or $\pm 20^\circ$ horizontally and $\pm 10^\circ$ vertically. Eye position signals were digitized on-line at either 200 or 400 samples/s and simultaneously displayed on the computer screen using the ViewDac data acquisition software (Keithley). Data files for each 20- or 40-s recording intervals were stored in binary format with 16-bit resolution for later analysis. We used an additional IR system (Ober) to simultaneously record both eyes in both planes on one of the dogs. The data were digitized at 300 Hz and stored with 12-bit resolution.

The combination of the sling apparatus with head and IR spectacle stabilization and 16-bit digitization eliminated the artifact problem present in our previous study, and confirmed the presence of uniocular saccades, which were recorded with both systems. Constant monitoring of each dog, by placing a hand on the back of their head, allowed us to note any movement that might occur during a 20- or 40-s record; such movement was rare and, when it occurred, the data were excluded.

Due to the nature of the primary recording apparatus, simultaneous measurements could be made from both eyes in either the horizontal or vertical plane, but not in both planes simultaneously. However, *either* eye could be recorded in *either* plane, allowing simultaneous recordings of one eye in the horizontal plane and the other in the vertical plane. Thus, we were able to make waveform, amplitude, frequency, and phase comparisons between the eyes in either plane when recording both eyes in that plane and, using that information plus simultaneous horizontal and vertical data, imply interplane waveform, frequency, and phase differences for each eye. Simultaneous recordings of both eyes in both planes, made with the Ober system on M6, verified the phase relationship between the horizontal and vertical motion of the eyes.

2.2. Protocol

Eye movements were recorded in a quiet examination room at the kennels where these untrained dogs are housed. The dogs were encouraged to view LEDs, blinking toys and noise-making toys at known gaze angles. Either horizontal, vertical or a combination of horizontal and vertical eye movements were made from the two eyes simultaneously under binocular or monocular viewing conditions. Because of the cooperative nature of most sheepdogs, we were able to obtain eye-movement records from all dogs but one without the use of sedatives. One dog required 20 mg of xylazine in order to obtain artifact-free records; a similar dose was found not to effect the nystagmus in our previous study.

The absence of a chiasm in the mutant dogs has been verified by anatomical post-mortem studies [15,22]. All mutant dogs with nystagmus in this family who have been studied anatomically, either lacked a chiasm or, in one case, had a severely maldeveloped chiasm. Three of the dogs, two from this study (M4 and M6) and one from the previous study (M3) have been studied anatomically and the absence of a chiasm verified. The pedigree of this family was shown in Figure 1 of the previous study [10]. During the initial part of this ocular motor study, we recorded from the three remaining mutants (M4, M5, and M6).

2.3. Analysis

Data analysis (and filtering, if required), statistical computation of means and standard deviations, and graphical presentation were performed using the ASYST (Keithley, Taunton MA) software for scientific computing. Eye velocities were obtained by digital (two-point, central-difference algorithm) differentiation of the position signals. Further details on ASYST may be found elsewhere [11].

3. Results

We recorded the eye movements of two male mutants (M5 and M6) and one female mutant (M4) to determine the characteristics of the previously identified CN and of the SSN diagnosed from both the videotapes and direct observation. In addition to eye-movement recording, we videotaped the eye movements of the mutant dogs over a period of several years (1991–1995). In 1993, examination of the videotapes revealed nystagmus that was at times disconjugate or contained a vertical/torsional see-saw component, and the occurrence of *uniocular* saccadic eye movements in all mutant dogs.

3.1. Eye movements of mutants

Our earlier, uncalibrated eye movement recordings of these dogs revealed CN-like waveforms in the horizontal plane coupled with transient SSN in at least one mutant (the SSN was identified from videotapes) [10]. In this study, we recorded both the horizontal and vertical components of the nystagmus exhibited by the mutant dogs.

The horizontal component of M5's nystagmus was either a higher frequency pendular (Fig. 1a) or lower frequency jerk (Fig. 1b) nystagmus. Pendular nystagmus is approximately sinusoidal and jerk refers to the saccadic fast phases of nystagmus. The amplitude of M5's horizontal nystagmus varied from 1 to 15°, and the frequencies were ~2.5 Hz for the pendular and ~1 Hz for the jerk nystagmus. As Fig. 1a shows, there could be a large amplitude difference in the pendular nystagmus of the two eyes. In Fig. 1b, increasing velocity slow phases and extended 'centralisation' (similar to jerk with extended foveation (J_{ef}) in human CN) are present in the fixating left eye. Since dogs have an area centralis instead of a fovea, we call it, 'jerk with extended *centralisation*' (J_{ec}). Some waveforms in Fig. 1a exhibit extended centralisation. Also evident in Fig. 1b, is a *uniocular* saccade in the right eye. In the vertical plane, M5 exhibited either a pendular SSN (Fig. 2a) or a jerk SSN (Fig. 2a,b). The SSN varied from 0.5–10° at frequencies of 3–7 Hz for the pendular and 0.5–3 Hz for the jerk waveform. In the horizontal plane, the oscillations of both eyes were conjugate (typical CN). In the vertical plane, they were phase-shifted by 180° (typical SSN), with occasional short intervals of 90–180° phase shifts. The fast phases of the jerk SSN, when present, were phase-locked with rightward (or leftward) horizontal fast phases. This produced *diagonal jerk* SSN with the right-eye fast phases, up and right (or left) while intorting and the left-eye fast phases moving down and right (or left) while extorting. The nystagmus of M5 was the most complex combination of horizontal CN and vertical SSN seen in any of the mutant dogs. Fig. 3a shows the simultaneous upward and leftward (downward and rightward) *diagonal pendular* SSN of the right eye and the corresponding downward and leftward (upward and rightward) motion of the left eye. Fig. 3b shows *diagonal dual jerk* SSN with simultaneous upward and leftward fast phases of the right eye and downward and leftward fast phases of the left eye; the superimposed diagonal pendular SSN is as described above for Fig. 3a. Monocular fixation revealed neither a latent component to the CN nor latent nystagmus.

The nystagmus of M6 consisted of either a high-frequency, pendular horizontal component (Fig. 4a) or J_{ec} , the canine equivalent of jerk with extended foveation (Fig. 4b). The amplitude of the horizontal pendular nystagmus varied from 1 to 4° at frequencies between 5

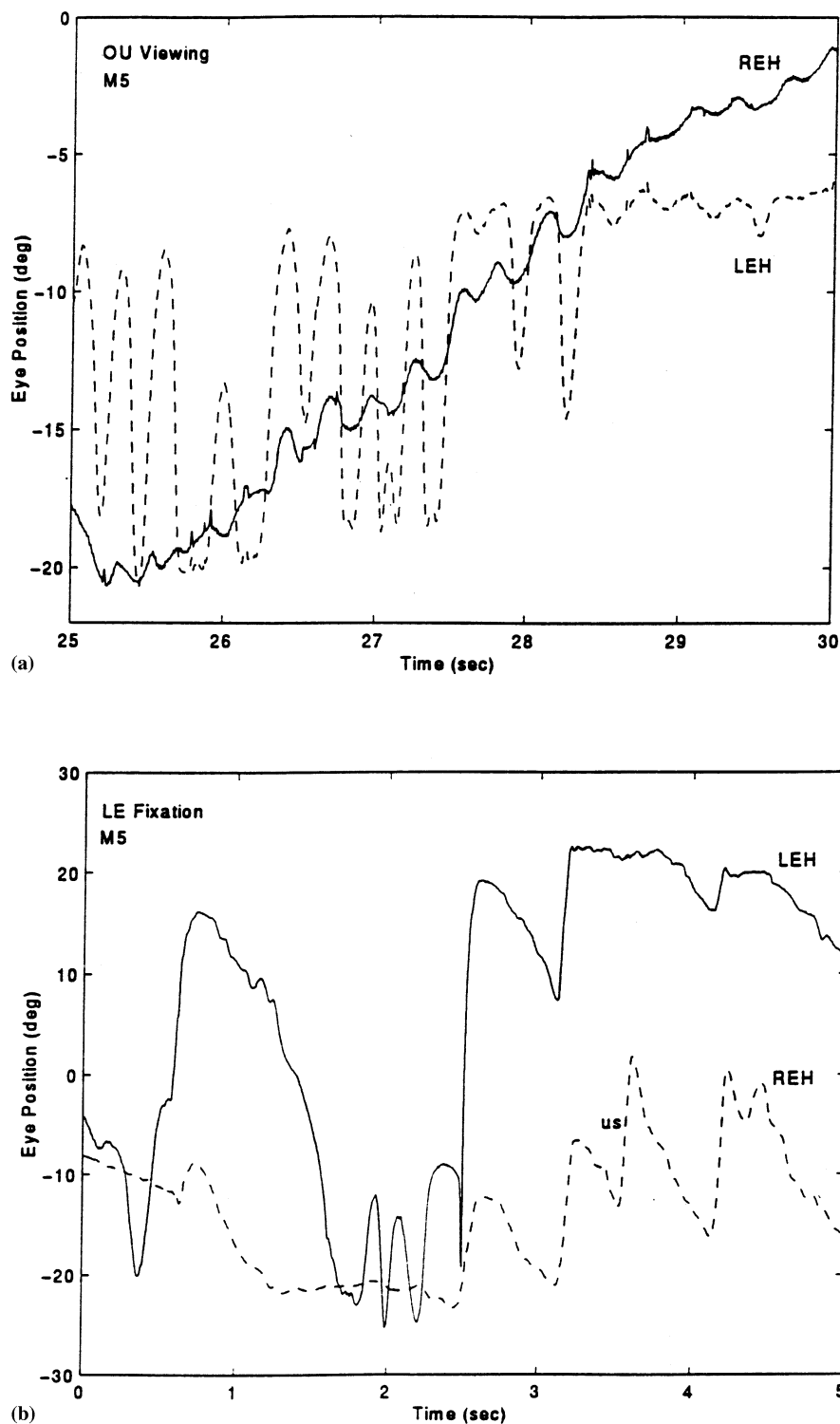


Fig. 1. Right- and left-eye horizontal recordings from M5 during binocular viewing. Large amplitude differences in both the pendular (a) and jerk (b) nystagmus are evident. Also seen in (b) is a unocular saccade in the right eye. In this and other figures: REH, right eye horizontal; LEH, left eye horizontal; OU, binocular; us, unocular saccade; s, conjugate saccade; rightward and upward movements are positive, and the time values on the x-axis are the actual intervals from their respective 20- or 40-s records.

and 6 Hz. The jerk nystagmus was 12–16° at ~1 Hz. The SSN of M6 was pendular (Fig. 5a,b) with variable amplitudes in either eye of 1–6°; the frequency varied from 3 to 6 Hz. Conjugate saccades are also present in

Fig. 5. In the horizontal plane, the oscillations of both eyes were usually conjugate (typical CN), with occasional phase shifts of 90–180°. In the vertical plane, they were phase-shifted by 180° (typical SSN). Monoc-

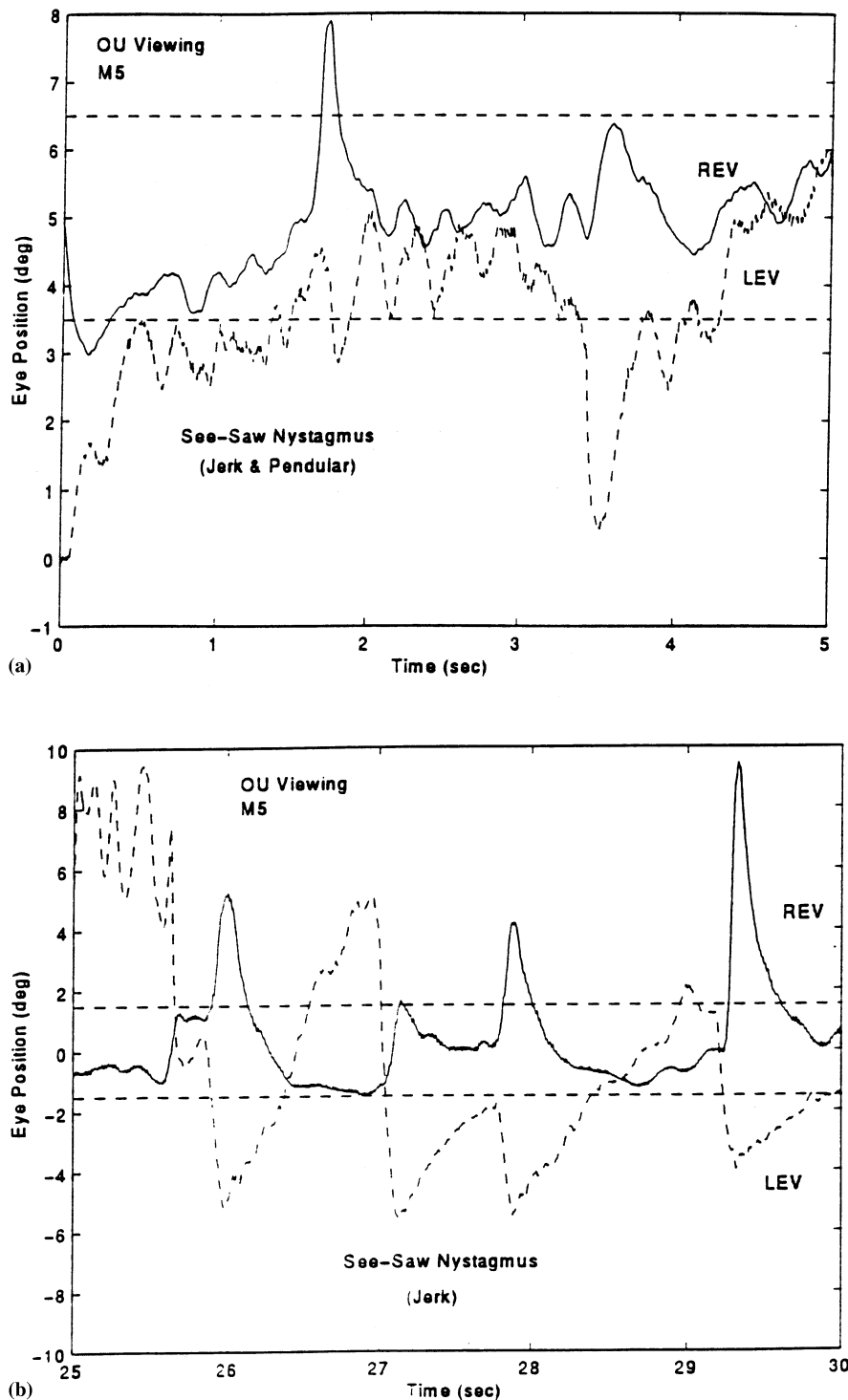


Fig. 2. Right- and left-eye vertical recordings from M5 during OU viewing. Both jerk and pendular see-saw nystagmus, in (a), and jerk see-saw nystagmus, in (b), are seen. In this and other figures: REV, right eye vertical; LEV, left eye vertical; and the dashed lines indicate the extent of either the horizontal ($\pm 3^\circ$) or vertical ($\pm 1.5^\circ$) area centralis.

ular fixation revealed neither a latent component nor latent nystagmus.

M4 had a slower horizontal pendular component (Fig. 6a) and exhibited jerk waveforms when fixating at either $+20^\circ$ or -20° (Fig. 6b). The pendular compo-

nent varied from 1 to 5° at frequencies from < 1 to 2 Hz and the jerk from 5 to 10° at ~ 3 Hz. Frequent *uniocular* saccades are indicated in Fig. 6, and a *uniocular* square-wave jerk and two large conjugate saccades in Fig. 6b. In the vertical plane, the pendular SSN of

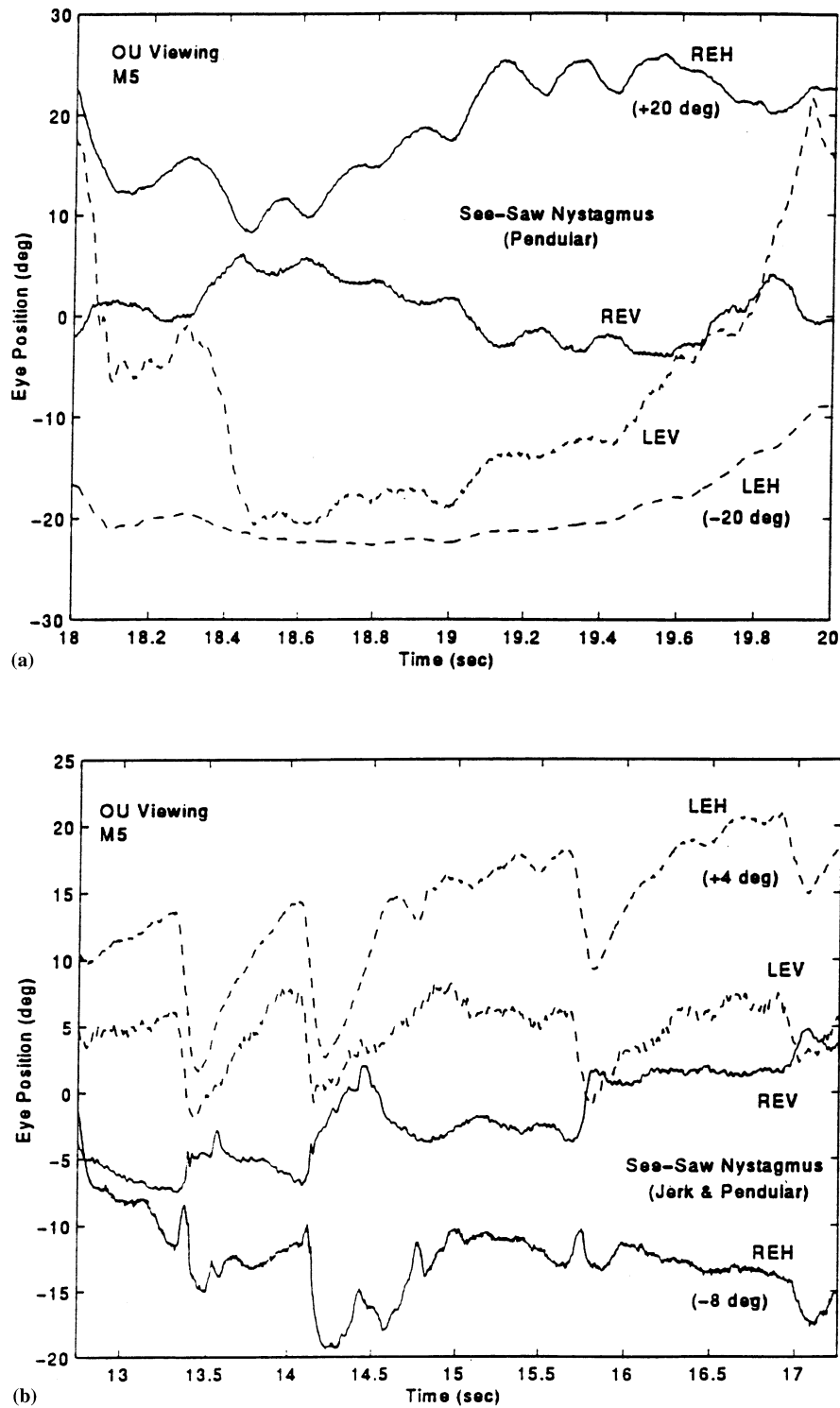


Fig. 3. Right- and left-eye horizontal and vertical recordings from M5 during OU viewing. (a) Pendular SSN with simultaneous pendular CN at the same frequency resulted in a diagonal pendular SSN, moving up-and-left (down-and-right) in the right eye and down-and-left (up-and-right) in the left eye. (b) Dual jerk (jerk plus pendular) SSN with simultaneous jerk-right CN resulted in a diagonal dual jerk SSN, beating up-and-left in the right eye and down-and-left in the left eye. During the slow phases (down-and-right in the right eye and up-and-right in the left eye), there was a superimposed diagonal pendular SSN, as described in (a). The horizontal traces in (a) and (b) were shifted by the indicated amounts for clarity.

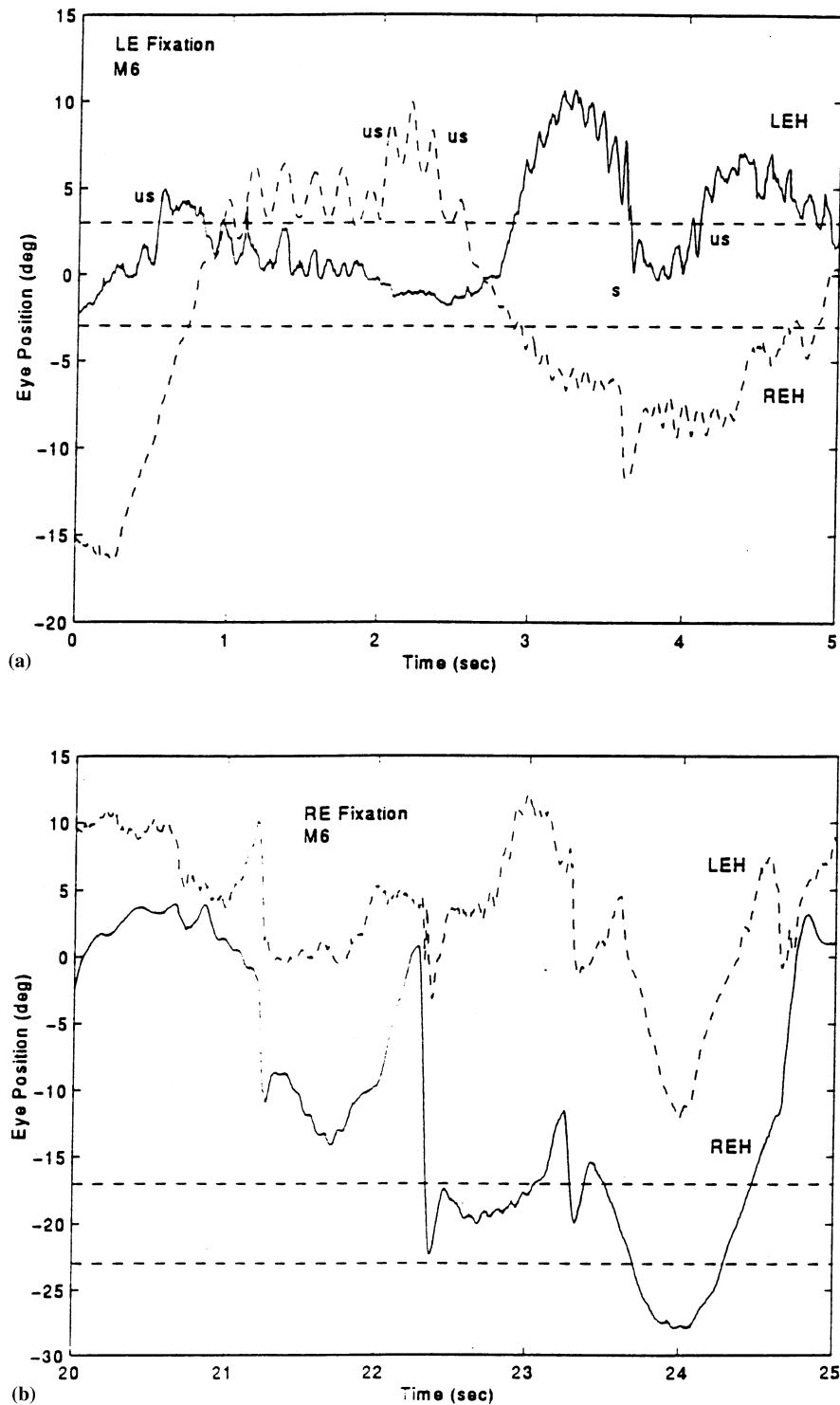
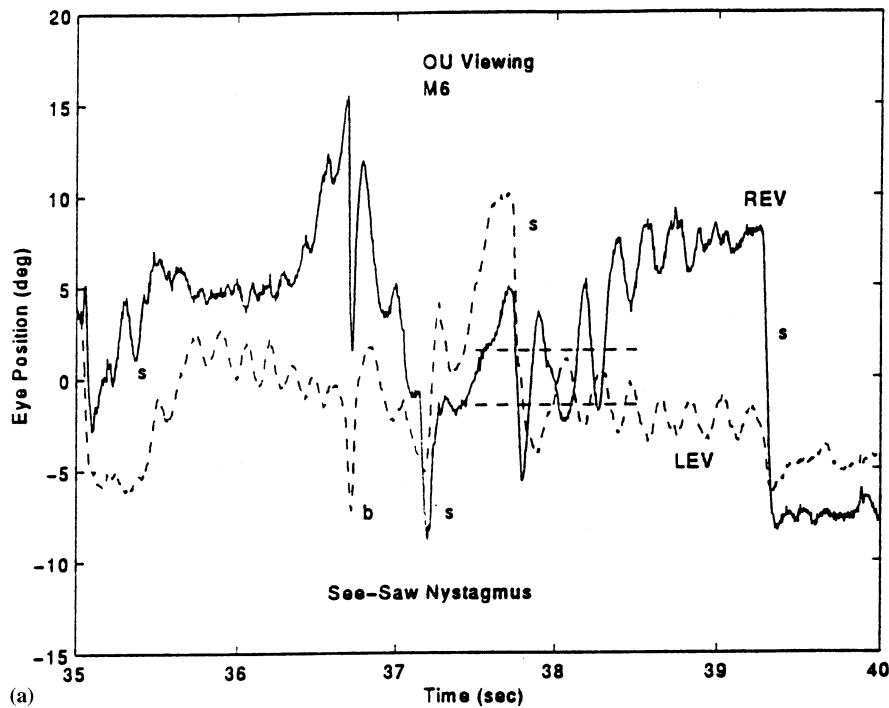


Fig. 4. Right- and left-eye horizontal recordings from M6 during OU viewing. Large amplitude differences in both the pendular (a) and jerk (b) nystagmus are evident. Also seen in (a) are unocular saccades in both eyes and a conjugate saccade.

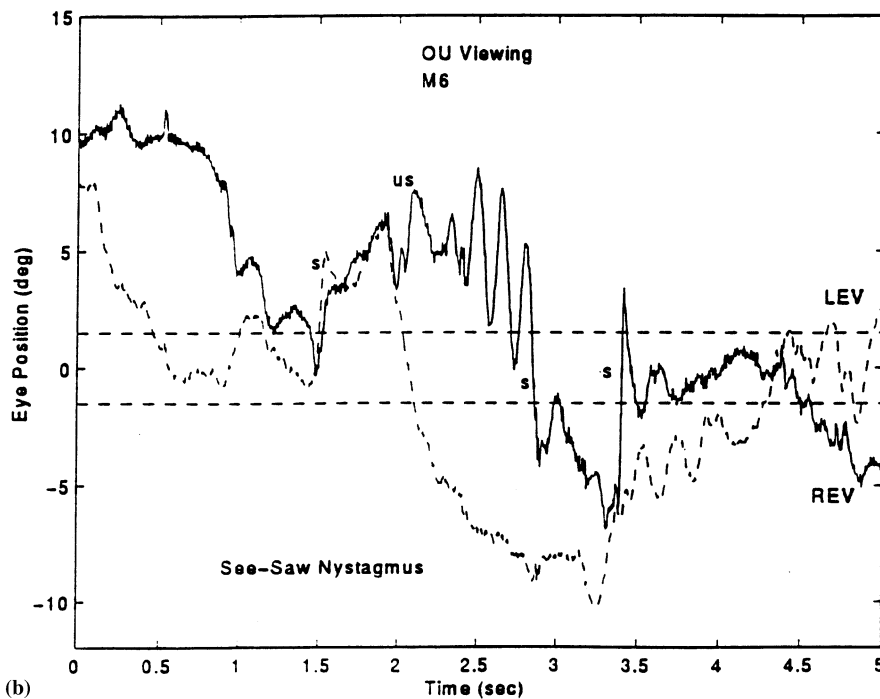
M4 was also slower than that of M5 or M6 (Fig. 7a). The SSN varied from 5 to 15° at ~1 Hz. Admixed with the SSN were conjugate, vertical pendular oscillations (Fig. 7a,b). In the horizontal plane, the oscillations of both eyes were either conjugate (typical CN) or occasionally phase-shifted by 180°. In the vertical

plane, they were phase-shifted by 180° (typical SSN), or 0°, (CN with a vertical component). Monocular fixation revealed neither a latent component nor latent nystagmus.

Due to both frequency and waveform (pendular vs. jerk) differences, the phase relationships between the



(a)



(b)

Fig. 5. Right- and left-eye vertical recordings from M6 during OU viewing. Pendular see-saw nystagmus and conjugate saccades with different amplitudes in each eye are seen in (a) and (b). A unocular saccade in the right eye is seen in (b). b, blink.

horizontal and vertical nystagmus components of each eye could vary from 0 through 180° or be undefined for any given interval of time and for any given dog. For example, the only dog to show jerk SSN (M5) did so at frequencies from 0.5 to 3 Hz. The horizontal oscilla-

tions were either 2.5 Hz (pendular) or 1 Hz (jerk). In the former case, and for all jerk SSN frequencies except 1 Hz, the horizontal and vertical phase relationship is undefined or not constant. At 1 Hz, the horizontal and vertical fast phases were time-locked, producing a diag-

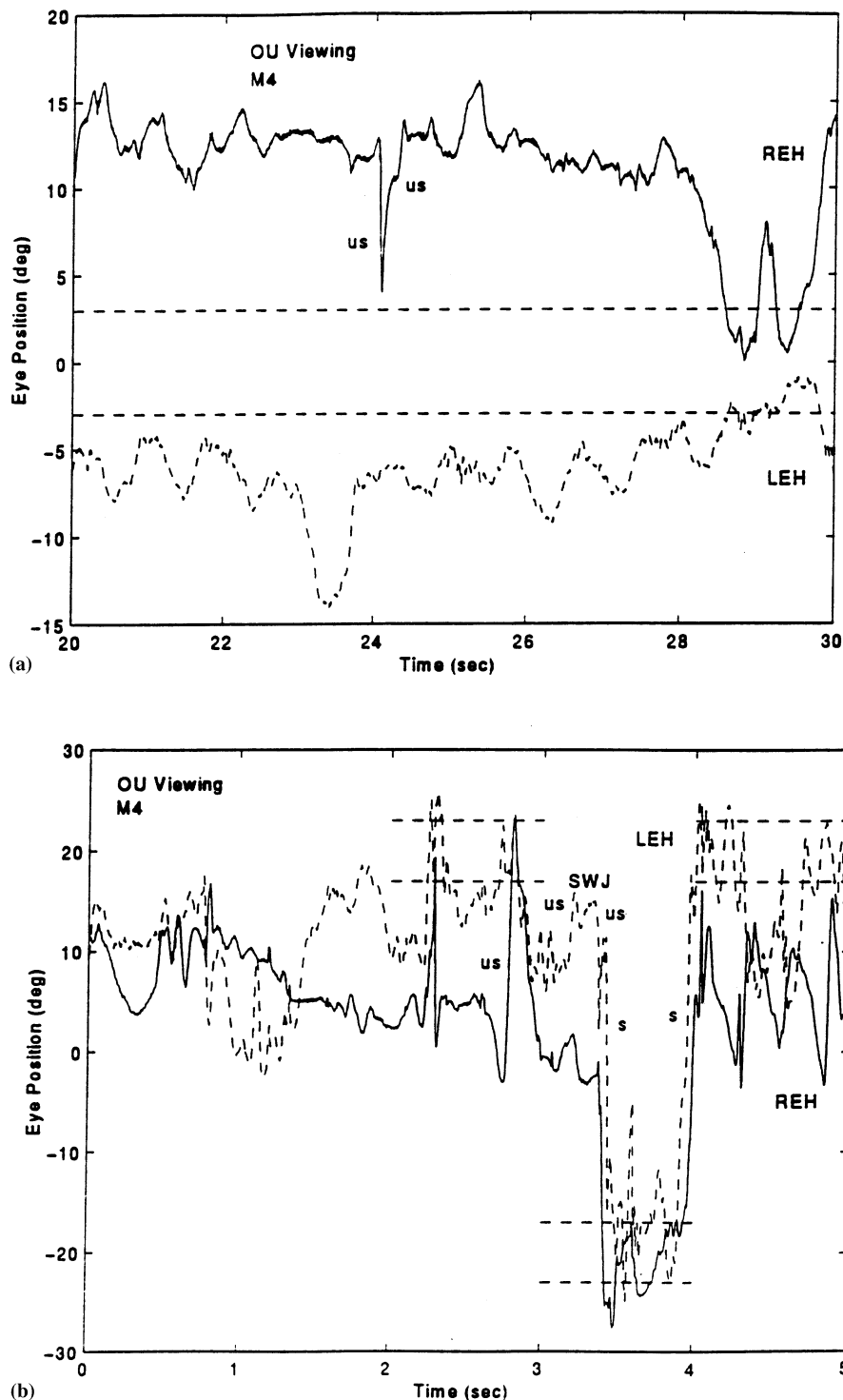


Fig. 6. Right- and left-eye horizontal recordings from M4 during OU viewing. Slow pendular, in (a), and jerk, in (b), nystagmus are evident. Uniocular saccades in the right eye are seen in both (a) and (b), and a uniocular square-wave jerk (SWJ) in the left eye and conjugate saccades are seen in (b).

onal jerk SSN. When the dogs exhibited their more common pendular SSN, its phase relationship to a horizontal jerk CN was also undefined, as it was to a pendular CN of another frequency. When the horizontal and vertical pendular frequencies were the same, the phase relationship was either 0° (producing

a diagonal pendular SSN up and to the right and down and to the left in the right eye) or 180° (producing a diagonal pendular SSN, up and to the left and down and to the right in the right eye); in each case the left eye moved in the opposite vertical direction.

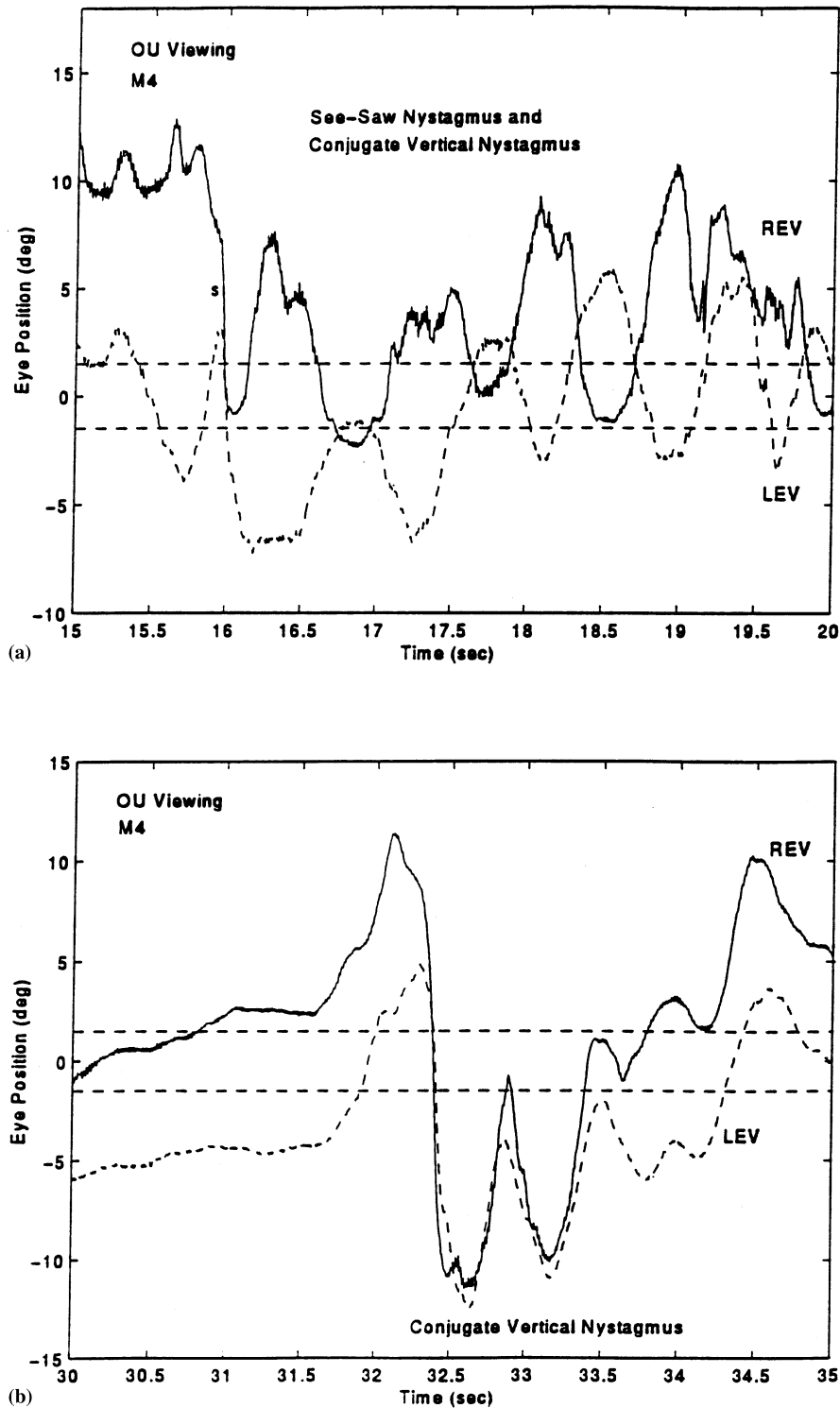


Fig. 7. Right- and left-eye vertical recordings from M4 during OU viewing. Pendular see-saw nystagmus is shown in (a) and conjugate vertical nystagmus in both (a) and (b). Conjugate saccades are seen in (a).

In addition to their normal, conjugate saccades, all mutants were able to make uniocular and disconjugate (convergent or divergent) saccades. Also, uniocular square-wave jerks were recorded (M4 and M5), as were

uniocular horizontal CN (M5 and M6), upbeat (M5, either eye) nystagmus, or horizontal CN of different frequencies in the two eyes (M5 and M6, either eye of greater frequency).

3.2. Chiasmal anatomy of mutants

At the time of this paper, the exact status of the chiasmal deficits in three of the mutant dogs had been determined by post-mortem anatomical studies. M3, an adult male who was included in our previous study [10], was a totally achiasmatic dog with absolutely no crossing fibers. M4, an adult female, also had a complete absence of retinal crossing fibers; she was a totally achiasmatic dog. M5, an adult male, has not yet been studied anatomically. M6, an adult male, had virtually no crossing fibers from the right optic nerve, but 58% of the fibers from the left optic nerve crossed at the chiasm (normal dogs have 80–82% crossed fibers). Thus, he had only *uniocular decussation* at the chiasm, with a highly abnormal visual-field topography in the right visual cortex [13].

4. Discussion

Our findings extend and refine previous work on the horizontal nystagmus in achiasmatic Belgian sheepdogs; it is the canine equivalent of human CN. However, the congenital SSN is a sign of achiasma in dogs [10]. In addition, we confirmed, with head-stabilized dogs, that uniocular saccades and oscillations were a part of the ocular motor signs associated with canine achiasma.

4.1. Degree of achiasma and see-saw nystagmus

Post-mortem examinations of the brains of three of the mutant dogs with both CN and SSN, revealed variation in the degree of chiasmal malformation. Total elimination of a crossed retinofugal projection (in M3 and M4) was associated with both forms of nystagmus. In contrast to human congenital bitemporal hemianopia, all achiasmatic dogs had an intact nasal hemiretina with normal, or near normal, populations of retinal ganglion cells. The partial (uniocular) decussation found in M6, who had 58% of the axons from one eye crossing, also was associated with both CN and SSN. It remains to be determined just how severe a deficit in the crossing fibers from one eye is necessary to result in CN or SSN in either dogs or humans.

A key issue is whether CN and SSN in achiasmatic dogs is directly associated with the failure of retinal axons to cross, or whether they are due to anatomical abnormalities in brainstem ocular motor pathways. Analysis of the achiasmatic dogs revealed remarkably normal brain anatomy [12,15,22]. The corpus callosum, anterior and posterior commissures were intact and of approximately normal size. Brain weight was normal and there was no suggestion of holoprosencephaly. Cytoarchitecture of the pretectum, midbrain, and pons

appeared normal. The only notable CNS abnormalities were disrupted patterns of lamination in the dorsal lateral geniculate nucleus and, of course, dramatic alterations in visual field maps in both the geniculate, the visual cortex [13,14,22], and presumably in pretectum and superior colliculus. Although we have not yet demonstrated normal anatomical connections among ocular motor nuclei in achiasmatic dogs, they do make conjugate saccades, raising the possibility that the abnormal eye movements may be secondary to the retinal decussation error and the reduced need for binocular coordination.

4.2. Eye movements in an achiasmatic human

Ocular motility studies of achiasmatic dogs, and collaborative efforts, have been significant factors contributing to the recognition and elucidation of the achiasmatic syndrome in humans [4]. These collaborative efforts led to the discovery of CN and SSN in dogs and, later, in a human. When we first recognized (from a videotape in 1993) that this achiasmatic human had SSN, the previous observation of SSN, noted in the video of one dog (1991) and by direct observation and additional video (1992), took on greater importance. It was later confirmed in this laboratory, by re-examination (in 1993) of the 1992 videos, and again (in 1995) by both videos and recordings, that *all* mutant sheepdogs studied also had SSN. Its presence in some of them had been masked by the CN, which had some vertical components. What was originally thought of as a unique secondary characteristic of the achiasmatic dog, now appeared to be a potentially useful diagnostic feature of achiasma in both species.

The condition of achiasma *in both dogs and humans* is associated with horizontal CN and congenital SSN; the occurrence of congenital SSN was unknown in dogs and is rare in humans, including a transient finding in albinism [16,18,23], where an excess of crossing fibers exist. An extensive analysis of the data from the human with achiasma (recorded at the Department of Physiology, Erasmus University, Rotterdam) was prepared by L.F.D. in 1994 [3]. However, the human data did not support the statement that the SSN damped with darkness, and it has been clearly demonstrated that the human could not have exhibited 'reversed pursuit' [6,9,17].

The 1994 analysis of the human achiasmatic patient's eye-movement data did reveal that she exhibited typical CN waveforms (predominantly pendular with foveating saccades (P_{fs}), pendular, pseudocycloid, and J_{ef}) and a pendular SSN. The following observations were made in that analysis. The CN frequencies ranged from 2 to 4 Hz and the SSN from 1.3 to 1.6 Hz. The human patient was unable to repeatedly foveate the target accurately, requiring a $\pm 2.5^\circ$ 'expanded' window to

define her foveation. She had both horizontal and vertical strabismus and exhibited alternating fixation. During right-eye fixation, her left eye was eso- and hypotropic and during left-eye fixation, her right eye was eso- and hypertropic. She had occasional square-wave jerks, as did her unaffected sister [19]. Convergence damped her CN, improving her foveation periods. Nystagmus acuity functions, calculated with the expanded window, showed improvement at near, conforming to her higher visual acuity at near [20]. Foveation was consistently better for near than for far targets. Thus, CN in this achiasmatic human behaved in a typical fashion, despite the achiasma, and was essentially identical to that described in this and our previous [10,21] reports for the dogs.

4.3. Achiasmatic dogs and humans

The characteristics of both the CN and SSN in the two species are summarized in Table 1. The data from four dogs and one human are similar in both species in all characteristics but one. The conjugacy of the horizontal CN in dogs could vary from 0 to 180° in dogs, but was always 0° in the human subject studied. This unique interruption of conjugacy in the CN of the dogs is reflected in the appearance of *uniocular* saccades in their records, a phenomenon not replicated in the human recordings.

The SSN and CN of achiasmatic dogs often had different frequencies. Analysis of the human data also showed appreciable differences in SSN and CN frequencies. As a consequence, the horizontal CN cannot be continuously phase-locked to the vertical SSN. This does not preclude phase locking of motion in both planes when the two frequencies coincide, as shown in Fig. 3. In these respects, our conclusions differ from an earlier suggestion that the two oscillations are always coupled [2] (but cf. their Figure 12), or that *only* the human had SSN [1].

Table 1
Nystagmus characteristics in achiasma

Nystagmus	Dogs (4)	Humans (1)
CN	Yes	Yes
Waveforms	P,J	P,J
Amplitude (°)	1–15	0.5–10
Frequency (Hz)	1–6	2–4
Conjugacy (°)	0–180	0
Plane	H ± V	H
SSN ^a	Yes	Yes
Waveforms	P,J	P
Amplitude (°)	0.5–15	0.5–6
Frequency (Hz)	0.5–6	1.3–1.6

P, pendular; J, jerk; H, horizontal; V, vertical.

^a Not seen in usual CN population.

As indicated above, congenital SSN is a rare condition. It has characteristics similar to the ocular tilt reaction and to dissociated vertical divergence, a form of congenital strabismus. In both, the elevated eye intorts and the depressed eye extorts. Lesions of the optic chiasm are associated with SSN and suggest that interruption of subcortical pathways involved in adaptive control of the vestibular system may be involved in the genesis of SSN. Based on the diagnoses (and later recordings) of congenital SSN in two species with achiasma, its otherwise rarity, and its presence in 50% of humans with bitemporal hemianopia (personal communication, W.F. Hoyt), the possibility is raised that the absence of decussating retinal axons (e.g. due to achiasma) may be a sufficient condition for its development; uniocular decussation may also result in SSN. This has potentially important implications for the clinical approach to infants with SSN. It may prove useful to screen these infants, using MRI to detect achiasma or structural chiasmal defects resulting in total or uniocular interruption of the crossing fibers from the retina; VEP may also be used to detect abnormalities in the decussation of retinal fibers.

4.4. Animal model for CN

Although the achiasmatic syndrome is not a common precondition for human CN, the nystagmus waveforms in mutant dogs are those of CN rather than some other type of nystagmus. The presence of braking [7] and 'foveating' saccades and 'foveation' periods, as well as the waveforms in achiasmatic dogs, are similar to those considered pathognomonic of human CN (P_{fs} , J_{ef} , and pseudopendular with foveating saccades (PP_{fs})) [8]. The less well-developed area centralis of the dog, compared to the human fovea, allows for considerably wider latitude in defining 'foveation'. The achiasmatic dogs exhibited uniocular nystagmus and, at times, lacked horizontal phase conjugacy; the one achiasmatic human recorded did not show these traits.

Since, CN in humans appears to be a disorder waiting to happen (being catalyzed by any one of many visual afferent problems, by genetic factors, or in the absence of any clinically evident problems), achiasmatic dogs represent an animal model in which anatomical, physiological, behavioral and therapeutic studies of the CN can be carried out.

4.5. Ocular motor organization

Dogs are a binocular, hunting mammal with an ocular motor system presumably quite similar to monkeys and humans. Dogs normally make conjugate movements to maintain binocular single vision. The achiasmatic dogs can, however, exhibit both uniocular saccades and oscillations. This suggests that, in addi-

tion to the anatomically separate populations of burst neurons on each side of the brainstem that synapse with anatomically separate populations of neural-integrator neuronal networks on their respective sides of the brainstem, there may exist anatomically separate neuronal populations (burst and neural-integrator) for each eye on both sides of the brainstem [5]. These populations would normally be yoked and fire in synchrony to produce conjugate eye movements. When yoking fails to develop, each population might be able to fire independently to innervate its respective eye muscle and move its respective eye in a desired direction. The striking incidence of uniocular saccades in achiasmatic dogs suggested that yoking could be broken to reveal an ocular motor architecture similar to that of the chameleon. The question of ocular motor architecture remains controversial and unresolved by current studies of disconjugate eye movements in humans and monkeys.

Acknowledgements

This work was supported in part by the Office of Research and Development, Medical Research Service, Department of Veterans Affairs (Dr. Dell'Osso) and by NEI RO1-6627 (Dr. Williams).

References

- [1] Apkarian P, Bour L, Barth PG. A unique achiasmatic anomaly detected in non-albinos with misrouted retinal-fugal projections. *Eur J Neurosci* 1994;6:501–7.
- [2] Apkarian P, Bour LJ, Barth PG, Wenniger-Prick L, Verbeeten B Jr. Non-decussating retinal-fugal fibre syndrome. An inborn achiasmatic malformation associated with visuotopic misrouting, visual evoked potential ipsilateral asymmetry and nystagmus. *Brain* 1995;118:1195–216.
- [3] Apkarian P, Dell'Osso LF, Ferraresi A, Van der Steen J. Ocular motor abnormalities in human achiasmatic syndrome. *Invest Ophthalmol Visual Sci* 1994;35:1410.
- [4] Dell'Osso LF. See-saw nystagmus in dogs and humans: an international, across-discipline, serendipitous collaboration. *Neurology* 1996;47:1372–4.
- [5] Dell'Osso LF. Evidence suggesting individual ocular motor control of each eye (muscle). *J Vestibular Res* 1994;4:335–45.
- [6] Dell'Osso LF. Evaluation of smooth pursuit in the presence of congenital nystagmus. *Neuro-ophthalmology* 1986;6:383–406.
- [7] Dell'Osso LF, Daroff RB. Braking saccade—A new fast eye movement. *Aviation Space Environ Med* 1976;47:435–7.
- [8] Dell'Osso LF, Daroff RB. Congenital nystagmus waveforms and foveation strategy. *Documenta Ophthalmol* 1975;39:155–82.
- [9] Dell'Osso LF, Van der Steen J, Steinman RM, Collewijn H. Foveation dynamics in congenital nystagmus II: Smooth pursuit. *Documenta Ophthalmol* 1992;79:25–49.
- [10] Dell'Osso LF, Williams RW. Ocular motor abnormalities in achiasmatic mutant Belgian sheepdogs: unyoked eye movements in a mammal. *Vis Res* 1995;35:109–16.
- [11] Hary D, Oshio K, Flanagan SD. The ASYST software for scientific computing. *Science* 1987;236:1128–32.
- [12] Hogan D, Garraghty PE, Williams RW. Lamination and visual topography in the lateral geniculate nucleus of normal and achiasmatic dogs. *Eur J Anat* 1996;1:3–11.
- [13] Hogan D, Garraghty PE, Williams RW. Abnormal retinofugal projections and visual cortical maps in a mutant with unilateral misrouting at the optic chiasm. *Soc Neurosci Abstr* 1996;22:1611.
- [14] Hogan D, Garraghty PE, Williams RW. Unilateral misrouting at the chiasm associated with disrupted lamination in the geniculate and a vertical inversion of the visual map in area 17. *Soc Neurosci Abstr* 1995;21:394.
- [15] Hogan D, Williams RW. Analysis of the retinas and optic nerves of achiasmatic Belgian sheepdogs. *J Comp Neurol* 1995;352:367–80.
- [16] Hoyt CS, Gelbart SS. Vertical nystagmus in infants with congenital ocular abnormalities. *Ophthalmic Pediatr Genet* 1984;4:155–62.
- [17] Kurzan R, Büttner U. Smooth pursuit mechanisms in congenital nystagmus. *Neuro-ophthalmology* 1989;9:313–25.
- [18] Schmidt D, Kommerell G. Congenitaler Schaukelnystagmus (see-saw nystagmus). *Albrecht von Graefe's Archiv Klin Exp Ophthalmol* 1974;191:265–72.
- [19] Shallo-Hoffmann J, Watermeier D, Petersen J, Mühlendyck H. Fast-phase instabilities in normally sighted relatives of congenital nystagmus patients—autosomal dominant and x-chromosome recessive modes of inheritance. *Neurosurg Rev* 1988;11:151–8.
- [20] Sheth NV, Dell'Osso LF, Leigh RJ, Van Doren CL, Peckam HP. The effects of afferent stimulation on congenital nystagmus foveation periods. *Vis Res* 1995;35:2371–82.
- [21] Williams RW, Dell'Osso LF. Ocular motor abnormalities in achiasmatic mutant Belgian sheepdogs. *Invest Ophthalmol Visual Sci* 1993;34:1125.
- [22] Williams RW, Hogan D, Garraghty PE. Target recognition and visual maps in the thalamus of achiasmatic mutant dogs. *Nature* 1994;367:637–9.
- [23] Zauberman H, Magora A. Congenital 'see-saw' movement. *Br J Ophthalmol* 1969;53:418–21.