



Testicular Sperm Sampling by Subcapsular Orchiectomy in Klinefelter Patients: A New Simplified Treatment Approach

Jens Fedder, Claus H. Gravholt, Stine Gry Kristensen, Niels Marcussen, Birte Engvad, Ann Mains Milton, and Claus Yding Andersen

OBJECTIVE	To evaluate subcapsular orchiectomy as a method to retrieve spermatozoa from minute testicular foci in men with Klinefelter syndrome (KS).
METHODS	Fourteen men with KS were consecutively recruited to unilateral subcapsular orchiectomy. Testicular tissue was dissected mechanically and enzymatically to identify possible sperm. Previous testosterone replacement therapy was interrupted for 10 months (range: 9-12 months) to minimize a possible effect on the spermatogenesis. Two men with high estrogen/testosterone ratios were treated with aromatase inhibitor (letrozol, 2.5 mg/d for 3 months) before operation.
RESULTS	Testicular sperm were detected in 5 of 14 KS men giving an overall success rate of 36%. The success rate was 50% (5 of 10 men) after exclusion of the 4 men previous treated with androgen substitution. So far, 3 (21%) clinical pregnancies and 2 live births or ongoing pregnancies (14%) have been obtained. Testicular sperm could not be detected in the 2 men treated with aromatase inhibitor before operation. The maximum operative time was 20 minutes, and none had surgical complications such as pain, fever, or hematomas. The mean testosterone level, measured 1-4 months after orchiectomy, decreased to 72% (7.9 ± 2.4 nmol/L) of the preoperative level.
CONCLUSION	Subcapsular orchiectomy appears to be easy and quick compared with conventional microtesticular sperm extraction. However, in this pilot study, it has not been possible to demonstrate pregnancy and live birth rates as high as that reported with microtesticular sperm extraction, and further studies are needed before the procedure should be used routinely for sperm retrieval in patients with KS. UROLOGY 86: 744–750, 2015. © 2015 The Authors. Published by Elsevier Inc. This is an open access article under the CC BY-NC-ND license (http://creativecommons.org/licenses/by-nc-nd/4.0/).

Men with Klinefelter syndrome (KS) usually present with germ cells until puberty but generally show azoospermia in adult life.¹ Thus, onset of puberty in KS is associated with accelerated germ cell depletion.² However, focal spermatogenesis may originate in euploid germ cell lines in such patients, although seminiferous tubules with full spermatogenesis usually appear in only very few foci.^{3,4}

The ability to father children is often an important question to many KS patients. Using new techniques of

microtesticular sperm extraction (micro-TESE), a number of studies have shown the possibility of extracting sperm for assisted reproduction in KS men, and to date, more than 100 healthy children have been born using sperm from KS men.⁵ In a large study including 115 men with nonmosaic KS, it was possible to find sperm in only 12 (10.3%) men by micro-TESE. However, because spermatids were detected in 50 (43.5%) of the men in this study, spermatid injections were performed.⁶ Conversely, 2 recent reviews reported mean TESE rates of 44% in 373

Financial Disclosure: The authors declare that they have no relevant financial interests.
Funding Support: The study was supported by Laboratory of Reproductive Biology, Scientific Unit, Horsens Hospital, Denmark.

Study Approval: The study has been approved by the Danish Scientific Ethics Committee of Middle Jutland (M–20100041) and the Danish Data Protection Agency (2010-41-4539) and registered at ClinicalTrials.gov (NCT 01750632).

Jens Fedder, Claus H. Gravholt, and Claus Yding Andersen designed the study. Jens Fedder performed the infertility treatment including the orchiectomies. Ann Mains Milton handled the testicular biopsies in the IVF laboratory; Stine Gry Kristensen and Claus Yding Andersen cryopreserved the testicular tissue and made the slides for microscopy. Niels Marcussen and Birte Engvad performed the histologic evaluations. All authors contributed to the final article based on a draft written by Jens Fedder.

From the Centre of Andrology, Fertility Clinic, Odense University Hospital, Odense C, Denmark; the Laboratory of Reproductive Biology, Scientific Unit, Horsens Hospital, Horsens, Denmark; the Department of Endocrinology and Internal Medicine, Aarhus University Hospital, Aarhus C, Denmark; the Department of Molecular Medicine, Aarhus University Hospital, Aarhus N, Denmark; the Laboratory of Reproductive Biology, University Hospital of Copenhagen (Rigshospitalet), Copenhagen Ø, Denmark; and the Centre of Andrology, Department of Pathology, Odense University Hospital, Odense C, Denmark

Address correspondence to: Jens Fedder, M.D., Ph.D., M.Sc., Centre of Andrology, Fertility Clinic, Odense University Hospital, Odense C, Denmark. E-mail: fedder@dadlnet.dk or Jens.Fedder@rsyd.dk

Submitted: March 17, 2015, accepted (with revisions): June 22, 2015

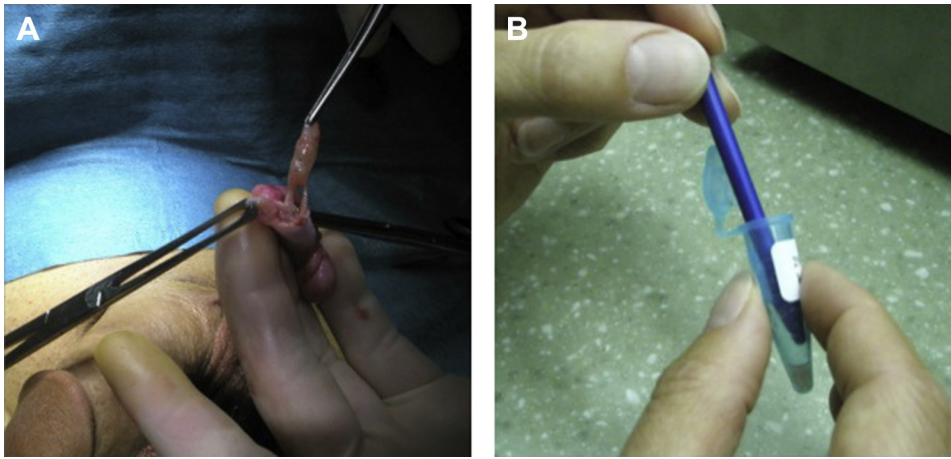


Figure 1. A, B. Testicular sperm extraction by subcapsular orchietomy. **(A)** Macroscopic picture from the operation theater. The testis tissue is blunt released from the inside the *Tunica albuginea* and removed in toto, and **(B)** Sperm extraction kit.

nonmosaic KS men⁵ and 50% in 741 KS men,⁷ respectively, using TESE or micro-TESE.

The collection of seminiferous tubules with active spermatogenesis from KS men is, however, a time-consuming procedure with a duration of up to 7 hours.⁸ TESE is usually performed on the day of, the day before, or some time before oocyte aspiration. In the last case, retrieved sperm are frozen until the ART procedure. Furthermore, if repeated sperm retrievals are required, including restitution intervals in between, the initiation of androgen treatment may be postponed. Therefore, we hypothesized that unilateral orchietomy would match or increase the success of other sperm retrieval procedures by optimizing the chances of finding useful sperm for treatment and cryopreservation in an effective way and allow the KS men to start androgen substitution therapy immediately. The primary outcome of this pilot study, which has run since 2010, is presence of testicular sperm, and a secondary outcome is clinical pregnancy.

METHODS

Patients

The 14 patients included in the project were recruited from the public fertility clinics in Odense, Brædstrup, Skive, and Holbæk. All KS men, aged 15-40 years, who wanted to have their own biological child and participate in the orchietomy project after being informed about its limitations and possible risks could be included. The only exclusion criterion was inability to understand the information given. They were usually referred for infertility treatment due to azoospermia. Determining the karyotype, which is an obligatory part of the examination program, revealed the diagnosis. In addition to karyotype, all non-vasectomized azoospermic men are examined for Y micro-deletions in the azoospermia factor region, cystic fibrosis transmembrane conductance regulator gene (CFTR) mutations, and as minimum levels of the hormones: follicle stimulating hormone (FSH), luteinizing hormone, testosterone fractions, and prolactin are determined.^{9,10}

The study was approved by the Scientific Ethics Committee of Middle Jutland and by the Data Protection Agency and registered

in ClinTrials.gov. All participants provided their written informed consent. Furthermore, inclusion of participants <18 years requires written informed consent from their parents.

Clinical Characterization

Age, height, and weight of each patient were monitored, and a clinical examination performed. Because testicular microlithiasis may reflect defective spermatogenesis,¹¹ testicular microlithiasis and echogenicity were evaluated ultrasonographically, and the testicular volumes calculated.¹²

Hormonal Pretreatment

Men substituted with testosterone undecanoate given as depots (Nebido, Bayer Schering, Berlin, Germany) had their treatment discontinued in average 10 months (range: 9-12 months) before sperm retrieval, and increased FSH and luteinizing hormone values after discontinuation was verified by analyses of blood samples. Two men with abnormally high estrogen/androgen ratio were given a 3-month pretreatment with letrozol, 2.5 mg/d (Femara, Novartis, Basel, Switzerland) to optimize the hormonal conditions before operation.

Unilateral Orchietomy

The operations were performed under general anesthesia. Furthermore, 20 mL of Lidocain (5 mg/mL; Sysgehus Apoteket Danmark, Copenhagen, Denmark) was injected around the spermatic cord (18 mL) and under the scrotal skin (2 mL).

To avoid fragmentation of the testis tissue, a longitudinal cut was performed through the skin and *Tunica albuginea* as described by Desmond et al.¹³ The testis tissue quelling out was removed in toto by blunt dissection (Fig. 1A), put into Sperm Preparation Medium (Product No. 1069; Origio, Måløv, Denmark), and transported to the laboratory. *Tunica albuginea* and the scrotal skin were closed with Vicryl 3-0 rapid continuous and knots, respectively (Ethicon Inc., a Johnson-Johnson company).

Sperm Harvesting From Testicular Tissue

Little pieces of testis tissue (2 × 2 × 2 mm) were prepared in the in vitro fertilization (IVF) laboratory to facilitate sperm identification. Pieces of tissue were shredded with microscope slides in

a culture petri dish (Nunc, Roskilde, Denmark) containing 2-3 mL of culture medium (IVF medium, Origio, Måløv, Denmark). In addition, an RNase, DNase, and pyrogen-free sperm extraction kit was used to pestle small testis biopsies with a gentle manual back-and-forth rotation (Fig. 1B; NordicCell, Copenhagen, Denmark, ref. 43190). After shredding and pestling, aliquots of 20 µl of testicular cell suspension was examined using an inverted microscope for localization of sperm (Nikon with Eppendorf micromanipulator equipment and Nomalski optics). If spermatozoa could not be identified by careful examination, centrifugation was performed, and the supernatant examined for presence of sperm. Furthermore, examination of migration from the pellet was done 1 hour after centrifugation. In addition, small, compact pieces of testis tissue were digested using collagenase, 1000 collagenase digestive units/mL according to the manufacturers recommendations (Gynemed Medizinprodukte GmbH & Co. KG, Switzerland).

Vitrification of Oocytes

Vitrification of oocytes allowing freshly retrieved testicular sperm to be used for fertilization of thawed oocytes was applied to the last 5 couples. Thus, the orchiectomies can be scheduled independent of oocyte aspiration. We used the minimum volume vitrification approach described in Kuwayama et al¹⁴ and Cobo et al¹⁵ using a commercially available Cryotop Safety Kit (Kitazato Co., Fujinomiya, Japan). Morphologically acceptable sperm identified were used for intracytoplasmic sperm injection (ICSI) immediately, with preference for motile sperm. Excess sperm were cryopreserved in straws using SpermFreeze Medium (FertiPro N.V., Beernem, Belgium).

Cryopreservation of Testis Tissue

Because cryopreservation of testicular tissue as tubular fragments rather than as testicular cell suspensions may reduce damages due to toxicity of cryoprotectants,¹⁶ a representative piece of the testis tissue was incubated in Sperm Preparation Medium (Product No. 1069; Origio, Måløv, Denmark) and sent (2 hour by car) on ice to the Laboratory of Reproductive Biology, University Hospital of Copenhagen, transported as previously described for ovarian tissue.¹⁷ On arrival, the tissue was cut into pieces of 2 × 2 × 2 mm in size and frozen using a cryoprotectant solution consisting of 1.5 mol/L ethyleneglycol, 0.1 mol/L sucrose, and 10 mg/mL human serum albumin as previously described.¹⁸

Histologic Examination

Testicular biopsies were fixed in Bouin fixative for 18-20 hours, dehydrated in ethanol, and embedded in paraffin. A few, small representative biopsies were cut into serial sections (5 µm thick), mounted on glass slides, and stained with Mayer's hematoxylin and periodic acid-Schiff reagent.

The numbers of hyalinized seminiferous tubules were counted. The proportion of tubules with Sertoli cell only and spermatogenesis, respectively, were registered. Leydig cell hypo- or hyperplasia and Leydig cell pleomorphism were noted. Finally, possible presence of fibrosis was scored from 0 to 3,¹⁵ where 0: <5%, 1: 6%-25%, 2: 26%-50%, and 3: >50% of the biopsy contained fibrotic tissue.¹⁹

Follow-up

After operation, the men were observed in the department for at least 4 hours and controlled for scrotal swelling before leaving

the hospital. The men were requested to call the hospital/J.F. in case of pain, fever, or scrotal swelling during the first 2 weeks after the operation. All KS men were requested to have measured s-testosterone about 3 months after orchiectomy.

Thirteen to 26 months after orchiectomy, a nonvalidated questionnaire (Appendix) was sent to the first 10 KS men who participated in this study. They were asked about any possible inconvenience during the first 2 weeks after the operation and about their health status 1-2 years later. The last 4 men have still not received a questionnaire because of shortage in observation interval. In addition, the participants were asked whether they would be willing to have the remaining testicle removed for fertility treatment.

Statistics

All variables were normally distributed, and *t* test was used. *P* values <.05 were considered as significant.

RESULTS

Fourteen men with a mean age (±standard deviation) of 31.8 ± 4.7 years were included. Twelve men had a 47,XXY karyotype and 2 mosaicism with 47,XXY[97]/46,XX[14]/46,XY[1] and 47,XXY[107]/46,XY[6] karyotypes. No adolescent was included. Testicular sperm could be identified and isolated in 5 men (36%) by the new treatment approach with subcapsular orchiectomy (Table 1). The operative time was maximum 20 min, and in no case, bleeding from the inside of *Tunica albuginea* was observed. A few microlithiasis elements (~5) were detected ultrasonographically in 6 of the 14 KS patients (bilaterally in 5) and did not predict the chance of detecting sperm (Table 1). After orchiectomy, nobody chose to have a testis prosthesis from cosmetic or other reasons.

The mean age, height, and weight did not differ between the men with and without sperm, although the mean weight tended to be lower for the 4 KS men in whom testicular sperm were found (*P* = .06; Table 2). As shown in Table 2, FSH was unable to predict identification of testicular sperm in this cohort of KS men. In fact, 2 of the sperm-positive men had FSH levels of 74 and 77 IU/L. When only including the 10 men not previously treated with androgens, the success rate in finding testicular sperm was 50% (5 of 10 KS men). Histologically, the testicular tissue was dominated by Sertoli cell only pattern and to a variable extent fibrosis and Leydig cell hyperplasia (Fig. 2).

In 3 of the 5 men in whom sperm were detected, a few tubules with active spermatogenesis were found, and in these 3 cases, clinical pregnancies were obtained. One pregnancy was obtained in a 25-year-old woman using cryopreserved sperm. Of 6 aspirated oocytes, 4 were fertilized by ICSI; 2 of these cleaved, and one 4-cell embryo was transferred 2 days after aspiration. Pregnancy was obtained, and a healthy girl was born. Another pregnancy was obtained in a 35-year-old woman. Of 6 vitrified oocytes, 2 survived warming and were fertilized with fresh sperm, and two 4-cells were transferred 2 days after oocyte

Table 1. Karyotypes, testicular microlithiasis, and hormone pretreatment of the 14 men with Klinefelter syndrome undergoing subcapsular orchiectomy

Patient Number	Karyotype	Testicular Microlithiasis	Cryptorchidism	Previous Androgen Treatment	Aromatase Inhibitor Pretreatment
1	47,XXY	None	+ (hormone treatment)	—	—
2	47,XXY	None	—	—	—
3	47,XXY	None	+ (late spontaneous descent)	—	—
4	47,XXY	None	—	—	—
5	47,XXY	Bilaterally	—	—	—
6	47,XXY	Unilaterally	+ (orchiopexia bilateral, aged 10 and 13 years)	+ (Nebido)	—
7	47,XXY	Bilaterally	+ (unilateral spontaneous descent, aged 7-8 years)	—	—
8	47,XXY	Bilaterally	—	—	+ (Letrozol)
9	47,XXY	None	—	+ (Nebido)	+ (Letrozol)
10	47,XXY/46,XX/46,XY	Bilaterally	—	—	—
11	47,XXY	None	—	+ (Nebido)	—
12	47,XXY	None	—	+ (Nebido)	—
13	47,XXY	None	—	—	—
14	47,XXY/46XX	Bilaterally	—	—	—

The 5 men for whom testicular sperm were detected in the IVF laboratory are given in bold.

Table 2. Demographic data, testicular volumes, and pre-operative FSH and testosterone levels (means \pm standard deviations) for men with Klinefelter syndrome according to whether testicular sperm were detected or not

	Testicular Sperm Detected (n = 5)	No Testicular Sperm (n = 9)	P Value*
Age (y)	29.8 \pm 5.7	32.9 \pm 4.0	.32
Height (m)	1.85 \pm 0.08	1.88 \pm 0.06	.47
Weight (kg)	80.2 \pm 9.3	94.2 \pm 15.5	.06
Body mass index (kg/m ²)	23.8 \pm 4.2	26.7 \pm 3.7	.23
Testis volume (mL)	3.4 \pm 1.4	2.8 \pm 1.8	.45
FSH (U/L)	46.3 \pm 27.4	25.7 \pm 15.4	.18
Testosterone (nmol/L)	12.8 \pm 4.5	9.9 \pm 2.0	.23

* Two-tailed t test.

aspiration, and the pregnancy is now ongoing with an ultrasonographically healthy boy. The third pregnancy was obtained with fresh sperm in a 31-year-old woman with an 8-cm transmurally located nonreducible fibroma. ICSI was performed on 2 vitrified-warmed oocytes, and 2 days later, one 4-cell embryo was transferred. At gestational week 7 + 4, a live embryo was identified in the uterus by ultrasonography, but unfortunately the patient had a miscarriage at gestational week 9. At the orchiectomy, excess testicular sperm were cryopreserved in 4 straws using glycerol as cryoprotectant. In a second ICSI attempt, 2 embryos were transferred 2 days after oocyte aspiration, but unfortunately pregnancy was not obtained. The man still has 3 straw with sperm cryopreserved. So far, 3 (21%) of the included couples have obtained pregnancy, and 2 (14%) have obtained live birth/ongoing pregnancy.

In 2 other men, a few sperm were detected; however, the sperm were morphologically abnormal and not

suitable for ICSI. In the testicles of these 2 men, it was not possible to find tubules with spermatogenesis by histologic examination. In 1 of these 2 men, conventional micro-TESE was performed on the other testis (5 months later) but without a positive result. Y microdeletions were in no case detected.

Nobody reported excessive pain, fever, or scrotal swelling during the first 2 weeks after orchiectomy. In only 5 cases, J.F. had the possibility to perform a clinical examination 6-24 months postoperatively because these KS men visited the fertility clinic anyway. In these 5 cases, the "pseudotesticle" consisting of *Tunica albuginea* and flanked by the epididymis was still present in the scrotum at examination. Testosterone measured 1-4 months after orchiectomy showed a 28% decrease to (7.9 \pm 2.4) nmol/L (lower normal limit, 8.4 nmol/L).

Questionnaires sent to the first 10 KS patients 1-2 years after orchiectomy were returned by 7. Of these, 4 reported mild pain and swelling of the scrotum during the first 1-2 weeks after operation, but fever was not reported. Two men were still tired and did not experience any improvement in their well-being 1-2 years after orchiectomy although they were treated with androgen substitution. Five of the 7 questionnaire responders were substituted with androgens since the operation. One man noted an improved sexual life with better erections, whereas 6 reported this to be unchanged. Two were willing to have an orchiectomy also on the other side if there was a chance of finding sperm for fertility treatment.

COMMENT

The success rates of finding testicular sperm in 5 (36%) of 14 men with KS searching fertility treatment and particularly 50% (5 of 10) men not formerly treated with androgen substitution were lower than an overall testicular sperm recovery rates of 44% and 50%

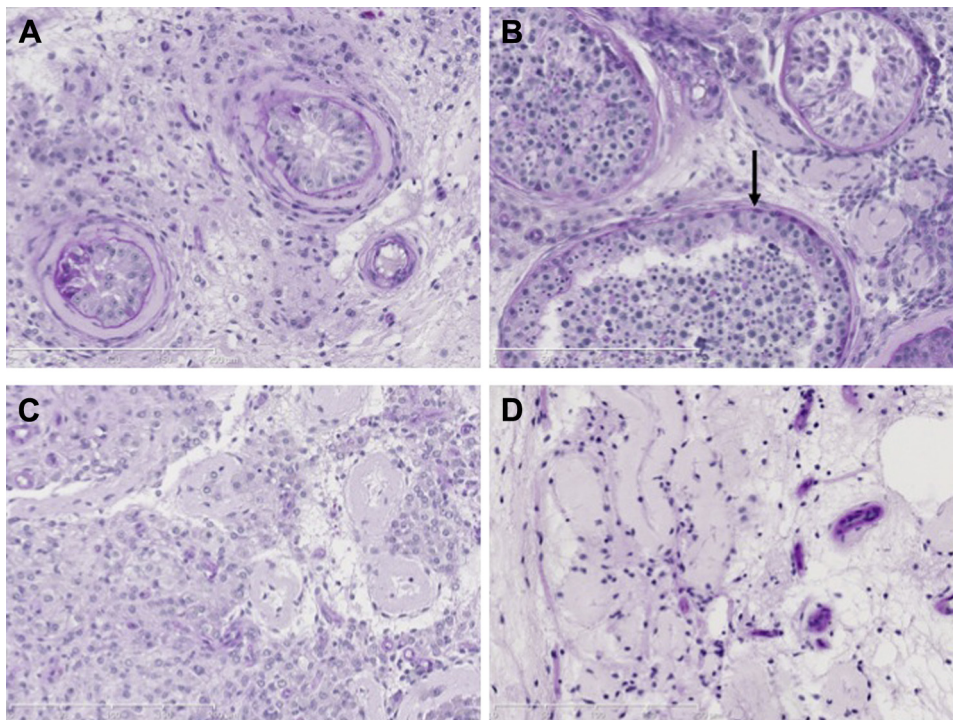


Figure 2. A-D. Histologic pictures of testis biopsies from the men with Klinefelter's syndrome. **(A)** scattered tubules with Sertoli cell only, **(B)** few tubules with spermiogenesis (arrow), **(C)** Leydig cell hyperplasia, and **(D)** hyalinized seminiferous tubules. Periodic acid- Schiff reagent staining $\times 200$.

(micro-TESE, 55% and 57%) found for adult KS patients in recent reviews.^{5,7} In a unique study including 45 KS men, testicular spermatozoa were reported to be successfully retrieved in up to 66% after micro-TESE.²⁰

The most critical point in this study may be removal of half the Leydig cells by removal of an entire testis may increase the need of androgen substitution therapy post-operatively. For comparison, 2 studies focusing on serum testosterone levels after TESE and micro-TESE in KS patients showed that testosterone levels decreased after surgery by either technique and never recovered to baseline levels.^{21,22} Takada et al²¹ found that the testosterone level in KS patients recovered to only 50% of the baseline value 12 months after micro-TESE, indicating that testosterone levels may be reduced after any sperm retrieval procedure.

Years of Age

The mean age of 29.8 years for the 5 men in whom testicular sperm were detected compared with 32.9 years for the 9 men without testicular sperm detected was in accordance to Vernaeve et al,²³ who examined 50 KS men and observed a mean age of 29.5 years for KS with detectable testicular sperm vs 32.8 years for KS without detectable sperm. The power was not strong enough in this study to show a significant difference.

Because spermatogenesis may decrease with increasing age, the optimal time for testicular sperm retrieval might be soon after puberty. Wikström et al²⁴ found

spermatogonia in 7 of 14 boys aged 10-14 years. At present, it is unclear where the lower age limit for retrieval of testis tissue or sperm for cryopreservation should be. In 2 recent studies, it was only possible to find sperm in 1 of 5²⁵ and 0 of 7 of these adolescents aged 10-16 years.²⁶ However, surprisingly, Mehta et al²⁷ were able to detect and cryopreserve testicular sperm from 7 of 10 adolescents, aged 14-22 years, who were treated with topical testosterone supplementation and aromatase inhibitor for 1-5 years before micro-TESE. More data are needed before it can be concluded whether cryopreservation of testicular tissue or sperm obtained by subcapsular orchiectomy or micro-TESE in the teenage years is preferable compared with sperm retrieval performed in a coincident cycle of ICSI in later life.

Hormone Predictors

In agreement with other studies, the concentration of hormones, and particularly FSH, did not predict the chance to identify sperm in the testis.²³ Neither inhibin B or anti-Müllerian hormone did predict the chance of finding testicular sperm, because they, after puberty, are found in very low levels.^{28,29} Interestingly, a recent study described that the intratesticular testosterone level is increased in KS patients compared with controls and suggested that the reason for the low systemic testosterone levels is an altered testicular vascularisation.³⁰ The high level of intratesticular testosterone may explain the scattered foci of spermiogenesis.

Hormonal pretreatment

In recent studies, a higher sperm retrieval rate was obtained after treatment with aromatase inhibitors, human chorionic gonadotrophine (hCG), or clomiphene in KS men with low pretreatment testosterone levels before micro-TESE.¹⁸ Because only 2 of the men included in this study were treated with an aromatase inhibitor, which is not allowed as routine treatment of KS patients in Denmark, no conclusions can be drawn. The aromatase inhibitors may decrease a high estradiol/testosterone ratio by the inhibition of aromatization of the A ring. A low pretreatment serum testosterone concentration is often found although the hypothalamus-pituitary gland–testis axis is intact,² and it might be because of a compromised Leydig cell function in men with KS or maybe rather to a reduced release into the bloodstream owing to altered testicular vascularization; the last hypothesis is supported by an increased ratio of intratesticular testosterone to serum testosterone in humans with KS.³⁰

Ramasamy et al²⁰ and Mehta et al²⁷ have treated adult KS men and teenage KS boys, respectively with hCG injections to increase s-testosterone, and presumably particularly intratesticular testosterone, with the purpose of improving the testicular sperm retrieval rate. In this study, the 1 man, who was very tired after discontinuation of testosterone treatment, benefitted from the hCG treatment. Unfortunately, it was not possible to detect testicular sperm in this man.

CONCLUSION

The technique of unilateral subcapsular orchiectomy appears to be a quick and safe procedure, and excess sperm and testicular tissue can be cryopreserved. However, at the present stage, pregnancy and live birth rates were lower than are reported with micro-TESE, and particularly in the 4 men previously given testosterone replacement therapy, no sperm could be found. The additional tissue extracted could in theory provide a greater chance for sperm identification, but this could not be demonstrated in this pilot study. Because testosterone levels decrease after all testicular retrieval procedures in men with KS, we find orchiectomy clinically and ethically acceptable. Therefore, under special circumstances subcapsular orchiectomy may be considered as a method of sperm extraction for a patient with KS. However, although subcapsular orchiectomy may represent an advancement in time, further studies are urgently needed before the procedure should be used routinely.

Acknowledgments. The authors thank technician Jan Pedersen for vitrification of oocytes of the female partners.

References

1. Lanfranco F, Kamischke A, Zitzmann M, et al. Klinefelter's syndrome. *Lancet*. 2004;364:272-283.
2. Wikström AM, Dunkel L. Testicular function in Klinefelter syndrome. *Horm Res*. 2008;69:317-326.

3. Aksglæde L, Wikström AM, Rajpert-De Meyts E, et al. Natural history of seminiferous tubule degeneration in Klinefelter syndrome. *Hum Reprod Update*. 2006;12:39-48.
4. Sciarano RB, Luna Hisano CV, Rahn MI, et al. Focal spermatogenesis originates in euploid germ cells in classical Klinefelter patients. *Hum Reprod*. 2009;24:2353-2360.
5. Fullerton G, Hamilton M, Maheshwari A. Should non-mosaic Klinefelter syndrome men be labelled as infertile in 2009? *Hum Reprod*. 2010;25:588-597.
6. Tanaka A, Tanaka I, Nagayoshi M, et al.: Risk level of intracytoplasmic sperm/spermatid injection for 115 non-mosaic Klinefelter syndrome patients. Abstract O-232, IFFS/ASRM Conjoint Meeting, Boston, Massachusetts, USA, October 12.-17., 2013.
7. Aksglæde L, Juul A. Testicular function and fertility in men with Klinefelter syndrome: a review. *Eur J Endocrinol*. 2013;168:R67-R76.
8. Ramasamy R, Fisher ES, Ricci JA, et al. Duration of microdissection testicular sperm extraction procedures: relationship to sperm retrieval success. *J Urol*. 2011;185:1394-1397.
9. Fedder J. History of cryptorchidism and ejaculate volume as simple predictors for the presence of testicular sperm. *Syst Biol Reprod Med*. 2011;57:154-161.
10. Fedder J, Crüger D, Østergaard B, et al. Etiology of azoospermia in 100 consecutive, non-vasectomized men. *Fertil Steril*. 2004;82:1463-1465.
11. Vegni-Talluri M, Bigliardi E, Vanni MG, et al. Testicular micro-liths: their origin and structure. *J Urol*. 1980;124:105-107.
12. Honig SC. New diagnostic techniques in the evaluation of anatomic abnormalities of the infertile male. *Urol Clin North Am*. 1994;21:417-432.
13. Desmond AD, Arnold AJ, Hastie KJ. Subcapsular orchiectomy under local anaesthesia. Technique, results and implications. *Br J Urol*. 1987;61:143-145.
14. Kuwayama M, Vajta G, Kato O, et al. Highly efficient vitrification method for cryopreservation of human oocytes. *Reprod Biomed Online*. 2005;11:300-308.
15. Cobo A, Kuwayama M, Pérez S, et al. Comparison of concomitant outcome achieved with fresh and cryopreserved donor oocytes vitrified by the Cryotop method. *Fertil Steril*. 2008;89:1657-1664.
16. Unni S, Kasiviswanathan S, D'Souza S, et al. Efficient cryopreservation of testicular tissue: effect of age, sample state, and concentration of cryoprotectant. *Fertil Steril*. 2012;97:200-208.
17. Rosendahl M, Schmidt KT, Ernst E, et al. Cryopreservation of ovarian tissue for a decade in Denmark: a view of the technique. *Reprod Biomed Online*. 2011;22:162-171.
18. Kvist K, Thorup J, Byskov AG, et al. Cryopreservation of intact testicular tissue from boys with cryptorchidism. *Hum Reprod*. 2006;21:484-491.
19. Mechlin CA, Levesque J, Feustel P, et al. Mast cell numbers negatively correlate with fibrosis in cryptorchid testes. *J Pediatr Urol*. 2013;11:1-5.
20. Ramasamy R, Ricci JA, Palermo GD, et al. Successful fertility treatment for Klinefelter's syndrome. *J Urol*. 2009;182:1108-1113.
21. Takada S, Tsujimura A, Ueda T, et al. Androgen decline in patients with nonobstructive azoospermia after microdissection testicular sperm extraction. *Urology*. 2008;72:114-118.
22. Okada H, Shirakawa T, Ishikawa T, et al. Serum testosterone levels in patients with nonmosaic Klinefelter syndrome after testicular sperm extraction for intracytoplasmic sperm injection. *Fertil Steril*. 2004;82:237-238.
23. Vernaev V, Staessen C, Verheyen G, et al. Can biological or clinical parameters predict testicular sperm recovery in 47,XXY Klinefelter's syndrome patients? *Hum Reprod*. 2004;19:1135-1139.
24. Wikström AM, Raivio T, Hadziselimovic F, et al. Klinefelter syndrome in adolescence: onset of puberty is associated with accelerated germ cell depletion. *J Clin Endocrinol Metab*. 2004;89:2263-2270.

25. Rives N, Milazzo JP, Perdrix A, et al. The feasibility of fertility preservation in adolescents with Klinefelter syndrome. *Hum Reprod.* 2013;28:1468-1479.
26. Gies I, De Schepper J, Van Saen D, et al. Failure of a combined clinical- and hormonal-based strategy to detect early spermatogenesis and retrieve spermatogonial stem cells in 47,XXY boys by single testicular biopsy. *Hum Reprod.* 2012;27:998-1004.
27. Mehta A, Bolyakov A, Roosma J, et al. Successful testicular sperm retrieval in adolescents with Klinefelter syndrome treated with at least one year of topical testosterone and aromatase inhibitor. *Fertil Steril.* 2013;100:970-974.
28. Pacenza N, Pasqualini T, Gottlieb S, et al. Clinical presentation of Klinefelter's syndrome: differences according to age. *Int J Endocrinol.* 2012; 324835, 6 pages.
29. Westlander G, Ekerhovd E, Bergh C. Low levels of serum inhibin B do not exclude successful sperm recovery in men with nonmosaic Klinefelter syndrome. *Fertil Steril.* 2003;79:1680-1682.
30. Tüttelmann F, Damm OS, Luetjens CM, et al. Intratesticular testosterone is increased in men with Klinefelter syndrome and may not be released into the bloodstream owing to altered testicular vascularization—a preliminary report. *Andrology.* 2004;2:275-281.

APPENDIX

SUPPLEMENTARY DATA

Supplementary data associated with this article can be found, in the online version, at <http://dx.doi.org/10.1016/j.urology.2015.06.044>