

Non-Traumatic Fracture of an Osteochondroma Mimicking Malignant Degeneration in an Adult with Hereditary Multiple Exostoses

Matthew M. Robbins, M.D., Scott Kuo, M.D., and Robert Epstein, M.D.

A 38-year-old man with a known history of hereditary multiple exostoses and no history of trauma presented with a painful right femur mass. While the clinical presentation was concerning for malignant degeneration or a large overlying bursitis, the radiologic evaluation demonstrated a large fractured pedunculated osteochondroma with a thick cartilage cap and underlying bone marrow edema. Traumatic fracture of an osteochondroma is an uncommon complication in patients with hereditary multiple exostoses. This case highlights an unusual presentation in which a patient with hereditary multiple exostoses and no history of trauma presented with a large fractured osteochondroma.

Introduction

Traumatic fracture of an osteochondroma is an uncommon complication in patients with hereditary multiple exostoses. This case highlights an unusual presentation in which a patient with hereditary multiple exostoses and no history of trauma presented with a

large fractured osteochondroma that mimicked malignant degeneration.

Case Report

A 38-year-old man with a past medical history of multiple hereditary exostoses presented to the emergency room with a two month history of an enlarging hip mass. The patient noted increasing hip pain and denied recent trauma. The patient reported a 15 lb weight loss over a two month period with decreased appetite. Physical examination revealed a palpable, firm, nontender 6 cm mass along the right hip. Additionally, there was a second firm, tender lesion within the right buttock that was approximately 10 x 7 cm in size. The limb was neurovascularly intact. The patient had limited range of motion in this right leg secondary to pain.

Radiographs of the femur and CT of the abdomen

Citation: Robbins MM, Kuo S, Epstein R. Non-traumatic fracture of an osteochondroma mimicking malignant degeneration in an adult with hereditary multiple exostoses. *Radiology Case Reports*. [Online] 2008;3:99.

Copyright: © 2008 The Authors. This is an open-access article distributed under the terms of the Creative Commons Attribution-NonCommercial-NoDerivs 2.5 License, which permits reproduction and distribution, provided the original work is properly cited. Commercial use and derivative works are not permitted.

Abbreviations: CT, computed tomography; MRI, magnetic resonance imaging

Matthew M. Robbins, M.D. (Email: m2rnjr@gmail.com), and Robert Epstein, M.D., are in the Department of Radiology, University of Medicine and Dentistry of New Jersey-Robert Wood Johnson Medical School, Piscataway, NJ, USA.

Scott Kuo, M.D., is at the University of Medicine and Dentistry of New Jersey-Robert Wood Johnson Medical School, Piscataway, NJ, USA..

Published: August 22, 2008

DOI: 10.2484/rcr.v3i3.99

Non-Traumatic Fracture of an Osteochondroma Mimicking Malignant Degeneration

and pelvis were obtained as part of the initial workup. The radiographs (Fig. 1) demonstrated soft tissue calcification adjacent to the greater trochanter of the right femur extending superiorly into the right gluteal region. The CT (Fig. 2) verified a large pedunculated osteochondroma arising from the anterior aspect of the right femoral neck with a thick cartilaginous cap and surrounding fluid. It also demonstrated a second region of calcification which was separate from the calcified osteochondroma that was contiguous with the femur. Given the sudden growth of a previously existing osteochondroma and the subsequent CT findings, an MRI was performed to better evaluate the cartilage cap and the surrounding soft tissue process.

MRI (Fig. 3) demonstrated multiple osteochondromas consistent with the patient's history of hereditary multiple exostoses. The large pedunculated osteochondroma arising from the anterior aspect of the right femoral neck had fractured with a displaced superior fragment. Additionally, the fragment had a somewhat uniform, but thickened cartilaginous cap measuring up to 20 mm at its thickest point. A large bursal fluid collection surrounded the osteochondroma. There was also marrow edema at the base of the osteochondroma stalk.

Bone scintigraphy was performed to assess for distant regions of abnormalities. The radionuclide bone scan with ^{99m}Tc (Fig. 4) showed increased uptake in the previously existing osteochondromas. There was increased activity noted in the right greater trochanteric region consistent with a fracture.

Due to the fracture and thickened cartilaginous cap, the patient underwent an open surgical biopsy. Only the

fractured portion of the pedunculated osteochondroma was resected and sent to pathology. The pathological specimen revealed the cartilaginous cap was up to 3.0 cm in thickness in multiple samples. However, no other features of a secondary chondrosarcoma were present,

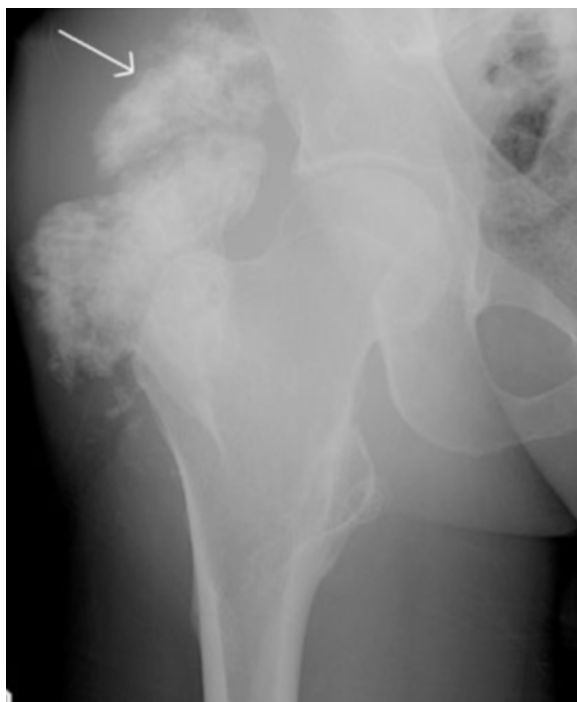

Figure 1. 39-year-old man with multiple hereditary exostoses and enlarging right hip mass. Radiograph shows soft tissue calcification adjacent to an exostosis arising from the greater trochanter, extending superiorly into the right gluteal region (arrow).

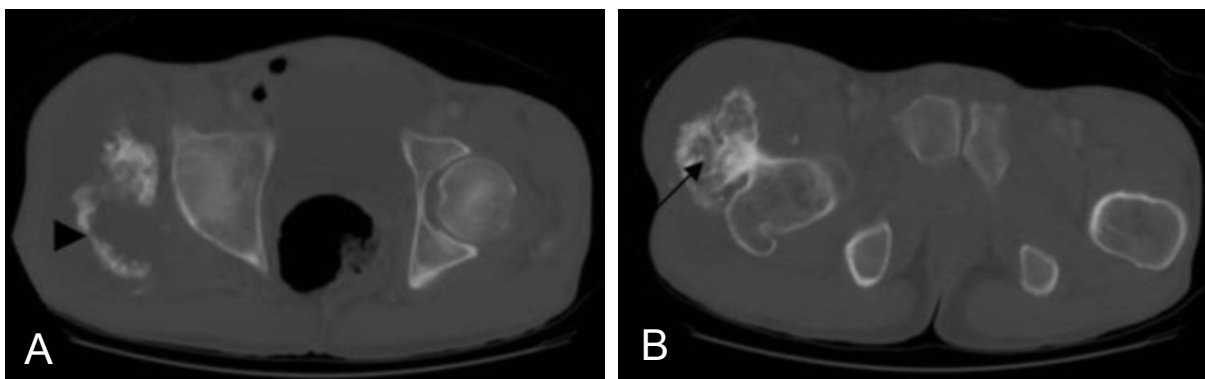


Figure 2A-B. Transverse CT slices through the pelvis show (A) calcified fragment (arrowhead) and (B) osteochondroma (arrow).

Non-Traumatic Fracture of an Osteochondroma Mimicking Malignant Degeneration

and a definitive diagnosis of malignant degeneration could not be made.

During follow up, the patient had decreased hip pain. Since the osteochondroma and cartilage cap size were so large, the patient continues to be closely monitored for any recurring symptoms or growth abnormalities.

Discussion

Hereditary multiple exostoses is an autosomal dominant disorder that presents in the first two decades of life with multiple osteochondromas [1, 2]. Complications of hereditary multiple exostoses include malignant

degeneration, bursitis, fractures, physical deformities, and vascular and neurologic compromise caused by the osteochondromas [3, 4, 5]. The most serious sequela, malignant degeneration, occurs in up to 3-5% of the patients with hereditary multiple exostoses in comparison to 1% of the patients with only a solitary osteochondroma [3, 6, 7, 8]. The risk of malignant degeneration in hereditary multiple exostoses has been reported to be as high as 25%, but this is controversial and may be due to sampling bias [6]. In our case, the presentation mimicked a possible malignant degeneration of an osteochondroma; however, a non traumatic fractured osteochondroma of the femoral neck was consequently found.

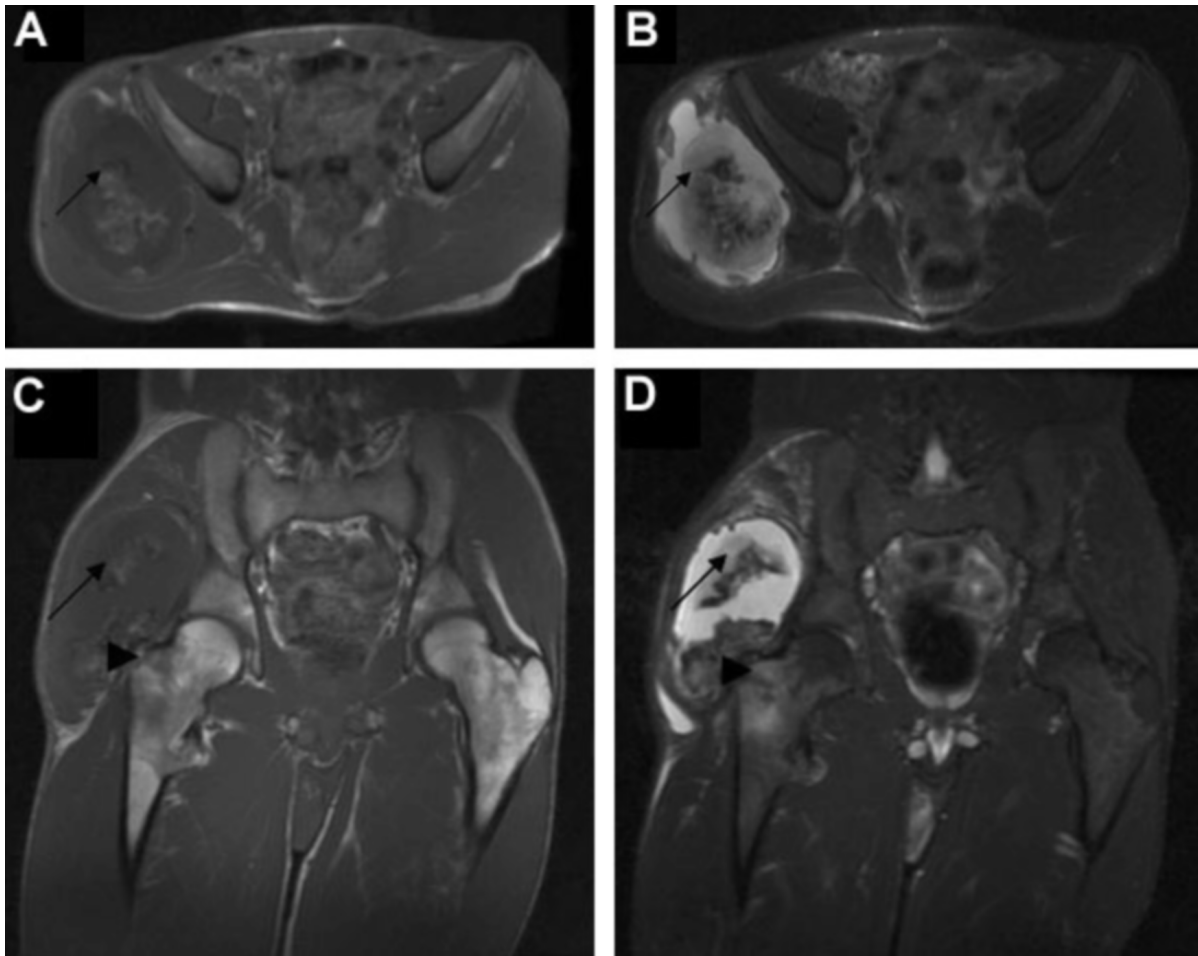


Figure 3.A-D (A-B) Transverse T1-weighted and T2-weighted and (C-D) coronal T1-weighted and T2-weighted MRI shows cartilage cap of osteochondroma (arrow) and fracture plane (arrowhead).

Non-Traumatic Fracture of an Osteochondroma Mimicking Malignant Degeneration

A fracture through the stalk of an osteochondroma is a well established, yet uncommon, cause of pain from an osteochondroma, with most published accounts associated with trauma [3, 9, 10]. Fractures through an osteochondroma have been reported to be as few as 4 fractures in 727 patients in a study by Dahlin et al or as many as 5 fractures in 70 patients in a study by Theodorou [11, 12]. Osteochondromas most at risk for fracture are located around the knees usually in the proximal tibia, distal femur and knee [2, 3, 11, 12]. A fracture of an osteochondroma off the proximal femur is rare [10].

In most cases, fractures occur because of direct injury [3]. Carpintero et al. studied 7 fractured osteochondromas over a 17 year period and found that 2 were caused by direct blows to the osteochondromas while the other 5 were fractured indirectly during physical activity [12]. In all 5 indirect cases, the patients described violent muscle contractions during activity, which possibly could have caused the fracture [12]. Even though our patient described no trauma, a benign growth of a pedunculated osteochondroma could lead

to a relative weakening of its stalk and the mechanics of the surrounding muscles creating friction along the osteochondroma could result in a pathologic fracture and pain [1, 4, 10].

In addition to a fracture occurring in the absence of trauma, this patient demonstrated other findings concerning for malignant degeneration such as new onset pain, growth of an osteochondroma in an already mature skeleton, a thick cartilaginous cap and marrow edema [1, 2, 4, 8]. Radiologically, suspicion should be raised with a cartilaginous cap greater than at least 1.5 cm, increasing irregularity of the cartilage surface, or development of a soft tissue calcification outside the expected boundary of the tumor [1, 2, 3, 5].

The index of suspicion for malignant degeneration led to further evaluation with nuclear scintigraphy. Though both benign and malignant osteochondromas can have increased uptake, previous studies have shown that a known mass with no uptake is indicative of a benign lesion [3, 6, 7, 13]. Our patient had markedly increased activity within the hip osteochondroma that could not definitively specify if a malignancy was pres-

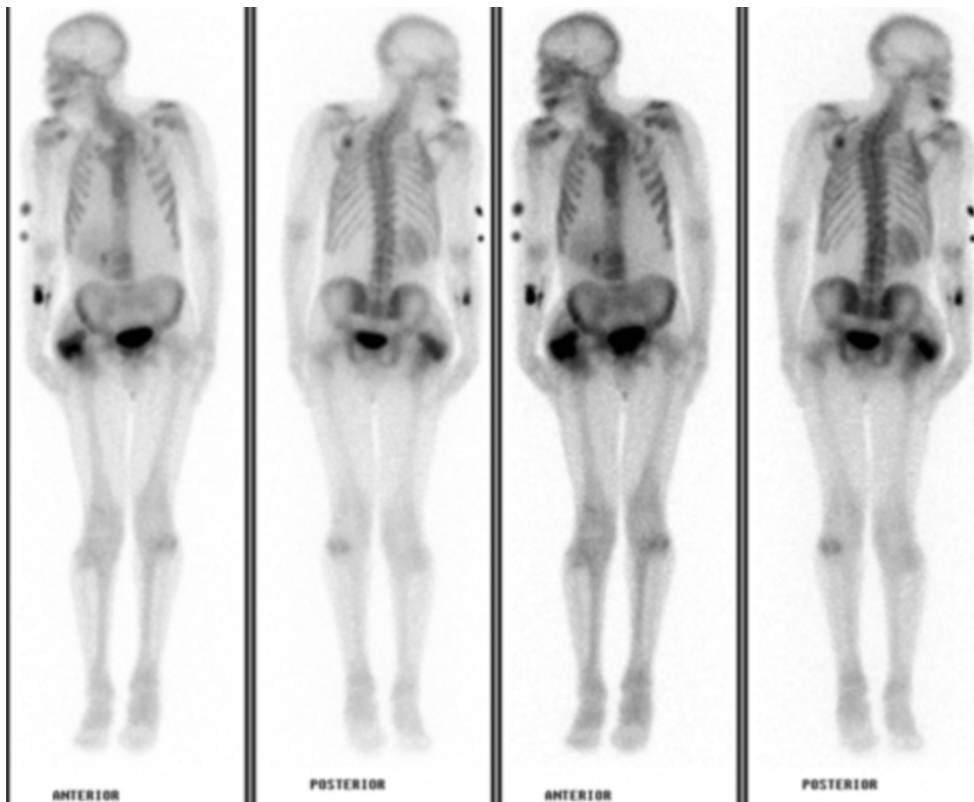


Figure 4. Radio-nuclide bone scan shows increased activity at the right hip.

Non-Traumatic Fracture of an Osteochondroma Mimicking Malignant Degeneration

ent; however, the increased activity could be explained by the recent fracture rather than a malignant process.

In summary, this case was atypical in that the patient presented with a non traumatic fracture of a large pedunculated osteochondroma. While the clinical presentation was concerning for malignant degeneration, the imaging and subsequent pathology confirmed the benign diagnosis.

References

1. Woertler K, Lindner N, Gosheger G. Osteochondroma: MR imaging of tumor-related complications. *European Radiology*. 2000; 10(5):832-40. [PubMed]
2. Lee K, Davies A, Cassar-Pullicino V. Imaging the Complications of Osteochondroma. *Clinical Radiology*. 2002 Jan; 57(1):18-28. [PubMed]
3. Murphey M, Choi J, Kransdorf M. Imaging of Osteochondroma: Variants and Complications with Radiologic-Pathologic Correlation. *Radiographics*. 2000 Sep-Oct; 20(5):1407-34. [PubMed]
4. Krieg JC, Buckwalter JA, Peterson KK, el Khoury GY, Robinson RA. Extensive growth of an osteochondroma in a skeletally mature patient. A case report. *Journal of Bone & Joint Surgery (Am)*. 1995 Feb; 77(2):269-73. [PubMed]
5. Nogier A, Pinieux G, Hottya G. Enlargement of a Calcaneal Osteochondroma after Skeletal Maturity. *Clinical Orthopaedics and Related Research*. 2006 Jun; 447:260-6. [PubMed]
6. Kivioja A, Ervasti H, Kinnunen J. Chondrosarcoma in a family with multiple hereditary exostoses. *Journal of Bone & Joint Surgery (Br)*. 2000 Mar; 82(2):261-6. [PubMed]
7. Hendel HW, Daugaard S, Kjaer A. Utility of planar bone scintigraphy to distinguish benign osteochondromas from malignant chondrosarcomas. *Clinical Nuclear Medicine*. 2002 Sep; 27(9):622-4. [PubMed]
8. Willms R, Hartwig C, Bohm P. Malignant transformation of a multiple cartilaginous exostosis a case report. *International Orthopaedics*. 1997; 21(2):133-6. [PubMed]
9. Davids JR, Glancy GL, Eilert RE. Fracture through the stalk of pedunculated osteochondromas. A report of three cases. *Clinical Orthopaedics*. 1991 Oct; (271):258-64. [PubMed]
10. Alonso-Torres A, Bernabeu D, Lopez-Barea F. Growth and fracture of an osteochondroma in an adult patient. *European Radiology*. 2004 Dec; 14(12):2366-7. [PubMed]
11. Prakash U, Court-Brown C.M. Fracture through an osteochondroma. *Injury*. 1996 Jun; 27(5):357-8. [PubMed]
12. Carpintero P, Leon F, et al. Fracture of Osteochondroma during Physical Exercise. *The American Journal of Sport Medicine*. 2003 Nov-Dec; 31(6):1003-6. [PubMed]
13. Restrepo J, Caride V. Tc-99m MDP Imaging in Hereditary Multiple Exostoses. *Clinical Nuclear Medicine*. 2003 Jul; 28(7):589-90. [PubMed]