



Case report

Fungal spondylodiscitis due to *Candida albicans*: an atypical case and review of the literature[☆]



Álynon Larocca Kulcheski^{a,b,*}, Xavier Soler Graells^{a,b}, Marcel Luiz Benato^{a,b}, Pedro Grein Del Santoro^{a,b}, André Luis Sebben^{a,b}

^a Orthopedics and Traumatology Service, Hospital de Clínicas, Universidade Federal do Paraná (UFPR), Curitiba, PR, Brazil

^b Hospital do Trabalhador, Universidade Federal do Paraná (UFPR), Curitiba, PR, Brazil

ARTICLE INFO

Article history:

Received 18 August 2014

Accepted 14 November 2014

Available online 18 October 2015

Keywords:

Candida albicans

Discitis

Spinal diseases

ABSTRACT

Spondylodiscitis due to *Candida* is a rare complication from hematogenic dissemination of infection caused by this fungus. We present an atypical case of spondylodiscitis caused by this germ that occurred after chest contusion and progressed with necrotizing fasciitis of the anterior region of the chest and osteomyelitis of the sternum. Through contiguity, it also affected the upper thoracic spine. The patient evolved with neurological alterations and recovered satisfactorily after appropriate treatment with surgical decompression of the spinal cord and specific antibiotic therapy.

© 2015 Sociedade Brasileira de Ortopedia e Traumatologia. Published by Elsevier Editora Ltda. All rights reserved.

Espondilodiscite fúngica por *Candida albicans*: um caso atípico e revisão da literatura

RESUMO

A espondilodiscite por *Candida albicans* é uma rara complicação da disseminação hematogênica da infecção por esse fungo. Apresentamos um caso atípico de espondilodiscite por esse germe ocorrido após trauma contuso torácico que cursou com fascite necrotizante da região anterior do tórax, osteomielite de esterno e, por contiguidade, afetou a coluna vertebral torácica alta. O paciente evoluiu com alteração neurológica e recuperou-se satisfatoriamente após tratamento adequado com descompressão medular cirúrgica e antibioticoterapia específica.

© 2015 Sociedade Brasileira de Ortopedia e Traumatologia. Publicado por Elsevier Editora Ltda. Todos os direitos reservados.

Palavras-chave:

Candida albicans

Discite

Doenças da coluna vertebral

[☆] Study carried out at the Orthopedics and Traumatology Service, Hospital de Clínicas, Universidade Federal do Paraná (UFPR) and Hospital do Trabalhador, Universidade Federal do Paraná (UFPR), Curitiba, PR, Brazil.

* Corresponding author.

E-mails: alylarocca@gmail.com, alynon.larocca@hotmail.com (Á.L. Kulcheski).

<http://dx.doi.org/10.1016/j.rboe.2015.10.005>

2255-4971/© 2015 Sociedade Brasileira de Ortopedia e Traumatologia. Published by Elsevier Editora Ltda. All rights reserved.

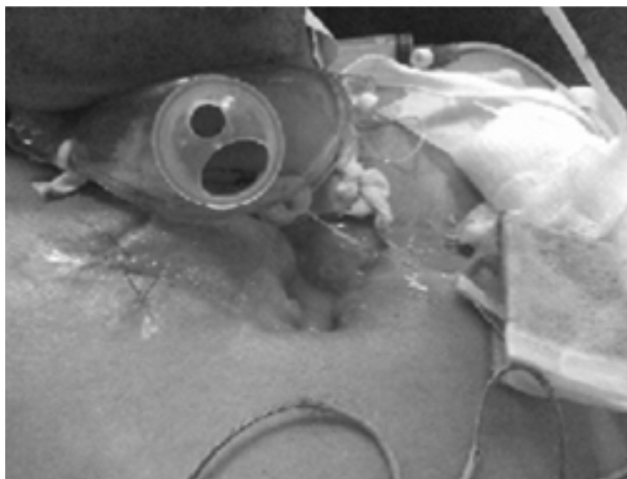

Fig. 1 – Initial aspect of the sternum lesion.

Introduction

Spinal cord infections are rare and comprise approximately 1% of bone infectious involvement.¹ Most of these infections are of pyogenic or tuberculous origin. Fungal infections are increasing, but are still extremely rare and occur more as opportunistic infections in immunocompromised individuals.² Despite the increased frequency, infection by *Candida albicans* is not common.³ We report an unusual case of thoracic spondylodiscitis caused by *C. albicans*. The literature was reviewed, aiming to better understanding the subject.

Case report

The patient was a 39-year-old homeless, chronic alcoholic male individual. He fell two meters to the ground in October 2012. He was treated in a trauma hospital, where he showed signs of septic shock, hyperemia and crackles in the sternal region, with 10 cm in diameter. Chest radiography and computed tomography (CT) showed pre-sternal subcutaneous emphysema and signs of sternum fracture, and culminated with a diagnosis of anterior chest wall necrotizing fasciitis (Fig. 1). Surgical debridement was performed in this region. The result of the of sternum soft tissue culture was positive for

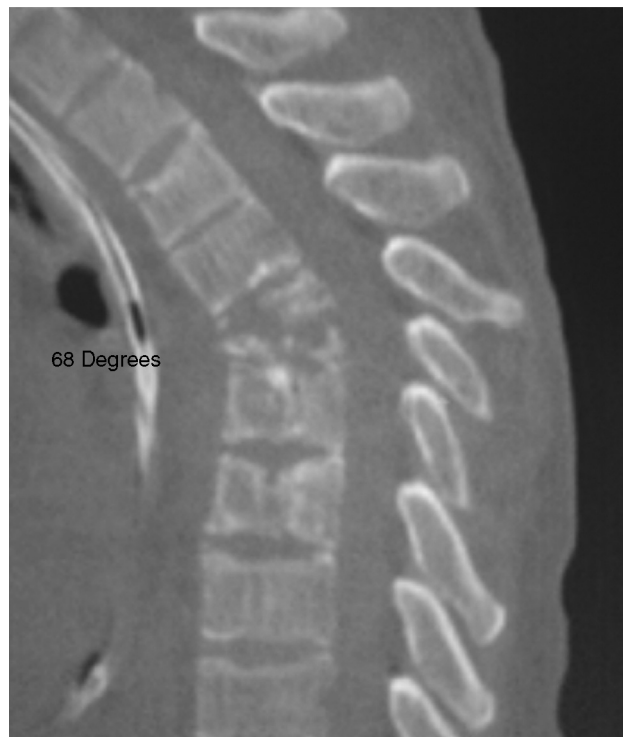

Fig. 3 – Cobb angle in the preoperative period between T2 and T7.

multisensitive *Escherichia coli* and the result of the sternal bone fragment culture for *C. albicans* was positive. Treatment with fluconazole (6 mg/kg/day) and Ciprofloxacin (400 mg 12/12 h) was started and drug use was scheduled for six months, initially intravenously and, after clinical improvement, by oral route. The patient developed vertebral osteomyelitis signs, with decreased height of the vertebral bodies and discs at the thoracic spine levels of T4–T5–T6 (Fig. 2). The patient was paralyzed, with altered sensitivity at the T4 level, compatible with Frankel B. Initial Cobb angle of 68° (Fig. 3) was observed. The patient underwent thoracotomy, which disclosed a spinal abscess and a large amount of purulent secretion. A corpectomy was performed from T4 to T6 with autologous iliac graft replacement and comprehensive spinal decompression in T4. There was improvement of pain complaints in the thoracic spine, with fever disappearance and improvement to Frankel

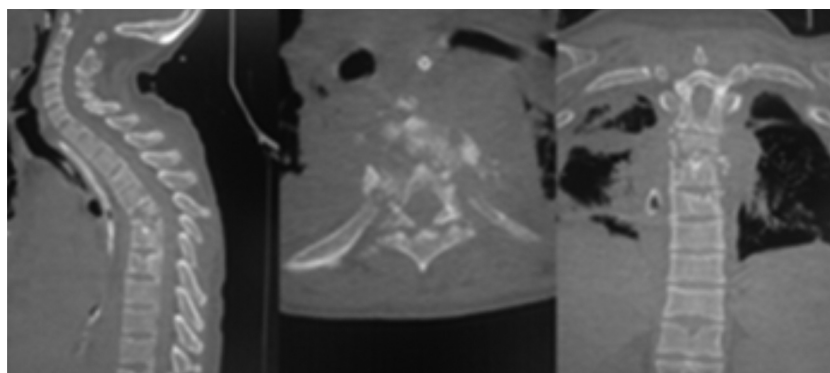


Fig. 2 – CT scans in the sagittal, axial and coronal sections.

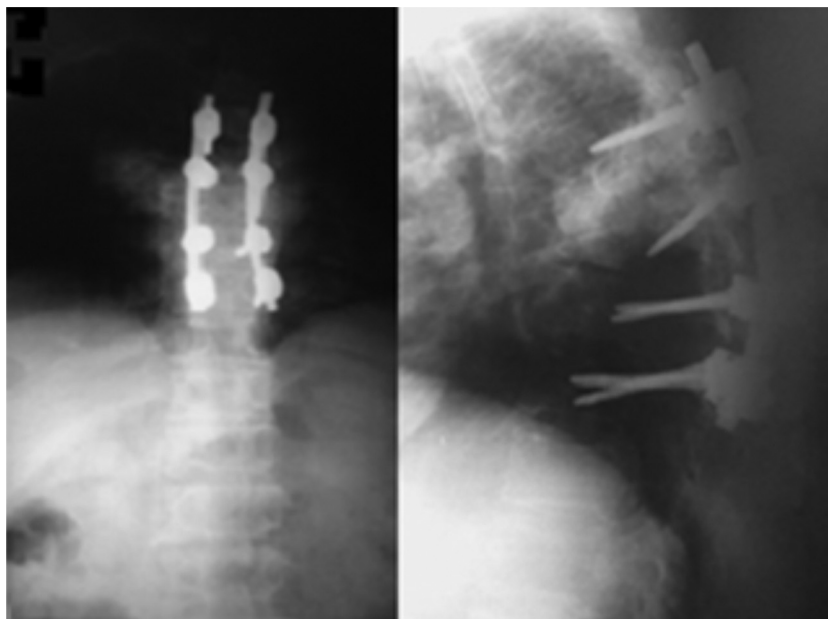


Fig. 4 – postoperative AP and profile radiographies.

C. At a second procedure, he was submitted to posterior fixation and arthrodesis with pedicle screws at the level of the thoracic spine from T3 to T7 (Fig. 4).

Postoperatively, he showed improvement of 13° of kyphosis in the Cobb angle and remained at 55° (Figs. 4 and 5). After eight months of the diagnosis, the patient showed improvement of the neurological level to Frankel D at the T4 level. Upon assessment at 12 months after the first diagnosis, the wounds were healed and he showed significant improvement in the thoracic kyphosis (Fig. 5). The patient was well, communicative, independent in relation to self-care, and managed to perform his activities without assistance or difficulty. During hospitalization the Oswestry Disability Index 2.0 was applied preoperatively and after the definitive surgical procedure. Preoperatively, he scored 70% and was classified as disabled. Postoperatively, the index was 25%, which showed good results in the pain/disability item.

Discussion

Despite the increase in the frequency of fungemia, infection by *C. albicans* is also a rare cause of spinal infection.³ The main risk factors are: prior antibiotic therapy, ICU stay, long-term catheter use, corticosteroids, intravenous drugs, transplants and chemotherapy.^{1,2,4,5} In our case, the patient was alcoholic, homeless and immunocompromised.

The most common location of spondylodiscitis by *Candida* is in the lumbar spine, and the presence of neurological deficit is infrequent.²

In 2001, Miller⁶ described 59 cases of spinal infection by *Candida*, 33 affecting the lumbar spine, 17 the chest, three the cervical and six both the thoracic and lumbar spine.

In our case, the upper thoracic region was affected and there was neurological deficit, in contrast to the literature. This

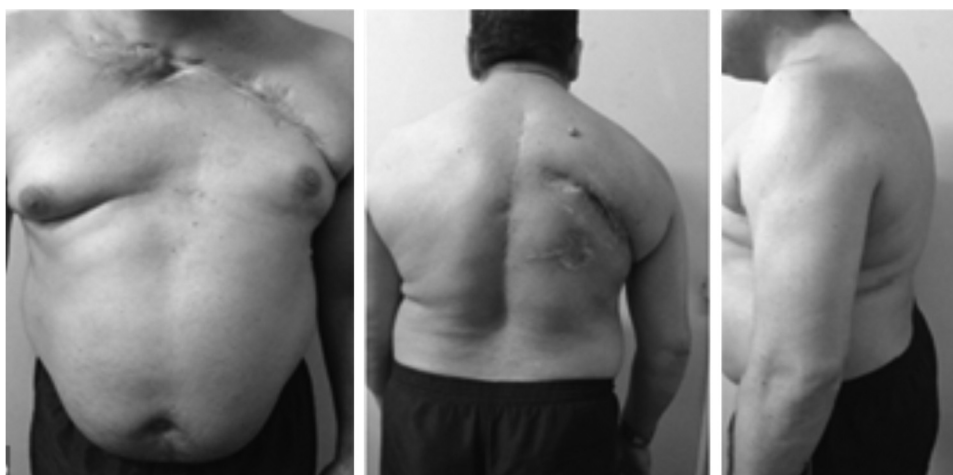

Fig. 5 – Clinical evolution 12 months after the initial diagnosis.

condition is usually insidious. The most useful clinical finding is pain in the affected area, both bone and paravertebral types.⁷ The paraplegia was noteworthy in our case. An association was observed between chest trauma and the spinal injury, a fact validated by literature.⁸

When *C. albicans* affects the spine, it usually causes disk narrowing, destruction of the endplates and the subjacent vertebral bone.⁴ These imaging findings are consistent with what we found in our case.

The optimized management of spinal infections by *Candida* remains unclear. Case reports such as this one help to increase the experience in the management and treatment of this disease.

Surgical treatment is not required in spondylodiscitis by *Candida*. However, it should be performed in cases where there is neurological deficit and vertebral instability.^{4,5} In the present report, the patient had neurological deficit (Frankel B) and vertebral instability, characterized by kyphosing of the thoracic spine.

Clinical treatment is carried out with antifungal drugs, using amphotericin B or fluconazole. One proposed treatment consists of 6–10 weeks of Amphotericin B IV at a dose of 0.5–0.6 mg/kg/day.⁹ Studies have shown that Fluconazole is as effective as amphotericin, showing higher safety and tolerability. In our institution, we chose to carry out the treatment with fluconazole.

Studies have documented that diagnostic delay is common.¹⁰ That is attributed to the rare occurrence and difficulty in cultivating the microorganisms. It has been suggested that a delay in the start of antifungal therapy is associated with a worse outcome, particularly the neurological one.¹⁰ We believe that our success was due to the early diagnosis and confirmation by biopsy and the sternum bone culture, as well as the identification of spinal cord compression. The treatment was promptly carried out with spinal decompression, rapid microbiological results and start of specific antifungal treatment.

Spondylodiscitis by *Candida* should be considered in immunocompromised patients. The definitive diagnosis is

achieved through isolation of *C. albicans* in blood or cultures. The antifungal treatment often results in the cure, even in cases of delayed diagnosis. When there is neurological instability or deficit, surgical treatment should be considered.

Conflicts of interest

The authors declare no conflicts of interest.

REFERENCES

1. Ghanayem AJ, Zdeblick TA. Cervical spine infections. *Orthop Clin North Am.* 1996;27(1):53–67.
2. Broner FA, Garland DE, Zigler JE. Spinal infections in the immunocompromised host. *Orthop Clin North Am.* 1996;27(1):37–46.
3. Johnson MD, Perfect JR. Fungal infections of the bones and joints. *Curr Infect Dis Rep.* 2001;3(5):450–60.
4. Gathe JC Jr, Harris RL, Garland B, Bradshaw MW, Williams TW Jr. *Candida* osteomyelitis. Report of five cases and review of the literature. *Am J Med.* 1987;82(5):927–37.
5. Almekinders LC, Greene WB. Vertebral *Candida* infections. A case report and review of the literature. *Clin Orthop Relat Res.* 1991;267:174–8.
6. Miller DJ, Mejicano GC. Vertebral osteomyelitis due to *Candida* species: case report and literature review. *Clin Infect Dis.* 2001;33(4):523–30.
7. Smith AS, Blaser SI. Infectious and inflammatory processes of the spine. *Radiol Clin North Am.* 1991;29(4):809–27.
8. Graells XS, Zaninelli EM, Collaço IA, Nasr A, Cecilio WAC, Borges GA. Thoracic injuries and spinal trauma: a complex association. *Coluna/Columna.* 2008;7(1):8–13.
9. Rex JH, Walsh TJ, Sobel JD, Filler SG, Pappas PG, Dismukes WE, et al. Practice guidelines for the treatment of candidiasis. *Infectious Diseases Society of America. Clin Infect Dis.* 2000;30(4):662–78.
10. Frazier DD, Campbell DR, Garvey TA, Wiesel S, Bohlman HH, Eismont FJ. Fungal infections of the spine. Report of eleven patients with long-term follow-up. *J Bone Joint Surg Am.* 2001;83(4):560–5.