

CME

iREVIEWS  
STATE-OF-THE-ART PAPER

# Cardiac Imaging and Stress Testing Asymptomatic Athletes to Identify Those at Risk of Sudden Cardiac Death

Andre La Gerche, MD, PhD,\*† Aaron L. Baggish, MD,‡ Juhani Knuuti, MD, PhD,§  
David L. Prior, MD, PhD,\* Sanjay Sharma, MD,|| Hein Heidbuchel, MD, PhD,†  
Paul D. Thompson, MD¶

Melbourne, Australia; Leuven, Belgium; Boston, Massachusetts; Turku, Finland;  
London, United Kingdom; and Hartford, Connecticut

## JACC: CARDIOVASCULAR IMAGING CME

### CME Editor: Ragavendra R. Baliga, MD

This article has been selected as this issue's CME activity, available online at <http://imaging.onlinejacc.org> by selecting the CME tab on the top navigation bar.

### Accreditation and Designation Statement

The American College of Cardiology Foundation (ACCF) is accredited by the Accreditation Council for Continuing Medical Education (ACCME) to provide continuing medical education for physicians.

The ACCF designates this Journal-based CME activity for a maximum of 1 *AMA PRA Category 1 Credit(s)*<sup>™</sup>. Physicians should only claim credit commensurate with the extent of their participation in the activity.

### Method of Participation and Receipt of CME Certificate

To obtain credit for this CME activity, you must:

1. Be an ACC member or *JACC: Cardiovascular Imaging* subscriber.
2. Carefully read the CME-designated article available online and in this issue of the journal.
3. Answer the post-test questions. At least 2 out of the 3 questions provided must be answered correctly to obtain CME credit.
4. Complete a brief evaluation.
5. Claim your CME credit and receive your certificate electronically by following the instructions given at the conclusion of the activity.

**CME Objective for This Article:** At the end of this activity the reader should be able to: 1) recognize some of the factors associated with sudden cardiac death (SCD) and provide some perspective regarding the incidence of SCD; 2) recognize some of the common and less common variants in the assessment of athlete's heart and differentiate these from findings suggestive of cardiac pathology; and 3) apply Bayes' theorem to determine appropriate utilization of diagnostic testing in athletic populations.

**CME Editor Disclosure:** *JACC: Cardiovascular Imaging* CME Editor Ragavendra R. Baliga, MD, has reported that he has no relationships to disclose.

**Author Disclosure:** Dr. Heidbuchel has received speakers' fees from Boehringer-Ingelheim, Daiichi Sankyo, Bayer, Pfizer, Sanofi-Aventis, Medtronic, Biotronik, and Merck; unconditional research grants from Medtronic, Biotronik, Boston Scientific, St. Jude Medical, and AstraZeneca; and collaborative research support from Siemens. Dr. Thompson owns stock in General Electric. All other authors have reported that they have no relationships relevant to the contents of this paper to disclose.

**Medium of Participation:** Print (article only); online (article and quiz).

### CME Term of Approval:

Issue Date: September 2013

Expiration Date: August 31, 2014

## Cardiac Imaging and Stress Testing Asymptomatic Athletes to Identify Those at Risk of Sudden Cardiac Death

---

Sudden cardiac death in young athletes is rare but tragic. The cardiology community is faced with the challenge of providing a sensible strategy for the prevention of SCD while simultaneously reaffirming that the benefits of regular exercise far outweigh potential risks. At present, there is a broad range of screening recommendations dependent upon country, sporting discipline, and competition level. While much recent debate has focused on the efficacy of screening with electrocardiography, a number of sporting bodies also mandate the inclusion of exercise testing and echocardiography in screening protocols. Cardiac magnetic resonance imaging, coronary calcium scoring and computed tomography coronary angiography have also been promoted as potentially valuable screening tools for competitive athletes. This review will examine the controversial topic of utilizing cardiac imaging for athlete pre-participation screening. Specifically, the limitations of screening for relatively rare disorders using imaging tools with uncertain or imperfect accuracy will be addressed. Current evidence suggests that the accuracy of all cardiac imaging modalities is insufficient to justify their use as primary screening modalities in athletes. Atypical findings such as marked cardiac dilation, reduced deformation, or small patches of delayed gadolinium enhancement may be commonly encountered in well-trained athletes, but, at present, the prognostic significance of such findings is unknown. Resulting uncertainty for the clinician and athlete has the potential for psychological stress, further testing, and unnecessary exclusions from competition. However, these concerns must not be confused with the extremely useful applications of cardiac imaging for the assessment of athletes with symptoms, an abnormal electrocardiogram or a positive family history. As modern imaging further enhances our understanding of the spectrum of athlete's heart, its role may expand from the assessment of athletes with suspected disease to being part of comprehensive pre-participation screening in apparently healthy athletes. (J Am Coll Cardiol Img 2013;6:993-1007)

© 2013 by the American College of Cardiology Foundation

The sudden death of a young healthy athlete is a tragedy that leaves unanswered questions that can complicate the family's grief and produce emotive debate in the community. *What was the cause? Could it have been prevented? Could I be at risk?* The public demands a response and, as qualified spokespeople on the issue, medical practitioners have the opportunity to both educate and learn. It is important to provide perspective and reassure the public of the overwhelmingly favorable risk-benefit profile of exercise, but we must also develop better strategies for preventing sudden cardiac death (SCD) in athletes. However, it can be extremely challenging to accurately identify conditions predisposing to SCD, all of which are uncommon, among a cohort that is self-selected for cardiovascular health. This

review focuses on the promise and limitations of multimodality cardiac imaging in identifying at-risk athletes. As an illustrative example, we will use the case of a 36-year-old marathon runner who, as is now mandated at some major city marathons, requires a medical certificate stating that he is medically fit to participate. Thirty-six years represents the approximate median age of participation in marathon events and also represents an age at which both inherited and acquired causes of SCD are prevalent. The issues discussed in relation to this case are relevant to a broader group of athletes, from the recreational enthusiast wishing to join a sporting club to elite professional athletes. However, it is the latter that frequently present the greatest dilemmas due to the diagnostic overlap between

---

From the \*St Vincent's Department of Medicine, University of Melbourne, Melbourne, Australia; †Department of Cardiovascular Medicine, University Hospital Leuven, Leuven, Belgium; ‡Division of Cardiology, Massachusetts General Hospital, Boston, Massachusetts; §Turku PET Centre, University of Turku and Turku University Hospital, Turku, Finland; ||Department of Cardiovascular Sciences, St George's, University of London, London, United Kingdom; and the ¶Division of Cardiology, Hartford Hospital, Hartford, Connecticut. Dr. Heidebuchel has received speakers' fees from Boehringer-Ingelheim, Daiichi Sankyo, Bayer, Pfizer, Sanofi-Aventis, Medtronic, Biotronik, and Merck; unconditional research grants from Medtronic, Biotronik, Boston Scientific, St. Jude Medical, and AstraZeneca; and collaborative research support from Siemens. Dr. Thompson owns stock in General Electric. All other authors have reported that they have no relationships relevant to the contents of this paper to disclose.

Manuscript received March 20, 2013; revised manuscript received May 24, 2013, accepted June 13, 2013.

profound athletic cardiac remodeling and cardiac pathology. Furthermore, the consequences of diagnostic inaccuracy are greater in professional athletes given the potential for lost careers and aspirations if an athlete is inappropriately disqualified or, on the other hand, a potentially greater exposure to exercise triggered SCD if an underlying pathology is missed.

Sport and exercise are an important part of daily life and should be encouraged for a multitude of reasons, including improved health outcomes and reduced SCD risk (1,2). Thus, a paradox exists whereby exercise is associated with substantial health benefits in the vast majority but may serve as a trigger for arrhythmias in a small minority with an underlying pathologic substrate. Therefore, the challenge for broad-based screening programs is to identify those at risk while minimizing harm through unnecessary exclusions from sport. In 1982, with this goal in mind, cardiologists lobbied government policy makers in Italy resulting in a law mandating pre-participation screening for all athletes age 12 years or older. Since this time, all Italian athletes have been required to undergo screening comprising clinical history, physical examination and an electrocardiogram (ECG) prior to acceptance in competitive sport (3). This policy has been both lauded and criticized in equal measure. Proponents cite proof of long-term efficacy among those screened under the Italian system (3,4), while others have argued that the incidence of SCD is extremely low in unscreened athletic populations and the less than perfect specificity of ECG screening has potential for harm through unnecessary investigations, psychological stress, and disqualifications (5-7). As the debate continues to rage, it is becoming increasingly clear that an opportunity has been missed. In 1982, when evidence for ECG screening was scarce, the medical fraternity and legislators could have insisted on a randomized trial (screening with vs. without ECG) in preference to uniform policy. Had this occurred, it might well have provided the definitive experience on which informed policy making could now be based. Similar lessons can be extrapolated to the topic of screening with cardiac imaging. Perhaps the foremost priority should be for evidence to lead the debate rather than opinion.

### Potential Causes of Sudden Cardiac Death in a 36-Year-Old Marathon Runner

The incidence of sudden death in young athletes ( $\leq 35$  years) is 0.6 to 3.6 per 100,000 population

per year and the majority of deaths are due to cardiovascular causes (3,5,8-10). For reasons that remain unexplained, the risk is approximately 10-fold greater among males than females and is higher among competitive athletes when compared with nonathletes (8,9). Although considerable attention has focused on young athletes, the risk of SCD is greater among sports participants older than 35 years and is greatest in the fifth decade (9). Prevention strategies aim to identify cardiac pathologies that may serve as a substrate for arrhythmias triggered by exercise. In general, inherited cardiomyopathies are the most frequent cause of SCD in young athletes while acquired heart disease, principally coronary artery disease, is most frequent in athletes of middle age and older (5,8,9,11-13). However, there is considerable overlap, particularly among 30- to 50-year-old athletes and it may also be that the incidence of inherited cardiomyopathies is underestimated in this group as autopsies are less often performed and coronary disease causation more frequently presumed. It would seem important that each of the conditions predisposing to SCD be considered in potential screening strategies for our 36-year old marathon runner under consideration (Fig. 1).

### Anticipating Screening Efficacy

The predictive value of a screening test may be anticipated according to Bayes' Theorem:

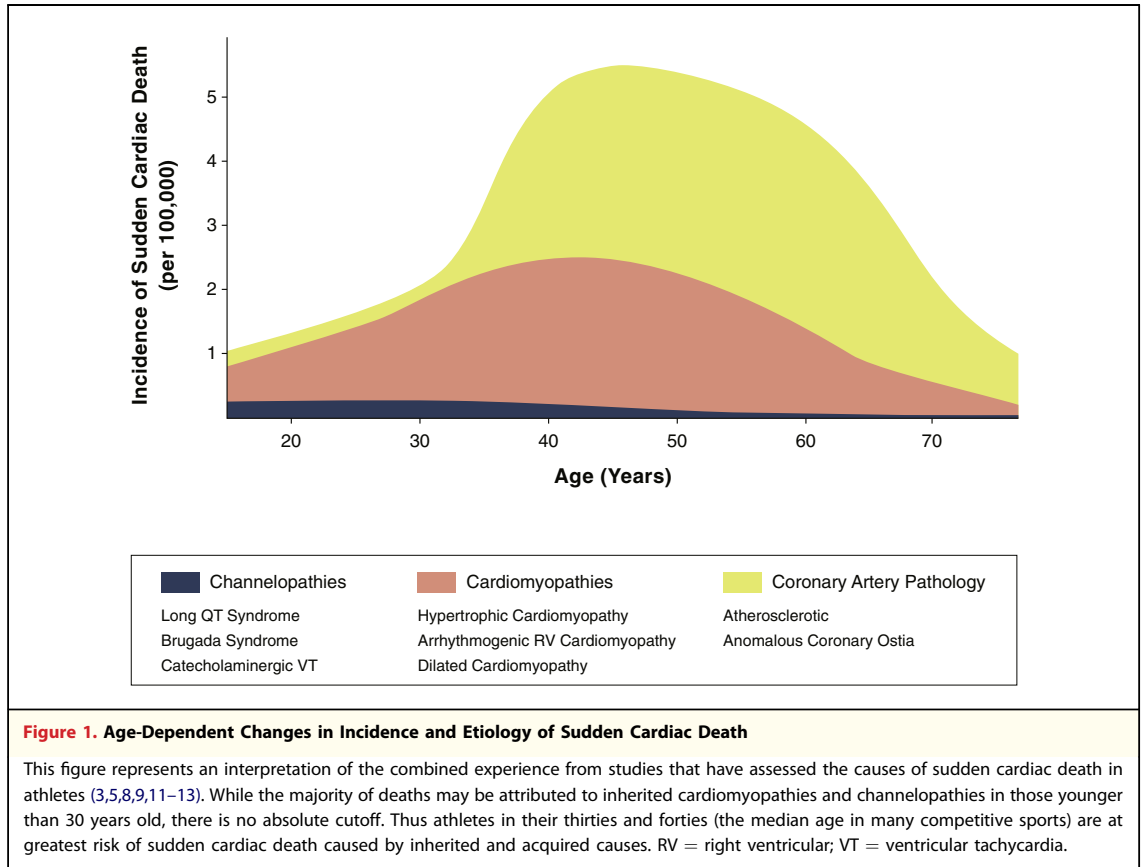
$$PV_{\text{test}} = \frac{P_{\text{pathology}} \times \text{Sensitivity}_{\text{test}}}{(P_{\text{pathology}} \times \text{Sensitivity}_{\text{test}}) + (P_{\text{no pathology}} \times \text{false positive}_{\text{test}})}$$

where  $PV_{\text{test}}$  is predictive value of the screening test,  $P_{\text{pathology}}$  is prevalence of a condition predisposing to sudden cardiac death,  $\text{Sensitivity}_{\text{test}}$  is sensitivity of the screening test, and  $\text{false positive}_{\text{test}}$  is  $100\% - \text{specificity}\%$  of the screening test, respectively.

This equation for calculating probabilities provides an instructive framework for evaluating the accuracy of diagnostic tests for rare conditions. When the disease prevalence is low, the probability of the test accurately identifying that pathology (the predictive value of the screening test) is exquisitely dependent on the test specificity. Unless the test is highly specific then an abnormal result on screening is most

### ABBREVIATIONS AND ACRONYMS

- ARVC** = arrhythmogenic right ventricular cardiomyopathy
- BAV** = bicuspid aortic valve
- CACS** = coronary artery calcium scoring
- CHD** = coronary heart disease
- CTCA** = computed tomography coronary angiography
- CMR** = cardiac magnetic resonance
- DGE** = delayed gadolinium enhancement
- ECG** = electrocardiogram
- HCM** = hypertrophic cardiomyopathy
- LV** = left ventricle
- RV** = right ventricle
- SCD** = sudden cardiac death
- VO<sub>2</sub>max** = maximal oxygen uptake



likely a false positive, prompting further testing with potential for emotional and financial harm.

### Prevalence Estimates

The goal of screening is to identify pathology that may predispose to SCD. Further risk stratification of those with a pathological finding to determine those at greater or lesser risk of SCD is extremely challenging because most of our knowledge of prognosis is derived from symptomatic patients.

Estimates for the community prevalence of conditions predisposing to SCD are provided in Figure 1. The most common inherited or congenital pathologies associated with SCD in athletes are hypertrophic cardiomyopathy (HCM; prevalence ~0.05 to 0.2%) (14-16), anomalous coronary arteries (~0.2%) (17), arrhythmogenic right ventricular cardiomyopathy (ARVC; ~0.1%) (18), and ion-channel disorders (~0.007 to 0.2%) (16,19). It is noteworthy that these prevalence estimates have been derived from unselected populations and may be greater than among athletes in whom a “healthy cohort” effect tends to select out individuals with underlying cardiovascular disease. For acquired

heart disease, approximately 0.5% of an asymptomatic population with a median age of 51 years was identified as having significant coronary artery disease (20) but this may overstate the risk for our 36-year-old marathon runner with well controlled coronary risk factors. Thus, we may conservatively estimate that there is a 1 in 200 (0.5%) risk of any underlying cardiac condition that may represent a substrate for SCD in our marathon runner. The predictive value of any imaging modality is likely to be poor given this very low disease prevalence. For example, if the imaging modality were 95% sensitive and specific, the predictive value of the test would only be 9%. In other words, 91% of “abnormalities” identified on screening could be expected to represent a false positive (i.e., they would *not* represent a risk for SCD).

These calculations are dependent on speculative estimates of the sensitivity and specificity of cardiac imaging tests for the identification of causes of SCD in asymptomatic populations. There are limited studies that have assessed the accuracy of imaging modalities in diagnosing cardiomyopathies and none of these have been performed in cohorts of asymptomatic athletic adults. This largely reflects the fact

that clinical diagnoses are seldom based on imaging alone. ARVC, for example, cannot be diagnosed solely on the basis of imaging yet can be diagnosed despite normal appearance on cardiac imaging (21). The remainder of the review will aim to highlight the promise and limitations of established and novel imaging modalities for this purpose.

Most screening algorithms propose imaging as a “second-line” strategy reserved for those with abnormal ECGs at rest. Indeed, cardiac imaging is invaluable for evaluating any athlete with symptoms, a positive family history, or abnormalities on screening examination or ECG. However, some international sporting bodies, such as the International Federation of Association Football (FIFA), the International Cycling Union (UCI), and the U.S. National Basketball Association (NBA) mandate echocardiography as part of primary screening tests in asymptomatic athletes. The rationale for combining ECG and imaging to screen athletes is that pathologies such as channelopathies and accessory pathways will be identified with ECG while coronary anomalies, aortopathies and some cardiomyopathies may be identified with imaging despite a normal ECG. In addition, it may be argued that in the middle-aged athlete screening should also address the increasingly appreciable risk of coronary heart disease. Thus, in the 36-year-old marathon runner exemplified in this review, comprehensive screening would need to include an ECG, imaging of cardiac structure and function, and some assessment of coronary risk. The following discussions address whether current imaging techniques have the accuracy to effectively predict athletes at greatest risk of SCD while minimizing the psychological, physical, and financial cost associated with false findings.

### Echocardiography

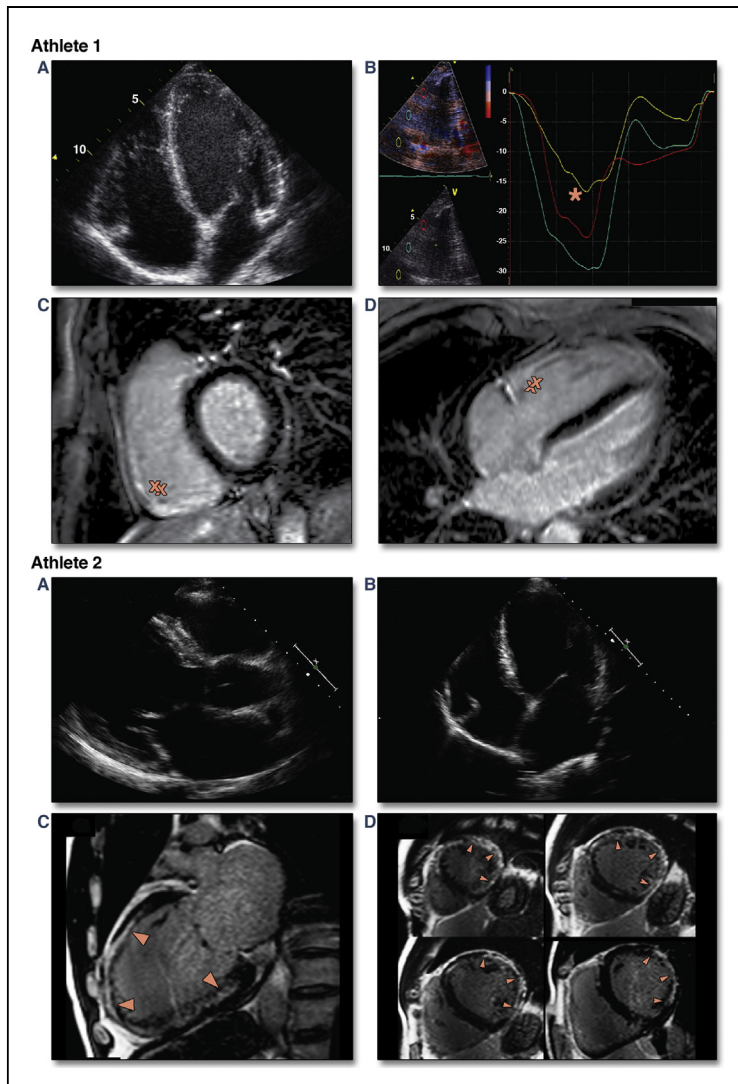
Echocardiography is a logical candidate as a screening modality. It is relatively inexpensive and accessible, and is free of any direct adverse effects. However, adverse financial and psychological side effects caused through misdiagnosis should not be overlooked. Thus, it is important to appraise the accuracy of echocardiography in successfully diagnosing pathology among an athletic cohort in whom profound cardiac remodeling is common.

The greatest body of evidence pertains to the diagnosis of HCM, which, in most series, is the predominant cause of SCD in young athletes. Among others, Maron and Pelliccia (22,23) have provided extensive data to enable better discrimination

between “physiological” and “pathological” hypertrophy, creating an algorithm in which ventricular dilation, a maximal oxygen uptake ( $VO_2\text{max}$ )  $>110\%$  of predicted and a reduction in hypertrophy with detraining all suggest physiological “athlete’s heart” while asymmetry of hypertrophy, left atrial enlargement, and abnormal diastolic function suggest hypertrophic cardiomyopathy. However, most of the experience used to formulate these criteria is derived from comparing athletes and patients with HCM whereas athletes with HCM frequently do not follow the rules, and this is especially true of endurance athletes. Sharma et al. (24) performed 1 of few studies which compared 8 highly trained athletes to 8 athletes with phenotypically mild, genotype positive HCM and found a considerable difference in  $VO_2\text{max}$  (66 vs. 33 ml/min/kg,  $p < 0.001$ ). However, it is difficult to quantify how much of this difference was due to the altered cardiac function and how much was due to differences in athletic conditioning and training volume. Perhaps surprisingly, it seems that some athletes with HCM can achieve high levels of cardiovascular conditioning and can be very competitive in endurance sports (25,26). For example, despite significant pathology, all 3 athletes in Figure 2 competed at an elite or sub-elite level in triathlon and athlete 3 was documented as having a  $VO_2\text{max}$  of nearly twice that predicted for his age.

Of promise is the accumulating evidence base for tissue Doppler and strain measures in the evaluation of athletes in whom HCM may be suspected. D’Andrea et al. (27) have provided a guide for normal ranges in a moderate sized athletic cohort and others have extended this experience by comparing athletes to patients with HCM (28). However, the study cohort of relatively severe HCM phenotypes was easily distinguished using the simplest echocardiographic measures (e.g., septal thickness 23 vs. 11 mm,  $p < 0.0001$ ) such that the incremental value of strain imaging was difficult to assess.

An increasing number of athletes may be diagnosed with HCM as a result of genotyping or with more sensitive diagnostic tools such as delayed gadolinium enhancement (DGE) identified with magnetic resonance imaging. These milder phenotypes may be compatible with high-level exercise performance and seem to be associated with few of the classical diagnostic hallmarks of HCM (25,26). A recent study by Maron et al. (29) reported that 10% of 114 young patients with asymptomatic HCM, largely diagnosed by means of DGE and/or familial studies, had a mild phenotype including a normal ECG. Thus, while we may easily identify



**Figure 2. Increased Sensitivity of Cardiac Magnetic Resonance in Identifying Pathology**

Images from 3 male middle-aged elite triathletes are presented. Athlete 1 presented with sustained ventricular tachycardia. He had changes consistent with athlete's heart on echocardiography (**1A**) including reduced basal right ventricular (RV) strain (indicated by \* in **1B**), which is a common finding in endurance athletes. However, on cardiac magnetic resonance imaging there was akinesis of the basal lateral RV free wall corresponding to areas of delayed enhancement (indicated by ‡ in **1C** and **1D**) consistent with localized scarring suggestive of arrhythmogenic right ventricular cardiomyopathy. Athlete 2 presented with palpitations. He had marked cardiac enlargement on echocardiography (**2A** and **2B**) but normal systolic function on echocardiography at rest and exercise. Cardiac magnetic resonance revealed large areas of delayed enhancement of the subepicardium and mid-myocardium (arrowheads, **2C** and **2D**) suggestive of a dilated cardiomyopathy. Athlete 3 survived a ventricular fibrillation arrest during a triathlon race. His left ventricular wall thickness on echocardiography was at the upper limits of normal (**3A**) and his diastolic myocardial velocities were normal (**3B**). Cardiac magnetic resonance imaging revealed mid-cavity obstruction during systole (**3C**) and apical gadolinium enhancement (‡, **3D**) suggestive of hypertrophic cardiomyopathy.

severe HCM by ECG and echocardiography, these phenotypic extremes are probably very rare among highly trained athletes.

Racial variance in cardiac morphology further complicates echocardiographic assessment. M-mode measures of septal wall thickness are the usual means by which HCM is suspected during an echocardiographic assessment and descriptions of the normal distribution of hypertrophy in male Caucasian athletes suggest that a dimension greater than 12 mm is rare and should be considered abnormal pending further investigations (30). However, 18% of male athletes of African/Afro-Caribbean have been found to have a septal thickness exceeding 12 mm and similar ethnic differences have also been reported for female athletes (31). It is likely that the specificity of echocardiography would be substantially reduced when screening athletic populations of age, gender and ethnic diversity in which our understanding of normal ranges is limited (32). As a result, we can be caught in the difficult situation of excluding athletes on a suspicion that they *may* have a disease that *may* cause SCD. This could be considered prudent by some and unacceptable by others.

The identification of other cardiomyopathies by echocardiography is similarly problematic. There is mounting evidence that intense endurance exercise results in morphological, functional and electrical remodeling of the right ventricle (RV), which may be equivalent, if not greater, than that of the left ventricle (LV) (33–36). Thus, distinguishing ARVC from the dilated athlete's heart can be extremely challenging. Our experience in screening elite endurance athletes is that the wide variance in structure and function of the RV creates significant diagnostic uncertainty. Echocardiograms from 4 professional cyclists from the same team are presented in [Online Video 1](#) illustrating the frequency in which RV assessment provides clinical challenges. Important changes to the Task Force criteria for ARVC diagnosis have qualified RV enlargement such that *regional* abnormalities in structure or function are now required, thereby reducing the overlap with athlete's heart (21). However, identification of regional RV abnormalities is imperfect. Teske *et al.* (37) performed Doppler and 2D deformation analysis (strain and strain rate) on patients with ARVC and found poor agreement between RV wall motion scoring and identification of regional abnormalities by strain. Even in healthy patients, the specificity of regional wall motion analysis of the RV was insufficient to provide diagnostic confidence.

Myocarditis and dilated cardiomyopathy have been implicated in a minority of SCD cases (5,8,12). Once again, in an asymptomatic population with

extremely high levels of fitness, the accurate identification of segmental or global ventricular dilation and hypokinesis is extremely challenging. Abergel et al. (38) performed echocardiographic assessments on 424 cyclists competing in the Tour de France and found that 51.4% exhibited significant LV dilation and 11.6% had a LV ejection fraction <53%, which could be compatible with a diagnosis of dilated cardiomyopathy. Furthermore, Gati et al. (39) recently reported that 8.1% athletes fulfilled conventional criteria for left ventricular noncompaction syndrome and yet only a very small minority of these had any other features suspicious of an underlying cardiomyopathy. Exercise echocardiography may prove a useful discriminator in these settings. Plehn et al. (40) reported that exercise caused a reduction in end-systolic volumes among healthy controls but not in patients with HCM or a dilated cardiomyopathy (40). Exercise echocardiography enables assessment of cardiac structure, function, and contractile reserve, which can be combined with real-time ECG data, thus arguably providing greatest promise as a single test for the exclusion of significant pathology in athletes in whom there is clinical suspicion. However, its predictive value in unselected athletic populations is insufficient to accurately predict the rare athlete at risk of SCD.

Ischemic cardiac disease, either due to anomalous coronaries or acquired atherosclerotic disease should be excluded as a potential cause of SCD. It has been demonstrated that the coronary ostia can be visualized in 90% to 92% of athletes using echocardiography and that the identification of anomalous ostia is highly specific (41,42). However, the sensitivity of echocardiography in detecting congenital coronary anomalies (the ability to identify all cases) has yet to be assessed, and it requires an experienced sonographer and good image quality to confidently identify the ostia and proximal course of the coronary circulation. Outside the realm of screening, in those athletes with exertional symptoms in which coronary anomalies may be suspected, it is advisable to consider computed tomography coronary angiography (CTCA) and/or cardiac magnetic resonance (CMR), which are highly accurate methods for identifying the precise anatomy of coronary anomalies (43).

Echocardiography may accurately identify proximal aortic dilatation and/or bicuspid aortic valve disease that may prevent some cases of SCD due to aortic dissection. Data from large cohorts of athletes have provided a clear definition of expected normal ranges of aortic size (44,45). While aortic dimensions are slightly increased in athletic cohorts

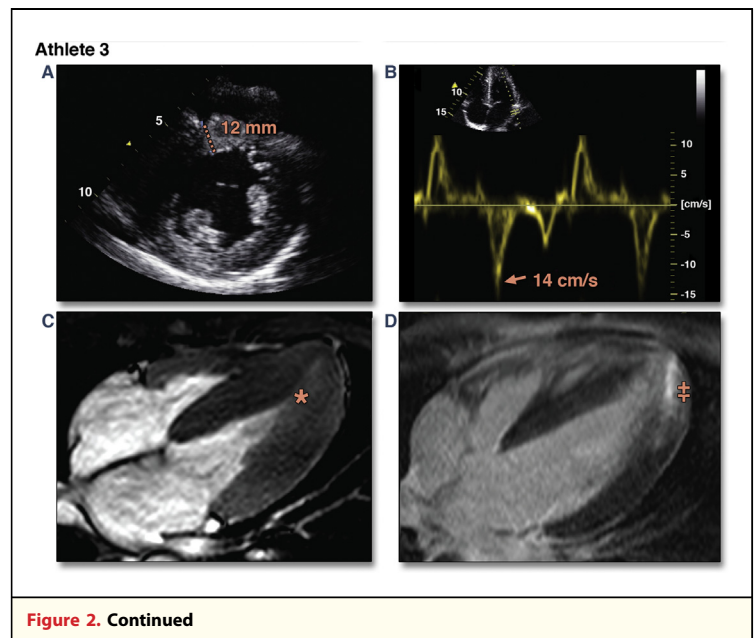


Figure 2. Continued

the difference is of minimal clinical significance and aortic root dimension of >40 mm in males or >34 mm in females should be considered abnormal. These represent useful diagnostic cutoffs for screening and may identify small numbers of athletes with severely dilated aortas at significant risk of dissection. On the other hand, some athletes will be identified with milder dilation in whom there is little evidence to direct advice on sports participation. Posing similar management issues, bicuspid aortic valve (BAV) pathology can be identified in as many as 2.5% of athletes undergoing echocardiographic screening (46). Identification of athletes with BAV may be helpful in identifying athletes in whom regular follow-up may prevent asymptomatic LV deterioration, particularly in the context of severe aortic regurgitation, although there is again limited evidence on the degree to which exercise modifies the natural progression of the disease. One may also argue that the majority of athletes with valvular complications secondary to BAV would be identified on physical examination and that progressive LV remodeling may result in ECG changes. Thus, while echocardiography will reliably identify aortopathies and BAV, the number of lives saved as a result of screening is likely to be very small. Although focused echocardiographic studies using portable or hand-held devices may minimize costs, echocardiography still requires considerable resource infrastructure and operator skill. This is likely to be prohibitive in most settings, with the possible exception of sports such as basketball in which

athletes with Marfan's syndrome may be more common.

Zeltser *et al.* (47) provide some insight into the potential limitations of a pre-participation screening program inclusive of an echocardiographic examination. They screened 2,051 high-school athletes with a "limited" echocardiographic examination comprising 2-dimensional measures of cardiac structure, volumes, and ejection fraction. Fourteen athletes (0.7%) were considered to have changes on echocardiogram suspicious of disease (10 HCM, 2 noncompaction, 1 dilated cardiomyopathy, and 1 subaortic stenosis), all but 3 of which had ECG changes that would have prompted further evaluation in any case. Of the 14 athletes with suspicious changes on screening echocardiography, 6 refused follow-up, 5 were considered normal after a more comprehensive echocardiogram, and 3 athletes were diagnosed with a cardiomyopathy (2 HCM, 1 noncompaction). However, none of these 3 diagnoses were subsequently confirmed by a blinded expert at an independent institution. Thus, this initial real-world experience would suggest that routine echocardiography has the potential to inappropriately exclude athletes while having limited or no efficacy in detecting pathological disease with potential for SCD.

Acquired atherosclerotic coronary disease may be identified using exercise echocardiography with moderate sensitivity and specificity (approximately 76% and 88%, respectively), comparing favorably with other stress-testing methods (48). However, few asymptomatic middle-aged athletes will have risk factors constituting intermediate pre-test likelihood by standardized criteria such as the Diamond-Forrester method or Duke Clinical Score (49,50), and thus exercise testing should not be recommended (51). Furthermore, while a positive stress test may be a good predictor of subsequent angina, it may not be a good predictor of subsequent myocardial infarction or SCD because the former requires an existing significant stenosis whereas the later generally occur in a nonobstructing lesion that experiences plaque disruption.

In the 36-year-old experienced marathon runner seeking medical clearance cited in this review, an echocardiogram was performed. As demonstrated in [Online Video 2](#), there were typical features of athlete's heart with moderate enlargement of all 4 cardiac chambers, particularly of the right atrium and right ventricle ([Fig. 3](#)). There was mild hypertrophy of the septum (11 mm) and of the RV free wall (6 mm). Low normal systolic function was confirmed with 3D echocardiography. Strain and strain rate of the RV

free wall demonstrated considerable heterogeneity with reduced values for the basal and mid segments. While each of these values is within the ranges commonly seen in highly trained athletes, they differ considerably from that which we would consider normal for a nonathlete. The borderline systolic function and low regional deformation make it difficult to conclusively exclude pathology.

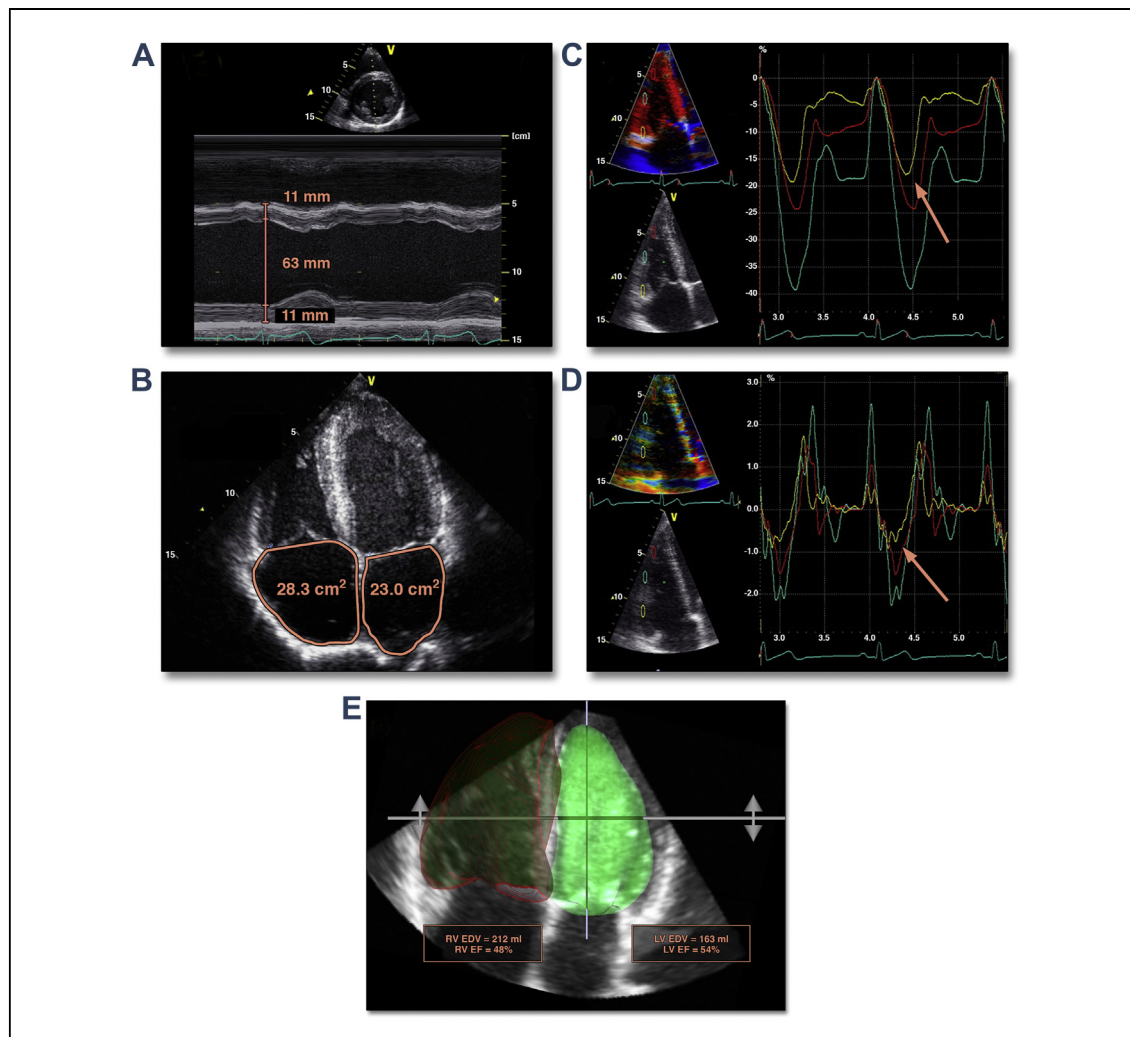
## CMR

CMR has considerable promise in the evaluation of the heart of an athlete. As compared with echocardiography, CMR enables better assessment of the morphology and function of all cardiac chambers while also enabling tissue characterization by means of T2-weighted imaging of acute edema and DGE assessment of focal and diffuse fibrosis (52). Recent developments suggest CMR may also become a gold standard means of assessing cardiac function during exercise (53).

In the recent era in which familial cardiomyopathies are being diagnosed using cascade screening of effected family members, it is increasingly recognized that CMR represents a more sensitive diagnostic tool. As compared with ECG and echocardiography, CMR including DGE assessment can identify athletes when the ECG and echocardiography are normal (29) ([Fig. 2](#)). Thus, CMR should be considered the most comprehensive imaging modality for the exclusion of pathology, making it an extremely valuable imaging modality for assessing athletes with concerning symptoms. However, the relative expense and limited availability of CMR make it less suitable for broad-based screening and the specificity of CMR testing in athletes with little pre-test probability for disease is not sufficiently high to preclude a significant burden of false positive results.

The accurate differentiation of normal athlete's heart from pathology is largely dependent upon our understanding of what constitutes normal. While we now have echocardiographic values from many thousands of athletes of differing demographics and sporting practices, normal CMR values are far less numerous, derived from few centers and from a less diverse sporting population. The largest experience describing the normal range of cardiac morphology and function is provided by the Utrecht group of Prakken *et al.* (54) who compared biventricular volumes, masses, and dimensions in 222 endurance athletes (79 elite and 143 recreational, 42% female) with 114 age and sex-matched nonathletes. They have also described morphological differences





**Figure 3. The “Gray Zone” in Established and Novel Echocardiographic Measures of a 36-Year-Old Well-Trained Marathon Runner**

Echocardiographic measures are demonstrated for the healthy marathon runner exemplified in this review. As is common in athletes, all 4 cardiac chambers are enlarged. M-mode measures demonstrate moderate left ventricular dilation and mild hypertrophy (A). The 2-dimensional atrial areas are mild to moderately increased (B), while 3-dimensional volumes are moderate (LV) to severely (RV) enlarged when compared with reference ranges derived from nonathletic populations (E). Color-coded Doppler derived strain (C) and strain rate (D) demonstrate mildly reduced basal strain and strain rate values (as indicated by the orange arrows). Many of these measurement values overlap with those of cardiomyopathies and there are currently very few diagnostic cutoff values that enable us to risk-stratify asymptomatic athletes with accuracy. Online Video 1 demonstrates unusual RV dilation and function in 4 professional cyclists, thus, further illustrating the difficulties in separating health from disease in asymptomatic athletes. Cardiac magnetic resonance imaging of our middle-aged marathon runner does not always resolve uncertainty, as illustrated in Online Video 2. EDV = end-diastolic volume; EF = ejection fraction; LV = left ventricle; RV = right ventricle.

in cardiac adaptation according to training and sport type in a manner similar to the experience with echocardiography (55,56). Interestingly, they report the only direct comparison between CMR and echocardiography in the assessment of athletes’ cardiac morphology in which, similar to non-athletic findings, measures of cardiac volumes are consistently larger while wall thickness and mass were lower when measured by CMR (57). In total, this constitutes an impressive body of work but

the application of this single-center experience in clinical decision making may be confounded by operator-specific differences in image acquisition and analysis techniques. For example, considerable differences between ventricular volumes determined from axial, as compared with short-axis acquisitions, have been observed even when analyzed at 1 institution using the same software (58,59). Thus, a broader and larger experience of healthy athlete CMR values is required prior to being able to use

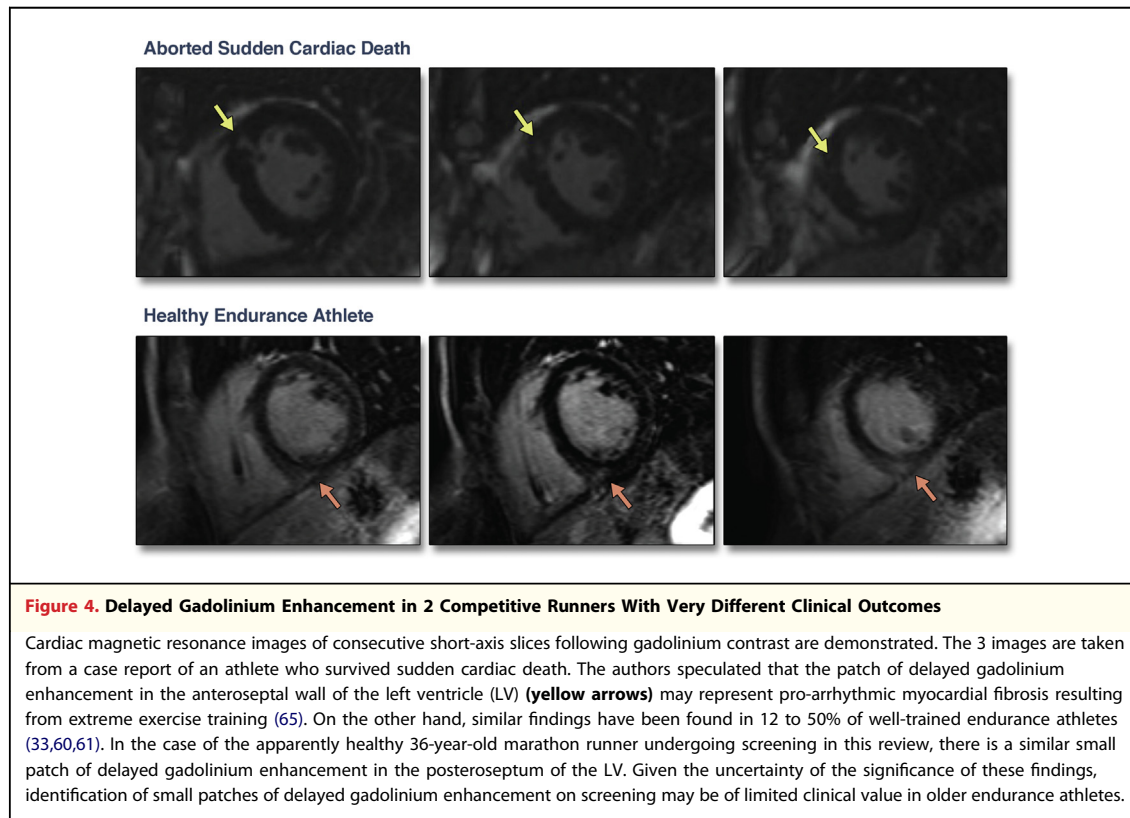
these to accurately identify athletes who have cardiac dimensions that may be considered abnormal.

Recently, there has been considerable interest generated by a number of studies in which DGE has been observed within the LV myocardium of ostensibly healthy athletes (33,60,61). It has been hypothesized that these small patches of DGE found in 12% to 50% of extensively trained veteran athletes may represent fibrosis resulting from extreme physical training (33,61). However, there are still very limited data on which to assess causality and there are a number of studies that have reported that DGE is not a feature of athlete's heart, albeit in younger, less trained cohorts (62–64). The fact that the DGE has been observed in healthy athletic cohorts would suggest that it is of limited clinical significance and we have no long-term clinical data to suggest otherwise. Recently, Trivax et al. (65) described the case of a middle-aged runner in whom aborted SCD was attributed to proarrhythmic myocardial fibrosis, as evidenced by a small patch of DGE (Fig. 4). However, if these changes may be identified in approximately 12% of asymptomatic “healthy” athletes then it may be presumptive to cite this as the probable cause of cardiac arrest. Moreover, if CMR with DGE is used to assess asymptomatic athletes then what advice do we offer the athlete in whom DGE is identified? We contend that there is a clear need to assess the long-term consequences of these findings but, in the meantime, there is no evidence on which to advise athletes of an increased risk of events. Perhaps more than anything, it highlights the need to have a good reason for doing a test which is expensive, time consuming, may include the use of contrast agents (with a small but definite risk) and, in some cases, may increase the level of uncertainty for the athlete and clinician.

### Coronary Artery Calcium Scoring and CTCA

For the 36-year-old marathon runner featured in this review, acquired coronary vascular disease represents 1 of the greater risks for SCD. Kim et al. (66) reported that among marathons completed in the United States, 2 in every 100,000 male athletes (mean age 52 years) suffered SCD, an incidence that seems to have increased in recent years. Among the 8 survivors of cardiac arrest in this study, causation was attributed to nonobstructive atherosclerotic disease in 5 athletes, none of whom had angiographic evidence of ruptured plaque. This raises the question as to whether otherwise stable coronary artery disease could constitute a risk for

SCD among the milieu of hemodynamic, catecholaminergic, and other stresses during a marathon. In this context, if screening were to be performed in our 36-year-old athlete, it may be prudent to include evaluation of his coronary arteries with CACS and/or CTCA. Both have been promoted as “promising tools” for screening asymptomatic veteran athletes (60,67) on the basis that they have proven value over clinical risk factors in the prediction of myocardial infarction and SCD, particularly among those of intermediate risk (16,68). However, there are a number of arguments against screening asymptomatic athletes with coronary artery calcium scoring (CACS) and CTCA. Apart from the financial cost of screening a low-risk cohort and the potential to cause harm due to contrast reactions and radiation exposure (accepting that this has been substantially reduced and now constitutes a relatively small dose), 1 prime concern is whether a significant finding on CACS or CTCA changes the management of the athlete. It is frequently argued that informing an asymptomatic individual of the presence, or likely presence, of coronary artery disease will increase physician and patient motivation to aggressively adhere to pharmacological and lifestyle prevention interventions (69). There have been 2 randomized controlled trials that investigated this hypothesis. Rozanski et al. (70) randomized 1,424 subjects to risk factor management including CACS and 713 subjects to management without CACS and determined that scanned subjects had a slightly greater reduction in systolic blood pressure (–7 mm Hg vs. –5 mm Hg,  $p = 0.02$ ) and low-density lipoprotein cholesterol (–17% vs. –11%,  $p = 0.04$ ), but there was no difference in medication adherence, smoking cessation or exercise and the CACS strategy tended to be more expensive (\$US 4,053 vs. \$3,649,  $p = 0.09$ ). O'Malley et al. (71) randomized 450 asymptomatic middle-aged army personnel who underwent CACS to either have their results known or withheld. Knowledge of CACS did not influence treatment adherence, intervention initiation or the extent to which risk factor management improved. Despite this relatively modest evidence for incremental benefit of CACS beyond traditional risk factor guided management, recent American College of Cardiology/American Heart Association guidelines support its use in asymptomatic individuals with intermediate cardiovascular risk (10% to 90% Framingham risk) but regard CACS as inappropriate for those of low risk (72). It would seem, therefore, that few athletes would benefit from CACS. If considering the study of Mohlenkamp et al. (60),



none of the 108 marathon runners age 50 years or older had a Framingham risk prediction of >10%.

According to American College of Cardiology/American Heart Association guidelines, there is no role for CTCA screening of asymptomatic individuals of low or moderate cardiovascular risk according to American Heart Association guidelines (72).

### Exercise Testing

A number of studies have demonstrated that an abnormal exercise ECG test is associated with cardiovascular events, total mortality, and SCD in asymptomatic adults (1,73,74). However, it is also notable that the predominant risk factor is low fitness. An exercise capacity of greater than 8 to 10 METs (approximating a  $VO_2$ max of 28 to 35 ml/min/kg or the ability to run slowly) is associated with fewer cardiovascular events and greater longevity in men and women, the predictive value of which exceeds any information provided from ECG changes during the test (73,74). Even among adults with a moderate to high risk of coronary vessel disease, significant myocardial ischemia is uncommon among those with a maximal exercise tolerance >10 METs (75). Thus, the simplest and most cost-effective risk stratification would be to simply determine whether an adult is

able to swim or jog at low to moderate intensity and directing further assessment at those who cannot. Athletes, virtually by definition, pass this test and have an excellent prognosis. Further testing will have limited impact on further refining this risk and is not recommended except in those who are planning on entering vigorous competitive situations and who have moderate-to-high cardiovascular risk profiles (76,77). There is no evidence to guide recommendations in athletes already engaged in vigorous sporting activities, such as the seasoned marathon runner exemplified in this review. If we conclude that the most predictive feature on exercise testing is fitness, then the answer is apparent before the athlete steps on the treadmill and any abnormality is, statistically, most likely to be benign.

Sofi *et al.* (78) provide the only large-scale evaluation of exercise stress testing in pre-participation screening for competitive sports. Drawing from the Italian experience in which exercise ECG testing has been a mandated part of pre-participation screening since 1982, the study reported the results of over 30,000 referrals for screening. The unselected population included a very broad age range (5 to 92 years, mean = 31 years) and a combination of well-trained athletes and nonathletes seeking to commence sport. Abnormalities were detected in 4.9% leading to

disqualification from competitive sport in 0.6% of the total population. The efficacy of these exclusions in preventing SCD remains unknown.

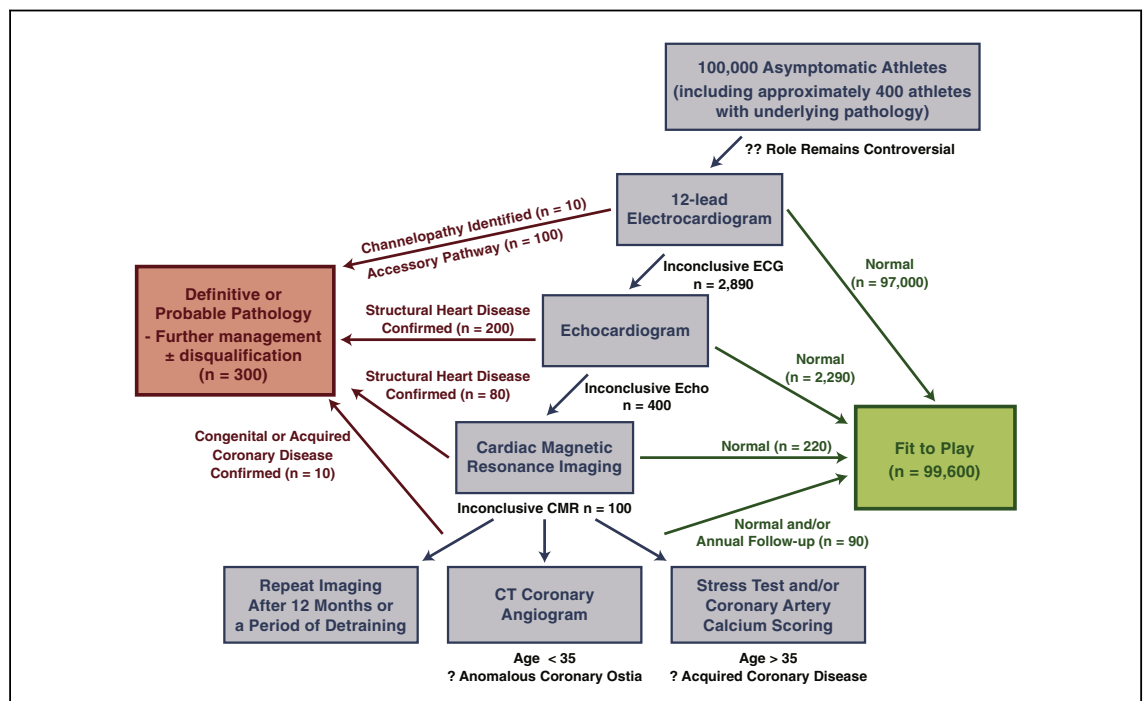
### Cardiac Imaging as a Second-Line Screening Tool

While there is no evidence to support cardiac imaging as a primary modality in screening asymptomatic athletes, it becomes of prime relevance in the evaluation of athletes in whom an abnormality is identified on ECG. Recently refined recommendations aim to increase the specificity of the screening ECG in athletes to >97% (79). If achieved, it may be expected that the prevalence of underlying cardiac disease will be far greater among those 3% of athletes with significant abnormalities on ECG. Thus, according to Bayes' theorem, the predictive value of cardiac imaging is much improved. Further testing should be applied on a case-by-case basis and should focus on appraising the differential diagnoses arising from the clinical examination, history and ECG. The flowchart provided in Figure 5 illustrates the manner in which a hierarchy of cardiac imaging modalities may enable differentiation of healthy athletes from those with conditions that require

further management to minimize the risk of SCD. This chart is unable to reflect the considerable flexibility required of clinical decision making. For example, in the athlete with deep T-wave inversion in anteroseptal leads (raising the suspicion of ARVC) or inferolateral leads (HCM), the clinician may be ill-advised to reassure the athlete even if the echocardiographic study were to appear normal. In this scenario, a subtle cardiomyopathy may be evident on CMR or may evolve with time, thus necessitating careful surveillance.

### Conclusions

Athletes represent a group in whom the risks of cardiovascular events and SCD are extremely low. The causes of SCD are relatively diverse and are not accurately identified by any 1 imaging test, especially in the middle-aged athlete who represents a substantial proportion of competitive sports participation. At present, we have an incomplete understanding of what constitutes the normal range of cardiac morphology and function among athletes of all ages and ethnicities. This is especially true for novel techniques and imaging modalities other than



**Figure 5. Screening 100,000 Asymptomatic Athletes Using a Hierarchy of Cardiac Imaging Modalities**

This flowchart provides an algorithm whereby cardiac imaging may be employed as secondary screening modality following refinement of the "at-risk" population by means of electrocardiogram (ECG) screening. This flowchart represents an ideal scenario in which all potentially serious pathology is identified (100% sensitivity) and no healthy athletes are incorrectly diagnosed with pathology (100% specificity) following the cascade of tests. CMR = cardiac magnetic resonance; CT = computed tomography.

the most basic echocardiographic measures. As exemplified by the examples in this review, atypical findings such as marked cardiac dilation, reduced deformation or small patches of delayed gadolinium enhancement may introduce uncertainty in the asymptomatic athlete in whom the risk of SCD is extremely small. Therefore, we do not believe that cardiac imaging can be recommended as a first-line screening tool. Rather, patient specific investigations should be focused on evaluating those athletes in whom clinical suspicion is raised by symptoms, family history, clinical exam and/or abnormalities on ECG. While it is imperative that we continue our efforts to safeguard athletes, we must

also recognize the current limitations of our tools in predicting SCD in low-risk populations.

#### Acknowledgements

The authors would like to thank the cardiology and radiology departments of the University Hospital of Leuven, St Vincent's Hospital Melbourne, and St George's Hospital London for providing some of the images used in this manuscript.

**Reprint requests and correspondence:** Dr. André La Gerche, Department of Cardiology, St Vincent's Hospital, PO Box 2900, Fitzroy 3065, Australia. *E-mail:* [Andre.LaGerche@svhm.org.au](mailto:Andre.LaGerche@svhm.org.au).

#### REFERENCES

1. Laukkanen JA, Makikallio TH, Rauramaa R, Kiviniemi V, Ronkainen K, Kurl S. Cardiorespiratory fitness is related to the risk of sudden cardiac death: a population-based follow-up study. *J Am Coll Cardiol* 2010;56:1476-83.
2. Shiroma EJ, Lee IM. Physical activity and cardiovascular health: lessons learned from epidemiological studies across age, gender, and race/ethnicity. *Circulation* 2010;122:743-52.
3. Corrado D, Basso C, Pavei A, Michieli P, Schiavon M, Thiene G. Trends in sudden cardiovascular death in young competitive athletes after implementation of a preparticipation screening program. *JAMA* 2006;296:1593-601.
4. Corrado D, Schimid C, Basso C, et al. Risk of sports: do we need a preparticipation screening for competitive and leisure athletes? *Eur Heart J* 2011;32:934-44.
5. Maron BJ, Doerer JJ, Haas TS, Tierney DM, Mueller FO. Sudden deaths in young competitive athletes: analysis of 1866 deaths in the United States, 1980-2006. *Circulation* 2009;119:1085-92.
6. Maron BJ, Haas TS, Doerer JJ, Thompson PD, Hodges JS. Comparison of U.S. and Italian experiences with sudden cardiac deaths in young competitive athletes and implications for preparticipation screening strategies. *Am J Cardiol* 2009;104:276-80.
7. Thompson PD. Preparticipation screening of competitive athletes: seeking simple solutions to a complex problem. *Circulation* 2009;119:1072-4.
8. Corrado D, Basso C, Rizzoli G, Schiavon M, Thiene G. Does sports activity enhance the risk of sudden death in adolescents and young adults? *J Am Coll Cardiol* 2003;42:1959-63.
9. Marijon E, Tafflet M, Celermajer DS, et al. Sports-related sudden death in the general population. *Circulation* 2011;124:672-81.
10. Harmon KG, Asif IM, Klossner D, Drezner JA. Incidence of sudden cardiac death in national collegiate athletic association athletes. *Circulation* 2011;123:1594-600.
11. Thompson PD, Funk EJ, Carleton RA, Sturmer WQ. Incidence of death during jogging in Rhode Island from 1975 through 1980. *JAMA* 1982;247:2535-8.
12. de Noronha SV, Sharma S, Papadakis M, Desai S, Whyte G, Sheppard MN. Aetiology of sudden cardiac death in athletes in the United Kingdom: a pathological study. *Heart* 2009;95:1409-14.
13. Van Camp SP, Bloor CM, Mueller FO, Cantu RC, Olson HG. Nontraumatic sports death in high school and college athletes. *Med Sci Sports Exerc* 1995;27:641-7.
14. Maron BJ, Gardin JM, Flack JM, Gidding SS, Kurosaki TT, Bild DE. Prevalence of hypertrophic cardiomyopathy in a general population of young adults. Echocardiographic analysis of 4111 subjects in the CARDIA Study. Coronary Artery Risk Development in (Young) Adults. *Circulation* 1995;92:785-9.
15. Maron BJ, Mathenge R, Casey SA, Poliac LC, Longe TF. Clinical profile of hypertrophic cardiomyopathy identified de novo in rural communities. *J Am Coll Cardiol* 1999;33:1590-5.
16. Rodday AM, Triedman JK, Alexander ME, et al. Electrocardiogram screening for disorders that cause sudden cardiac death in asymptomatic children: a meta-analysis. *Pediatrics* 2012;129:e999-1010.
17. Davis JA, Cecchin F, Jones TK, Portman MA. Major coronary artery anomalies in a pediatric population: incidence and clinical importance. *J Am Coll Cardiol* 2001;37:593-7.
18. Gemayel C, Pelliccia A, Thompson PD. Arrhythmogenic right ventricular cardiomyopathy. *J Am Coll Cardiol* 2001;38:1773-81.
19. Cerrone M, Napolitano C, Priori SG. Genetics of ion-channel disorders. *Curr Opin Cardiol* 2012;27:242-52.
20. Pilote L, Pashkow F, Thomas JD, et al. Clinical yield and cost of exercise treadmill testing to screen for coronary artery disease in asymptomatic adults. *Am J Cardiol* 1998;81:219-24.
21. Marcus FI, McKenna WJ, Sherrill D, et al. Diagnosis of arrhythmogenic right ventricular cardiomyopathy/dysplasia: proposed modification of the task force criteria. *Circulation* 2010;121:1533-41.
22. Maron BJ, Pelliccia A. The heart of trained athletes: cardiac remodeling and the risks of sports, including sudden death. *Circulation* 2006;114:1633-44.
23. Maron BJ. Distinguishing hypertrophic cardiomyopathy from athlete's heart: a clinical problem of increasing magnitude and significance. *Heart* 2005;91:1380-2.
24. Sharma S, Elliott PM, Whyte G, et al. Utility of metabolic exercise testing in distinguishing hypertrophic cardiomyopathy from physiologic left ventricular hypertrophy in athletes. *J Am Coll Cardiol* 2000;36:864-70.
25. Wilson MG, Chandra N, Papadakis M, O'Hanlon R, Prasad SK, Sharma S. Hypertrophic cardiomyopathy and ultra-endurance running—two incompatible entities? *J Cardiovasc Magn Reson* 2011;13:77.

26. La Gerche A, Taylor AJ, Prior DL. Athlete's heart: the potential for multimodality imaging to address the critical remaining questions. *J Am Coll Cardiol Img* 2009;2:350-63.
27. D'Andrea A, Cocchia R, Riegler L, et al. Left ventricular myocardial velocities and deformation indexes in top-level athletes. *J Am Soc Echocardiogr* 2010;23:1281-8.
28. Afonso L, Kondur A, Simegn M, et al. Two-dimensional strain profiles in patients with physiological and pathological hypertrophy and preserved left ventricular systolic function: a comparative analyses. *BMJ Open* 2012;2.
29. Rowin EJ, Maron BJ, Appelbaum E, et al. Significance of false negative electrocardiograms in preparticipation screening of athletes for hypertrophic cardiomyopathy. *Am J Cardiol* 2012;110:1027-32.
30. Pelliccia A, Maron BJ, Spataro A, Proschan MA, Spirito P. The upper limit of physiologic cardiac hypertrophy in highly trained elite athletes. *N Engl J Med* 1991;324:295-301.
31. Rawlins J, Carre F, Kervio G, et al. Ethnic differences in physiological cardiac adaptation to intense physical exercise in highly trained female athletes. *Circulation* 2010;121:1078-85.
32. Prior DL, La Gerche A. The athlete's heart. *Heart* 2012;98:947-55.
33. La Gerche A, Burns AT, Mooney DJ, et al. Exercise-induced right ventricular dysfunction and structural remodeling in endurance athletes. *Eur Heart J* 2012;33:998-1006.
34. La Gerche A, Heidbuchel H, Burns AT, et al. Disproportionate exercise load and remodeling of the athlete's right ventricle. *Med Sci Sports Exerc* 2011;43:974-81.
35. Teske AJ, Prakken NH, De Boeck BW, et al. Echocardiographic tissue deformation imaging of right ventricular systolic function in endurance athletes. *Eur Heart J* 2009;30:969-77.
36. Kim JH, Noseworthy PA, McCarty D, et al. Significance of electrocardiographic right bundle branch block in trained athletes. *Am J Cardiol* 2011;107:1083-9.
37. Teske AJ, Cox MG, De Boeck BW, Doevendans PA, Hauer RN, Cramer MJ. Echocardiographic tissue deformation imaging quantifies abnormal regional right ventricular function in arrhythmic right ventricular dysplasia/cardiomyopathy. *J Am Soc Echocardiogr* 2009;22:920-7.
38. Abergel E, Chatellier G, Hagege AA, et al. Serial left ventricular adaptations in world-class professional cyclists: implications for disease screening and follow-up. *J Am Coll Cardiol* 2004;44:144-9.
39. Gati S, Chandra N, Bennett RL, et al. Increased left ventricular trabeculation in highly trained athletes: do we need more stringent criteria for the diagnosis of left ventricular non-compaction in athletes? *Heart* 2013;99:401-8.
40. Plehn G, Vormbrock J, Perings S, et al. Comparison of right ventricular functional response to exercise in hypertrophic versus idiopathic dilated cardiomyopathy. *Am J Cardiol* 2010;105:116-21.
41. Zeppilli P, dello Russo A, Santini C, et al. In vivo detection of coronary artery anomalies in asymptomatic athletes by echocardiographic screening. *Chest* 1998;114:89-93.
42. Weiner RB, Wang F, Hutter AM Jr., et al. The feasibility, diagnostic yield, and learning curve of portable echocardiography for out-of-hospital cardiovascular disease screening. *J Am Soc Echocardiogr* 2012;25:568-75.
43. Prakken NH, Cramer MJ, Olimulder MA, Agostoni P, Mali WP, Velthuis BK. Screening for proximal coronary artery anomalies with 3-dimensional MR coronary angiography. *Int J Cardiovasc Imaging* 2010;26:701-10.
44. Pelliccia A, Di Paolo FM, De Blasiis E, et al. Prevalence and clinical significance of aortic root dilation in highly trained competitive athletes. *Circulation* 2010;122:698-706, 3 p following 706.
45. Iskandar A, Thompson PD. A meta-analysis of aortic root size in elite athletes. *Circulation* 2013;127:791-8.
46. Stefani L, Galanti G, Toncelli L, et al. Bicuspid aortic valve in competitive athletes. *Br J Sports Med* 2008;42:31-5; discussion 35.
47. Zeltser I, Cannon B, Silvana L, et al. Lessons learned from preparticipation cardiovascular screening in a state funded program. *Am J Cardiol* 2012;110:902-8.
48. Garber AM, Solomon NA. Cost-effectiveness of alternative test strategies for the diagnosis of coronary artery disease. *Ann Intern Med* 1999;130:719-28.
49. Diamond GA, Forrester JS. Analysis of probability as an aid in the clinical diagnosis of coronary-artery disease. *N Engl J Med* 1979;300:1350-8.
50. Pryor DB, Harrell FE Jr., Lee KL, Califf RM, Rosati RA. Estimating the likelihood of significant coronary artery disease. *Am J Med* 1983;75:771-80.
51. Douglas PS, Khandheria B, Stainback RF, et al. ACCF/AHA/ACEP/AHA/ASNC/SCAI/SCCT/SCMR 2008 appropriateness criteria for stress echocardiography: a report of the American College of Cardiology Foundation Appropriateness Criteria Task Force, American Society of Echocardiography, American College of Emergency Physicians, American Heart Association, American Society of Nuclear Cardiology, Society for Cardiovascular Angiography and Interventions, Society of Cardiovascular Computed Tomography, and Society for Cardiovascular Magnetic Resonance endorsed by the Heart Rhythm Society and the Society of Critical Care Medicine. *J Am Coll Cardiol* 2008;51:1127-47.
52. Jellis C, Martin J, Narula J, Marwick TH. Assessment of non-ischemic myocardial fibrosis. *J Am Coll Cardiol* 2010;56:89-97.
53. La Gerche A, Claessen G, Van de Bruene A, et al. Cardiac MRI: a new gold standard for ventricular volume quantification during high-intensity exercise. *Circ Cardiovasc Imaging* 2013;6:329-38.
54. Prakken NH, Velthuis BK, Teske AJ, Mosterd A, Mali WP, Cramer MJ. Cardiac MRI reference values for athletes and nonathletes corrected for body surface area, training hours/week and sex. *Eur J Cardiovasc Prev Rehabil* 2010;17:198-203.
55. Luijckx T, Velthuis BK, Backx FJ, et al. Anabolic androgenic steroid use is associated with ventricular dysfunction on cardiac MRI in strength trained athletes. *Int J Cardiol* 2013;167:664-8.
56. Luijckx T, Cramer MJ, Prakken NH, et al. Sport category is an important determinant of cardiac adaptation: an MRI study. *Br J Sports Med* 2012;46:1119-24.
57. Prakken NH, Teske AJ, Cramer MJ, et al. Head-to-head comparison between echocardiography and cardiac MRI in the evaluation of the athlete's heart. *Br J Sports Med* 2012;46:348-54.
58. Fratz S, Schuhbaeck A, Buchner C, et al. Comparison of accuracy of axial slices versus short-axis slices for measuring ventricular volumes by cardiac magnetic resonance in patients with corrected tetralogy of fallot. *Am J Cardiol* 2009;103:1764-9.
59. Alfakih K, Plein S, Bloomer T, Jones T, Ridgway J, Sivanathan M. Comparison of right ventricular volume measurements between axial and short axis orientation using steady-state free precession magnetic resonance imaging. *J Magn Reson Imaging* 2003;18:25-32.
60. Mohlenkamp S, Lehmann N, Breuckmann F, et al. Running: the

- risk of coronary events: Prevalence and prognostic relevance of coronary atherosclerosis in marathon runners. *Eur Heart J* 2008;29:1903-10.
61. Wilson M, O'Hanlon R, Prasad S, et al. Diverse patterns of myocardial fibrosis in lifelong, veteran endurance athletes. *J Appl Physiol* 2011;110:1622-6.
  62. O'Hanlon R, Wilson M, Wage R, et al. Troponin release following endurance exercise: is inflammation the cause? a cardiovascular magnetic resonance study. *J Cardiovasc Magn Reson* 2010;12:38.
  63. Trivax JE, Franklin BA, Goldstein JA, et al. Acute cardiac effects of marathon running. *J Appl Physiol* 2010;108:1148-53.
  64. Mousavi N, Czarneci A, Kumar K, et al. Relation of biomarkers and cardiac magnetic resonance imaging after marathon running. *Am J Cardiol* 2009;103:1467-72.
  65. Trivax JE, McCullough PA. Phidipides cardiomyopathy: a review and case illustration. *Clin Cardiol* 2012;35:69-73.
  66. Kim JH, Malhotra R, Chiampas G, et al. Cardiac arrest during long-distance running races. *N Engl J Med* 2012;366:130-40.
  67. Borjesson M, Drezner J. Cardiac screening: time to move forward! *Br J Sports Med* 2012;46 Suppl 1:i4-6.
  68. Greenland P, LaBree L, Azen SP, Doherty TM, Detrano RC. Coronary artery calcium score combined with Framingham score for risk prediction in asymptomatic individuals. *JAMA* 2004;291:210-5.
  69. Kalia NK, Miller LG, Nasir K, Blumenthal RS, Agrawal N, Budoff MJ. Visualizing coronary calcium is associated with improvements in adherence to statin therapy. *Atherosclerosis* 2006;185:394-9.
  70. Rozanski A, Gransar H, Shaw LJ, et al. Impact of coronary artery calcium scanning on coronary risk factors and downstream testing the EISNER (Early Identification of Subclinical Atherosclerosis by Noninvasive Imaging Research) prospective randomized trial. *J Am Coll Cardiol* 2011;57:1622-32.
  71. O'Malley PG, Feuerstein IM, Taylor AJ. Impact of electron beam tomography, with or without case management, on motivation, behavioral change, and cardiovascular risk profile: a randomized controlled trial. *JAMA* 2003;289:2215-23.
  72. Taylor AJ, Cerqueira M, Hodgson JM, et al. ACCF/SCCT/ACR/AHA/ASE/ASNC/NASCI/SCAI/SCMR 2010 appropriate use criteria for cardiac computed tomography. A report of the American College of Cardiology Foundation Appropriate Use Criteria Task Force, the Society of Cardiovascular Computed Tomography, the American College of Radiology, the American Heart Association, the American Society of Echocardiography, the American Society of Nuclear Cardiology, the North American Society for Cardiovascular Imaging, the Society for Cardiovascular Angiography and Interventions, and the Society for Cardiovascular Magnetic Resonance. *J Am Coll Cardiol* 2010;56:1864-94.
  73. Mora S, Redberg RF, Cui Y, et al. Ability of exercise testing to predict cardiovascular and all-cause death in asymptomatic women: a 20-year follow-up of the lipid research clinics prevalence study. *JAMA* 2003;290:1600-7.
  74. Myers J, Prakash M, Froelicher V, Do D, Partington S, Atwood JE. Exercise capacity and mortality among men referred for exercise testing. *N Engl J Med* 2002;346:793-801.
  75. Bourque JM, Holland BH, Watson DD, Beller GA. Achieving an exercise workload of > or = 10 metabolic equivalents predicts a very low risk of inducible ischemia: does myocardial perfusion imaging have a role? *J Am Coll Cardiol* 2009;54:538-45.
  76. Smith SC Jr., Amsterdam E, Balady GJ, et al. Prevention Conference V: Beyond secondary prevention: identifying the high-risk patient for primary prevention: tests for silent and inducible ischemia: Writing Group II. *Circulation* 2000;101:E12-6.
  77. Maron BJ, Araujo CG, Thompson PD, et al. Recommendations for preparticipation screening and the assessment of cardiovascular disease in masters athletes: an advisory for healthcare professionals from the working groups of the World Heart Federation, the International Federation of Sports Medicine, and the American Heart Association Committee on Exercise, Cardiac Rehabilitation, and Prevention. *Circulation* 2001;103:327-34.
  78. Sofi F, Capalbo A, Pukccci N, et al. Cardiovascular evaluation, including resting and exercise electrocardiography, before participation in competitive sports: cross sectional study. *BMJ* 2008;337:a346.
  79. Drezner JA, Ackerman MJ, Anderson J, et al. Electrocardiographic interpretation in athletes: the 'Seattle Criteria'. *Br J Sports Med* 2013;47:122-4.

---

**Key Words:** athlete's heart ■ cardiomyopathy ■ cardiovascular screening ■ exercise ■ risk prediction ■ sudden cardiac death.

#### APPENDIX

For supplemental videos and their legends, please see the online version of this article.

To participate in this CME activity by taking the quiz and claiming your CME credit certificate, please go to [www.imaging.onlinejacc.org](http://www.imaging.onlinejacc.org) and select the CME tab on the top navigation bar.