



## Retroperitoneal paraganglioma presenting with pancytopenia: A rare case with rare manifestation



Mutlu Ünver<sup>a,\*</sup>, Şafak Öztürk<sup>a</sup>, Varlık Erol<sup>b</sup>, Erdem Barış Cartı<sup>c</sup>, Osman Bozbıyık<sup>d</sup>, Eyüp Kebapçı<sup>e</sup>, Mustafa Ölmez<sup>e</sup>, Gökhan Akbulut<sup>e</sup>

<sup>a</sup> İzmir University, Department of General Surgery, İzmir, Turkey

<sup>b</sup> Başkent University, Department of General Surgery, İzmir, Turkey

<sup>c</sup> Aydın State Hospital, Department of General Surgery, Aydın, Turkey

<sup>d</sup> Afyon Kocatepe University, Department of General Surgery, Afyon, Turkey

<sup>e</sup> Tepecik Education and Research Hospital, Department of General Surgery, İzmir, Turkey

### ARTICLE INFO

#### Article history:

Received 2 July 2015

Received in revised form 18 July 2015

Accepted 20 July 2015

Available online 28 July 2015

#### Keywords:

Paraganglioma

Pancytopenia

Retroperitoneal

Reactive thrombocytosis

### ABSTRACT

**INTRODUCTION:** Paragangliomas are tumors that arise from extraadrenal chromaffin cells and most of them are asymptomatic presenting with painless mass. Retroperitoneal paragangliomas are mostly benign with good prognosis; however, they can present with abdominal pain, palpable mass, or hypertensive episodes. Surgical resection is still the main treatment and necessary for histological assessment. **CASE REPORT:** A 41 year old female patient presented with 6 months of loss of appetite, weight loss, weakness and breathlessness on exertion. The patient's initial blood examination showed marked anemia, reduced leukocyte count with neutropenia and lymphopenia and a marked reduction in the platelet count. The patient was admitted for evaluation of her pancytopenia. Magnetic resonance imaging revealed a 8 × 7 × 8 cm sized mass closed to the pancreatic tail invading splenic hilum. A large mass was identified retroperitoneally, closed to the tail of pancreas with a splenic hilum invasion. Total mass resection and splenectomy was performed.

**DISCUSSION:** Complete surgical excision is the treatment of choice for extra-adrenal paragangliomas as well as for recurrent or metastatic neoplasms. Reactive thrombocytosis is a common cause of thrombocytosis. Splenectomy was found to be one of the main causes of extreme reactive thrombocytosis. Reactive thrombocytosis is a predictable finding after splenectomy and management of the thrombocytosis and prevention of complications should be initiated.

© 2015 The Authors. Published by Elsevier Ltd. on behalf of Surgical Associates Ltd. This is an open access article under the CC BY-NC-ND license (<http://creativecommons.org/licenses/by-nc-nd/4.0/>).

## 1. Introduction

Paragangliomas are tumors that arise from extraadrenal chromaffin cells and can develop at various sites of the body including the head, neck, thorax and the abdomen. Most of the paragangliomas are asymptomatic presenting with painless mass. About 75% of paragangliomas are sporadic and 85% of paragangliomas develop in the abdominal cavity [1].

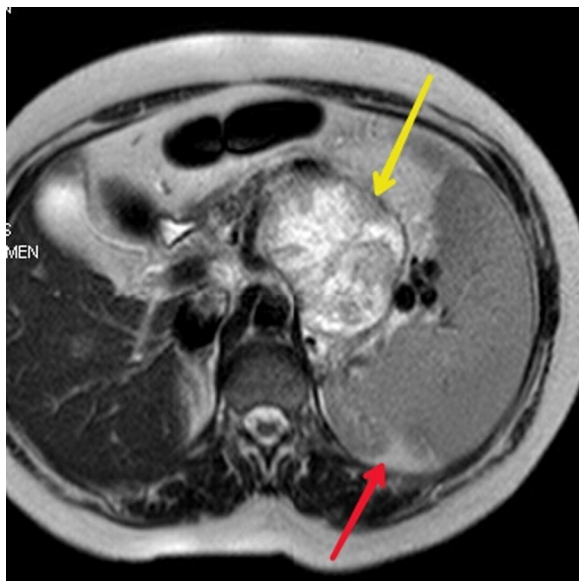
When presenting within the abdominal cavity, they may arise as a primary retroperitoneal neoplasm and can mimic vascular malformations or other conditions related to specific retroperitoneal organs such as the pancreas, kidneys, or adrenals. Retroperitoneal paragangliomas arise from specialized neural crest derived cells distributed along the aorta in association with the sympathetic

chain. Retroperitoneal paragangliomas mainly affect adults who are in the fourth or fifth decade of life, and they have no sex predilection [2]. Retroperitoneal paragangliomas are mostly benign with good prognosis; however, they can present with abdominal pain, palpable mass, or hypertensive episodes [3]. Patients with secretory tumors experience paroxysmal episodic hypertension, as well as the typical triad of symptoms associated with pheochromocytomas, for example, palpitations, headache and sweating. Nonfunctional paragangliomas most commonly manifest as abdominal pain or a mass [4]. In the present case, we report a rare case of a retroperitoneal paraganglioma presenting with pancytopenia.

## 2. Case report

A 41 year old female patient presented with 6 months of loss of appetite, weight loss, weakness, and breathlessness on exertion. There was no history of smoking and alcohol abuse. There was no remarkable family history. On admission, vital signs (blood

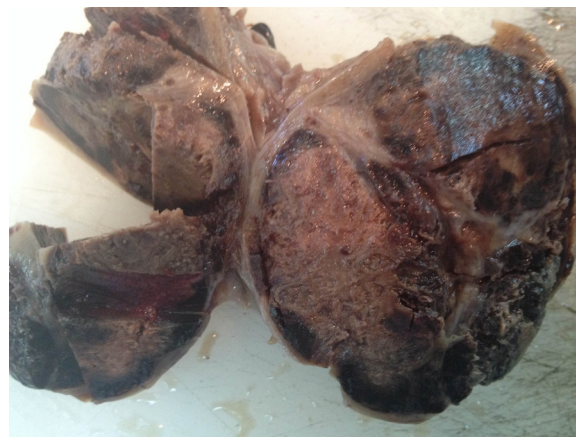
\* Corresponding author at: İzmir University, Department of General Surgery, Yeni Girne Bulv. 1825sk no. 12, Karşıyaka, İzmir, Turkey. Fax: +90 2323423371.  
E-mail address: [mutluunver@gmail.com](mailto:mutluunver@gmail.com) (M. Ünver).



**Fig. 1.** T2 weighted axial MRI image (red arrow shows the spleen and yellow arrow shows the mass which is centrally hyperintense and peripherally hypointense). (For interpretation of the references to color in this figure legend, the reader is referred to the web version of this article.)

pressure, heart rate, respiration rate, and body temperature) were within normal limits. There was no peripheral lymphadenopathy, hepatomegaly or splenomegaly in physical examination. The initial blood examination showed marked anemia (Hb = 7.6 g/dl), reduced leukocyte count (2100/cu mm) with neutropenia and lymphopenia and a marked reduction in the platelet count (70,000 platelets/cu mm). A repeat complete blood count (CBC) showed similar results. Basic metabolic panel, chest X-ray film, and electrocardiogram results were all normal. Tumor marker assays showed that alpha-fetoprotein was 7.2 n/ml (normal 0–8.1), carcinoembryonic antigen (CEA) was 3 ng/ml (normal 0–5), carbohydrate antigen 19–9 (CA 19–9) was 11 U/ml (normal 0–37).

The patient was admitted for evaluation of her pancytopenia by haematology department. All the results, testing for human immunodeficiency virus (HIV), Epstein–Barr virus (EBV), cytomegalovirus, hepatitis, parvovirus B19, and antinuclear antibodies were negative. B12 and folate levels were in normal limits. Upper GI endoscopy and colonoscopy were also normal. Then bone marrow aspiration was performed to evaluate the cause of pancytopenia. The aspirate was normocellular and showed normal maturation of all the three series. The bone marrow reaction was normoblastic. Abdominal USG was performed to revealed the dimensions of the spleen. A 8 × 7 size cm mass from pancreatic tail to splenic hilum was observed in the abdominal USG. Magnetic resonance imaging revealed a 8 × 7 × 8 cm sized mass closed to the pancreatic tail invading splenic hilum (Fig. 1). The patient underwent a laparotomy with a median superior incision. A large mass was identified retroperitoneally, closed to the tail of pancreas with a splenic vein occlusion. Total mass resection and splenectomy was performed (Fig. 2). Mean operative time was 120 min and mean blood loss was 200 cc. A significant improvement in the total leucocyte and platelet count was seen on the third day of surgery. There was an increase in the haemoglobin concentration but was the last parameter to show improvement. Her platelet count was abnormally elevated to 677,000 platelets/cu mm postoperative day 6. The patient remained asymptomatic at discharge, and the recommendations for reactive thrombocytosis after splenectomy were discussed with her. We recommended mobilization and increased fluid intake. She was started on 100 mg of aspirin daily. The patient



**Fig. 2.** Grossly characteristic brown appearance of the tumor. Tumor mass is well-circumscribed with a fibrous capsule.

was discharged after 7 postoperative day. One month following surgery, blood counts were in normal limits. Pathological examination of the specimen was reported as paraganglioma (Fig. 3).

At 6-months follow-up, the patient's complete blood count remains normal and abdominal CT did not reveal any recurrence of the mass.

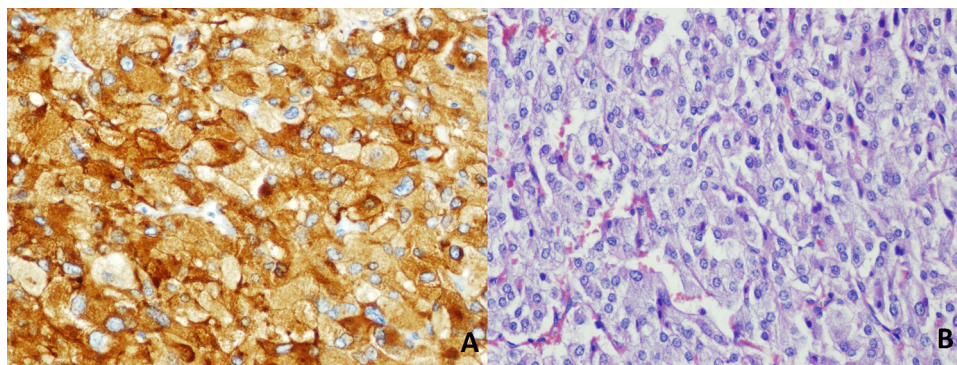
### 3. Discussion

Paragangliomas are extra-adrenal chromaffin tumours that develop at the expense of neuroectodermal cells of the autonomous nervous system [5]. Paragangliomas can develop at various sites of the body including the head, neck, thorax and the abdomen. Despite most of the paragangliomas are asymptomatic, retroperitoneal and nonfunctioning forms are very rare [6]. The first imaging modality in the diagnosis of extra-adrenal paragangliomas is magnetic resonance imaging (MRI) secondary to superior tissue characterization and absence of radiation hazards [7]. Computerized tomography (CT) scan also has sensitivity of around 90% for identifying extra-adrenal paragangliomas and they appear as highly vascular structure with areas of intralesional hemorrhage and necrosis [8]. Metaiodobenzylguanidine scintigraphy (MIBG scintigraphy) has often been used as an imaging modality in the diagnosis of neuroendocrine tumors, but it lacks sensitivity for extra-adrenal paragangliomas [1].

Complete surgical excision is the treatment of choice for extra-adrenal paragangliomas as well as for recurrent or metastatic neoplasms [2]. Patient with metastatic disease will require adjuvant radiotherapy while chemotherapy is restricted to patients not accessible for surgery and resistant to radionuclide therapy [9].

Reactive thrombocytosis is a common cause of thrombocytosis [10]. Splenectomy was found to be one of the main causes of extreme reactive thrombocytosis as in the present case [11]. Reactive thrombocytosis is a predictable finding after splenectomy, with the platelet count peaking at 1 to 3 weeks and returning to normal levels in weeks, months, and, rarely, years [12]. Essential thrombocytosis is not a well-recognized cause for arterial and venous thrombosis. Management of the thrombocytosis and prevention of complications should be initiated [13]. The first line of therapy is the administration of platelet-antiaggregating medication such as aspirin [14].

Histopathological findings are not much useful to differentiate between benign and malignant paragangliomas only extensive local invasion and distant metastasis to liver, bone, and lymph nodes have been used as indicators for malignancy [1,8]. Follow-up imaging is necessary in cases of patients with elevated



**Fig. 3.** (A): Chromogranin A: Tumor cells are diffusely positive for neuroendocrine marker Chromogranin A immunohistochemically. (B): H&E: Well defined nests of cuboidal cells separated by highly vascularized fibrous septa. Individual cells have a moderately abundant granular basophilic cytoplasm.

metanephrine and catecholamine levels or with non functional original tumors [3]. Because of malignant potential and higher recurrence rate in paragangliomas, lifelong followup is always recommended [15].

#### 4. Conclusion

Paragangliomas are very rare entities and has never been reported before manifesting with pancytopenia. Surgical resection is still the main treatment and necessary for histological assessment. Reactive thrombocytosis is a predictable finding after splenectomy as in the present case. Management of the thrombocytosis and prevention of complications should be kept in mind after splenectomy.

#### Funding

None.

#### Consent

Written informed consent was obtained from the patient for publication of this case report and any accompanying images.

#### Ethical approval

N/A.

#### Conflict of interest

None.

#### Author contribution

Mutlu Ünver M.D.; Study concept or design, data collection, data analysis or interpretation, writing the paper.

Şafak Öztürk M.D.; Study concept or design, data collection, data analysis or interpretation, writing the paper.

Varlık Erol M.D.; Data analysis or interpretation, writing the paper.

Erdem Barış Cartı M.D.; Data analysis or interpretation, writing the paper.

Osman Bozbıyık M.D.; Data analysis or interpretation, writing the paper.

Eyüp Kebaşçı M.D.; Study concept or design, data collection.  
Mustafa Ölmez M.D.; Study concept or design, data collection.  
Gökhan Akbulut M.D.; Study concept or design, data collection, data analysis or interpretation, writing the paper.

#### Gurantor

Mutlu Ünver.

#### References

- [1] P. Brahmabhatt, P. Patel, A. Saleem, R. Narayan, M. Young, Retroperitoneal paraganglioma presenting as a chest pain: a case report, *Case Rep. Oncol. Med.* 2013 (2013) 329472.
- [2] W.C. Lin, H.Y. Wang, C.W. Chang, J.L. Lin, C.H. Tsai, Retroperitoneal paraganglioma manifesting as paralytic ileus: a case report, *J. Med. Case Rep.* 6 (June (1)) (2012) 158.
- [3] D. Erickson, Y.C. Kudva, M.J. Ebersold, G.B. Thompson, C.S. Grant, J.A. van Heerden, W.F. Young Jr, Benign paragangliomas: clinical presentation and treatment outcomes in 236 patients, *J. Clin. Endocrinol. Metab.* 86 (2001) 5210–5216.
- [4] G.A. Kaltsas, G.M. Besser, A.B. Grossman, The diagnosis and medical management of advanced neuroendocrine tumors, *Endocr. Rev.* 25 (2004) 458–511.
- [5] F. Crozier, E. Lechevallier, C. Eghazarian, M. André, D. Sammama, P. Wilshire, V. Vidal, P. Pascal, J.M. Bartoli, Retroperitoneal nonsecreting paraganglioma, *J. Radiol.* 80 (1999) 150–152.
- [6] L. Louafy, A. Lakhouloufi, R. Hamddaoui, F. Chehab, D. Khaiz, A. Bouzidi, Non-functional retroperitoneal paraganglioma, *Prog. Urol.* 11 (2001) 512–516.
- [7] K.Y. Lee, Y.W. Oh, H.J. Noh, Y.J. Lee, H.S. Yong, E.Y. Kang, K.A. Kim, N.J. Lee, Extraadrenal paragangliomas of the body: imaging features, *AJR Am. J. Roentgenol.* 187 (2) (2006 August) 492–504.
- [8] G. Sangster, D. Do, C. Prevgliano, B. Li, D. LaFrance, M. Heldmann, Primary retroperitoneal paraganglioma simulating a pancreatic mass: a case report and review of the literature, *HPB Surg.* 2010 (2010) 645728.
- [9] K.F. Andersen, R. Altaf, A. Krarup-Hansen, B. Kromann-Andersen, T. Horn, N.J. Christensen, H.W. Hendel, Malignant pheochromocytomas and paragangliomas—the importance of a multidisciplinary approach, *Cancer Treat. Rev.* 37 (April (2)) (2011) 111–119.
- [10] M. Griesshammer, M. Bangerter, T. Sauer, R. Wennauer, L. Bergmann, H. Heimpel, Aetiology and clinical significance of thrombocytosis: analysis of 732 patients with an elevated platelet count, *J. Intern. Med.* 245 (3) (1999) 295–300.
- [11] D.H. Buss, A.W. Cashell, M.L. O'Connor, F. Richards 2nd, Case LD, Occurrence, etiology, and clinical significance of extreme thrombocytosis: a study of 280 cases, *Am. J. Med.* 96 (3) (1994) 247–253.
- [12] Wintrobe's Clinical Hematology, in: J.P. Greer, J. Foerster, J.N. Lukens, G.M. Rodgers, F. Paraskevas, B. Glader (Eds.), 11th ed., Lippincott Williams & Wilkins, Philadelphia, 1981, pp. 1128–1134.
- [13] A. Tefferi, H.C. Hoagland, Issues in the diagnosis and management of essential thrombocythemia, *Mayo Clin. Proc.* 69 (7) (1994) 651–655.
- [14] P.N. Khan, R.J. Nair, J. Olivares, L.E. Tingle, Z. Li, Postsplenectomy reactive thrombocytosis, *Proc. (Bayl. Univ. Med. Cent.)* 22 (January (1)) (2009) 9–12.
- [15] U. Shah, A. Giubellino, Pacak K. Pheochromocytoma, implications in tumorigenesis and the actual management, *Minerva Endocrinol.* 37 (June (2)) (2012) 141–156.

#### Open Access

This article is published Open Access at [sciendoirect.com](http://sciendoirect.com). It is distributed under the [IJSCR Supplemental terms and conditions](#), which permits unrestricted non commercial use, distribution, and reproduction in any medium, provided the original authors and source are credited.