

IMAGES IN INTERVENTION

“DVT” of the Heart

A “Novel” Treatment for an Old Problem



Naga Venkata Pothineni, MD, Amit Bahia, MD, Freij Gopal, MD, Zubair Ahmed, MD, Barry F. Uretsky, MD, Abdul Hakeem, MD

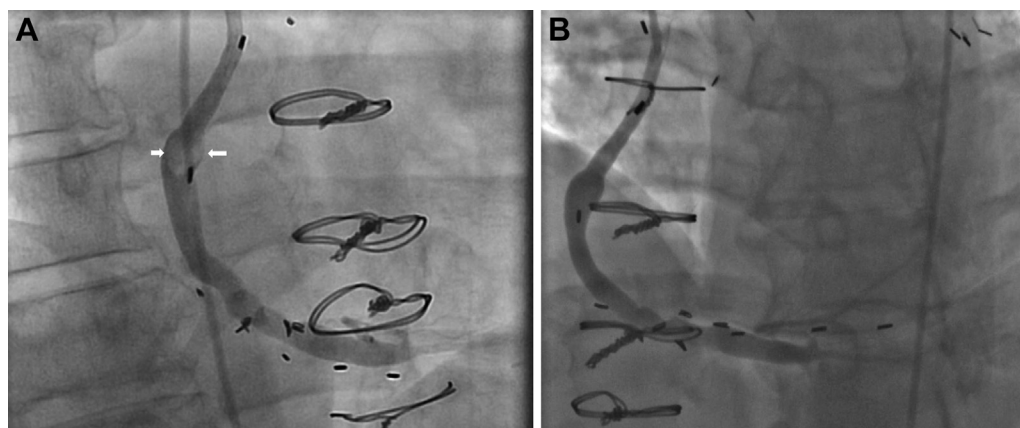
Thrombotic lesions of saphenous venous grafts (SVGs) are frequently encountered, and interventions may be technically fraught with embolic complications. The following 2 cases suggest the potential role in selected cases of novel oral anticoagulants (NOACs) in the treatment of SVG thrombosis to obviate the need for percutaneous intervention (PCI):

- *Case 1:* A 62-year-old man with 4-vessel coronary artery bypass graft surgery performed 9 years earlier presented with a non-ST-segment elevation myocardial infarction. Angiography showed the SVG to

right posterior descending artery to have a large thrombus in its midsegment with Thrombolysis In Myocardial Infarction flow grade 3, but it was otherwise without significant graft disease (**Figure 1A**). All other grafts were patent. The patient was treated with low-molecular-weight heparin for 1 week, followed by dabigatran etexilate 150 mg twice a day for 1 week. Repeat angiography after 2 weeks showed complete thrombus resolution (**Figure 1B**).

- *Case 2:* A 67-year-old woman with 3-vessel coronary artery bypass graft surgery 5 years earlier presented with unstable angina. Angiography showed subtotal

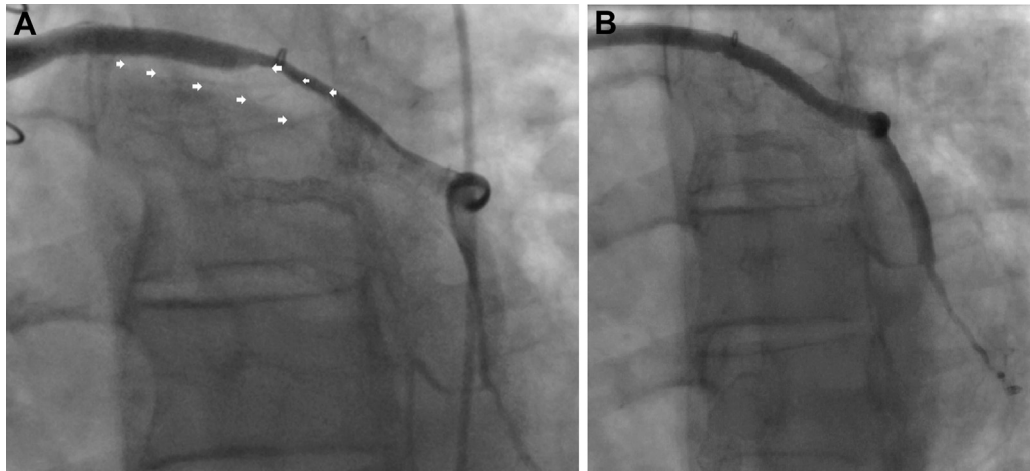
FIGURE 1 Right Anterior Oblique Projections of Case 1



(A) Right anterior oblique projection showing a thrombus (**arrows**) in the midportion of the saphenous venous graft (SVG). **(B)** Right anterior oblique projection with resolution of SVG thrombus and widely patent SVG.

From the Division of Cardiology, University of Arkansas for Medical Sciences, Little Rock, Arkansas. The authors have reported that they have no relationships relevant to the contents of this paper to disclose.

Manuscript received February 26, 2015; accepted March 12, 2015.

FIGURE 2 Anteroposterior Projections of Case 2

(A) Anteroposterior projection with a large layered thrombus (arrows) in a saphenous venous graft (SVG). (B) Anteroposterior projection with resolution of thrombus and patent SVG.

occlusion of the SVG to an obtuse marginal branch with a large layered thrombus and minimal atherosclerotic obstruction elsewhere in the graft (Figure 2A). All other grafts were patent. The patient was initiated on rivaroxaban 20 mg daily. Angiography 4 weeks later revealed thrombus resolution and normalization of coronary flow (Figure 2B).

Acute SVG thrombosis frequently presents as acute coronary syndrome (ACS). PCI has traditionally been the treatment of choice for abrupt SVG thrombotic occlusions. It carries the risk of distal embolization, no reflow, and periprocedural myocardial infarction. Among pharmacological alternatives for acute SVG thrombosis, glycoprotein IIb/IIIa antagonists (1) and warfarin (2) have been successfully used as pre-PCI thrombus reduction strategies. We report the use of NOACs as “destination therapy” without the need for PCI for acute SVG thrombosis in the

setting of ACS. It is unclear if the thrombus resolution was spontaneous with time or secondary to NOACs. We are also uncertain about the success rate and patient selection for this approach. Factors that might influence success rate include thrombus burden, age of the graft, and presence or absence of graft degeneration. In summary, we report the first use of NOACs for the treatment of acute SVG thrombosis in the setting of ACS. This noninvasive approach may be safe and effective in selected patients who have focal nonflow limiting thrombotic SVG occlusions in the absence of significant angiographic graft disease.

REPRINT REQUESTS AND CORRESPONDENCE: Dr. Naga Venkata Pothineni, 4301 West Markham Street, #532, Little Rock, Arkansas 72205. E-mail: nvpothineni@uams.edu.

REFERENCES

1. Senturk T, Aydin Kaderli A, Aydin O, Yesilbursa D, Akin Serdar O. Successful treatment of saphenous venous graft thrombus by tirofiban infusion. *Heart Lung* 2010;39:237-9.
2. Chow WH, Hon PH. Successful stenting after Coumadin therapy and thrombus resolution in a stenotic saphenous vein graft. *Cathet Cardiovasc Diagn* 1996;39:438-9.

KEY WORDS apixaban, dabigatran, rivaroxaban, saphenous venous graft thrombosis