

## Heterotopic Pregnancy Following Reversal of Tubal Ligation

Stephanie Eschenbach, M.D., Dirk Entzian, M.D., and Deborah A. Baumgarten, M.D.

We describe the case of a 37-year-old woman who had undergone reversal of tubal ligation with subsequent heterotopic pregnancy. We review the initial radiological evaluation of heterotopic pregnancies and the subsequent radiologic findings following appropriate therapy.

### Introduction

Heterotopic pregnancy is a relatively rare event—the simultaneous occurrence of two or more implantations sites. Most often seen, is an intrauterine pregnancy with a concomitant ectopic pregnancy [1]. Described historically as only occurring in 3 per 100,000 pregnancies [2], more recent estimates describe an occurrence of up to 1.25 per 10,000 pregnancies within the general population [3]. There are several risk factors which increase the incidence of heterotopic pregnancy above that of the general population. These risk factors include increased use of assisted reproductive technologies, prevalent use of IUDs, increased number of tubal surgeries, pharmacologic ovulation stimulation and increased incidence of pelvic inflammatory disease. With these risk factors, and

especially with the use of assisted reproductive technologies, the occurrence can jump up to 1 in 100 pregnancies [4].

### Case Report

A 37-year-old gravida 4 para 3-0-1-3 female presented to our hospital in June 2007 with pain and spotting with a known history of pregnancy. A transvaginal ultrasound was performed, which demonstrated a 6-week and 3-day intrauterine gestation with positive fetal cardiac activity (Figures 1A-B). Additionally, a right adnexal mass was identified, which contained a hypoechoic component characteristic of a gestational sac. Within the gestational sac, a small yolk sac and fetal pole were identified, corresponding to a 6-week and 0-day gestation (Figure 1C). This gestation also displayed positive fetal cardiac activity (Figure 1D).

The patient's past medical history was significant for three prior cesarean sections and prior bilateral tubal ligation. The patient had no prior IUD use, no prior ectopic pregnancy, no history of assisted reproduction and no history of pelvic inflammatory disease. A hysterosalpingogram performed in January 2006, demonstrated lack of tubal patency (Figure 2A).

---

Citation: Eschenbach S, Entzian D, Baumgarten DA. Heterotopic pregnancy following reversal of tubal ligation. *Radiology Case Reports*. [Online] 2008;3:191.

Copyright: © 2008 The Authors. This is an open-access article distributed under the terms of the Creative Commons Attribution-NonCommercial-NoDerivs 2.5 License, which permits reproduction and distribution, provided the original work is properly cited. Commercial use and derivative works are not permitted.

Abbreviations: BPM, beats per minutes; CRL, crown-rump length; HCG, human chorionic gonadotropin; IUD, intrauterine device; MRI, magnetic resonance imaging

Stephanie Eschenbach, M.D. (Email: stephanieeschenbach@yahoo.com), Dirk Entzian, M.D., and Deborah A. Baumgarten, M.D., are in the Department of Radiology, Emory University, Atlanta, GA, USA.

Published: June 11, 2008

DOI: 10.2484/rcr.v3i2.191

## Heterotopic Pregnancy Following Reversal of Tubal Ligation

In April 2006, the patient had undergone reversal of her tubal ligation with right tubo-ovarian anastomosis, lysis of adhesions and myomectomy. A left tubo-ovarian anastomosis was not attempted secondary to dense adhesions in the left adnexa. Intraoperative methylene blue test demonstrated successful reanastomosis on the right. Hysterosalpingogram performed in January, 2007

confirmed tubal patency on the right, with no tubal patency on the left (Figure 2B).

The patient was given the diagnosis of early intrauterine pregnancy and right tubal pregnancy and was admitted to the hospital. Following admission, the patient underwent an exploratory laparotomy, right partial salpingectomy and lysis of adhesions. During surgery,

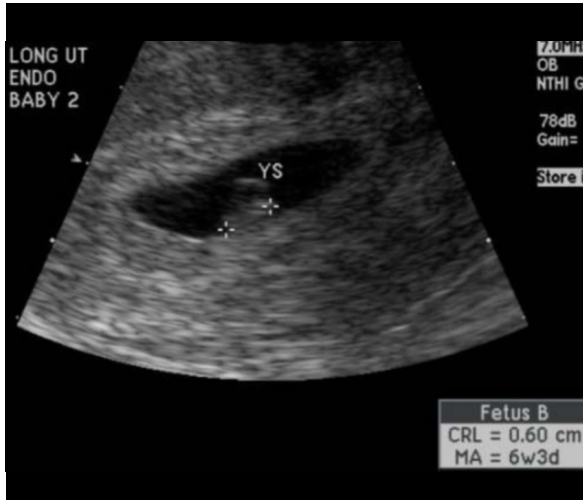


Figure 1A. 37-year-old woman with heterotopic pregnancy. At presentation, transvaginal ultrasound of the uterus showing an intrauterine gestation with a crown-rump length (CRL) of 6 mm corresponding to a 6 week 3 day gestation.

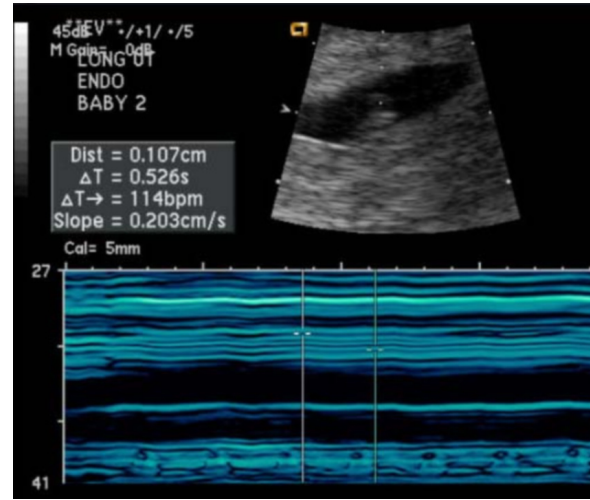


Figure 1B. Transvaginal ultrasound showing cardiac activity at 114 beats per minute (BPM) in the intrauterine pregnancy.

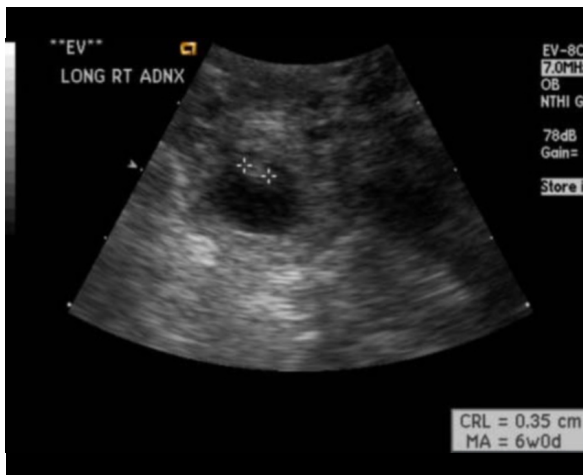

Figure 1C. Transvaginal ultrasound of the right adnexa showing an ectopic pregnancy with a CRL of 3.5 mm corresponding to a gestational age of 6 weeks 0 days.

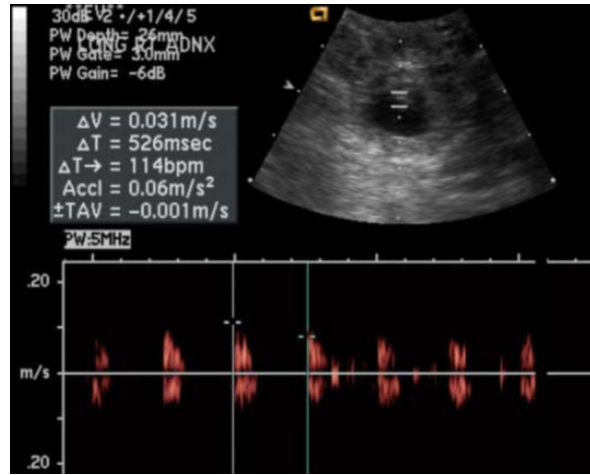


Figure 1D. Transvaginal ultrasound showing cardiac activity at 114 BPM in the ectopic pregnancy.

## Heterotopic Pregnancy Following Reversal of Tubal Ligation

the mid-portion of the right fallopian tube demonstrated a 2 x 2.5 cm mass, consistent with a non-ruptured ectopic pregnancy. This mass was excised and sent to pathology for further evaluation. The final pathology report described a 1.2 cm gestational sac, which contained a 0.3 cm embryo, confirming the initial sonographic diagnosis.

Three days following the removal of the right ectopic pregnancy, a repeat pelvic ultrasound was performed. The intrauterine pregnancy was again identified, with a crown-rump length corresponding to a gestational age of 6 weeks and 5 days (Figure 3A). There was positive fetal cardiac activity (Figure 3B). Evaluation of the right adnexa revealed a small amount of free fluid, with absence of the previously seen right adnexal mass, which was concordant with the known surgical history. Both ovaries demonstrated rounded, thick walled cysts with peripheral blood flow consistent with corpus luteum of pregnancy (Figures 3C-D).

An additional follow up pelvic ultrasound 12 days later showed progression of the intrauterine pregnancy, with a gestational age of 8 weeks and 3 days (Figure 4A). Normal fetal heart tones were documented (Figure 4B). Again, no adnexal masses were seen.

The patient then returned to the care of her outside physician until it was time for delivery. The patient returned to our hospital approximately 29 weeks after the

last pelvic ultrasound. At that time, the patient underwent a scheduled repeat cesarean section. A viable 2760 g infant was delivered, with Apgars of 8 at 1 minute and 9 at 5 minutes.

### Discussion

The frequency of heterotopic pregnancy is quite low for the general population, with a conservative estimate of 1.25 per 10,000 pregnancies [3]. The occurrence of heterotopic pregnancy increases with various risk factors, for example, assisted reproduction up to 1 in 100 pregnancies [4]. The various risk factors include not only assisted reproduction, but also prior tubal surgery, as was the case with our patient, IUD use, pharmacologic ovarian stimulation, prior ectopic pregnancy and a history of pelvic inflammatory disease.

Diagnosis of heterotopic pregnancy can be difficult and is not as straightforward as the diagnosis of an ectopic pregnancy. Ectopic pregnancies can present with vaginal bleeding, palpable adnexal mass and abdominal tenderness. Only 50% of patients with an ectopic pregnancy will present with the classic triad of pain, amenorrhea and vaginal bleeding. Ectopic pregnancies typically have a lower beta HCG level than intrauterine pregnancies, and can be diagnosed with ultrasound [5].

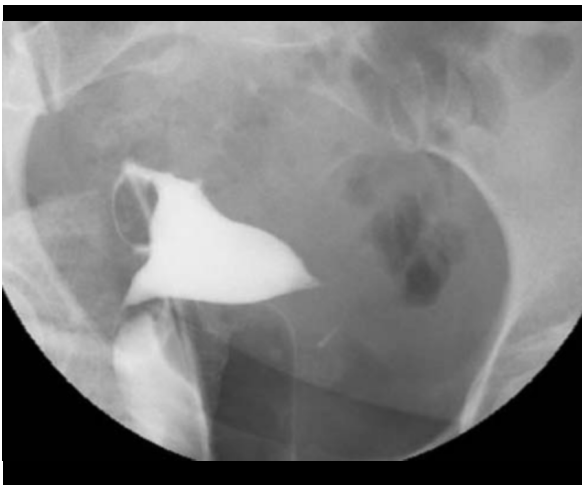

Figure 2A. Hysterosalpingogram performed 18 months earlier, following tubal ligation, demonstrated no tubal patency on either side.

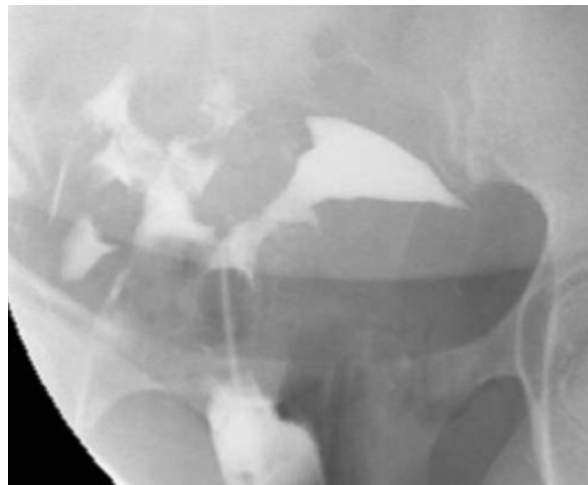

Figure 2B. Hysterosalpingogram performed 6 months earlier, following reversal of right tubal ligation, demonstrated right-sided tubal patency.

## Heterotopic Pregnancy Following Reversal of Tubal Ligation

What makes the diagnosis of heterotopic pregnancy tricky is that the beta HCG, although positive, is typically in the expected range and an intrauterine pregnancy will be seen on ultrasound, which will explain the lab values. The index of suspicion will be raised for an ectopic pregnancy if the beta HCG level is positive and no intrauterine pregnancy is seen, however if an intra-

uterine pregnancy is seen, the index of suspicion will go down [6]. It is of the utmost importance to recognize a simultaneous ectopic pregnancy with an intrauterine pregnancy. According to a study by Habana et al, cornual heterotopic pregnancy can have an incidence of rupture in up to 48.6% of cases, which can lead to catastrophic bleeding and sometimes necessitate hyster-

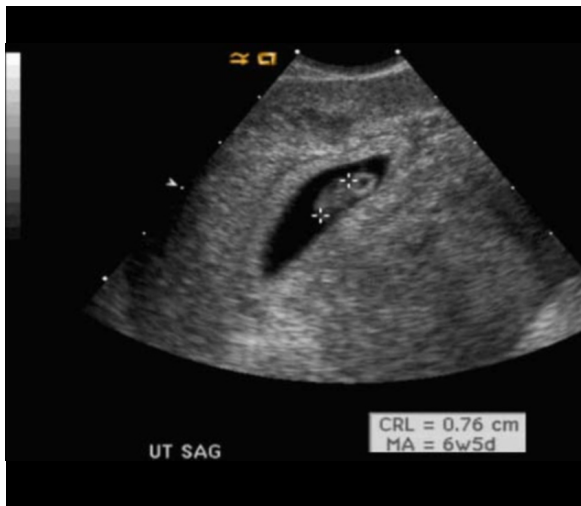


Figure 3A. Follow up to surgical excision of the right tubal pregnancy. Transvaginal ultrasound showed interval growth of the intrauterine gestation, now measuring 7.6 mm and corresponding to a 6 week 5 day gestation.

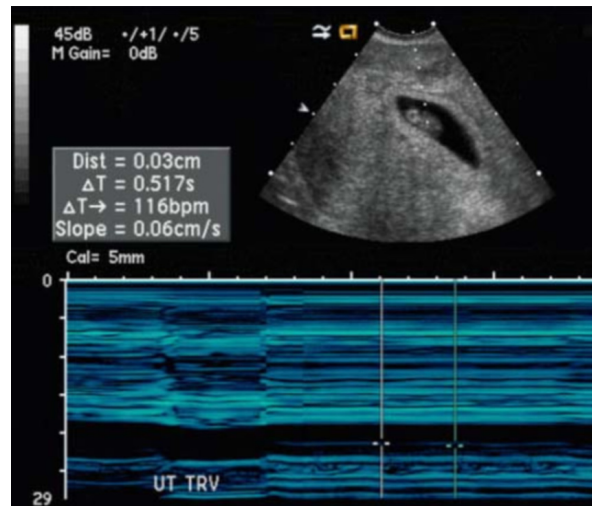


Figure 3B. Transvaginal ultrasound documenting cardiac activity (116 BPM) in the intrauterine gestation following selective removal of the ectopic gestation.

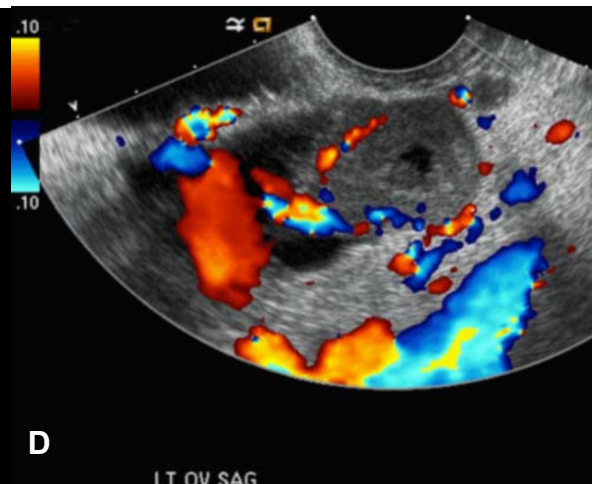
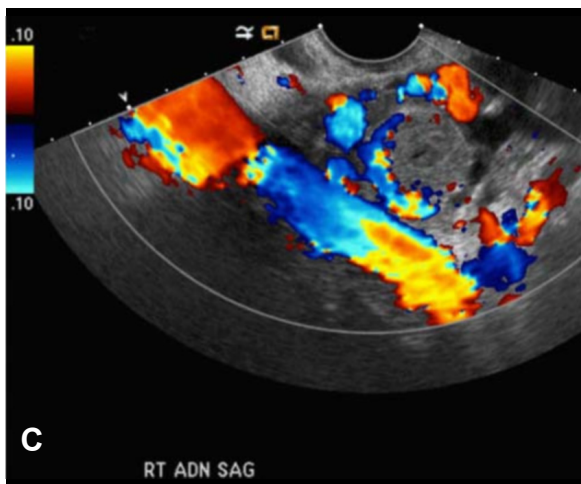


Figure 3C-D. Color Doppler transvaginal imaging through the right ovary demonstrates a thick-walled cyst with peripheral flow consistent with a corpus luteum.

## Heterotopic Pregnancy Following Reversal of Tubal Ligation

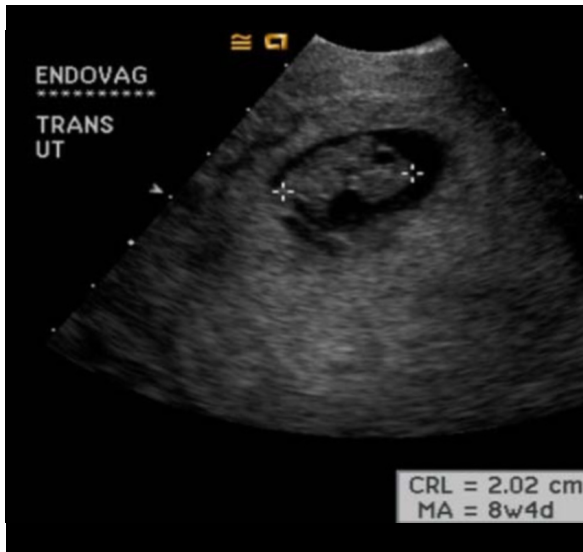


Figure 4A. Follow-up to surgical excision of the right tubal pregnancy. Follow-up transvaginal ultrasound demonstrates continued appropriate growth of the intrauterine gestation now measuring 2 cm corresponding to a gestational age of 8 weeks 4 days.

ectomy [7]. Fortunately, modern imaging techniques, such as pelvic ultrasound and pelvic MRI can greatly aid in the diagnosis of heterotopic pregnancy.

The extrauterine pregnancy in cases heterotopic pregnancy has the same appearance as an isolated ectopic pregnancy. On ultrasound this includes an adnexal mass, live extrauterine embryo, free fluid (particularly hemorrhagic) in the pelvis or peritoneum, hematosalpinx and an adnexal “ring-of-fire” sign on color Doppler images [8]. This latter finding should not be confused with the corpus luteum of pregnancy which can also show peripheral flow with color Doppler imaging.

There are several different management options for heterotopic pregnancy. One option includes selective surgical removal of the ectopic pregnancy, which overall, seems to have the best live birth rate. Another option is medical management, which include therapies with prostaglandin and methotrexate. Prostaglandin therapy is undesirable for the intrauterine pregnancy due to its effect on uterine contractility. Methotrexate is undesirable due to its adverse effects on the developing fetus within the uterus. Advantages to medical treatment in-

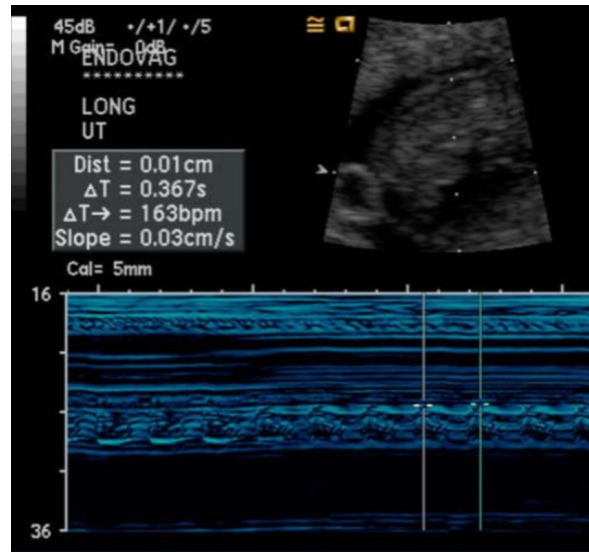


Figure 4B. Follow-up transvaginal ultrasound demonstrates fetal cardiac activity at 163 BPM.

cluded preservation of the integrity of the uterus, therefore allowing future vaginal delivery, and the avoidance of anesthesia and surgery [7]. Fernandez et al reports one case of expectant management in a heterotopic pregnancy, however this case was unique in the fact that the cornual gestation had expired, as documented by ultrasound. There was resolution of the cornual gestation and the intrauterine pregnancy was carried to term [9]. In our case, successful selective removal of the adnexal pregnancy allowed a normal term delivery of the intrauterine gestation.

### References

1. Somers MP, Spears M, Maynard AS, Syverud SA. Ruptured heterotopic pregnancy presenting with relative bradycardia in a woman not receiving reproductive assistance. *Ann Emerg Med* 2004 Mar;43(3):382-5. [PubMed]
2. DeVoe RW, Pratt JH. Simultaneous intrauterine and extrauterine pregnancy. *Am J Obst Gynecol* 56: 1119, 1948.

## Heterotopic Pregnancy Following Reversal of Tubal Ligation

3. Bello GV, Schonolz D, Moshirpur J, Jeng DY, Berkowitz RL: Combined pregnancy: the Mount Sinai experience. *Obstet Gynecol Surv* 1986 Oct;41(10):603-13. [PubMed]
4. Goldman GA, Fisch B, Ovadia J, Tadir Y. Heterotopic pregnancy after assisted reproductive technologies. *Obstet Gynecol Surv* 1992 Apr;47(4):217-221. [PubMed]
5. Sepilian, VP, Wood E. Ectopic Pregnancy. In *Gynecology and Obstetrics* www.eMedicine.com [Last accessed on 5.26.2008].
6. Harrington JC, Lyons EA. Heterotopic pregnancy. www.TheFetus.net [Last accessed 5.26.2008].
7. Habana A, Anuja D, Giraldo JL, Jones EE. Cornual heterotopic pregnancy: contemporary management options. *Am J Obst Gynecol* 2000 May;182(5):1264-1270. [PubMed]
8. Bourgon D, Outwater E. Ectopic Pregnancy. In *Radiology* www.eMedicine.com [Last accessed on 5.26.2008].
9. Fernandez H, Lelaidier C, Doumerc S, Fournet P, Olivennes F, Frydman R: Nonsurgical treatment of heterotopic pregnancy: a report of six cases. *Fertil Steril* 1993 Sep;60(3):428-432. [PubMed]