



The Egyptian German Society for Zoology
The Journal of Basic & Applied Zoology

www.egsz.org
www.sciencedirect.com



Ameliorative effect of the sea cucumber *Holothuria arenicola* extract against gastric ulcer in rats



Sohair R. Fahmy ^{*}, Mahmoud A. Amer, Mohannad H. Al-killidar

Zoology Department, Faculty of Science, Cairo University, Giza 12613, Egypt

Received 15 September 2014; revised 22 February 2015; accepted 8 March 2015

Available online 11 April 2015

KEYWORDS

Holothuria arenicola;
 Gastric ulcer;
 Indomethacin;
 Cold stress;
 Oxidative stress

Abstract *Holothuria arenicola* is the most important and abundant sea cucumber species in the Mediterranean Sea on the Egyptian coast. This work aimed to investigate the prophylactic and the curative effects of *H. arenicola* extract HaE (200 mg/kg) on gastric mucosal damage following indomethacin and cold stress in healthy rats. Sixty-four rats were randomly divided into four main groups. Rats of the first group (8 rats/group) were administered distilled water orally (control group), rats of the second group (8 rats/group) were administered single oral dose of indomethacin (150 mg/kg) and exposed to cold stress ($4 \pm 1^\circ\text{C}$) for 30 min to induce gastric ulcer (GU) model (ulcer group), rats of the third group, prophylactic group (24 rats/group) were treated with HaE and/or ranitidine (RAN) and then exposed to GU and rats of the fourth group, curative group (24 rats/group) were exposed firstly to GU and then treated with HaE and/or RAN. The results clearly indicate that pre-treatment with HaE and/or ranitidine significantly decreases the ulcer index, showing 72.50%, 53.11% and 80.56% ulceration inhibition, respectively. However, post-treatment with HaE and/or ranitidine significantly decreases the ulcer index, showing 51.66%, 62.41% and 67.78% ulceration inhibition, respectively. The results also showed that pre and post-treatment with HaE and/or RAN significantly decreased gastric malondialdehyde (MDA) level and enhanced reduced glutathione (GSH), catalase (CAT), glutathione-S-transferase (GST) and superoxide dismutase (SOD) levels. The results clearly indicate that pre-treatment with HaE is preferable.

© 2015 The Egyptian German Society for Zoology. Production and hosting by Elsevier B.V. This is an open access article under the CC BY-NC-ND license (<http://creativecommons.org/licenses/by-nc-nd/4.0/>).

Introduction

Gastric ulcer disease (GUD) is a common problem of the gastro-intestinal tract with increasing incidence and prevalence attributed to loss of balance between aggressive and protective

factors. Gastric ulcer develops because of several endogenous aggressive factors, including hydrochloric acid, pepsin, refluxed bile, leukotrienes and reactive oxygen species (ROS), and several exogenous factors including non-steroidal anti-inflammatory drugs (NSAIDs), stress, alcohol and *Helicobacter pylori* infection are major causative agents for gastric mucosal damage and ulceration (Rang et al., 2003; Nartey et al., 2012). NSAIDs including indomethacin are effective in the treatment of a variety of acute and chronic pain conditions. Their use has been associated with gastric mucosal damage as a side effect

^{*} Corresponding author. Tel.: +20 01149939166.

E-mail address: sohairfahmy@gmail.com (S.R. Fahmy).

Peer review under responsibility of The Egyptian German Society for Zoology.

<http://dx.doi.org/10.1016/j.jobaz.2015.03.001>

2090-9896 © 2015 The Egyptian German Society for Zoology. Production and hosting by Elsevier B.V.

This is an open access article under the CC BY-NC-ND license (<http://creativecommons.org/licenses/by-nc-nd/4.0/>).

(Fukushima et al., 2014). Indomethacin is a synthetic NSAIDs that is known to induce severe gastric mucosal lesions (Abbas and Sakr, 2013). It is a potent inhibitor of prostaglandins' synthesis, which are important mediators of the inflammatory response (Robbin et al., 2009).

In rats, indomethacin, has been shown to cause significant gastrointestinal damage (Takeuchi et al., 2002) and oxidative stress (Okayama et al., 2009).

Oxidative stress, which is a state of unbalanced levels of reactive oxygen species (ROS), causes a variety of conditions that stimulate either additional ROS production or a decline in antioxidant defenses. Reactive oxygen species (ROS) and free radicals play an important role in the pathogenesis of several human diseases, including GUD (Gulcin, 2012; Mei et al., 2013). Indomethacin, a well-known NSAID, induces erosions and lesions in gastroduodenal tract through multifaceted processes, such as inhibition of cyclooxygenase (COX)-mediated prostaglandin synthesis, over expression of interleukin-1 (IL-1), polymorphonuclear leukocyte infiltration of generation of ROS and induction of apoptosis (Ansari and Lal, 2009). Several phenotypes of gastrointestinal diseases, such as peptic ulcer disease and gastroparesis, are known to be related to antioxidant property dysfunction (Suzuki et al., 2012). Stress has become an integral part of human life and organisms are constantly subjected to stressful stimuli that affect numerous physiological processes. It has been demonstrated that restraint and cold (4 °C), as well as indomethacin (Kleiman-Wexler et al., 1989), can induce ulceration.

Many synthetic compounds such as ranitidine and omeprazole, which block acid secretion, are now used as antiulcer drugs. Since synthetic drugs are often encountered with some adverse effects, treatment with natural products is now considered as an alternative approach to control the disease. Natural products have long been recognized as a rich source of potent therapeutics, but further development is often limited by high structural complexity and high molecular weight (Ononye et al., 2013). Sea cucumbers are marine invertebrates of the phylum of Echinodermata, sometimes referred to as marine ginseng, produce numerous compounds with diverse functions and are potential sources of active ingredients for agricultural, nutraceutical and pharmaceutical products (Bahrami et al., 2014). They are also remarkably rich in vitamins, trace elements, and polysaccharides (chondroitin sulfate), which reduce arthritis pain and inhibit viral activities, and saponin glycosides that inhibit cancer activities (Hamel and Mercier, 2004). *Holothuria arenicola* is the most important and abundant sea cucumber species in the Mediterranean Sea on the Egyptian coast (Kilada et al., 2000). In addition to their flavor, sea cucumbers are commonly used to treat wounds, eczema, arthritis, hypertension, and impotence (Sugawara et al., 2006; Ridzwan, 2007; Subramaniam et al., 2013). Gastric ulcer is essentially a deep wound in the stomach wall that involves epithelium, endothelium, connective tissue, and smooth muscle. Therefore, healing of a gastric ulcer means a restoration of those tissues that have been damaged during ulceration. So, the present study aims to assess the prophylactic and the curative effect of the sea Cucumbers *H. arenicola* extract (HaE) in comparison with ranitidine in a model of indomethacin and cold stress-induced gastric ulcer in male albino rats and to investigate its underlying anti-oxidative mechanisms. The

present study also conducts to assess the employment of (HaE) as alternative or complementary to the established antiulcer drug ranitidine.

Materials and methods

Chemicals and reagents

Indomethacin was obtained from Sigma Chemical Co. (St. Louis, MO, USA). 2,2-diphenyl-1-picrylhydrazyl (DPPH). Ranitidine (50 mg/kg) was obtained from Hamdoun Pharmacy (Mohamed Roshdi St, Agoza, Egypt). Kits for all biochemical parameters and other chemicals and reagents were purchased from the Biodiagnostic Company (El Moror St, Dokki, Egypt).

H. arenicola sample collection

Samples were collected from the Abu-Qir Bay in the Egyptian Mediterranean coast of the eastern Alexandrian coast (May–June 2012). Samples were gently cleaned and washed to remove sediment and other small organisms attached to their bodies.

Samples were maintained in stock tank filled with filtered seawater at ambient temperature. The samples were packed immediately with ice prior to sending to the lab and kept at –80 °C until extracted.

Preparation of the *H. arenicola* extract (HaE)

The phosphate buffer extract was prepared according to the method of Yasumoto et al. (1967).

After being sliced open and its internal organs removed, the body wall of the sea cucumber *H. arenicola* was blended in phosphate buffer (in a volume = 4 × tissue weight) and extracted at room- temperature (25 °C) with pH 7.2 for 5 h. The filtered was collected immediately, concentrated and lyophilized using LABCONCO lyophilizer, shell freeze system, USA.

Free radical scavenging activity

The free radical scavenging activities of the extract and ascorbic acid were analyzed by the DPPH assay (Sanchez-Moreno et al., 1998). A 1.0 ml of the test extract, at gradient final concentrations of 10–80 mg/ml, was mixed with 2 ml of 0.3 mM DPPH solution in MeOH in a cuvette. The absorbance was taken at 517 nm after 20 min of incubation in the dark at room temperature. The experiment was done in triplicates. The percentage antioxidant activity was calculated as follows:

%Antioxidant Activity [AA] = $100 - \left[\frac{(\text{Abs}_{\text{sample}} - \text{Abs}_{\text{blank}}) \times 100}{\text{Abs}_{\text{control}}} \right]$. Where $\text{Abs}_{\text{sample}}$ was the absorbance of sample solution (2.0 ml) + DPPH solution (1.0 ml, 0.3 mM), $\text{Abs}_{\text{blank}}$ was the absorbance of Methanol (1.0 ml) + sample solution (2.0 ml), $\text{Abs}_{\text{control}}$ was the absorbance of DPPH solution (1.0 ml, 0.3 mM) + methanol (2.0 ml).

Ethical consideration

Experimental protocols and procedures used in this study were approved by the Cairo University, Faculty of Science Institutional Animal Care and Use Committee (IACUC) (Egypt), (CUFS/F/01/13). All the experimental procedures were carried out in accordance with international guidelines for the care and use of laboratory animals.

Experimental animals

Male albino Wistar rats (*Rattus norvegicus*) weighing 120–130 g were purchased from the animal house of National Research Center, Cairo, Egypt. The animals were housed in polypropylene cages (five animals per cage) for 72 h before commencement of the experiments for acclimatization, at controlled condition of temperature 18 °C with a 12-h light: 12-h dark cycle. Rats were fed standard diet and tap water *ad libitum*.

Toxicity study (OECD 420)

Wistar rats weighing 150–160 g were used for acute toxicity study. The animals (12 rats) were divided into control and test groups containing six animals each. The rats were administered orally with sea cucumbers *H. arenicola* extract (HaE) at dose levels of 5 g/kg (high dose) and 2 g/kg (low dose). Normal control rats received the same amount of vehicle (distilled water) only. Animals were observed carefully for 24 h after extract administration and then for the next 14 days. At the end of this experimental period, the rats were observed for signs of toxicity, morphological behavior, and mortality. Acute toxicity was evaluated based on the number of deaths (if any). Acute toxicity was calculated as OECD guidelines 420 (Fixed dose method) (Vanden Heuvel et al., 1990; Whitehead and Curnow, 1992).

Induction of severe gastric ulcers

The ulcer was induced by a combination of indomethacin and cold stress (severe gastric ulcer, SGU) model (Arai et al., 1987). Indomethacin was administered as a single oral dose (150 mg/kg) (Thong-Ngam et al., 2012) and the cold stress was 4 ± 1 °C for 30 min (Retana-Márquez et al., 2003).

Experimental protocol

Before the experiment, rats were deprived of food, but not water, for 20–24 h. In this experiment the animals (64 rats) were divided into four main groups. Rats of the first group (8 rats/group) were administered distilled water orally (control group). The rats of the second group (8 rats/group) were exposed to severe gastric ulcer (SGU) model (ulcer group). Rats of the third group (24 rats/group) were used to study the prophylactic effect of HaE and/or ranitidine (RAN) and rats of the fourth group (24 rats/group) were used to study the curative effect of HaE and/or ranitidine (RAN).

Prophylactic effect of *H. arenicola* extract (HaE)

Rats of the prophylactic group were assigned randomly into three subgroups (8 rats/subgroup). Rats of the first subgroup

were treated orally with HaE (200 mg/kg b.wt. ED50), rats of the second subgroup treated with ranitidine (50 mg/kg b.wt.) and rats of the third subgroup treated with HaE (200 mg/kg) and ranitidine (50 mg/kg). All groups were treated for 1 h and then exposed to severe gastric ulcer (SGU) model.

Curative effect of *H. arenicola* extract (HaE)

In the curative treatments, rats were exposed firstly to severe gastric ulcer (SGU) model and then divided randomly into three main subgroups. Rats of the first subgroup were treated orally with HaE (200 mg/kg b.wt.), rats of the second subgroup treated with ranitidine (50 mg/kg b.wt.) and rats of the third subgroup treated with HaE (200 mg/kg) & ranitidine (50 mg/kg).

Animal handling

At the end of the experimental period, animals were euthanized after being fasted overnight under deep anesthesia with sodium pentobarbital. Stomachs were removed and immediately blotted using filter paper to remove traces of blood. Immediately after the animals were sacrificed their stomachs were dissected out, incised along the greater curvature and the gastric juice was collected. Mucosa was rinsed with cold normal saline to remove blood contaminant if any. The hemorrhagic and ulcerative lesions were counted and measured under a light microscope by two colleagues who were blinded to the treatment. The stomach of rats was stored at –80 °C for biochemical analysis.

Macroscopic evaluation of stomach

The stomach's ulcerative lesions were examined by a 10× magnifier lens to assess the formation of ulcers. The numbers of ulcers were counted. Scoring of ulcer will be made as follows:

Normal colored stomach	(0)
Red coloration	(0.5)
Spot ulcer	(1)
Hemorrhagic streak	(1.5)
Deep ulcers	(2)
Perforation	(3)

Mean ulcer score for each animal will be expressed as ulcer index. The percentage of ulcer protection was determined as follows:

The percentage of inhibition (%) was calculated by the following formula:

$$\% \text{ inhibition} = \frac{\text{UA control} - \text{UA treated}}{\text{UA control}} \times 100$$

Analysis of gastric juice

Gastric juice collected from each animal was centrifuged at 3000 rpm for 10 min to remove any solid debris and the volume of the supernatant was measured.

Determination of gastric acidity

Gastric juice samples were back titrated against 0.01 mol/L NaOH using phenolphthalein indicator (1% in absolute ethanol) to the faint pink colored end point. The total acidity was expressed as milliequivalents using the following equation:

$$\text{Total acidity (mEq/L)} = \text{mLsNaOH/liter juice} \times 50.$$

Tissue homogenate preparation

Stomach tissue was homogenized (10% w/v) in ice cold 0.1 M phosphate buffer (pH 7.4). The homogenate was centrifuged at 3000 rpm for 15 min at 4 °C and the supernatant was used for the estimation of oxidative stress parameters.

Assessment of oxidative stress markers

Oxidative stress markers were detected in the resultant supernatant of stomach homogenate. The appropriate kits (Biodiagnostic kits, Biodiagnostic Dokki, Giza, Egypt) was used for the determination of malondialdehyde (MDA) (Ohkawa et al., 1979), glutathione reduced (GSH) (Aykac et al., 1985), catalase (CAT) was detected according to method described by Aebi (1984), glutathione-S-Transferase (GST) (Habig et al., 1974) and superoxide dismutase (SOD) (Nishikimi et al., 1972).

Statistical analysis

All results were expressed as mean \pm standard error (SE) of eight animals in each group. All data obtained were analyzed by ANOVA followed by Duncan test at 95% confidence level. Values of $P < 0.05$ were considered as statistically significant. All computations were performed using SPSS version 20.0 software.

Results

Free radical scavenging activity

The results of DPPH scavenging activity of HaE and ascorbic acid are shown in Table 1. The radical scavenging activities were estimated by comparing the percentage of inhibition of DPPH radical by the tested extract and the ascorbic acid. The data were displayed with mean \pm SEM of three replications. The present results showed that HaE produced dose dependent inhibition of DPPH radical ranging from 82.3% to 95.2% as compared to ascorbic acid.

Acute toxicity

From the experiment performed as per the OECD Guidelines 420, the results reveal that the *H. arenicola* extract (HaE), has been found toxic at 5000 mg/kg body weight of experimental animals as in the first 4 h of observation 2/3 morbidity was observed. None of the 6 rats died or showed any sign of toxicity at the limit dose of 2000 mg/kg orally for HaE in the first 48 h. No evidence of toxicity was noted during the period of

Table 1 Percent inhibition of DPPH by *Holothuria arenicola* extract (HaE) and ascorbic acid.

Concentration (mg/ml)	% Inhibition of DPPH by HaE	% Inhibition of DPPH by ascorbic acid
10	82.3 \pm 2.3	95.20 \pm 4.3
20	91.4 \pm 3.2	95.70 \pm 3.1
30	91.6 \pm 2.6	93.50 \pm 3.8
40	92.8 \pm 4.1	95.02 \pm 2.9
50	93.1 \pm 3.8	93.80 \pm 1.9
60	94.7 \pm 5.1	93.20 \pm 2.2
70	95.2 \pm 2.2	94.40 \pm 3.1
80	91.8 \pm 3.8	93.60 \pm 2.2

Values are given as mean \pm SE.

DPPH: 1,1-Diphenyl-2-picrylhydrazyl.

observation. The LD₅₀ was therefore taken as above 2000 mg/kg orally. The median effective dose (ED₅₀) was selected based on the proposed LD₅₀ obtained from the acute toxicity study. This dose was considered one tenth of the proposed LD₅₀, that is, 200 mg/kg body weight.

Antiulcer effects of *H. arenicola* extract (HaE) on gastric lesions

Administration of indomethacin at 150 mg/kg and cold-restraint stress (SGU) caused severe hemorrhagic lesions covering the entire glandular area of the stomach (Table 2). However, oral pre-treatment with HaE and/or RAN significantly reduced the ulcer index, showing 72.50%, 53.11% and 80.56% ulceration inhibition, respectively. In addition, oral post-treatment with HaE and/or RAN reduced significantly the ulcer index, recorded 51.66%, 62.41% and 67.78% ulceration inhibition respectively (Table 2).

Effect of *H. arenicola* extract (HaE) on gastric acid output and gastric acidity

As shown in Table 2, administration of indomethacin at 150 mg/kg and cold stress (SGU) caused a significant increase in the gastric acid output into the gastric lumen (2.80 \pm 0.10) as compared to the normal control group (1.70 \pm 0.08). However, treatment with HaE and/or RAN either pre or post-treatment significantly decreased the gastric acid output. In addition, the level of gastric juice acidity was significantly decreased from 8.61 \pm 0.64 mEq/L in the model group to 3.16 \pm 0.11 mEq/L, 5.73 \pm 0.12 mEq/L and 2.15 \pm 0.19 mEq/L after pre-treatment administration of the HaE and/or RAN respectively (Table 2). Whereas, post-treatment administration of HaE and/or RAN induced a significant decrease in the gastric juice acidity, recording 3.26 \pm 0.13, 5.94 \pm 0.10 and 2.97 \pm 0.09 respectively (Table 2).

Effect of *H. arenicola* extract (HaE) on gastric reduced glutathione (GSH)

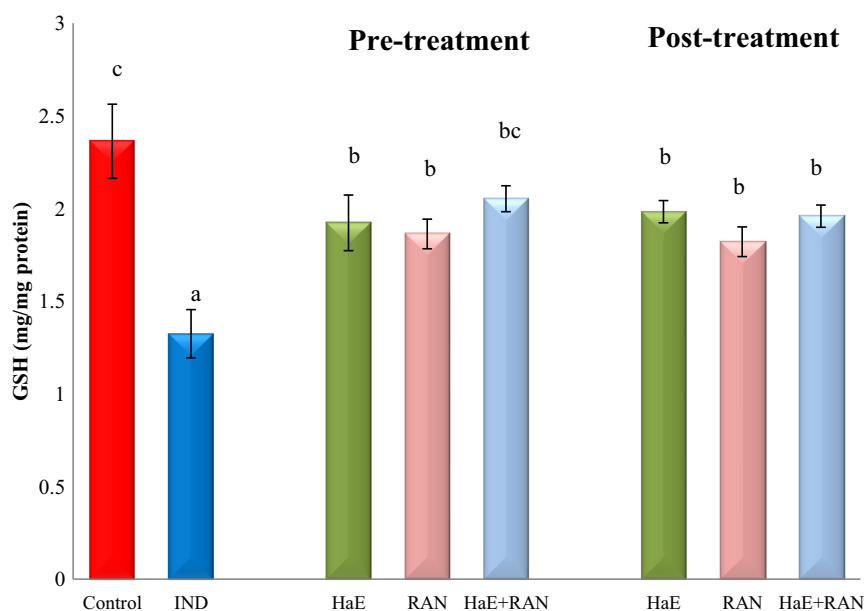
Gastric GSH level of rats administered indomethacin at 150 mg/kg and cold stress (SGU) was decreased significantly ($P < 0.05$) as compared to the control rats (Fig. 1). Pre or post-treatment with HaE and/or RAN significantly increased

Table 2 Antiulcer effects of *Holothuria arenicola* extract (HaE) and/or ranitidine (RAN) on gastric ulcer inhibition, gastric juice volume and total gastric acidity in indomethacin (IND) and cold stress-induced gastric ulcer in rats.

	Group	Gastric ulcer index	Gastric ulcer inhibition (%)	Gastric juice volume (ml)	Total gastric acidity (mEq/L)
Pre-treatment	Control	0	–	1.70 ± 0.08 ^c	4.89 ± 0.11 ^c
	IND	18.62 ± 1.90 ^c	–	2.80 ± 0.10 ^d	8.61 ± 0.64 ^e
	HaE	05.12 ± 1.36 ^{ab}	72.50	1.14 ± 0.06 ^a	3.16 ± 0.11 ^b
	RAN	08.73 ± 2.19 ^b	53.11	1.10 ± 0.07 ^a	5.73 ± 0.12 ^d
Post-treatment	HaE + RAN	03.62 ± 1.18 ^{ab}	80.56	1.48 ± 0.04 ^b	2.15 ± 0.19 ^a
	HaE	09.00 ± 2.47 ^b	51.66	1.04 ± 0.02 ^a	3.26 ± 0.13 ^b
	RAN	07.00 ± 2.53 ^b	62.41	0.96 ± 0.04 ^a	5.94 ± 0.10 ^d
	HaE + RAN	06.00 ± 1.77 ^b	67.78	1.38 ± 0.04 ^b	2.97 ± 0.09 ^b

Values are given as mean ± SE for 8 rats in each group.

Values with different superscript letters are significantly different ($P < 0.05$).

**Figure 1** Effect of *arenicola* extract (HaE) and/or ranitidine (RAN) on gastric glutathione reduced (GSH) content in indomethacin and cold stress induced gastric ulcer in rats.

*Values are given as mean ± SE for 8 rats in each group.

*Values with different superscript letters are significantly different ($P < 0.05$).

($P < 0.05$) the gastric GSH level, as compared to the SGU group (Fig. 1).

Effect of *H. arenicola* extract (HaE) on gastric malondialdehyde (MDA)

Fig. 2 shows that, the level of gastric malondialdehyde (MDA) increased significantly ($P < 0.05$) subsequent to indomethacin at 150 mg/kg and cold stress (SGU) (1.16 ± 0.09) as compared to the control group (0.66 ± 0.05). Administration of HaE and/or RAN either pre or post-treatment decreased ($P < 0.05$) the levels of MDA (Fig. 2).

Effect of *H. arenicola* extract (HaE) on different gastric antioxidant enzymes

Results recorded in Figs. 3–5 show that administration of indomethacin at 150 mg/kg and cold stress (SGU) significantly ($P < 0.05$) decreased the activities of gastric glutathione-S-

transferase (GST), catalase (CAT) and superoxide dismutase (SOD) as compared to the control group. Pre-treatment with HaE and/or RAN increased significantly ($P < 0.05$) GST activity as compared to the GSU group (Fig. 3) while, administration of HaE either alone or with RAN caused a significant increase ($P < 0.05$) in the activities of both CAT and SOD enzymes as compared to the SGU group (Figs. 4 and 5). In the post-treated groups, administration of HaE either alone or with RAN increased significantly ($P < 0.05$) the activities of GST enzyme. Regarding CAT activity, only administration of HaE + RAN increased its activity as compared to the SGU group (Fig. 4). However, post-treatment with HaE and/or RAN caused a significant increase ($P < 0.05$) in the SOD activity as compared to the SGU group (Fig. 5).

Discussion

Peptic ulcer disease is a gastrointestinal disorder defined by mucosal damage associated with peptic ulcer and gastritis

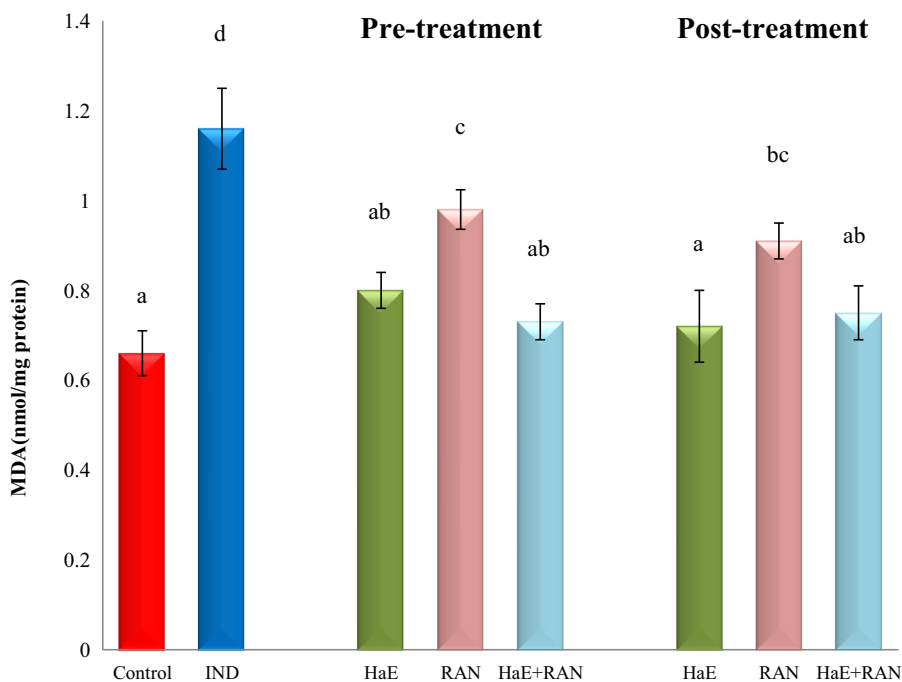


Figure 2 Effect of *arenicola* extract (HaE) and/or ranitidine (RAN) on gastric malondialdehyde (MDA) content in indomethacin and cold stress induced gastric ulcer in rats.

*Values are given as mean \pm SE for 8 rats in each group.

*Values with different superscript letters are significantly different ($P < 0.05$).

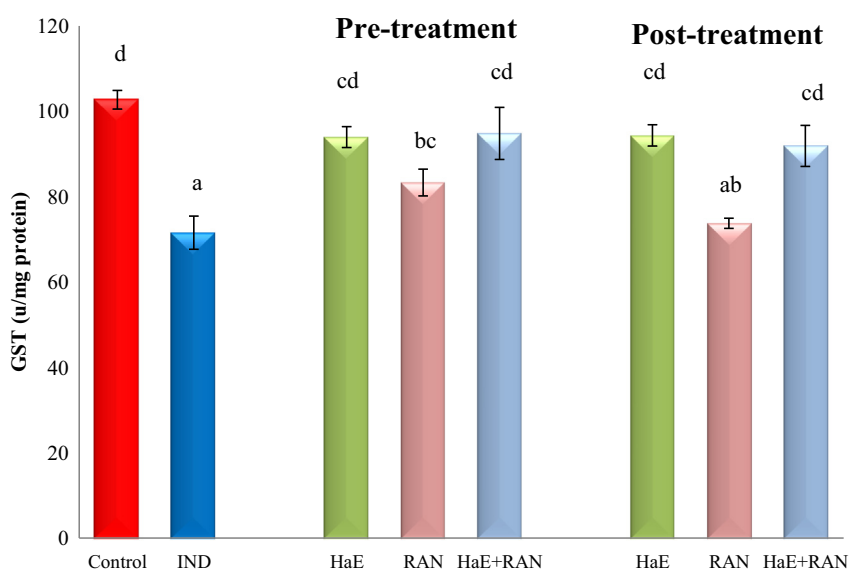


Figure 3 Effect of *arenicola* extract (HaE) and/or ranitidine (RAN) on gastric glutathione-S-transferase (GST) concentration in indomethacin and cold stress induced gastric ulcer in rats.

*Values are given as mean \pm SE for 8 rats in each group.

*Values with different superscript letters are significantly different ($P < 0.05$).

(Ozbayer et al., 2013). Traditional medicines have been used to prevent or treat gastric ulcers for a long time. Accordingly, many natural products have been examined for their anti-ulcerogenic effects (Ozbayer et al., 2013; Choudhary et al., 2014). But, there is no report about the anti-ulcerogenic activity of *Holothuria sp.* until now. So, the present study designed

to assess the anti-ulcerogenic efficacy of *H. arenicola* extract (HaE) against severe gastric ulcer induced by indomethacin and cold stress in rats. Several agents have been tried in experimental animal studies to prevent gastric ulcer injuries caused by NSAIDs (Mei et al., 2013; Ozbayer et al., 2013; Choudhary et al., 2014). These agents can be categorized into

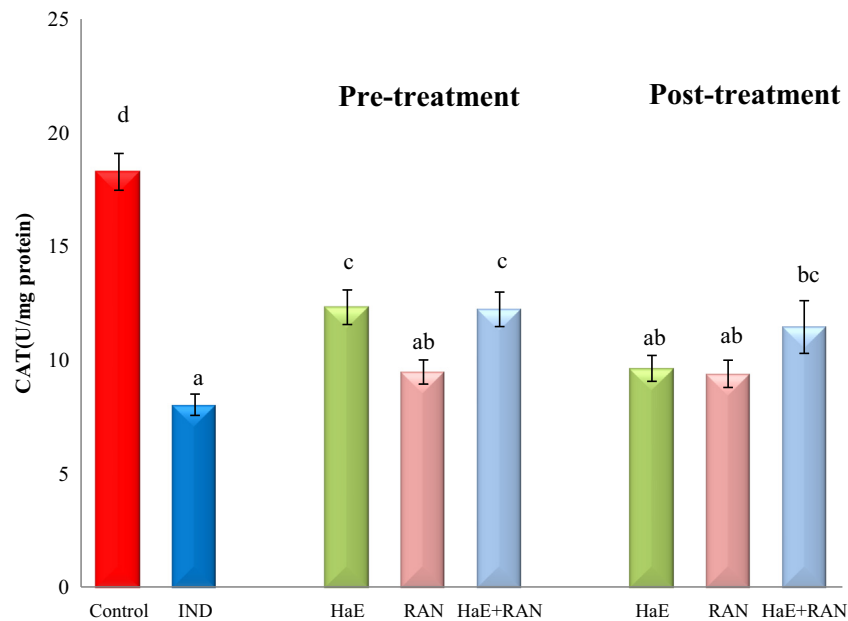


Figure 4 Effect of *Holothuria arenicola* extract (HaE) and/or ranitidine (RAN) on gastric catalase (CAT) activity in indomethacin and cold stress induced gastric ulcer in rats.

*Values are given as mean \pm SE for 8 rats in each group.

*Values with different superscript letters are significantly different ($P < 0.05$).

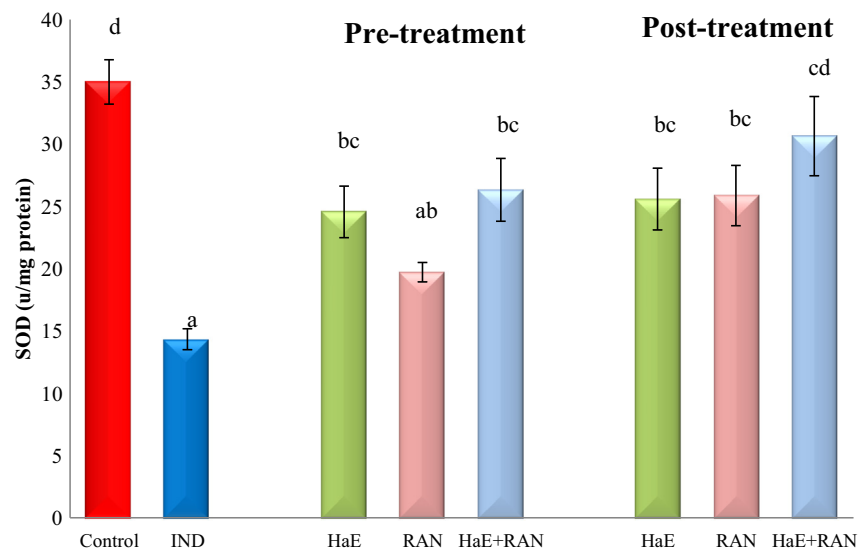


Figure 5 Effect of *arenicola* extract (HaE) and/or ranitidine (RAN) on gastric superoxide dismutase (SOD) activity in indomethacin and cold stress induced gastric ulcer in rats.

*Values are given as mean \pm SE for 8 rats in each group.

*Values with different superscript letters are significantly different ($P < 0.05$).

two groups based on their mode of action: prostaglandin analogs (Sontag et al., 1994) and antioxidants (Mei et al., 2013; Ozbayer et al., 2013).

Indomethacin is known to cause ulcer especially in an empty stomach (Suleyman et al., 2010) and mostly on the mucosal part of the stomach (Nwafor et al., 1996) by inhibition of gastric prostaglandins both through the

cyclooxygenases COX-1 and COX-2 enzyme pathway (Brzozowski et al., 2001) and increased free radical formation (Shoman et al., 2009). Moreover, the hypothermic and restraint stress-induced ulcers are believed to result from an increase in the formation of free radicals (Morsy et al., 2009). In this study, administration of indomethacin coupled with hypothermic and restraint stress causes accumulation of

gastric acid in the stomach and visible and clear gastric ulcer. Prostaglandins function to protect the stomach from injury by stimulating the secretion of mucus and bicarbonate. Gastric acid hypersecretion is one of the major pathogenic factors for the induction of gastric ulcer disease (Tuorkey and Karolin, 2009). In agreement with the report of Nagar et al. (2012), gastric ulcer lesion recorded following indomethacin administration in the present study may be due to suppression of prostaglandin synthesis, which increased gastric acidity and subsequently stomach susceptibility to mucosal injury. Most therapeutic agents are used to inhibit the gastric acid secretion or to boost the mucosal defense mechanisms by increasing mucosal production, stabilizing the surface epithelial cells (Tiwari et al., 2012). In the present study, HaE administration significantly decreased the gastric acidity and gastric ulcer index either alone or in combination with ranitidine during pre or post treatment which may be due to reductions in gastric acid and gastric cytoprotection. It was reported that sea cucumber could facilitate wound healing besides reducing gastric ulcer, and inflammation (Ridzwan, 2010). Since sea cucumber feeds on bottom sediment, it should contain high levels of branched chain fatty acids, believed to be the substances that facilitate in wound repair (Subramaniam et al., 2013). HaE may stimulate gastric mucosal cellular growth and repair by the same mechanism of wound healing.

Gastric ulcers form as a result of a multifaceted process which includes acid secretion, reactive oxygen species (ROS) generation and extracellular matrix (ECM) degradation (Mei et al., 2013). ROS can damage cellular lipids, proteins, and DNA leading to oxidative stress (Droge, 2002). Oxidative stress plays an important role in gastric mucosal damage (Bhattacharyya et al., 2014). In particular, generation of oxygen free radicals and lipid peroxidation play a key role in the development of the gastric mucosal lesions induced by indomethacin (Vemula et al., 2012; Abbas and Sakr, 2013). The present study confirmed the finding of Ajeigbe et al. (2012) and Abbas and Sakr (2013), who recorded elevations in the levels of the end products of lipid peroxidation, malondialdehyde (MDA) in the gastric tissues following indomethacin treatment. It was reported that, the oxidative stress in gastric tissue causes damage to key biomolecules such as lipids. This was apparent from the stimulated lipid oxidation leading to increased accumulation of MDA. Levels of MDA are thought to reflect free radical mediated cell membrane damage. As shown in the present results, HaE pre or post-treatment and/or ranitidine significantly reverted the indomethacin-induced changes in MDA, suggesting that the mechanism of both ranitidine and HaE anti-ulcerogenic effects may be due to its antioxidant effect (Ardestani et al., 2004).

Glutathione reduced (GSH) protect cells against free radicals, peroxides and other toxic compounds (Hiraishi et al., 1994). Depletion of gastric mucosal GSH may result in the accumulation of free radicals that can initiate membrane damage by lipid peroxidation. In consonance with our study Abbas and Sakr (2013) and Mei et al. (2013), have reported depletion in GSH level in the gastric tissues of indomethacin treated rats. Gastric damage depleted the GSH levels acting as the first line of cellular defense against oxidative injury. This might lead to aggravated tissue damage during stomach ulceration (El-Missiry et al., 2001). Treatment with ranitidine and HaE either pre or post-treatment in the present study

restored GSH content. HaE provided a marked suppression of oxidative damage through excellent radical scavenging activity to DPPH radical. Moreover, many dietary polyphenols are antioxidants, and the possibility exists that they protect against oxidative damage by directly neutralizing reactive oxidants (Moskaug et al., 2005). The body wall of the sea cucumbers contains high amounts of phenolic compounds (Althunibat et al., 2009). HaE phenolic contents may exert the scavenging activities by donating a hydrogen atom from their phenolic hydroxyl groups (Mustafa et al., 2010). So, HaE may be an effective source of direct precursors for salvage GSH biosynthesis.

The endogenous anti-oxidant enzymes CAT, SOD, and GST in the gastric mucus are the key component of cellular defense system against reactive oxygen species (Nartey et al., 2012). However, SOD destroys the highly reactive radical superoxide ($O_2^{\cdot-}$) by converting it into the less reactive peroxide (H_2O_2), which can be destroyed by a CAT reaction. CAT is a highly reactive enzyme that reacts with H_2O_2 to form water and molecular oxygen. Viewed in conjunction with the report of Kaplan et al. (2012), Abbas and Sakr (2013) and Badr and Al-Mulhim (2014) the inhibition of CAT, SOD and GST activities following indomethacin treatment in the present study may be due to the enhancement of the MDA, which is known to inhibit protein synthesis and the activities of certain enzymes. These observations confirm the findings of several studies, which reported alterations in anti-oxidant enzyme activities in indomethacin exposed animals (Abbas and Sakr, 2013; Mei et al., 2013; Badr and Al-Mulhim, 2014). Administration of HaE pre or post-treatment and/or ranitidine enhanced the activities of CAT, SOD and GST in indomethacin-induced peptic ulcer. The enhancement in the activities of the studied enzymes may be to prevent the accumulation of excessive free radicals and protect stomach from ulcer formation, suggesting that the anti-ulcerogenic effect of HaE against oxidative stress-induced injury might be involved in decreasing lipid peroxide generation and stimulating antioxidant enzyme.

In conclusion, the present study confirms that HaE decreased lipid peroxidation, improved antioxidant status and activation of free radical scavenging enzymes, thereby could be a good new treatment for gastric ulcer. The study also demonstrated that the combination of HaE and ranitidine compared to an individual use of HaE or ranitidine has more potent therapeutic effect. Therefore we suggest that HaE may be used as a complementary drug with the recommended anti-ulcer drugs for gastric ulcer healing in humans.

References

- Abbas, A.M., Sakr, H.F., 2013. Effect of selenium and grape seed extract on indomethacin-induced gastric ulcers in rats. *J. Physiol. Biochem.* 69 (3), 527–537.
- Aebi, H., 1984. Catalase in vitro. *Methods Enzymol.* 105, 121–126.
- Ajeigbe, K., Oladejo, E., Emikpe, B., Asuk, A., Olaleye, S., 2012. The dual modulatory effect of folic acid supplementation on indomethacin-induced gastropathy in the rat. *Turk. J. Gastroenterol.* 23 (6), 639–645.
- Althunibat, O.S., Hashim, R.B., Taher, M., Daud, J.M., Ikeda, M., Zali, I., 2009. In vitro antioxidant and antiproliferative activities of three Malaysian sea cucumber species. *Eur. J. Sci. Res.* 37, 376–387.

- Ansari, K.F., Lal, C., 2009. Synthesis and evaluation of some new benzimidazole derivatives as potential antimicrobial agents. *Eur. J. Med. Chem.* 44 (5), 2294–2299.
- Arai, I., Hirose, H., Usuki, C., Muramatsu, M., Aihara, H., 1987. Effects of indomethacin and cold stress on gastric acid secretion and ulceration. The effects of anti-acid secretory agents in rats. *Res. Commun. Chem. Pathol. Pharmacol.* 57 (3), 313–327.
- Ardestani, S.K., Janlow, M.M., Kariminia, A., Tavakoli, Z., 2004. Effect of cimetidine and ranitidine on lipid profile and lipid peroxidation in γ -irradiated mice. *Acta Med. Iran* 42, 198–204.
- Aykac, G., Uysal, M., Yalcin, A., Kocak-Toker, N., Sivas, A., Oz, H., 1985. The effect of chronic ethanol ingestion on hepatic lipid peroxide, glutathione, glutathione peroxidase and glutathione transferase in rats. *Toxicology* 36 (1), 71–76.
- Badr, G.M., Al-Mulhim, J.A., 2014. The protective effect of aged garlic extract on nonsteroidal anti-inflammatory drug-induced gastric inflammations in male albino rats. *Evid. Based Complement. Altern. Med.* 2014, 759642.
- Bahrami, Y., Zhang, W., Franco, C., 2014. Discovery of novel saponins from the viscera of the sea cucumber *Holothuria lessona*. *Mar. Drugs* 12 (5), 2633–2667.
- Bhattacharyya, A., Chattopadhyay, R., Mitra, S., Crowe, S.E., 2014. Oxidative stress: an essential factor in the pathogenesis of gastrointestinal mucosal diseases. *Physiol. Rev.* 94 (2), 329–354.
- Brzozowski, T., Konturek, P.C., Konturek, S.J., et al., 2001. Classic NSAID and selective cyclooxygenase (COX)-1 and COX-2 inhibitors in healing of chronic gastric ulcers. *Microsc. Res. Tech.* 1, 343–353.
- Choudhary, M., Kumar, V., Singh, S., 2014. Gastric antisecretory and cytoprotective effects of hydroalcoholic extracts of *Plumeria alba* Linn. leaves in rats. *J. Integr. Med.* 12 (1), 42–51.
- Droge, W., 2002. Free radicals in the physiological control of cell function. *Physiol. Rev.* 82, 47–95.
- El-Missiry, M.A., El-Sayed, I.H., Othman, A.I., 2001. Protection by metal complexes with SOD mimetic activity against oxidative gastric injury induced by indomethacin and ethanol in rats. *Ann. Clin. Biochem.* 38, 694–700.
- Fukushima, E., Monoi, N., Mikoshiba, S., Hirayama, Y., Serizawa, T., Adachi, K., Koide, M., Ohdera, M., Murakoshi, M., Kato, H., 2014. Protective effects of acetaminophen on ibuprofen-induced gastric mucosal damage in rats with associated suppression of matrix metalloproteinase. *J. Pharmacol. Exp. Ther.* 349 (1), 165–173.
- Gulcin, I., 2012. Antioxidant activity of food constituents: an overview. *Arch. Toxicol.* 86 (3), 345–391.
- Habig, W., Pabst, M., Jakpby, W., 1974. *J. Biol. Chem.* 249, 7130–7139.
- Hamel, J.F., Mercier, A., 2004. Synchronous gamete maturation and reliable spawning induction method in holothurians. In: Lovatelli, A., Conand, C., Purcell, S., Uthicke, S., Hamel, J.-F., Mercier, A. (Eds.), *Advances in Sea Cucumber Aquaculture and Management*. FAO Fisheries Technical Reports No. 463. FAO, Rome, p. 425 (359–372).
- Hiraishi, H., Terano, A., Ota, S., Mutoh, H., Sugimoto, T., Harada, T., Razandi, M., Ivey, K.J., 1994. Protection of cultured rat gastric cells against oxidant-induced damage by exogenous glutathione. *Gastroenterology* 106, 1199–1207.
- Kaplan, K.A., Odabasoglu, F., Halici, Z., Halici, M., Cadirci, E., Atalay, F., Aydin, O., Cakir, A., 2012. Alpha-lipoic acid protects against indomethacin-induced gastric oxidative toxicity by modulating antioxidant system. *J. Food Sci.* 77 (11), 224–230.
- Kilada, R.W., Abdel Razek, F.A., Yassin, M.H., 2000. Population growth and sexual reproduction of the sea cucumber *Holothuria arenicola* from the Eastern Mediterranean Egypt. *J. Aquat. Bull. Fish.* 4 (4), 119–135.
- Kleiman-Wexler, R.L., Adair, C.G., Ephgrave, K.S., 1989. Pharmacokinetics of naloxone: an insight into the locus of effect on stress-ulceration. *J. Pharmacol. Exp. Ther.* 251, 435–438.
- Mei, X.T., Xu, D.H., Xu, S.K., Zheng, Y.P., Xu, S.B., 2013. Zinc(II)-curcumin accelerates the healing of acetic acid-induced chronic gastric ulcers in rats by decreasing oxidative stress and downregulation of matrix metalloproteinase-9. *Food Chem. Toxicol.* 60, 448–454.
- Morsy, M., Ashour, O., Amin, E., et al., 2009. Gastroprotective effects of telmisartan on experimentally-induced gastric ulcers in rats. *Pharmazie* 64, 590–594.
- Moskaug, J.Ø., Carlsen, H., Myhrstad, M.C.W., Blomhoff, R., 2005. Polyphenols and glutathione synthesis regulation. *Am. J. Clin. Nutr.* 81 (Suppl.), 277S–283S.
- Mustafa, R.A., Abdul Hamid, A., Mohamed, S., Bakar, F.A., 2010. Total phenolic compounds, flavonoids, and radical scavenging activity of 21 selected tropical plants. *J. Food Sci.* 75 (1), 28–35.
- Nagar, H., Tiwari, P., Jain, D.K., Chandel, H.S., 2012. Evaluation of anti-ulcer activity of stem bark extract of *Aphanamixis polystachya* in experimental rat. *Indian J. Pharm. Educ. Res.* 46 (3), 222–227.
- Nartey, E.T., Ofosuhene, M., Agbale, C.M., 2012. Anti-ulcerogenic activity of the root bark extract of the African laburnum “*Cassia sieberiana*” and its effect on the anti-oxidant defence system in rats. *BMC Complement. Altern. Med.* 10 (12), 247.
- Nishikimi, M., Roa, N.A., Yogi, K., 1972. The occurrence of superoxide anion in the reaction of reduced phenazine methosulfate and molecular oxygen. *Biochem. Biophys. Res. Commun.* 46, 849–854.
- Nwafor, P.A., Effraim, K.D., Jacks, T.W., 1996. Gastroprotective effects of aqueous extracts of *Khaya senegalensis* bark on indomethacin induced ulceration in rats. *West Afr. J. Pharmacol. Drug Res.* 12, 46–50.
- Ohkawa, H., Ohishi, N., Yagi, K., 1979. Assay for lipid peroxides in animal tissues by thiobarbituric acid reaction. *Anal. Biochem.* 95, 351–358.
- Okayama, T., Yoshida, N., Uchiyama, K., Takagi, T., Ichikawa, H., Yoshikawa, T., 2009. Mast cells are involved in the pathogenesis of indomethacin-induced rat enteritis. *J. Gastroenterol.* 44 (19), 35–39.
- Ononye, S.N., VanHeyst, M.D., Oblak, E.Z., Zhou, W., Ammar, M., Anderson, A.C., Wright, D.L., 2013. Tropolones as lead-like natural products: the development of potent and selective histone deacetylase inhibitors. *ACS Med. Chem. Lett.* 4 (8), 757–761.
- Ozbayer, C., Kurt, H., Ozdemir, Z., Tuncel, T., Moheb Saadat, S., Burukoglu, D., Senturk, H., Degirmenci, I., Gunes, H.V., 2013. Gastroprotective, cytoprotective and antioxidant effects of *Oleum cinnamomi* on ethanol induced damage. *Cytotechnology* (Epub ahead of print).
- Rang, H.P., Dale, M.M., Ritter, M., Moore, P.K. (Eds.), 2003. *Pharmacology*, fifth ed. Churchill, Livingstones, Edinburgh (pp. 797).
- Retana-Márquez, S., Bonilla-Jaime, H., Vázquez-Palacios, G., Domínguez-Salazar, E., Martínez-García, R., Velázquez-Moctezuma, J., 2003. Body weight gain and diurnal differences of corticosterone changes in response to acute and chronic stress in rats. *Psychoneuroendocrinology* 28 (2), 207–227.
- Ridzwan, B.H., 2007. *Sea Cucumber: The Malaysian Heritage*. Research Centre, IUM, Kuala Lumpur, Malaysia.
- Ridzwan, B.H., 2010. *Sea Cucumbers*, A. Malaysian Heritage, first ed. Research Management Centre of International Islamic University Malaysia (IUM), Kuala Lumpur Wilayah Persekutuan, Malaysia (pp. 2).
- Robbin, S.L., Kumar, V., Ramzi, C., 2009. Acute and chronic inflammation, eighth ed.. In: *Basic Pathology* W.B. Company, Philadelphia (pp. 31–58).
- Sanchez-Moreno, C., Larrauri, J.A., Saura-Calixto, F., 1998. A procedure to measure the antiradical efficiency of polyphenol. *J. Sci. Food Agric.* 76 (2), 270–276.
- Shoman, M.E., Abdel-Aziz, M., Aly, O.M., et al., 2009. Synthesis and investigation of anti-inflammatory activity and gastric

- ulcerogenicity of novel nitric oxide-donating pyrazoline derivatives. *Eur. J. Med. Chem.* 44, 3068–3076.
- Sontag, S.J., Schnell, T.G., Budiman-Mak, E., Adelman, K., Fleischmann, R., Cohen, S., Roth, S.H., Ipe, D., Schwartz, K.E., 1994. Healing of NSAID-induced gastric ulcers with a synthetic prostaglandin analog (enprostil). *Am. J. Gastroenterol.* 89 (7), 1014–1020.
- Subramaniam, B.S., Amuthan, A., D'Almeida, P.M., Arunkumar, H.D., 2013. Efficacy of gamat extract in wound healing in albino wistar rats. *Int. J. Pharm. Sci. Rev. Res.* 20 (1), 142–145.
- Sugawara, T., Zaima, N., Yamamoto, A., Sakai, S., Noguchi, R., Hirata, T., 2006. Isolation of sphingoid bases of sea cucumber cerebrosides and their cytotoxicity against human colon cancer cells. *Biosci. Biotechnol. Biochem.* 70, 2906–2912.
- Suleyman, H., Albayrak, A., Bilici, M., Cadirci, E., Halici, Z., 2010. Different mechanisms in formation and prevention of indomethacin-induced gastric ulcers. *Inflammation* 33 (4), 224–234.
- Suzuki, H., Nishizawa, T., Tsugawa, H., Mogami, S., Hibi, T., 2012. Roles of oxidative stress in stomach disorders. *J. Clin. Biochem. Nutr.* 50 (1), 35–39.
- Takeuchi, K., Miyazawa, T., Tanaka, A., Kato, S., Kunikata, T., 2002. Pathogenic importance of intestinal hypermotility in NSAID induced small intestinal damage in rats. *Digestion* 66, 30–41.
- Thong-Ngam, D., Choochuai, S., Patumraj, S., Chayanupatkul, M., Klaikeaw, N., 2012. Curcumin prevents indomethacin induced gastropathy in rats. *World J. Gastroenterol.* 18 (13), 1479–1484.
- Tiwari, D.K., Tripathi, R.K., Jena, J., 2012. Evaluation of antiulcer and antianxiety activity of *Aphanamixis polystachya* stem bark extract on rats. *Int. J. Pharm. Pharm. Sci.* 5 (1), 148–151.
- Tuorkey, M., Karolin, K., 2009. Antiulcer activity of curcumin on experimental gastric ulcer in rats and its effect on oxidative stress/ antioxidant, IL6 and enzyme activities. *Biomed. Environ. Sci.* 22, 488495.
- Vanden Heuvel, M.J., Clark, D.G., Fielder, R.J., Koundakjian, P.P., Oliver, G.J.A., Pelling, D., Tomlinson, N.J., Walker, A., 1990. The international validation of a fixed-dose procedure as an alternative to the classical LD₅₀ test. *Food Chem. Toxicol.* 28, 469–482.
- Vemula, S.K., Chawada, M.B., Thakur, K.S., Vahalia, M.K., 2012. Antiulcer activity of Amlapitta Mishran suspension in rats: a pilot study. *Anc. Sci. Life* 32 (2), 112–115.
- Whitehead, A., Curnow, R.N., 1992. Statistical evaluation of the fixed-dose procedure. *Food Chem. Toxicol.* 30, 313–324.
- Yasumoto, T., Nakamura, K., Hashimoto, Y., 1967. A new saponin holothuria B isolated from sea cucumber *Holothuria vagabunda* and *Holothuria lubrica*. *Agric. Biol. Chem.* 31, 7–10.